

Combined endovascular repair of aorta and removal of penetrating pedicle screw after posterior instrumentation: a case report and literature review

Giroto, Dean Giroto; Burić, Josip; Šimić, Hrvoje; Tomulić, Vjekoslav; Jakljević, Tomislav; Kvas, Zvonimir

Source / Izvornik: **Acta clinica Croatica, 2024, 63., 422 - 430**

Journal article, Published version

Rad u časopisu, Objavljena verzija rada (izdavačev PDF)

<https://doi.org/10.20471/acc.2024.63.02.20>

Permanent link / Trajna poveznica: <https://um.nsk.hr/um:nbn:hr:184:485783>

Rights / Prava: [Attribution-NonCommercial-NoDerivatives 4.0 International/Imenovanje-Nekomercijalno-Bez prerada 4.0 međunarodna](#)

Download date / Datum preuzimanja: **2025-03-10**



Repository / Repozitorij:

[Repository of the University of Rijeka, Faculty of Medicine - FMRI Repository](#)





COMBINED ENDOVASCULAR REPAIR OF AORTA AND REMOVAL OF PENETRATING PEDICLE SCREW AFTER POSTERIOR INSTRUMENTATION: A CASE REPORT AND LITERATURE REVIEW

Dean Giroto¹, Josip Burić¹, Hrvoje Šimić¹, Vjekoslav Tomulić², Tomislav Jakljević² and Zvonimir Kvas¹

¹Department of Neurosurgery, Rijeka University Hospital Center, Rijeka, Croatia;

²Department of Cardiovascular Diseases, Rijeka University Hospital Center, Rijeka, Croatia

SUMMARY – Stabilization of spine using transpedicular screws is the most commonly used instrumentation technique among spinal surgeons. The ‘free hand’ technique is considered relatively safe and can be performed under x-ray control. Vascular injuries with misplaced screws are rare but potentially fatal complications. Injury of thoracoabdominal aorta by malpositioned screw demands a multidisciplinary approach. Injury of vessel wall might demand screw removal and vessel wall repair. Here we present a case of 72-year-old female patient who underwent long segment fixation of thoracolumbar spine. During follow up, computed tomography (CT) scan and afterwards aortography showed a lesion of the posterior aortic wall by malpositioned screw without signs of bleeding. After meticulous preparation, combined endovascular repair with stent-graft and removal of the penetrating screw were performed. Endovascular treatment was performed simultaneously with screw removal. During screw removal, the patient was in lateral decubital position. The patient was discharged on postoperative day 8. Follow up CT aortography 6 months later showed no leak or other changes in the aorta. We found combined endovascular vessel repair with simultaneous screw removal safe and sufficient for this kind of aortic injury. Although lateral decubital position bears limitations, it gives enough space for the operator. Performing intraoperative aortography provides good insight into stent position and possible bleeding after screw removal.

Key words: Pedicle screw; Endovascular repair; Aortic injury

Introduction

Instrumented fusion for the treatment of degenerative spine conditions is nowadays a common and widely used technique among spinal surgeons. Stabilization of spine using transpedicular screws is the strongest stabilization system in use^{1,2}. Placing

of a transpedicular screw in the vertebral body using the ‘free hand’ technique is considered a relatively safe technique that can be performed under intraoperative x-ray control. However, optimal placement of pedicle screw often presents a substantial surgical challenge especially in cases of severe spinal deformity. Every surgeon must have in mind that changes of vertebral body position due to sagittal or lateral bending also reflect on the surrounding anatomical structures^{1,2}. For increased accuracy and reduction of screw malpositioning, screws can be placed under intraoperative navigation.

Correspondence to: *Zvonimir Kvas, MD*, Department of Neurosurgery, Rijeka University Hospital Center, Krešimirova 42, HR-51000 Rijeka, Croatia

E-mail: zvonimirkvas@gmail.com

Received August 22, 2023, accepted October 23, 2023

Vascular injuries are rare but well-known complications of spinal instrumentation especially at the upper thoracic spine, and although their incidence is not precisely defined, it is considered to be low¹⁻³. In their paper, Hicks *et al.*, systematically reviewed 14570 pedicle screws placed in thoracic or lumbar spine of 1666 patients and found only 0.7% screws to have come in contact with the aorta, without major vessel complications reported⁴. The incidence of major vessel injury by pedicle screw does not vary significantly among other authors, but the overall opinion is that the incidence of vascular injuries is underreported^{1,4-6}. Injury of thoracoabdominal aorta by a malpositioned screw most often demands a multidisciplinary approach to the patient. Presentation of injury can vary from dramatic acute bleeding due to perforation of blood vessel to completely asymptomatic patients. In some cases, pseudoaneurysm or thrombotic formation can be found. However, most frequently the finding is incidental, i.e., observed during routine radiological follow up^{1,2,4,7-9}. Delayed injury can occur due to movement of the screw (e.g., body collapse and possible screw breakthrough) that penetrates the periaortic space even 20 years after initial operation was performed^{5,10}. When the aortic wall is injured, general opinion is that the penetrating screw should be removed, while for screws impinging to vessels there is no clear treatment opinion in the literature^{3,5,8}. Valič *et al.* proposed an algorithm for the treatment of suspected aortic wall injury with pedicle screw as the only available evidence-based literature for adverse vascular events⁹. In some other cases, only radiological follow up is recommended as a precaution measure^{1,3,9}. Treatment options for aortic lesions due to screw penetration include endovascular repair, open surgical repair, or a combination of both with or without removal of the malpositioned screw. In this article, we report our experience in a case of aortic wall injury with malpositioned pedicle screw. Relevant available literature regarding management of the potential vascular complications after spine surgery is reviewed.

Case Report

A 72-year-old female patient was previously treated for osteoporotic L2 body fracture with absolute stenosis of the spinal canal. Primary surgery included transpedicular stabilization two levels above and two

levels below the fractured vertebra and decompression without vertebral body collapse correction. During follow up examination after a few years, the patient complained of increased low back pain with inability to maintain upright posture. Radiological assessment showed failure of the hardware and new L5 vertebral body fracture occurred. Her back pain was accentuated with loading during standing position and the patient developed limitation in walking with the range of movement limited to short distance (Fig. 1). Considering the symptoms and radiological findings, it was decided to perform a revision surgery for correction of the fracture and re-alignment of the sagittal balance. Transpedicular fixation from Th9 to S1 with pelvic alar screw was done, combined with a posterolateral corpectomy of the collapsed L2 body and L1-L3 interbody fusion with Harms cage and autologous bone (Fig. 2). Postsurgical course was uneventful, the patient was mobilized with thoraco-lumbo-sacral orthosis and was discharged on postoperative day 8. A month later, the patient was readmitted due to acute back pain after fall on the back and difficult ambulation. Computed tomography (CT) scan of thoracolumbar spine showed no additional fractures or hardware failure but eventually showed malposition of the left pedicle screw at Th11 level, which was outside the vertebral body and penetrated the periaortic space. Further examination, angiography and CT aortography were performed and showed lesion of the posterior aortic wall by the malpositioned screw that was penetrating inside the vessel by approximately 3.5 mm (Fig. 3). However, no periaortic contrast extravasation signs were observed nor the patient complained of symptoms that could be connected with it. A multidisciplinary consultation with vascular surgeon and interventional radiologist/cardiologist (in our institution, endovascular repair of thoracic aorta is performed by cardiologist) was arranged and it was decided to perform screw removal using a combined approach, i.e., endovascular repair of the aorta and removal of the malpositioned screw in the same act. The surgery was performed in angiography theater (cath lab), but we had operating room prepared for immediate conversion to open surgery in case of uncontrolled hemorrhage. Initially, the patient was in supine position for endovascular catheter placement through the right femoral artery and another one through the left femoral artery. Aortography and

intravascular ultrasound (IVUS) were performed to demonstrate clear screw penetration in the aorta by approximately 0.7 cm. Then, the patient was turned to the right lateral position for posterior approach to the spine for screw removal. Intravascular-balloon catheter was placed proximally to the lesion as a prophylactic measure for vessel occlusion if major bleeding should occur. The initial plan was to place a short stent-graft at the affected aortic segment to avoid possible occlusion of the supplying arteries to the spinal cord and possible spinal cord ischemia. It was supposed to be gradually deployed as the screw removal would proceed. However, after screw removal and stent deployment (BeGraft 22x48 mm), it migrated caudally below the level of the lesion and major bleeding was observed originating from the screw path, and follow

up aortography showed leakage. Due to this event, a longer self-expandable stent graft was positioned above the short one and deployed (Valiant 26x150 mm). Follow up aortography and IVUS showed satisfactory position of the implanted graft, without any further signs of periaortic contrast leak. Malpositioned screw in Th12 was removed and rods were connected (Fig. 4). The patient was stable throughout the procedure. Postoperatively, the patient was admitted in the Intensive Care Unit for the first postoperative night and removed to the ward on the next morning. The patient recovered well without complications and was discharged on postoperative day 8. CT aortography obtained at 6 months showed no contrast leak or any other changes in the affected aorta.

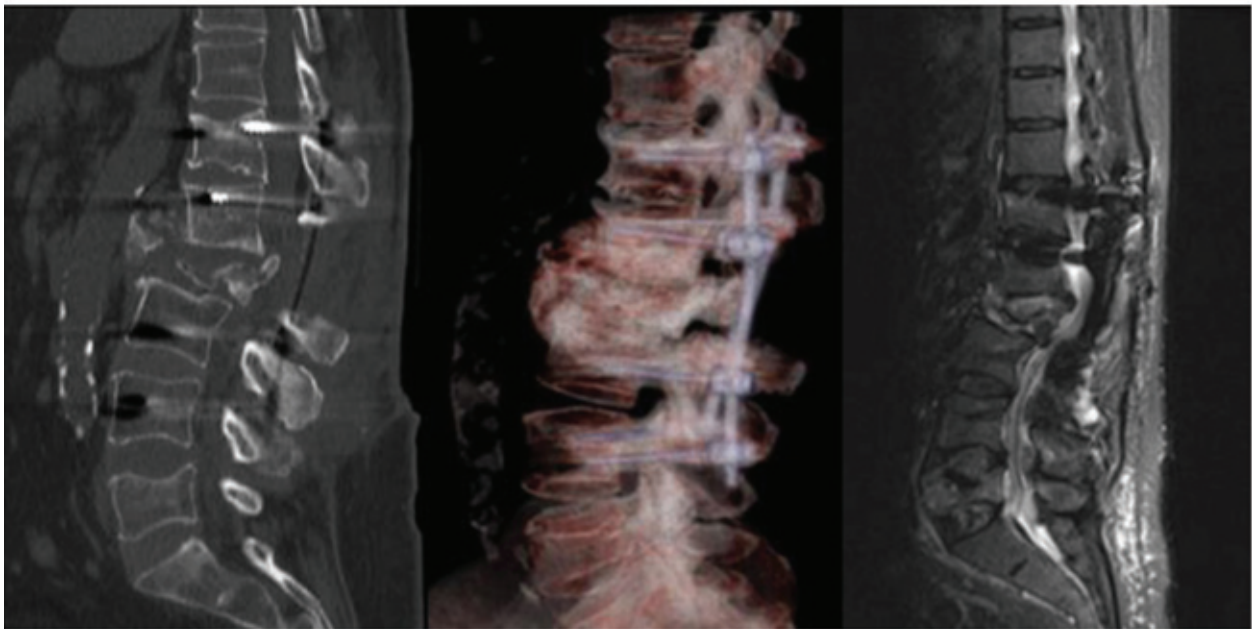


Fig. 1. Preoperative computed tomography scan, with reconstruction, and magnetic resonance imaging.

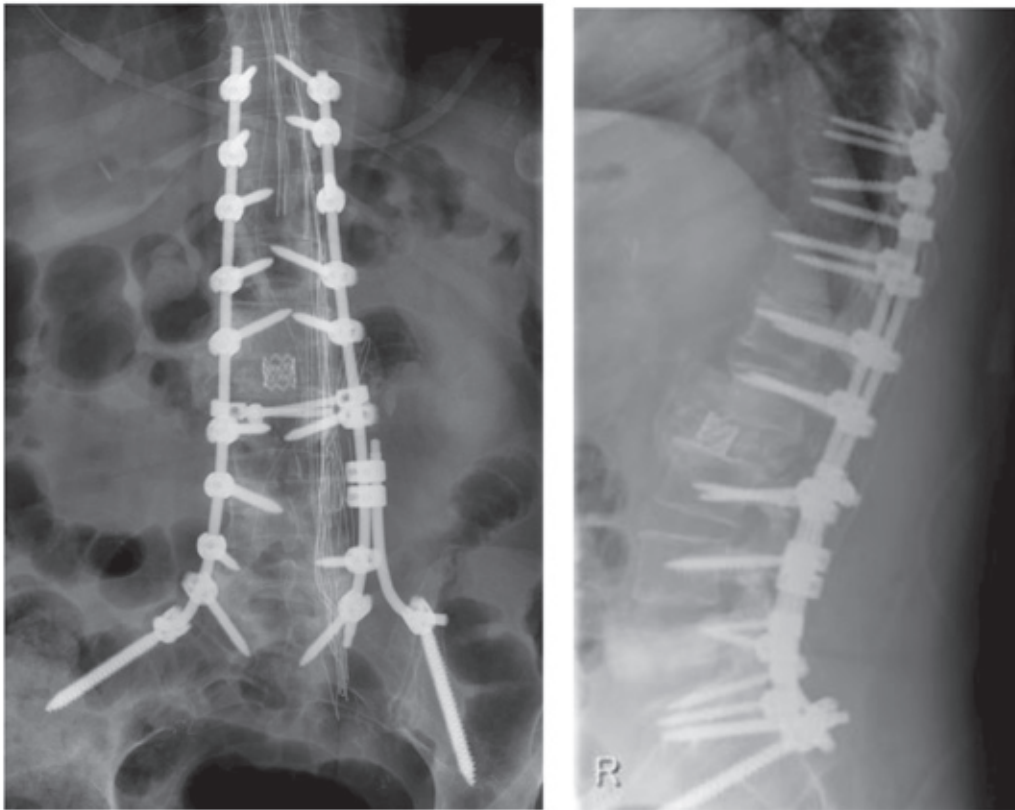


Fig. 2. Postoperative anteroposterior and profile radiogram.

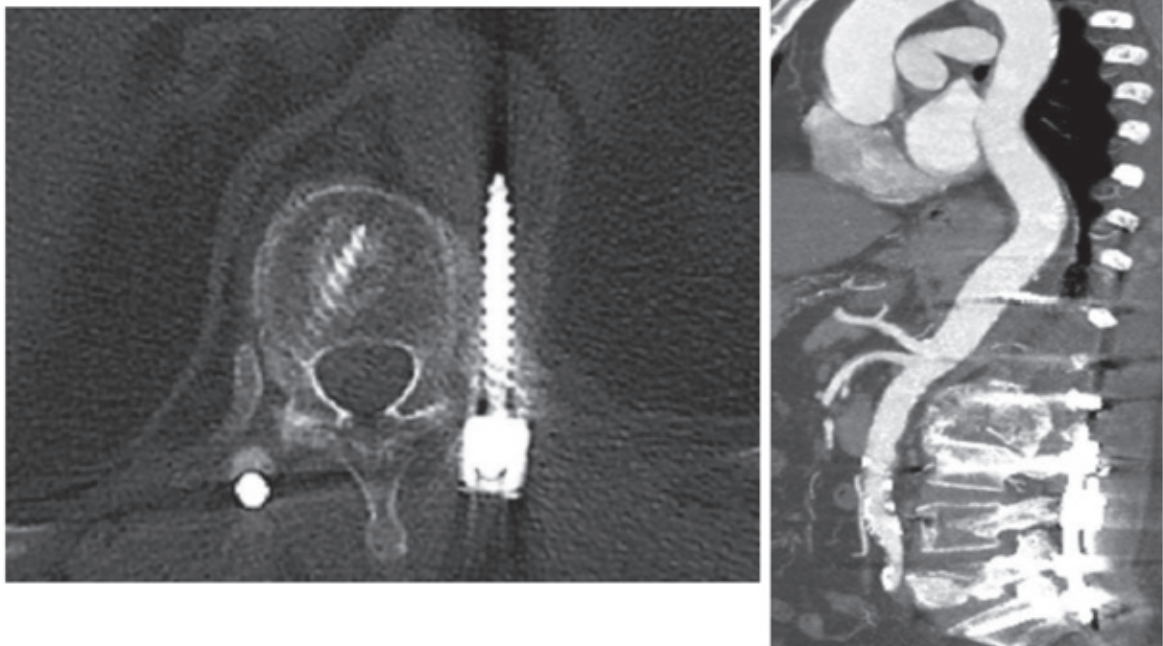


Fig. 3. Computed tomography of thoracic spine showing misplaced left pedicle screw in Th 11; computed tomography aortogram showing the tip of the screw penetrating vessel wall.

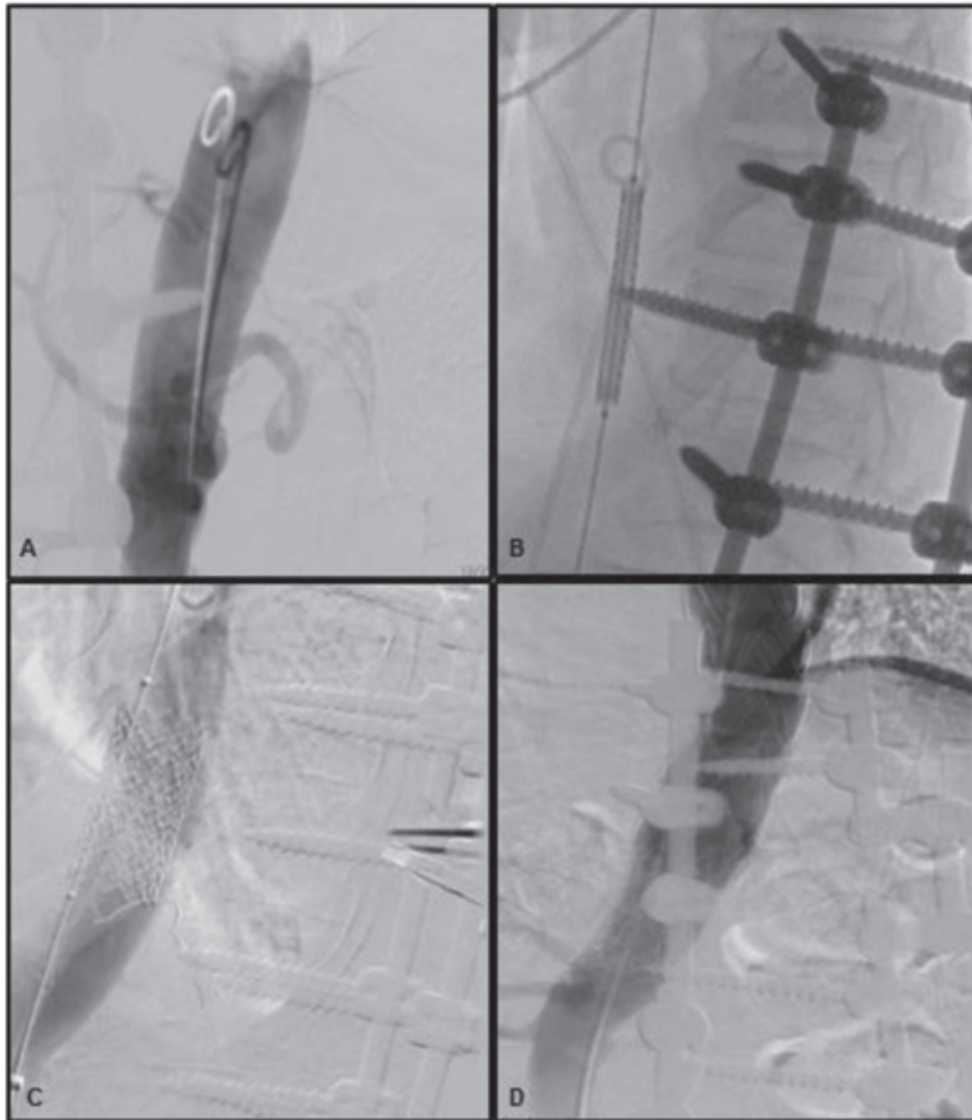


Fig. 4. (A) Intraoperative aortography; (B) stent placing at the level of aortic lesion; (C) initial stent positioned; (D) final aortography, rod continuity established with side connectors and traversing rod.

Literature Review

We searched the PubMed database for case reports using the search terms “aortic injury” and „pedicle screw“, which yielded 78 results. Titles and abstracts were reviewed, and 16 papers reporting aortic lesions due to misplaced pedicle screw where endovascular surveillance or repair had been performed, were analyzed. Six papers where there was no removal of

misplaced screw or the cause of spine pathology was fresh trauma were excluded. Eventually, 10 papers, all single case reports were analyzed^{5,7,8,12,13,15,17-19,21}. A list of analyzed papers of aortic lesions due to misplaced pedicle screw in spine deformity surgery that included endovascular surveillance or repair and removal of misplaced screw is shown in Table 1.

Table 1. List of case reports of aortic lesion endovascular repair and penetrating pedicular screw removal

| Author | Year | Level | Pathology | Presentation | Aortic lesion | Endovascular intervention |
|-------------------------------------|------|--------|-------------------------------|-------------------|---------------------------------|---------------------------|
| Minor <i>et al.</i> ¹⁸ | 2004 | T5 | Degenerative kyphoscoliosis | Incidental | Penetration | Stent graft |
| Hu <i>et al.</i> ¹⁷ | 2009 | T5 | Pyogenic spondylitis | Incidental | Impingement | Stent graft |
| Clarke <i>et al.</i> ⁸ | 2011 | T6 | Burst fracture (osteoporotic) | Incidental | Penetration | Stent graft |
| Potter <i>et al.</i> ⁵ | 2013 | T6 | Tumor | Mid-thoracic pain | Impingement | None |
| Pesenti <i>et al.</i> ¹⁵ | 2014 | T7 | Degenerative kyphoscoliosis | Incidental | Partial penetration | Stent graft |
| Tong <i>et al.</i> ¹² | 2015 | T11 | Earlier operated fracture | Incidental | Impingement | Stent graft |
| Mirza <i>et al.</i> ²¹ | 2017 | T10 | Degenerative spine disease | Mid-thoracic pain | Penetration with pseudoaneurysm | Stent graft |
| Martin <i>et al.</i> ⁷ | 2018 | T8 | Discitis | Incidental | Penetration | Stent graft |
| Yammine <i>et al.</i> ¹³ | 2018 | N/A | Earlier operated fracture | Incidental | Penetration | Stent graft |
| Tharp <i>et al.</i> ¹⁹ | 2022 | T5, T6 | Idiopathic scoliosis | Mid-thoracic pain | Penetration | Stent graft |

Discussion

Pedicle screw placement in ideal trajectory runs through the center of the pedicle and adequately penetrates vertebral body between 50% and 80% of its volume. Penetration by more than 80% of the vertebral body length on profile radiograph or lateral deviation of the screw trajectory can raise concern for penetration of the anterior or lateral edge of vertebral body and possible injuries to the nearby structures, possibly major blood vessels⁹. In our institution, plain radiographs are performed postoperatively to estimate the pedicle screw position, and if there is suspicion of malposition, CT scan is performed. Vascular injuries due to screw misplacement, although rare, pose a very real risk of spinal instrumentation and present a serious and potentially devastating complication^{1,2,6-8}. If there is suspicion of vessel injury with malpositioned screw intraoperatively, extreme caution is needed if attempting to remove the screw without confirmation of the possible vessel lesion because massive bleeding

from a perforated vessel could present a serious, life-threatening adverse event^{9,19}. Most injuries reported in the available literature were late findings in asymptomatic or mildly symptomatic patients, as shown in Table 1^{1,3, 5,7-9,12,13,15,17-19,21}. In such cases, decision on surgical intervention can be based on two facts: (1) constant pulsatile microtrauma can cause thinning and eventual erosion of vessel wall with further consequences (bleeding, thrombosis, pseudoaneurysm...), and (2) depth of the screw encroaching, i.e., the deeper the screw is protruding, the higher is the mechanical strength of microtrauma due to larger contact surface^{1,9}. For a clearly penetrating screw, it is inevitable to perform surgical intervention with vessel repair^{1,5,8,9,21}. Multidisciplinary evaluation of the patient is necessary including spinal surgeon, vascular surgeon, anesthesiologist, and radiologist/cardiologist^{1,5,11,12}.

Open surgery for aortic wall injury is major operation which carries high morbidity and mortality, especially in older population who mostly require spinal instrumentation^{7,8}. Matsuzaki *et al.* presented a case of thoracic aorta perforation from an anteriorly placed screw found on routine CT follow up, where they performed thoracotomy, cardiopulmonary bypass, and replacement of an 8-cm thoracic aortic segment²⁰. Although the patient did well, repair of chronic traumatic aortic aneurysms carries a mortality rate of up to 50% and can be easily complicated with pulmonary failure or spinal cord ischemia⁸. Endovascular approach bears a lower risk and morbidity, and is the most often used technique whenever available^{1,5,7-13,15,17-19,21}. Since the first reported case with endovascular repair that was performed in 2004 by Minor *et al.*, a respectable number of cases can be found in the available literature, with minor differences. Our choice to use the combined endovascular approach seemed to be the safest and most efficient method, given the conditions of the lesion and the patient.

Stent graft placement and hardware removal can be performed simultaneously by removing the screw partially before stent placement or first deploying the stent and then removing the screw⁷. Clarke *et al.* describe their experience where they initially removed the screw, but after screw removal there was unanticipated gush of blood from the screw hole. To stop bleeding, they inserted a screw with larger diameter but short enough not to reach the aorta, which stopped bleeding, and eventually they positioned the stent⁸. Simultaneous careful removal of the screws with deployment of the endograft obviates concern of the possible damage to the endograft from the screw tip^{12,13}. In our case, we also planned to perform simultaneous stent deployment during screw removal to minimize the risk of the possible stent damage, and as we believed, to best control the possible bleeding. If there is no sign of aortic wall penetration, as in the work by Potter *et al.*, where initial aortogram did not show any signs of intraluminal material, removing of the screw without additional endovascular intervention might be sufficient⁵. Performing endovascular repair first and open removal of the screw on the day after can also be done, as reported by Hu *et al.*¹⁷. Some authors report no further complication after endovascular intervention

in cases of aortic wall injury without removing the malpositioned hardware; however, principally it was not their initial decision but were rather forced to do it due to technical problems with removing hardware^{10,22}. When using closed graft for endovascular repair, it is obligatory to bear in mind the possible closure of cord supplying arteries^{9,12}. Our initial plan was to use a short stent (48 mm in length) but due to inadequate closure of the lesion, we had to adjust our approach with placement of an additional longer graft. To avoid or minimize the risk, as Tong *et al.* highlight, planning of stent dimension can be performed based on CT angiogram measurement¹². We want to point to the importance of performing follow up aortography, as we had leakage due to graft malposition, which is the most important sign for additional actions. This may be an advantage of simultaneous approach because through performing follow up aortography whenever necessary, vascular team can have supervision of the stent-graft position and can easily record the possible bleeding from the lesion during or after screw removal. Performing endovascular intervention first, and then posterior approach for hardware removal (e.g., changing position of the patient) might bear the risk of additional graft slip and if it is not ideally positioned, leaves the lesion uncovered. Additional balloon catheter in place of the possible bleeding can also be 'back-up' in case of unexpected event^{5,7,8,19}. Patient positioning in the right lateral decubital position needs to be performed carefully to avoid the possible bleeding on entering the vessel or movement of vascular catheter⁷. It may seem that lateral position is unconventional for hardware manipulation but none of the authors pointed to it as an unbearable circumstance^{5,8,7,12,13,18,19,21}, as also confirmed by our experience. This position also permits urgent thoracotomy if necessary.

Performing posterior instrumentation, free hand or navigated, always bears the risk of screw misplacement, and there is always the question if there is the need of postoperative screw position follow up^{1,2,4,23}. We consider that plain radiographs can give a relatively good insight in hardware position and show the potential need of additional radiological examination. However, with uncharacteristic complaints after pedicle screw instrumentation, the possible vascular injury should be borne in mind^{14,23}.

Conclusion

Aortic injury due to malposition of spinal screw is a very rare and underreported but potentially devastating complication. Combined endovascular approach with simultaneous removal of malpositioned screw seems to be safe and efficient way to deal with this kind of challenge. Placing the patient in lateral decubital position for screw removal after initial endovascular catheter placement gives enough space for all operators to work. Performing intraoperative aortography provides good insight into stent position and possible bleeding after screw removal and stent positioning; as we showed in our case, it helps decide on performing additional intervention. Using a short graft should be considered in order to limit the risk of possible spinal cord ischemia.

References

- Kayacı S, Cakir T, Dolgun M, Cakir E, Bozok Ş, Temiz C, Caglar YS. Aortic injury by thoracic pedicle screw. When is aortic repair required? Literature review and three new cases. *World Neurosurg.* 2019 Aug;128:216-24. doi: 10.1016/j.wneu.2019.04.173. Epub 2019 May 9. PMID: 31077895.
- Elliott MJ, Slakey JB. Thoracic pedicle screw placement: analysis using anatomical landmarks without image guidance. *J Pediatr Orthop.* 2007 Jul-Aug;27(5):582-6. doi: 10.1097/01.bpb.0000279030.59150.13. PMID: 17585271.
- Foxx KC, Kwak RC, Lutzman JM, Samadani U. A retrospective analysis of pedicle screws in contact with the great vessels. *J Neurosurg Spine.* 2010 Sep;13(3):403-6. doi: 10.3171/2010.3.SPINE09657. PMID: 20809738.
- Hicks JM, Singla A, Shen FH, Arlet V. Complications of pedicle screw fixation in scoliosis surgery: a systematic review. *Spine (Phila Pa 1976).* 2010 May 15;35(11):E465-70. doi: 10.1097/BRS.0b013e3181d1021a. PMID: 20473117.
- Potter MQ, Lawrence BD, Kinikini DV, Brodke DS. Periaortic pedicle screw removal with endovascular control of the aorta and intraoperative aortography: a case report and review of the literature. *Evid Based Spine Care J.* 2013 Oct;4(2):149-53. doi: 10.1055/s-0033-1357358. PMID: 24436714; PMCID: PMC3836958.
- Papadoulas S, Konstantinou D, Kourea HP, Kritikos N, Haftouras N, Tsolakis JA. Vascular injury complicating lumbar disc surgery. A systematic review. *Eur J Vasc Endovasc Surg.* 2002 Sep;24(3):189-95. doi: 10.1053/ejvs.2002.1682. PMID: 12217278.
- Martin S, Lindsay R, Baker RC. Simultaneous endovascular repair of a thoracic aortic injury during posterior pedicle screw removal: a case report. *Ann Vasc Surg.* 2018 Apr;48:252.e1-252.e4. doi: 10.1016/j.avsg.2017.10.021. Epub 2017 Dec 8. PMID: 29225127.
- Clarke MJ, Guzzo J, Wolinsky JP, Gokaslan Z, Black JH 3rd. Combined endovascular and neurosurgical approach to the removal of an intraaortic pedicle screw. *J Neurosurg Spine.* 2011 Nov;15(5):550-4. doi: 10.3171/2011.7.SPINE10267. Epub 2011 Aug 5. PMID: 21819185.
- Valič M, Žižek D, Špan M, Mihalić R, Mohar J. Malpositioned pedicle screw in spine deformity surgery endangering the aorta: report of two cases, review of literature, and proposed management algorithm. *Spine Deform.* 2020 Aug;8(4):809-17. doi: 10.1007/s43390-020-00094-5. Epub 2020 Mar 13. PMID: 32170660.
- Been HD, Kerkhoffs GM, Balm R. Endovascular graft for late iatrogenic vascular complication after anterior spinal instrumentation: a case report. *Spine (Phila Pa 1976).* 2006 Oct 15;31(22):E856-8. doi: 10.1097/01.brs.0000240761.13090.a9. PMID: 17047534.
- Lopera JE, Restrepo CS, Gonzales A, Trimmer CK, Arko F. Aortoiliac vascular injuries after misplacement of fixation screws. *J Trauma.* 2010 Oct;69(4):870-5. doi: 10.1097/TA.0b013e3181f0bd55. PMID: 20938274.
- Tong X, Gu P, Yu D, Guo F, Lin X. An endovascular treatment of a thoracic aortic injury caused by a misplaced pedicle screw: case report and review of the literature. *J Formos Med Assoc.* 2015 May;114(5):464-8. doi: 10.1016/j.jfma.2013.09.014. Epub 2013 Dec 2. PMID: 24290859.
- Yamine H, Ballast JK, Boyes C, Arko FR. TEVAR for treatment of metallic pedicle screw penetrating the thoracic aorta. *J Cardiol. Clin Res.* 2018 6(2):1132. doi: 10.47739/2333-6676/1132.
- Wegener B, Birkenmaier C, Fottner A, Jansson V, Dürr HR. Delayed perforation of the aorta by a thoracic pedicle screw. *Eur Spine J.* 2008 Sep;17(Suppl 2):S351-4. doi: 10.1007/s00586-008-0715-9. Epub 2008 Jul 10. PMID: 18622634; PMCID: PMC2525912.
- Pesenti S, Bartoli MA, Blondel B, Peltier E, Adetchessi T, Fuentes S. Endovascular aortic injury repair after thoracic pedicle screw placement. *Orthop Traumatol Surg Res.* 2014 Sep;100(5):569-73. doi: 10.1016/j.otsr.2014.03.020. Epub 2014 Jul 9. PMID: 25023930.
- Carmignani A, Lentini S, Acri E, Vazzana G, Campello M, Volpe P, Acri IE, Spinelli F. Combined thoracic endovascular aortic repair and neurosurgical intervention for injury due to posterior spine surgery. *J Card Surg.* 2013 Mar;28(2):163-7. doi: 10.1111/jocs.12052. Epub 2013 Jan 7. PMID: 23294480.
- Hu HT, Shin JH, Hwang JY, Cho YJ, Ko GY, Yoon HK. Thoracic aortic stent-graft placement for safe removal of a malpositioned pedicle screw. *Cardiovasc Intervent Radiol.* 2010 Oct;33(5):1040-3. doi: 10.1007/s00270-009-9782-5. Epub 2009 Dec 24. PMID: 20033688.
- Minor ME, Morrissey NJ, Peress R, Carroccio A, Ellozy S, Agarwal G, Teodorescu V, Hollier LH, Marin ML. Endovascular treatment of an iatrogenic thoracic aortic injury after spinal instrumentation: case report. *J Vasc Surg.* 2004 Apr;39(4):893-6. doi: 10.1016/j.jvs.2003.10.056. PMID: 15071460.

19. Tharp P, King RW, Frankel BM, Wooster MD. Thoracic endovascular aortic repair for iatrogenic injury of the thoracic aorta. *J Endovasc Ther.* 2022 Oct;29(5):813-7. doi: 10.1177/15266028211065968. Epub 2021 Dec 12. PMID: 34894824.
20. Matsuzaki H, Tokuhashi Y, Wakabayashi K, Kitamura S. Penetration of a screw into the thoracic aorta in anterior spinal instrumentation. A case report. *Spine (Phila Pa 1976).* 1993 Nov;18(15):2327-31. doi: 10.1097/00007632-199311000-00033. PMID: 8278856.
21. Mirza AK, Alvi MA, Naylor RM, Kerezoudis P, Krauss WE, Clarke MJ, Shepherd DL, Nassr A, DeMartino RR, Bydon M. Management of major vascular injury during pedicle screw instrumentation of thoracolumbar spine. *Clin Neurol Neurosurg.* 2017 Dec;163:53-9. doi: 10.1016/j.clineuro.2017.10.011. Epub 2017 Oct 16. PMID: 29073499.
22. Zerati AE, Leiderman DB, Teixeira WG, Narazaki DK, Cristante AF, Wolosker N, de Luccia N, Barros Filho TE. Endovascular treatment of late aortic erosive lesion by pedicle screw without screw removal: case report and literature review. *Ann Vasc Surg.* 2017 Feb;39:285.e17-285.e21. doi: 10.1016/j.avsg.2016.06.020. Epub 2016 Sep 22. PMID: 27666805.
23. Aigner R, Bichlmaier C, Oberkircher L, Knauf T, König A, Lechler P, Ruchholtz S, Frink M. Pedicle screw accuracy in thoracolumbar fractures – is routine postoperative CT scan necessary? *BMC Musculoskelet Disord.* 2021 Nov 26;22(1):986. doi: 10.1186/s12891-021-04860-y. PMID: 34836522; PMCID: PMC8620926.

Sažetak

KOMBINIRANO ENDOVASKULARNO LIJEČENJE LEZIJE AORTE I UKLANJANJE PENETRIRAJUĆEG PEDIKULARNOG VIJKA NAKON STRAŽNJE INSTRUMENTACIJE KRALJEŽNICE: PRIKAZ SLUČAJA I PREGLED LITERATURE

D. Girotto, J. Burić, H. Šimić, V. Tomulić, T. Jakljević, Z. Kvas

Stabilizacija kralježnice transpedikularnim vijcima najčešća je tehnika instrumentacije među spinalnim kirurzima. Tehnika „slobodne ruke“ je relativno sigurna uz kontrolu intraoperacijskog rendgena. Vaskularne ozljede malpozicioniranim vijcima su rijetke, ali potencijalno kobna komplikacija. Ozljede torakoabdominalne aorte malpozicioniranim vijkom zahtijevaju multidisciplinarni pristup. Ozljeda stijenke krvne žile može zahtijevati uklanjanje vijka i popravak lezije. U ovom radu prikazujemo slučaj 72-godišnje bolesnice kod koje je učinjena duga fiksacija torakolumbarne kralježnice. Kontrolna kompjutorizirana tomografija (CT) tijekom poslijeoperacijskog praćenja, a potom i aortografija pokazali su leziju stražnjeg zida aorte malpozicioniranim vijkom bez znakova krvarenja. Nakon minuciozne pripreme učinjen je kombinirani zahvat, tj. simultani endovaskularni popravak aorte stent-graftom i uklanjanje vijka. Tijekom uklanjanja vijka bolesnica je bila u desnom bočnom položaju. Otpuštena je na kućno liječenje osmog poslijeoperacijskog dana. Kontrolna CT aortografija 6 mjeseci kasnije nije pokazala krvarenja ili bilo kakve promjene na aorti. Smatramo da je simultani endovaskularni popravak lezije aorte i uklanjanje vijka siguran i prikladan pristup u liječenju ove komplikacije. Bočni položaj nosi određena ograničenja za operatore, ali istodobno ostavlja dovoljno prostora za siguran rad. Intraoperacijska aortografija daje dobar uvid u položaj stenta ili eventualno krvarenje nakon uklanjanja vijka.

Ključne riječi: *Pedikularni vijak; Endovaskularno liječenje; Lezija aorte*