

Analysis of Axillary Lymph Nodes in Breast Cancer Patients with Positive Sentinel Lymph Node Biopsy

Grebić, Damir; Grbas, Harry; Valković Zujić, Petra; Mavrić, M.; Tomašić, AM.

Source / Izvornik: **West Indian Medical Journal, 2024, 71, 9 - 13**

Journal article, Published version

Rad u časopisu, Objavljena verzija rada (izdavačev PDF)

<https://doi.org/10.7727/wimj.2017.092>

Permanent link / Trajna poveznica: <https://urn.nsk.hr/urn:nbn:hr:184:023207>

Rights / Prava: [Attribution 4.0 International](#)/[Imenovanje 4.0 međunarodna](#)

Download date / Datum preuzimanja: **2024-12-20**



Repository / Repozitorij:

[Repository of the University of Rijeka, Faculty of Medicine - FMRI Repository](#)



Analysis of Axillary Lymph Nodes in Breast Cancer Patients with Positive Sentinel Lymph Node Biopsy

D Grebić¹, H Grbas¹, PV Zujčić², M Mavrić³, AM Tomašić⁴

ABSTRACT

Objective: To determine the prevalence of positive non-sentinel nodes (non-SLN) after axillary dissection for positive sentinel lymph node (SLN) and the relationship between occurrence of positive non-SLNs and penetration of the sentinel's capsule by malignant cells, as well as grade and molecular subtype of the breast cancer.

Methods: An analysis was performed of a total of 77 patients with a positive SLN from a five-year period. Patients were categorized according to the following criteria: positivity of non-SLN, invasion of SLN capsule, tumour grade, T stage and molecular subtype.

Results: In over 65% of patients, non-SLN were negative for metastases despite a positive SLN. A statistically significant correlation was observed between SLN capsule penetration and positive non-SLN metastases ($p < 0.001$). It was also observed that non-SLN metastases are more commonly positive in patients with a high tumour grade, high T stage, and HER2-positive and triple-negative tumours.

Conclusion: Non-SLN metastases are generally found in patients with SLN capsule penetration by malignant cells, in those with poorly differentiated tumours (high grade), and in those with high T stage, as well as in triple-negative and HER2-positive tumours. Based on these findings, such patients should undergo axillary dissection due to an increased risk of non-SLN metastases.

Keywords: Axillary dissection, breast cancer, positive sentinel lymph node, radiotherapy, surgery

INTRODUCTION

A sentinel lymph node (SLN) or lymph node guardian is defined as the first lymph node that drains lymph from a given area. A sentinel lymph node biopsy (SLNB) implies focused excision and pathological examination of axillary lymph nodes most likely to receive tumour metastases while avoiding morbidities associated with complete axillary nodal dissection (1).

Today, there are a number of controversial opinions on the indications and contraindications for a SLNB.

According to guidelines set forth by the European Association of Nuclear Medicine (EANM) and the

Society of Nuclear Medicine and Molecular Imaging (SNMMI), a SLNB is indicated for patients with early-stage (T1 and T2) breast cancer proven by cytology or biopsy, and in whom axillary metastases are not suspected clinically or already proven by histology or cytology. Former standard practice of axillary lymph node dissection (ALND) in order to stage the disease has been replaced with SLNB in early-stage breast cancer patients. Therefore, ALND is performed if the dissemination of disease to axillary lymph nodes is shown preoperatively, or in the case of a positive SLN (metastasis shown in

From: ¹Department of General and Oncological Surgery, Rijeka Clinical Hospital Center, Faculty of Medicine, University of Rijeka, Krešimirova 42, 51000 Rijeka, Croatia, ²Department of Radiology, Rijeka Clinical Hospital Center, Faculty of Medicine, University of Rijeka, Krešimirova 42, 51000 Rijeka, Croatia, ³Institute of Emergency Medicine, Franje Galinca 4, 42000 Varaždin, Croatia and ⁴Institute of Emergency Medicine, Edoarda Pascalija 3, 52470 Umag, Croatia.

Correspondence: Dr D Grebić, Department of General and Oncological Surgery, Clinical Hospital Center Rijeka, School of Medicine, University of Rijeka, Krešimirova 42, 51000 Rijeka, Croatia. Email: damir.grebic@medri.uniri.hr

pathohistological analysis) and in cases when a SLN was not identified by lymphoscintigraphy (2).

Based on the St. Gallen and the American Society of Clinical Oncology (ASCO) guidelines, ALND is not recommended prior to pathohistological analysis in the case of isolated positive, cytologically proven, tumour cells in a SLN. The American Society of Clinical Oncology (ASCO) does not recommend a SLNB for inflammatory carcinoma, advanced tumours (T3 and T4) or ductal carcinoma *in situ* (DCIS), when breast sparing surgery is anticipated. A sentinel lymph node biopsy (SLNB) can be done for multicentric tumours, although a high percentage of false negatives and axillary metastasis is found in these patients (3, 4). A sentinel lymph node biopsy (SLNB) for DCIS is indicated when mastectomy is planned (5). The indications for SLNB are controversial in pregnancy, although according to the ASCO guidelines SLNB is not recommended in pregnancy (3, 6). If a patient receives neoadjuvant chemotherapy prior to surgery, SLNB may be taken, but axillary dissection is obligatory in the case of a positive finding (7). Of SLN marking techniques, the dual-marking technique (lymphoscintigraphy and dye marking) is recommended in order to reduce the possibility of false-negative results. The reasons for lack of SLN presentation may include obstruction of lymph flow or SLN infiltration with tumour or malignant cells, for which axillary dissection is required (8). In the case of SLN micrometastases, ALND is unnecessary (9). There are still studies that show a longer period without disease recurrence in cases where axillary dissection is performed along with systemic therapy and axillary radiotherapy when one or two positive SLNs are found (studies MA.20 i EORTC 22922/10925) (10).

Newer studies suggest the use of systemic therapy and radiotherapy as an alternative to axillary dissection when one or two positive SLNs are found (AMAROS study i ACOSOG Z0011). This research compared two groups of patients with early stages of breast cancer and positive SLNs. One group of patients underwent tumour removal and axillary dissection, although the second group underwent tumour removal and postoperative radiotherapy (without axillary dissection). It was concluded that there is no difference in the recurrence-free period or a period of survival in these two groups of patients. For this reason, updated guidelines suggest that for patients with one or two positive SLNs, breast sparing surgery and subsequent radiotherapy, axillary dissection is unnecessary (11).

The aim of this study was to determine the prevalence of a positive non-SLN after axillary dissection was done due to a positive SLN and also to determine how the prevalence of positive non-SLNs relates to penetration of the sentinel's capsule by malignant cells, T stage, grade and molecular subtype of the breast cancer.

SUBJECTS AND METHODS

The proposed study was undertaken at the Department of General and Oncological Surgery, Rijeka Clinical Hospital Center. Consent was obtained from the Ethics Committee. Data were collected on patients with invasive breast cancer with a positive SLN. The study included data from a total of seventy-seven (77) patients from a five-year period (2009–2014), meaning that the study was retrospective, descriptive and analytical. Data on the total number of positive non-SLN metastases after axillary dissection were key. Additional data processed included: SLN penetration by malignant cells, tumour grade, T stage and molecular subtype.

Patients were divided into several groups. The first group included patients with positive non-SLN metastases after axillary dissection was done due to a positive SLN, as opposed to those in which after axillary dissection due to a positive SLN, non-SLN were negative. The second group included patients with SLN capsule penetration by malignant cells, compared to those in which the SLN capsule was intact. Based on this division, the following two subgroups were created: patients with SLN capsule penetration and positive non-SLN after axillary dissection versus patients with SLN capsule penetration, but negative non-SLN. The next group consisted of patients in which the SLN capsule was intact and after axillary dissection, non-SLN were negative, compared to patients with an intact capsule, but positive non-SLN after axillary dissection. Additional groups included patients with a positive non-SLN after axillary dissection due to a positive SLN, and patients with a negative non-SLN after axillary dissection according to the tumour grade, tumour T stage, and molecular subtype.

Statistical analyses

Data were collected and sorted on Microsoft Windows using the Microsoft Excel application. Statistical analysis was done using the Statistica 12 program, with the Fisher's exact test, *p*-values less than 0.05 were considered statistically significant.

RESULTS

A total of 26 patients (33.77%) had non-SLN metastases after axillary dissection for positive SLN, the remaining 51 patients (66.23%) having a positive SLN with negative non-SLNs (Figure).

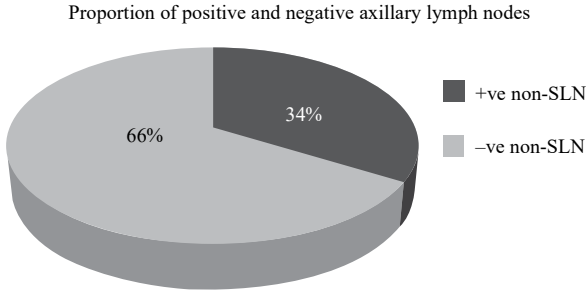


Figure: This figure shows the proportion of patients with positive non-SLN after axillary dissection was done due to a positive SLN compared to patients with a negative non-SLN after dissection due to a positive SLNB.

Analysis of the sentinel lymph node capsule

Based on the pathohistological analysis, 29 patients (37.66%) had a positive SLN where cancer cells penetrated the SLN capsule (Table 1). Among these 29 patients with capsular penetration, 19 patients (65.52%) had positive non-SLN (Table 2).

Table 1: Proportion of positive SLN with an intact capsule compared to SLN with a penetrated capsule

Positive SLN	
Intact capsule-penetrated capsule	
Patients 48 (62%); 29 (38%)	

The table shows the percentage of cases in which malignant cells penetrated the sentinel’s capsule (29, 38%) compared to the percentage with an intact sentinel’s capsule (48, 62%).

Table 2: Proportion of positive and negative non-SLNs in cases with penetrated sentinel’s capsule

Penetrated sentinel’s capsule	
Positive non-SLN patients	Negative non-SLN patients
19 (66%)	10 (34%)

Among the remaining 48 patients with an intact SLN capsule, seven patients (14.58%) also had positive non-SLN after axillary dissection (Table 3). The Fisher’s exact test calculated a statistically significance difference between these two groups ($p < 0.001$) for the likelihood of non-SLN metastases in cases of SLN capsular penetration compared to cases without capsular penetration.

Table 3: Percentage of positive and negative non-SLNs in the axilla in cases of an intact sentinel’s capsule

Intact capsule of SLN	
Positive non-SLN patients	Negative non-SLN patients
7 (15%)	41 (85%)

Grade of tumour and positive axillary lymph nodes

Of the total of 26 patients with a positive non-SLN, six patients (23.07%) had tumour grade 1, 17 patients (65.39%) had grade 2 and three patients (11.54%) had grade 3 (Table 4). In the 51 patients who had negative non-SLN, 39 patients (76.48%) had tumour grade 1, 11 patients (21.56%) had grade 2 and one patient (1.96%) had grade 3. The Fisher’s exact test calculated a statistically significant difference ($p < 0.001$) for the likelihood of non-SLN metastases between low- and high-differentiated tumours (Table 5).

Table 4: Proportion of each histological grade of tumours in the 26 patients with a positive non-SLN

Grade	Number (percentage) of patients
Grade 1	6 (23%)
Grade 2	17 (65%)
Grade 3	3 (12%)

Table 5: Proportion of each histological grade of tumours in the 51 patients with a negative non-SLN

Grade	Number (percentage) of patients
Grade 1	39 (76%)
Grade 2	11 (22%)
Grade 3	1 (2%)

Tumour T stage and positive axillary lymph nodes

Of the total of 77 patients, 35 patients (45.45%) had stage T1 carcinoma, and 42 patients (54.55%) had stage T2. Positive non-SLN were found in two (5.71%) patients with stage T1 disease, but in 24 (57.14%) with stage T2. Fisher’s exact test once again calculated a statistically significant difference ($p < 0.001$).

Tumour molecular subtype

According to molecular findings, patients were classified into four main groups: luminal A, luminal B, HER2-positive and triple-negative tumours. The luminal A group included 25 patients of which only four cases (16.00%) had positive non-SLN. The luminal B group had 40 patients of which 16 patients (40.00%) had positive non-SLN. The HER2-positive group had 10 patients

of which four patients (40.00%) had positive non-SLN. The final triple-negative group had only two patients with positive non-SLN in both cases (100%) (Table 6). The Fisher's exact test calculated a statistically significant difference ($p < 0.001$) for the likelihood of non-SLN metastases between triple-negative and HER2-positive tumours compared to luminal A and luminal B tumours.

Table 6: Molecular subtypes of the breast cancer. The table shows the number (percentage) of positive non-SLN according to the molecular subtype of the tumour

Molecular subtypes	Luminal A	Luminal B	HER-2 positive	Triple negative
Number of patients	25	40	10	2
Positive non-SLN	4 (16%)	16 (40%)	4 (40%)	2 (100%)

DISCUSSION

Of a total of 77 patients who underwent breast cancer surgery and had a positive SLN, 26 patients had positive non-SLN. This is a frequency of 33.77%, which is in line with other studies (9). Between the patients with an intact SLN capsule and those with SLN capsular penetration, a statistically significant difference was shown in terms of the occurrence of positive non-SLN ($p < 0.001$).

A majority of patients had cancer classified as grade 1 (58.44%), followed by grade 2 (36.37%) and grade 3 (5.19%). The lowest prevalence of positive non-SLN was observed in patients with grade 1, then grade 2 and the highest with grade 3, as expected, considering that an increase in tumour grade means more malignant, less differentiated tumors (12–14). The study shows a statistically significant correlation between higher grade tumours and non-SLN metastases ($p < 0.001$).

Patients in this study had cancer, classified as stage T1 or T2. Most patients (54.55%) had T2 cancer, which shows that the national breast cancer-screening programme still does not detect cancer in its earliest stage. An important result of this study is that of 26 patients with positive non-SLN, 24 had stage T2 tumors, indicating a statistically significant correlation between occurrence of positive non-SLNs and increasing T-stage of disease ($p < 0.001$) (13).

Most patients had luminal A and luminal B molecular subtypes (total 84.41%). The others were HER2-positive and triple negative. Patients with luminal A tumour subtype had the lowest percentage of positive non-SLN (16%). In comparison, both patients with triple negative tumour subtype had positive non-SLN. These results correlate with findings of other research in which HER2-positive and triple negative tumour subtypes are

associated with a higher prevalence of non-SLN metastases (15).

Results of this study show that current practice, in which a positive SLN is always accompanied by axillary dissection, leads to unnecessary axillary dissection in over 65% of patients that had negative non-SLNs. That is, only 35% of patients in this study had positive non-SLN. This study shows that non-SLN metastases are generally found (in 73.08% of cases) in patients with a SLN capsule penetrated by tumour cells, in patients with low differentiated tumours (high grade), and in those with high-tumour T stage. Based on these findings, such patients should undergo axillary dissection due to an increased risk of non-SLN metastases. According to the updated guidelines, in other cases, axillary dissection can be spared, and substituted with conservative treatment, such as radiotherapy, to reduce the number of unnecessary operations, and to improve quality of life (9, 10).

CONCLUSION

Non-SLN metastases are generally found in patients with positive SLN capsule penetration by malignant cells, in those with low differentiated tumours (high grade), and in those with high T stage, as well as in triple-negative and HER2-positive tumours. Based on these findings, such patients should undergo axillary dissection due to an increased risk of non-SLN metastases.

AUTHORS' NOTE

Damir Grebić wrote the manuscript, participated in data analysis and interpretation, critically revised the manuscript and approved the final version. Harry Grbas participated in the interpretation of data, revision of the manuscript and approved the final version. Petra Valković Zujic performed the statistical analysis and created the figures. Matija Mavrić and Ana Marija Tomasić collected the data, participated in data analysis and interpretation. The authors declare that they have no conflicts of interest.

REFERENCES

1. Cheng G, Kurita S, Torigian DA, Alavi A. Current status of sentinel lymph-node biopsy in patients with breast cancer. *Eur J Nucl Med Mol Imaging* 2011; **38**: 562–75.
2. Giammarile F, Alazraki N, Aarsvold JN, Audisio RA, Glass E, Grant SF et al. The EANM and SNMMI practice guideline for lymphoscintigraphy and sentinel lymph node localisation in breast cancer. *Eur J Nucl Med Mol Imaging* 2013; **40**: 1932–47.
3. Lyman GH, Giuliano AE, Somerfield MR, Benson AB, Bodurka DC, Burstein HJ et al. American Society of Clinical Oncology guideline

- recommendations for sentinel lymph node biopsy in early-stage breast cancer. *J Clin Oncol* 2005; **23**: 7703–20.
4. Lyman GH, Temin S, Edge SB, Newman LA, Turner RR, Weaver DL et al. Sentinel lymph node biopsy for patients with early-stage breast cancer: American Society of Clinical Oncology clinical practice guideline update. *J Clin Oncol* 2014; **32**: 1365–83.
 5. Intra M, Rotmensz N, Veronesi P, Colleoni M, Iodice S, Paganell G et al. Sentinel node biopsy is not a standard procedure in ductal carcinoma in situ of the breast: the experience of the European Institute of Oncology on 854 patients in 10 years. *Ann Surg* 2008; **247**: 315–19.
 6. Gentilini O, Cremonesi M, Trifiro G, Ferrari M, Baio SM, Caracciolo M et al. Safety of sentinel node biopsy in pregnant patients with breast cancer. *Ann Oncol* 2004; **15**: 1348–51.
 7. Vugts G, Maaskant-Braat AJ, De Roos WK, Voogd AC, Nieuwenhuijzen GA. Management of the axilla after neoadjuvant chemotherapy for clinically node positive breast cancer. A nationwide survey study in The Netherlands. *Eur J Surg Oncol* 2016; **42**: 956–64 .
 8. Brenot Rossi I, Houvenaeghel G, Jacquemier J, Bardou VJ, Martino M, Hassan-Sebbag N et al. Nonvisualisation of axillary sentinel node during lymphoscintigraphy: is there a pathologic significance in breast cancer? *J Nucl Med* 2003; **44**: 1232–7.
 9. Giuliano AE, Hunt KK, Ballman KV, Beitsch PD, Whitworth PW, Blumencranz PW et al. axillary dissection vs no axillary dissection in women with invasive breast cancer and sentinel node metastasis. *JAMA* 2011; **305**: 569–75.
 10. Donker M, Van Tienhoven G, Straver ME, Meijnen P, Van De Velde CJ, Mansel RE et al. Radiotherapy or surgery of the axilla after a positive sentinel node in breast cancer (EORTC 10981-22023 AMAROS): a randomised, multicentre, open-label, phase 3 non-inferiority trial. *Lancet Oncol* 2014; **15**: 1303–10.
 11. Giuliano AE, McCall L, Beitsch P, Whitworth PW, Blumencranz P, Leitch AM et al. Locoregional recurrence after sentinel lymph node dissection with or without axillary dissection in patients with sentinel lymph node metastases: the American College of Surgeons Oncology Group Z0011 randomized trial. *Ann Surg* 2010; **252**: 426–33.
 12. Bojić T, Djordjević N, Karanikolić A, Filipović S, Granić M, Poultsidi AA. Assessment of axillary lymph nodes involvement in patients with breast cancer depending on the tumor size and its histological and nuclear grades. *Vojnosanit Pregl* 2012; **69**: 414–19.
 13. Fajdić J, Džepina I. Breast surgery. Zagreb: School Book; 2006: 61–89.
 14. Port ER, Patil S, Stempel M, Morrow M, Cody HS. Number of lymph nodes removed in sentinel lymph node-negative breast cancer patients is significantly related to patient age and tumor size: a new source of bias in morbidity assessment? *Cancer* 2010; **116**: 1987–91.
 15. Jans JB, Escudero NM, Pulgar DB, Acevedo FC, Sánchez CR, Camus AM. Clinicopathologic subtypes and compromise of lymph nodes in patients with breast cancer. *Ecancermedalscience* 2014; **8**: 448.

© West Indian Medical Journal 2024.

This is an article published in open access under a Creative Commons Attribution International licence (CC BY). For more information, please visit https://creativecommons.org/licenses/by/4.0/deed.en_US.

