

# Cutaneous manifestations of polycystic ovary syndrome and their management

---

**Ključarić, Adriana**

**Master's thesis / Diplomski rad**

**2024**

*Degree Grantor / Ustanova koja je dodijelila akademski / stručni stupanj:* **University of Rijeka, Faculty of Medicine / Sveučilište u Rijeci, Medicinski fakultet**

*Permanent link / Trajna poveznica:* <https://um.nsk.hr/um:nbn:hr:184:456736>

*Rights / Prava:* [In copyright](#)/[Zaštićeno autorskim pravom.](#)

*Download date / Datum preuzimanja:* **2024-11-07**



*Repository / Repozitorij:*

[Repository of the University of Rijeka, Faculty of Medicine - FMRI Repository](#)



**UNIVERSITY OF RIJEKA  
FACULTY OF MEDICINE**

**INTEGRATED UNDERGRADUATE AND GRADUATE UNIVERSITY OF  
MEDICINE IN ENGLISH**

**Adriana Ključarić**

**CUTANEOUS MANIFESTATIONS OF POLYCYSTIC OVARY SYNDROME AND  
THEIR MANAGEMENT**

**GRADUATION THESIS**

**Rijeka, 2024**

**UNIVERSITY OF RIJEKA  
FACULTY OF MEDICINE**

**INTEGRATED UNDERGRADUATE AND GRADUATE UNIVERSITY OF  
MEDICINE IN ENGLISH**

**Adriana Ključarić**

**CUTANEOUS MANIFESTATIONS OF POLYCYSTIC OVARY SYNDROME AND  
THEIR MANAGEMENT**

**GRADUATION THESIS**

**Rijeka, 2024**

Thesis mentor: **Assoc. Prof. Sandra Peternel, MD, PhD**

The graduation thesis was graded on June 25<sup>th</sup> 2024 in Rijeka, before the Committee composed of the following members:

- 1. Assoc. Prof. Sanja Klobučar, MD, PhD** (President of the Committee)
- 2. Prof. Gordana Blagojević, MD, PhD**
- 3. Assist. Prof. Marko Klarić, MD, PhD**

The graduation thesis contains 33 pages, 9 figures, 2 tables, and 39 references.

## **Prologue**

## **Acknowledgments**

*To my family, thank you for your endless support.*

## Table of Contents

<b>1. Introduction .....</b>	<b>1</b>
<b>1.1. Definition of Polycystic Ovary Syndrome.....</b>	<b>1</b>
<b>1.2. Epidemiology .....</b>	<b>2</b>
<b>1.3. Etiology and Pathophysiology .....</b>	<b>2</b>
<b>1.4. Clinical Features and diagnostic criteria .....</b>	<b>3</b>
<b>2. Aims and objectives.....</b>	<b>4</b>
<b>3. Literature review .....</b>	<b>4</b>
<b>3.1. Dermatologic manifestations .....</b>	<b>4</b>
3.1.1. <i>Hirsutism</i> .....	4
3.1.2. <i>Acne</i> .....	6
3.1.3. <i>Androgenic Alopecia</i> .....	9
3.1.4. <i>Acanthosis Nigricans</i> .....	12
<b>3.2. Treatment.....</b>	<b>14</b>
3.2.1. <i>Hyperandrogenism</i> .....	14
3.2.2. <i>Hirsutism</i> .....	17
3.2.3. <i>Acne</i> .....	18
3.2.3.1 Topical Treatments.....	19
3.2.3.2 Systemic treatments.....	22
3.2.3.3 Procedural Therapies .....	23
3.2.4. <i>Androgenic alopecia</i> .....	23
3.2.4.1 Hormonal therapies .....	23
3.2.4.2 Non-hormonal therapies .....	24
3.2.5. <i>Acanthosis Nigricans</i> .....	25
<b>4. Discussion .....</b>	<b>26</b>
<b>5. Conclusion.....</b>	<b>28</b>
<b>6. Summary .....</b>	<b>29</b>
<b>7. Literature Cited.....</b>	<b>30</b>

## List of abbreviations and acronyms

PCOS – Polycystic ovary syndrome  
PCOM – Polycystic ovary morphology  
BMI – body mass index  
DM type 2 – Diabetes mellitus type 2  
hCG- human chorionic gonadotropin  
DHEAS - dehydroepiandrosterone sulfate  
FSH – follicle stimulating hormone  
LH – luteinizing hormone  
SHBG – sex hormone binding globulin  
NASH – nonalcoholic steatohepatitis  
DHT - dihydrotestosterone  
mFG – modified Ferriman-Gallwey score  
5 $\alpha$ -DHT – 5- alpha – dihydrotestosterone  
IGF-1 – Insulin-like growth factor 1  
CRH – corticotropin-releasing hormone  
TNF- $\alpha$ - tumor necrosis factor alpha  
AR – androgen receptor  
IL-6 - interleukin 6  
TLR2 - toll-like receptor 2  
IGA scale - Investigator’s Global Assessment Scale  
FDA - Food and Drug Administration  
ANSD- androstenedione  
AGA - Androgenic alopecia  
FPHL - female pattern hair loss  
AN - acanthosis nigricans  
HPA axis - hypothalamic–pituitary–adrenal axis  
EP – estroprogestin  
DEJ- dermo-epidermal junction  
IR – insulin resistance  
VTE- venous thromboembolism  
COCP – Combined Oral Contraceptive Pill

OC – Oral Contraceptive

GnRH - Gonadotropin-releasing hormone

MI- myo-inositol

DCI – D- chiro-inositol

DPP-4- dipeptidyl peptidase-4

RARs- retinoic acid receptors

TMP/SMX – Trimethoprim/sulfamethoxazole

FAGA – female androgenic alopecia

PRP – Platelet-Rich Plasma

PL – Platelet Lysate

LLLT- Low- Level Laser Therapy

TCA - Trichloroacetic acid

Cyclic GMP – cyclic guanosine triphosphate

BMP – Bone Morphogenic Protein



## 1. Introduction

### 1.1. Definition of Polycystic Ovary Syndrome

Polycystic ovary syndrome (otherwise known as Stein-Leventhal syndrome, or PCOS) is an endocrinological condition that is most prevalent in women of childbearing age. PCOS may present in various ways and will lower the quality of life as well as life expectancy. (1) Even though the etiology of PCOS is undetermined, it is regarded as a multifactorial syndrome with a variety of endocrinological, genetic, metabolic, dermatologic, and external manifestations. (1, 2)

Three diagnostic criteria are currently used for diagnosing PCOS, all based on similar characteristics. First phenotypes were defined by the 1990 National Institutes of Health criteria. Phenotype A is described as hyperandrogenism associated with oligo-anovulation and polycystic ovarian morphology (PCOM). It is also known as the "complete" or "classical" PCOS phenotype. Phenotype B is the same as phenotype A without PCOM. Furthermore, another phenotype was described by the 2006 Androgen Excess & PCOS Society and the 2003 Rotterdam Criteria – Phenotype C, characterized by hyperandrogenism and specific PCOM but without oligo-anovulation. It is also sometimes referred to as "ovulatory PCOS". Finally, the 2003 Rotterdam criteria included a fourth PCOS phenotype – Phenotype D (oligo-anovulation with specific ovarian morphology, excluding hyperandrogenism). (1, 3)

**Table 1.** Simplified overview of PCOS phenotypes. (1-3)

Phenotypes	Hyperandrogenism	Oligo-anovulation	PCOM
<b>A</b>	+	+	+
<b>B</b>	+	+	-
<b>C</b>	+	-	+
<b>D</b>	-	+	+

## 1.2. Epidemiology

In the last 26 years, numerous studies reported that PCOS affects 5-20% of women of child-bearing age, depending on diagnostic criteria that were in use. (3) It is estimated that every fifth woman is affected by PCOS. (4)

Although many women experience obesity and PCOS, 1/3 of the affected women are of normal body weight. Therefore, PCOS is unrelated to the ongoing rise in obesity rates. There is a significant number of PCOS cases in women with normal BMI. However, high BMI and PCOS do have certain conditions in common, such as DM type 2 and increased morbidity of long-term disease, such as cardiovascular. (3)

## 1.3. Etiology and Pathophysiology

This multifactorial disorder arises from different environmental factors, genetic interactions, and hormonal components. (2)

Several studies indicate that a fetus exposed to high levels of androgens *in utero* is likely to show signs of PCOS in adolescence, with the androgens most likely originating from the female fetus's ovaries in response to maternal hCG levels. Another study in mice demonstrated that elevated levels of anti-Müllerian hormone during late pregnancy resulted in PCOS-like symptoms, including high LH pulses and elevated androgens. These findings suggest the potential for transgenerational transmission of PCOS. (2,4) Epigenetically, the probability of childhood obesity is greater in children born from pregnancy complicated by diabetes, which increases the likelihood of early-onset DM2, suggesting that gestational diabetes may be a risk factor for PCOS. (2)

Reduced ability to tolerate glucose, increased insulin secretion, and high levels of LH promote androgen secretion via theca cells. This, in turn, will limit the release of SHBG in the liver, favoring the development of hyperandrogenism. (2, 3, 5)

Insulin resistance influences the occurrence and continuation of PCOS. This is primarily due to an abnormality in the receptors for insulin caused by overabundant serine phosphorylation and reduced tyrosine phosphorylation, resulting in reduced insulin stimulation of the phosphatidylinositol-3-kinase signaling route. This, in turn, stimulates glucose transportation and thus raises blood sugar concentration. High levels of insulin cause hypophysis to produce LH, which stimulates androgen secretion and affects the creation and size of ovarian follicles. Both high insulin and androgen levels restrict SHBG production, resulting in a rise in free androgens. (6)

#### 1.4. Clinical Features and diagnostic criteria

Regarding the gynecological aspect of clinical manifestations in PCOS, the most common are the following: secondary amenorrhea, oligomenorrhea, menorrhagia, and infertility or difficulties conceiving. (4) Menstrual irregularities are defined based on the duration since menarche. After more than one year of menarche, irregularities include menstrual bleeding occurring less than every 21 days or more than every 45 days. Beyond three years post-menarche, irregularities are characterized by cycles  $< 21$  and  $> 35$  days. Additionally, if it has been more than one year since the onset of menstruation, any cycle lasting more than 90 days is considered irregular. (5) However, menstrual cycles that occur more frequently (meaning less than 24 days), known as polymenorrhea, may happen in a small number of cases. (2) Some women may experience regular cycles, making it crucial to measure progesterone levels during the luteal phase to determine whether these cycles are ovulatory. (2, 3) Infertility in PCOS is primarily a consequence of anovulatory menstruation, making PCOS the most typical cause of anovulatory infertility and infertility in general. Such ovulatory dysfunctions often result in subfertility. (3, 4) During pregnancy, there is a heightened likelihood of spontaneous abortion and complications such as gestational diabetes and hypertension. (2) The risk of endometrial hyperplasia and, albeit less commonly, endometrial cancer, is increased in PCOS patients due to the presence of unopposed estrogen.

Evaluating polycystic ovarian morphology (PCOM) requires high-resolution transvaginal ultrasound. PCOM is characterized as having ovaries with a volume exceeding 10 mL and/or more than 20 antral follicles (5) in at least one ovary, each measuring 2 to 9 mm. (4)

In the endocrinological profile of PCOS patients, insulin resistance and related conditions, including metabolic syndrome (particularly in obese patients), are notable. Metabolic syndrome is an umbrella term encompassing metabolic factors, including central obesity, elevated blood pressure, compromised fasting blood glucose levels, and abnormal lipid levels. These conditions significantly elevate the risk of sleep apnea. Furthermore, PCOS patients are prone to non-alcoholic fatty liver disease, which, if neglected, can lead to other disorders like cirrhosis and nonalcoholic steatohepatitis (NASH). (3, 7)

The most common dermatological features in PCOS patients are hirsutism, acne vulgaris, androgenic alopecia, acanthosis nigricans, and seborrhea. The literature overview will discuss more on this topic.

Current recommendation is to use the modified Rotterdam diagnostic criteria, which states that PCOS can be confirmed when at least two are present: (1) Clinical or biochemical

hyperandrogenism, (2) signs of oligo-anovulation, and (3) ultrasound-confirmed PCOM, with the exclusion of any pertinent illnesses.

Blood tests can detect biochemical hyperandrogenism. Raised total or free testosterone, computed free testosterone indices, DHEAS, and ANSD levels can all be evaluated. For clinical hyperandrogenism, a modified Ferriman-Gallways (mFG) score should be employed. When determining the acceptable level, it is important to take into account the patient's ethnic background. Oligo-anovulation is indicated by menstrual bleedings that are longer than thirty-five days intervals or, according to some studies, fewer than eight times per year. (8)

## **2. Aims and objectives**

As previously described, polycystic ovary syndrome is the most prevalent cause of infertility in childbearing-age women. This paper aims to comprehensively review and evaluate various dermatological conditions associated with PCOS in terms of diagnosis, understanding of etiology and pathophysiology, and therapeutic options. By cataloging all potential treatment modalities, assessing their advantages and disadvantages, and comparing approaches, this review seeks to provide insights into optimal therapeutic strategies.

## **3. Literature review**

### **3.1. Dermatologic manifestations**

#### *3.1.1. Hirsutism*

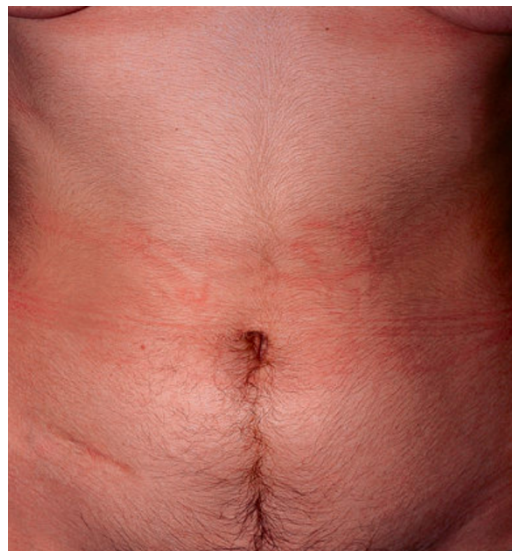Hirsutism is characterized by the appearance of terminal hair growth in places susceptible to androgens that aren't typical in women. (9). (Figure 1.)

Terminal, vellus, and lanugo hair are the three types of hair. Lanugo is present during the first days of life and will spontaneously vanish. Vellus hair lacks pigment and is very fine and short, while terminal hair, in contrast, is extended in length, thicker, and pigmented. Women commonly exhibit terminal hair in areas like their eyebrows, eyelashes, scalp, underarms, and pubic region. However, in PCOS patients, terminal hair can be observed on the chin, inner thighs, linea alba, buttocks, upper lip, chest, breast areola, and external genitalia (10) Androgen activity in these areas will convert soft vellus hairs into harsh terminal hairs. Axillary and pubic regions are more perceptive to low amounts of androgens; other areas require more androgen for follicles to terminalize.

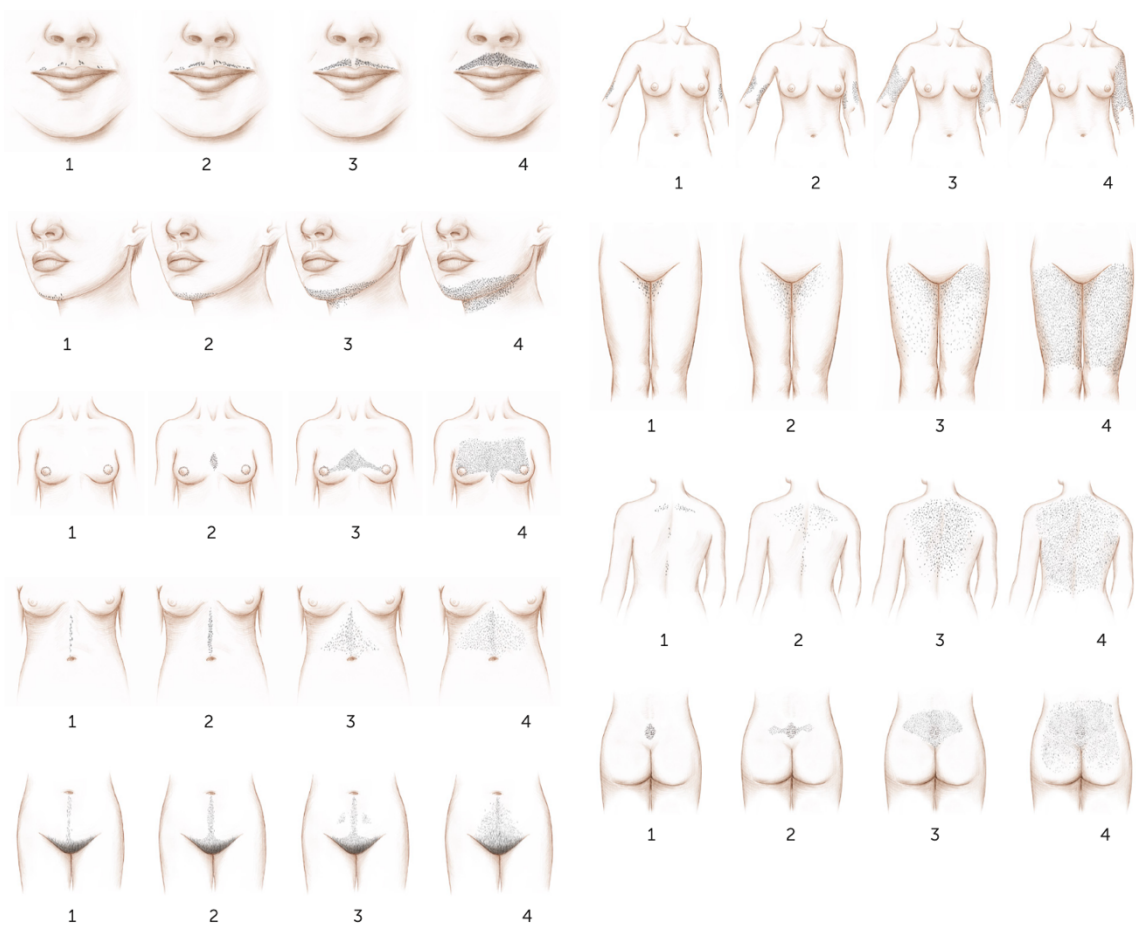
The three phases of the cycle of hair follicles are anagen, catagen, and telogen. The anagen stage is when hair grows most actively, lasting up to 6 years on the scalp and shorter on other

body areas (a few months). About 85-90% of scalp hair is in this phase, with variations due to age, region, and gender. In the catagen stage, hair ceases to grow because follicles undergo degeneration, keratinocyte apoptosis, and follicles atrophy. Telogen follows a resting phase with low follicle activity and hair shedding. It lasts 2-4 months on the scalp and 3 months up to half a year on the legs. Reactivation of the follicle signals the start of the next anagen phase. (10) Scalp that reacts to androgens shows follicular miniaturization and a decrease in the length of the anagen phase, resulting in a greater percentage of hair in the telogen stage. (9) 5- $\alpha$  reductase is a catalyst that turns testosterone into dihydrotestosterone (DHT). (9) Greater activity of this enzyme, which is activated by hyperandrogenism and insulin-like growth factors, results in heightened androgenic effects within the hair follicle. (10, 11)

In the diagnosis of hirsutism, a modified Ferriman-Gallway (mFG) grading method is employed (Figure 2). Hirsutism is assessed by grading nine body areas from zero (no terminal hair) to four (terminal male pattern hair growth), with the highest score of 36. (9-11) A score over eight, usually, suggests hirsutism. Important considerations include age (androgen secretion may diminish with aging), ethnicity, and skin type. Higher Fitzpatrick skin types are associated with the greatest mFG grade and hirsutism rates. Some research indicated that East Asian, Hispanic, and South Asian women typically have lower scores compared to Middle Eastern women.(9)



**Figure 1:** Central hirsutism in a female patient (score 3 on mFG for the lower abdomen)  
(Source: Bologna JL, editor. *Dermatology*. U: Reynolds R. In: *Hypertrichosis and Hirsutism*. 4<sup>th</sup> ed. Edinburgh: Elsevier; 2018. P. 1188- 202)



**Figure 2:** Modified Ferriman-Gallwey Score for hirsutism.

Nine bodily locations are scored on a scale of 1 to 4. An overall rating below 8 suggests normal, 8-15 mild hirsutism, while 15+ implies moderate to severe hirsutism.

*(Source: Bode D, Seehusen DA, Baird D. Hirsutism in Women. Am Fam Physician 2021; 85(4):373-80)*

### 3.1.2. Acne

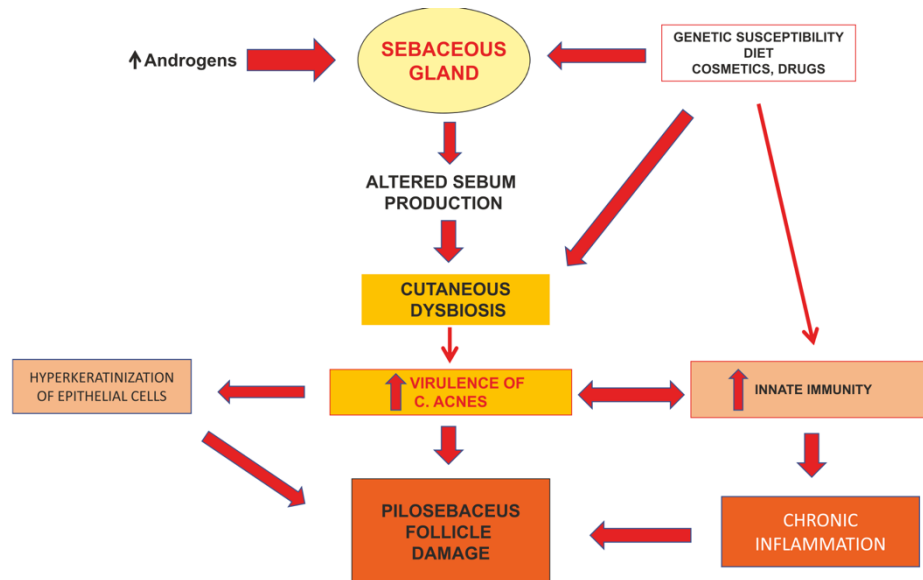
Female adult acne is an inflammatory condition that arises from several interconnected factors. (13) First, sebum production increases and is altered. Sebocytes release sebum into the follicle via the hair canal. Sebum comprises of triglycerides, fatty acids (57.5%), cholesterol esters, and squalene. Sebum lubricates the skin, carries antioxidants, defends against UV radiation, and induces antimicrobial activity. (13,14) However, variations in the lipid content of sebum, more specifically, a higher proportion of monounsaturated fatty acids, a lower amount of linoleic acid, and greater production of squalene and lipid peroxides, decrease the skin's protective barrier and actively contribute to inflammation, leading to the formation of acne. (13)

The powerful 5 $\alpha$ -dihydrotestosterone (5 $\alpha$ -DHT) is responsible for excessive oil generation. It is produced from testosterone by the enzyme 5 $\alpha$ -reductase type 1, primarily found in face sebocytes and sweat glands. 5 $\alpha$ -DHT targets sebaceous glands through the nuclear androgen receptor (AR). Research on genes reveals that AR disruption is connected with severe acne, as indicated by a substantial association among teens experiencing severe acne, and a Myc protooncogene linked to AR overexpression in the chromosome 8 q24 area. (14) Estrogens oppose androgens, which reduces sebaceous gland function. They additionally participate in wound repair and anti-inflammatory activities via intricate mechanisms with IGF-1. A comprehensive evaluation indicated that individuals having acne showed decreased blood estrogen levels than controls, indicating that estrogen plays a role in acne etiology. (14) Furthermore, corticotropin-releasing hormone (CRH) and cortisol regulate sebum activity. Acne-affected skin has a greater concentration of CRH within its oil glands, which inhibits sebocyte division, stimulates the generation of oil, and upregulates  $\Delta$ 5-3 $\beta$ -hydroxysteroid dehydrogenase, which stimulates androgens. Although stress hormones are generated under emotional stress, their direct effect on acne lesion formation via sebaceous gland pathways is little understood. Some research shows a link between stress and acne severity, however direct analysis of sebaceous production during stressful circumstances has shown unclear findings. For example, a study of 94 adolescents reported no significant change in oil measures across high & low-stress circumstances, indicating that different processes trigger acne lesion formation in stressful environments. (14)

Inflammation is nowadays recognized as a critical component of acne etiology, occurring in both early and later lesion stages. Both affected and unaffected skin show higher amounts of inflammatory agents, including interleukins and TNF- $\alpha$ . This inflammatory reaction is influenced by components like changed oil structure, *Cutibacterium acnes*, engagement of TLR2, and lipid imbalances on the skin surface. Lipoperoxides generated by squalene breakdown are thought to contribute to acne development by increasing keratinocyte proliferation and cytokine release. Androgens like dihydrotestosterone (DHT) upregulate inflammatory cytokines including TNF- $\alpha$  and IL-6 in sebocytes. This emphasizes the dual involvement of androgens in acne development, namely sebum production and inflammation. (14) Another factor in acne development is skin disbalance with *C. acnes*. ( Figure 3.)

Additionally, the process of comedone formation is initiated by irregularities in the differentiation and proliferation of keratinocytes, which ultimately lead to the clogging of pilosebaceous follicles and the formation of comedones. An environment containing a lot of sebum facilitates the colonization of *C. acnes*, which prolongs inflammation and leads to

formation of papules, pustules, nodules, cysts, and scars. (15) Activation of innate immunity will perpetuate dysbiosis and the inflammatory process. (13)

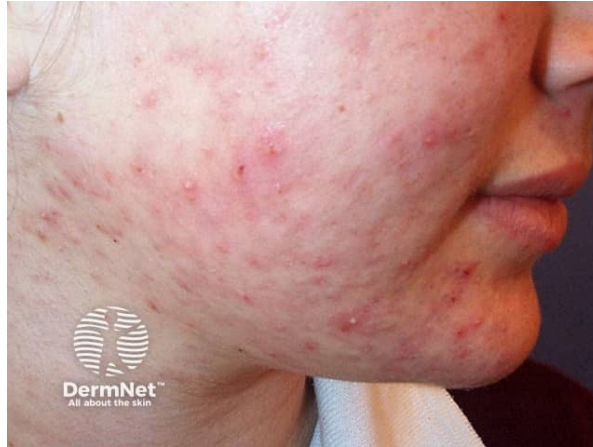

**Figure 3.** Pathophysiology of adult acne (13)

(Source: Carmina E, Dreno B, Lucky WA, Agak WG, Dokras A, Kim JJ, et al. *Female Adult Acne and Androgen Excess: A Report From the Multidisciplinary Androgen Excess and PCOS Committee. J Endocr Soc.* 2022; 6(3):bvac003)

Proper evaluation of acne severity using established grading and categorization tools is critical in order to direct therapies and assess therapy results. The IGA Scale, approved by the Food and Drug Administration, comprises of 5 separate categories. Grade 0 denotes clean skin free of lesions. The first grade, defined as "nearly clear," has few non-inflammatory (comedonal) lesions and a maximum of one minor inflammatory lesion. The second stage, or "mild severity," includes occasional non-inflammatory lesions as well as several inflammatory papular or pustular lesions, but without nodules. (Figure 4.) As the disease progresses to third grade, or "moderate severity," the skin develops multiple non-inflammatory and inflammatory lesions, with a single tiny nodular lesion. Grade 4 is classified as "severe" due to multiple non-inflammatory and inflammatory lesions, but also multiple nodular changes. (16)





**Figure 4.** Mild acne on the lower portion of the face in a female patient

*(Source: DermNet [Internet]. New Zealand: DermNet New Zealand Trust; [updated 2024; accessed June 24, 2024]. Available from: <https://dermnetnz.org/images>)*

### 3.1.3. Androgenic Alopecia

Androgenic Alopecia (AGA) is a non-scarring hair loss that involves progressive hair thinning as a result of high androgens. (17)

Research indicates that the prevalence of AGA increases with age. Among Caucasian European women in the USA, Australia, and the UK, prevalence rates are between 3% and 12% in their 30s, 14% and 18% in their 60s, and 29% and 56% in women aged 70 and above. In comparison, Asian women exhibit a lower prevalence, reaching 12%- 25% in those over 70. (18, 19)

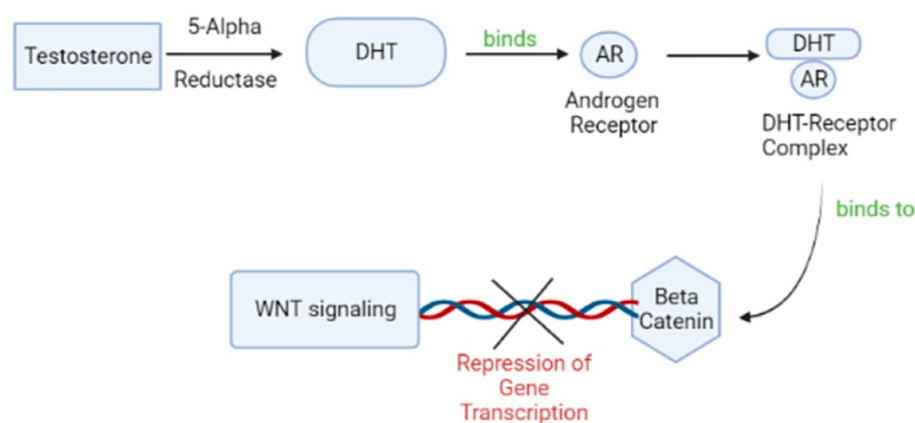
The manifestation of AGA in individuals with PCOS is the result of a multifaceted interplay involving hormonal, genetic, and environmental factors.

In PCOS, as previously mentioned, there is an excess of androgens, more particularly testosterone and DHT. DHT directly impacts susceptible hair follicles in the dermal papilla in a way that it attaches to hair follicles' AR. (17) Miniaturization occurs when terminal hair follicles turn into vellus follicles. Hair follicles gradually shrink, accompanied by a diminished period of the anagen phase. This indicates that the hair remains in the growth phase for a shorter duration while it spends longer in the resting phase (telogen), resulting in increased shedding and slower hair replacement. The result is shorter, thinner, and less pigmented hair. Nevertheless, the total count of follicles remains constant. (17, 19, 20)

Hair follicle growth and regeneration are significantly influenced by the Wnt/ $\beta$ -catenin pathway, activated by interactions with the vitamin D receptor. This aids in pushing follicles from the telogen phase to the anagen phase (without relying on circulating vitamin D3).

However, this beneficial effect is countered by androgens that enhance the expression of the glycogen synthase kinase-3 beta, impeding the pathway and leading to typical androgenetic alopecia features like enlarged sebaceous glands and shrunken hair follicles. This underscores the dual role of biochemical pathways in hair follicle dynamics and disease manifestation (Figure 5). (17, 21)

Some studies show the possible correlation between inflammation and AGA in women, also termed female pattern hair loss (FPHL). Biopsy specimens from FPHL individuals showed 37% more inflammation compared to control individuals. (18) AGA's pathophysiology might potentially involve low-grade persistent inflammation. In the catagen phase, inflammatory peptides such as TNF- $\alpha$  and IL-1 were found. Furthermore, prostaglandin D2 was found to be elevated in bald scalps. Elevated prostaglandin D<sub>2</sub> was also shown in transgenic mice, which showed hair loss and miniaturization. (21)



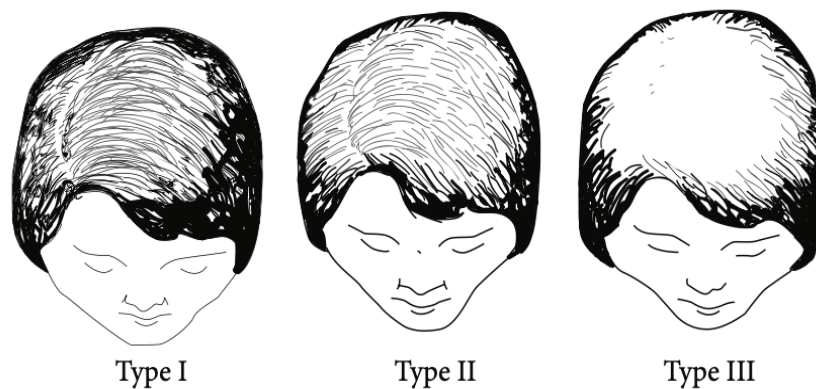
**Figure 5.** An Overview of Pathophysiology of AGA

(Source: Bajoria PS, Dave PA, Rohit RK, Tibrewal C, Modi NS, Gandhi SK, et al. Comparing Current Therapeutic Modalities of Androgenic Alopecia: A Literature Review of Clinical Trials. *Cureus*. 2023;15(7):e42768.)

AGA can manifest in three different patterns. The first involves widespread reduction at the crown but preserves the hairline at the front, as assessed by Ludwig and Sinclair's score (Figure 6). The second pattern is marked by decreasing hair volume and broadening of the scalp's

middle region, breaking the hairline at the front, known as the Christmas tree shape on the Olsen scale. (Figure 7.) The third pattern exhibits thinning in temporal region with result of recession on both sides, according to the Hamilton-Norwood scale. These typical hair loss patterns leave the occipital area unaffected, likely due to hormonal factors. (17)

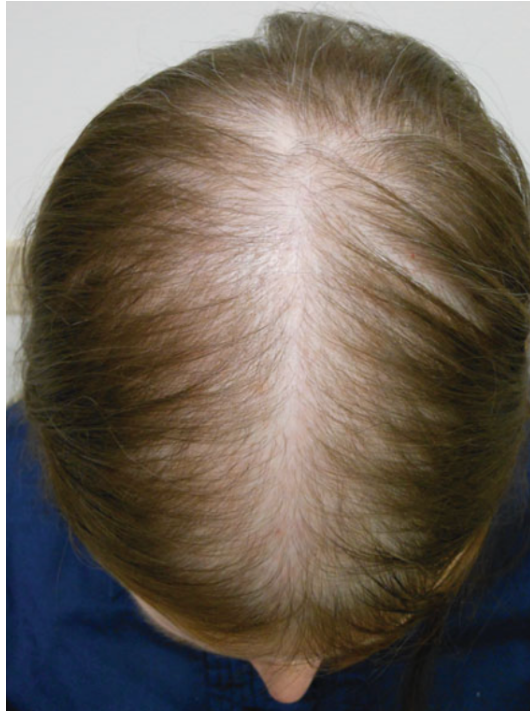Another clinical characteristic of AGA is the lack of shedding, which can be evaluated through the hair pull test. If more than 0-2 hairs are pulled out, it may indicate an additional condition, such as telogen effluvium alongside AGA. (21)



**Figure 6.** The Ludwig triad scale type of balding in women. Generalized crown balding while maintaining the frontal hairline. (17)

*(Source: Vujovic A, Del Marmol V. The Female Pattern Hair Loss: Review of Etiopathogenesis and Diagnosis. BioMed Res Int.2014:1-8)*

AGA is generally diagnosed clinically, which includes a thorough medical history and physical assessment, as well as scalp inspection and testing for other immunological or hormonal conditions. The doctor should note the age of onset, length of duration, development of balding, and periods of increased activity, often reported in the fall and winter seasons. Patients need to be queried regarding weakening and shedding. While a positive family history is expected, a lack of one does not rule out FPHL. A complete gynecological and obstetrical history should also be taken. (17,21)



**Figure 7.** A female patient with androgenic alopecia exhibiting thinning of hair centrally.  
(Source: Soutor C, Hordinsky MK. *Clinical Dermatology. 1st ed. New York: McGraw-Hill Education; 2013* )

#### 3.1.4. *Acanthosis Nigricans*

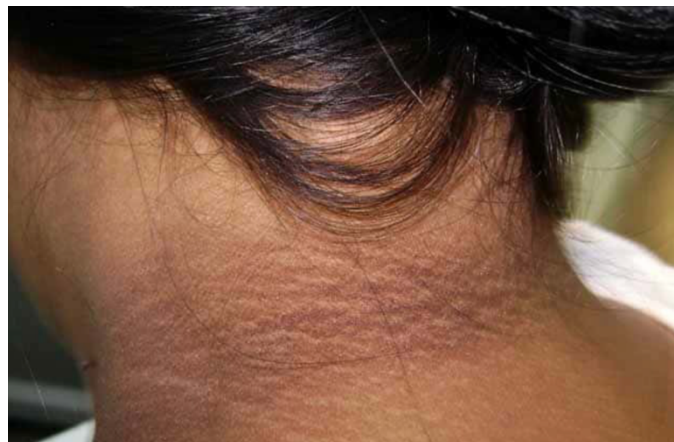Acanthosis nigricans (AN) is a prevalent chronic disorder manifested with velvety, hyperpigmented, and hyperkeratotic plaques predominantly seen in body folds such as the neck (Figure 8.), axillae, groin, antecubital and popliteal fossae. The distribution is most commonly symmetrical. The pigmentation is primarily due to the thickened epidermis and hyperkeratosis, not because of increased melanin. It is usually asymptomatic but may be pruritic. From a histopathological perspective, AN is marked by papillomatosis (irregular growth of papillary layer in the skin, giving it a warty look) and hyperkeratosis (over-thickening of the stratum corneum), contributing to the distinctive rough and darkened appearance of the skin. (22, 23)

With the increasing trend of obesity and associated metabolic disorders (DM2), there has been an increase in the incidence of AN. It ranges widely between 7% and 74%, in accordance with age, race, frequency type, obesity level, and concurrent endocrine disorders. The highest prevalence is reported to be in African American women. (23) AN is commonly present in

PCOS patients, as well as in individuals with insulin resistance and obesity, both disorders prevalent in PCOS. It can also be present in some malignancies. The prevalence of the disorder in Caucasians is less than 1%, in the Latin population a bit more, while it is primarily prevalent in African Americans. (22)

Insulin crosses DEJ to attain keratinocytes. In small amounts, it controls metabolism and weakly promotes growth. In greater quantities, it can have stronger growth-stimulating impacts by attaching to insulin-like growth factor 1 receptors (IGF-1Rs), boosting the growth of keratinocytes and fibroblasts, ultimately resulting in the development of AN. Hyperinsulinemia contributes to AN development by rising free circulating IGF-1 levels and promoting cell growth and differentiation. (23)

AN severity is graded on a scale from 0-4 about the affected areas. (22) There are different types of AN. When we speak in terms of PCOS, this is syndromic AN. Type A of syndromic AN is accompanied by hyperandrogenism IR (HAIR-AN syndrome), and it includes hyperandrogenemia, IR, and AN. Type B manifests in patients with poorly managed DM, ovarian HA, or autoimmune disorders. Other types of AN include obesity-associated AN, medication-associated AN (medications that promote hyperinsulinemia), auto-immune AN ( in SLE), acral AN, unilateral AN, familial AN, benign genetic AN, and mixed-type AN. (23)



**Figure 8.** A female patient with Acanthosis nigricans presenting on the neck.

(Source: DermNet [Internet]. New Zealand: DermNet New Zealand Trust; [updated 2024; accessed June 24, 2024]. Available from: <https://dermnetnz.org/images>)

### 3.2. Treatment

PCOS treatment needs to be customized to each patient's particular requirements, intending to reduce hyperandrogenic signs, induce ovulation, regulate menstrual cycles, and prevent cardiac and metabolic issues. The most challenging signs for women suffering from PCOS are period irregularities, hirsutism, and reproductive issues. Due to the complexity of PCOS, therapy is usually multimodal and unique to the patient's particular signs and symptoms. Cycle abnormalities, androgen-related signs, and infertility are among the most common symptoms addressed by both pharmaceutical and nonpharmacological therapies. While there are different therapeutic options for addressing metabolic comorbidities in PCOS, no single medication can handle the whole range of metabolic irregularities. Nutrition and lifestyle changes, are also essential in PCOS treatment. Combining lifestyle changes and drugs produces better metabolic advantages compared to monotherapy. (24)

#### 3.2.1. Hyperandrogenism

As previously stated, PCOS is associated with hyperandrogenism, which is defined by an imbalance in hormonal levels. When treating hyperandrogenism caused by PCOS, it is critical to evaluate any coexisting diseases, such as insulin resistance, as well as any potential contraindications for a specific treatment. Hormonal therapy is a feasible therapeutic choice for correcting this imbalance, but a thorough assessment of every patient's individual clinical profile is required for successful and appropriate treatment.

##### a. Blocking of androgen production and decrease in bioavailability of androgens

Combined estrogen-progestin oral contraceptives (COCP) represent the first line of therapy in patients of reproductive age who don't want to become pregnant. Estrogens contribute by blocking the synthesis of LH, which will simultaneously increase SHBG. The increased production of SHBG eventually decreases circulatory androgens. Due to elevated SHBG levels, ovarian androgen production lowers, decreasing free testosterone levels. Some progestins, such as levonorgestrel and norethindrone, are contraindicated in PCOS, as they present with some androgenic effects. Also, COCP has a negative effect on insulin resistance. Adverse effects may present as dyslipidemia, thrombogenesis, and increased risks of cardiovascular events. Women who are tobacco users, obese, of advanced age (>39), and at high risk for VTE have a recommended lower dose of ethinyl estradiol. The minimum effective dose is typically 20 mcg, as opposed to a standard dose that is 30-35 mcg. However, it has an equal effect. After 6 months of COCP therapy, the symptoms of the condition should be re-evaluated for improvement.

Should there be no improvement, an additional therapy with antiandrogen should be considered. (1,25–27)

GnRH agonists or antagonists may also be considered with the aim of reducing gonadal hormone generation. However, their main adverse effect is the significant lowering of estrogen, which is associated with osteoporosis. (27) Other side effects include atrophy of the vagina and hot flushes, which are commonly seen in menopause due to reduced estrogen levels. GnRH antagonists should be used when antiandrogens and COCP therapy fail. (28)

Theoretically, corticosteroids may improve hormonal dysbalance by inhibiting androgen generation. However, their negative effects exceed their potential positive effects, and prolonged therapy with corticosteroids is not recommended routinely in PCOS-associated hyperandrogenism. (27) Nevertheless, low doses of glucocorticoids can potentially treat hirsutism if the patient has no effects after taking COCP as monotherapy or COCP with antiandrogens as dual therapy or to stimulate ovulation. (25)

b. Suppression of androgen conversion peripherally

Finasteride is a selective 5-alpha-reductase type 2 inhibitor. Type 1 exists in the sebaceous glands, whereas the second type is found in the prostate gland. Finasteride is used to treat benign hyperplasia of the prostate. (27) It stops the conversion from testosterone to DHT in hair follicles. (26) FPHL is typically treated with 5- $\alpha$  reductase inhibitors, which limit the transformation of testosterone to its more powerful form, DHT. Although these agents were not designed particularly for use with excessive levels of androgens in women and have not been FDA-approved for this particular reason, they have proven successful in treating FPHL hirsutism in women with PCOS. (29) In women it can be used at 5 mg daily dose, and it is shown that in 6 months to 1 year, it lowered mFG score by up to 17% and decreased hair thickness in hirsutism. (27, 30) Due to finasteride teratogenic effect, suitable contraceptive methods should be implemented. (27) Inhibitors of 5-alpha-reductase are contraindicated in patients with breast cancer history as they can lead to elevated estrogen levels. (29)

c. Blockage of androgen activity

Spirolactone, a competitive androgen for 5-alpha-reductase and sex hormone binding globuline androgen receptor, acts as a light diuretic. It has been shown to improve signs of hirsutism by up to 19% on the mFG scale at doses of 100 mg to 200 mg for up to 6 months. Because of the teratogenic consequences it can have on a male fetus by blocking androgen action, which is crucial for the formation of male external genitalia, it is necessary to implement adequate contraceptive measures. Given that it is a potassium-sparing diuretic, a possible

adverse effect is hyperkalemia, postural hypotension, and vertigo. It can also cause menstrual irregularities and hepatic complications. (1,9,27,28,30)

Cyproterone acetate is a potent progestin that competitively blocks androgen receptor and 5 alpha-reductase, decreasing free testosterone concentration. A dose of 50-100 mg of cyproterone acetate is combined with 30-35 micrograms of ethinyl estradiol daily, and it showed higher effectiveness than spironolactone 100 mg daily. Adverse effects include decreased libido, VTE risk, and mood swings. (26,28,30)

Flutamide is a nonsteroidal antiandrogen and is a therapy of choice in prostate cancer. However, its effectiveness extends into treating hirsutism, AGA, and acne. (9) Doses of 250 to 500 mg daily demonstrate antiandrogenic activity, resulting in up to 40% reduction in the mFG score. Yet, it is not commonly employed for the therapy of hirsutism because of the unwanted effects it may exert, such as liver toxicity. (30,31) Flutamide traverses the blood-brain barrier, disrupting androgenic hormones' negative feedback impact on the HPA axis. That may result in large rises in LH and testosterone. (29)

Bicalutamide, a targeted AR blocker, is authorized by the FDA for the medical management of prostatic cancer. When compared to spironolactone, bicalutamide has zero mineralocorticoid action and does not block 5 alpha-reductase. A study found that individuals who received both bicalutamide 50 mg daily and COCPs over a 12-month period saw a greater decrease in hirsutism than individuals who received only COCPs. (29)

#### d. Insulin sensitizers

Although not fundamentally an anti-androgenic compound, metformin's impact on insulin and androgen concentrations makes it an effective supportive therapy for alleviating hyperandrogenism symptoms in PCOS. By improving insulin sensitivity in tissues and reducing insulin concentrations, it can indirectly lower the production of androgens. It is used as a first-line therapy for IR, a second-choice therapy for menstruation abnormalities along with COCP, and a third therapeutical choice for hirsutism combined with COCP and spironolactone. (27,32,33)

Inositols operate as secondary messengers in insulin-related signaling routes, promoting a variety of insulin activities. In the therapy of PCOS, two important isomers, myo-inositol (MI) and D-chiro-inositol (DCI) are used as dietary supplements. While DCI improves insulin sensitivity by lowering systemic androgens, MI is primarily active in the ovaries, helping with FSH signaling. MI and DCI have both been shown to be successful in lowering LH, the ratio between LH and FSH, and testosterone concentration in PCOS. Studies indicate that



administering MI and DCI in a certain ratio (40:1) is especially successful in recovering ovulation.

DPP-4 inhibitors increase incretin concentrations, which regulate blood sugar by increasing insulin production, inhibiting glucagon release, and decreasing hepatic sugar synthesis. Sitagliptin, administered at a dose of 100 mg daily for thirty days, successfully decreases circulating glucose and abdominal adipose tissue while improving beta-cell activity and preventing diminished tolerance to glucose.

SGLT2 inhibitors diminish circulating sugar levels by eliminating glucose and sodium through urine. They concentrate on the uptake of glucose in the renal proximal tubules. When compared with metformin, empagliflozin significantly improves weight reduction, body mass index, waist-to-hip ratio, and decreases body fat. Licogliflozin, in a dose of 50 mg three times daily, successfully decreases high insulin levels and a high level of androgens in PCOS women, indicating that it might be a viable novel therapy. (34)

### *3.2.2. Hirsutism*

Hirsutism treatment should involve a combination of inhibition of androgens and cosmetic procedures. The treatment should also target conditions associated with PCOS, metabolic and gynecological disorders like endometrial hyperplasia, type 2 diabetes mellitus, etc., via lifestyle modification and/or medication.

Oral contraceptives (OC) are most frequently used to treat hirsutism. They lower circulating LH and FSH levels, lowering ovarian androgen synthesis and possibly decreasing adrenal androgen generation. Progestin can inhibit 5 $\alpha$ -reductase and subsequently block the AR, while estrogen in the COCP boosts SHBG levels, which decreases free testosterone; however, the progestin influence on SHBG is that of estrogen; it lowers SHBG with a subsequent increase in free testosterone. Because of this, OC used for hirsutism should have progestin, whose androgenic action is depressed (e.g., norethindrone acetate, desogesterol, norgestimate, etc.). Adverse effects include breast sensitivity, mood swings, abnormal bleeding aside from menstruation, mood swings, and minor fluid accumulation. Similarly, progestin in large doses can enhance the liver metabolism of testosterone and subsequently lower LH levels. However, the efficacy of this treatment in hirsutism therapy is not yet fully understood. (30)

In women of reproductive age affected by hirsutism, the first line of therapy is monotherapy with COCP. If the desired effect is not achieved in half a year, the second line of therapy is a dual therapy combination of COCP with either spironolactone or cyproterone acetate. In

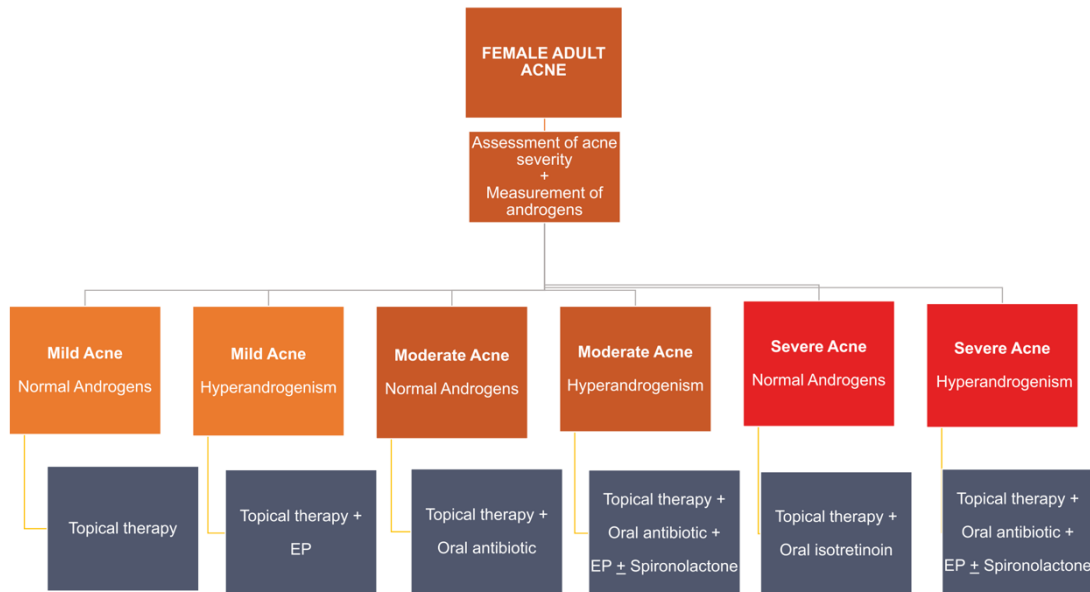
postmenopausal women, the therapy should include spironolactone or cyproterone acetate. In both cases, if the symptoms of hirsutism are severe or recurrent, the use of finasteride or GnRH agonist in combination with COCP is the therapy of choice.

Non-hormonal therapeutic options for hirsutism include mechanical epilation or depilation (shaving, plucking, waxing), chemical depilation or bleaching, topical eflornithine hydrochloride, electrolysis and laser or intense pulsed light procedures.

### 3.2.3. Acne

Regardless of the severity of their acne, PCOS patients should use COCP in conjunction with acne therapies, whether systemic or topical. COCP can effectively treat acne in PCOS, particularly in cases with deeply embedded nodules and recurrent acne on oral retinoids. Studies showed a 30-60% drop in the incidence of acne during three to six months of COCP therapy seen in 50-90% of patients. (13,15) For individuals with moderate to severe acne who are unresponsive to treatment, spironolactone could be introduced alongside estrogestins. If the patients are also unresponsive to the addition of spironolactone, oral retinoids are indicated as the next option. Using the acne grading tool is important before initiating therapy. A stepwise approach is recommended in acne therapy in patients who have PCOS (Figure 9). Those are:

1. Local therapy + COCP for mild acne
2. Local therapy + systemic antibiotic + COCP for moderate acne
3. Systemic Retinoid + COCP for severe acne. (13)



**Figure 9.** Guideline for initial management of adult acne based on serum androgen concentration. (13)

*(Source: Carmina E, Dreno B, Lucky WA, Agak WG, Dokras A, Kim JJ, et al. Female Adult Acne and Androgen Excess: A Report From the Multidisciplinary Androgen Excess and PCOS Committee. J Endocr Soc. 2022; 6(3):bvac003)*

### 3.2.3.1 Topical Treatments

Managing acne fundamentally relies on topical applications due to their limited systemic side effects, direct skin action, and ease of use.

Retinoids bind to RARs in the nucleus of the cell, primary RAR- $\gamma$ , which is predominant in human skin. FDA-approved retinoids for acne include tretinoin, adapalene, tazarotene, and trifarotene. These vitamin A derivatives have anti-inflammatory and comedolytic properties, making them valuable in treating acne. Their effect on gene transcription enhances skin cell turnover and lowers oil production. (13) Tretinoin, the first-generation retinoid, binds to RAR- $\gamma$ . Its key activities include epithelial layer normalization, pilosebaceous unit blockage prevention, and reduction of oil generation. Adapalene, a third-generation retinoid, binds to RAR- $\beta$  and RAR- $\gamma$ , lowering hyperkeratinization and inflammation with fewer adverse effects. Tazarotene binds selectively like adapalene. It is more potent than adapalene. However, it is also less tolerable, while adapalene is most tolerable but isn't as potent as tazatorene. Trifarotene is a retinoid of fourth-generation that was authorized by the FDA in 2019. It

selectively targets RAR- $\gamma$  and significantly reduces lesions, although it causes irritation. Topical retinoids are known to cause irritation, dryness, burning, and UV hypersensitivity; it is therefore advisable to introduce moisturizers and sun protection continuously. Retinoids are discouraged throughout pregnancy in favor of alternatives that are safer, such as azelaic acid or topical clindamycin. (13)

Topical benzoyl peroxide is a frequently employed therapy to treat mild or moderate acne. It is typically the initial therapy. Upon penetration into the pilosebaceous unit, it produces free radicals, which then destroy the cellular membranes of *C. acnes*. It possesses modest comedolytic and anti-inflammatory effects and prevents bacterial resistance; hence, it is used in combination with topically applied antibiotics or topical retinoids. Typically administered once a day, the benefits ought to be observed within a period of three weeks, with maximal lesion clearance occurring in 8-12 weeks. Lack of moisture, erythema, and allergic responses are all adverse side effects. (16) It can also cause photosensitivity and clothes bleaching. (35)

Topical antibiotics have both antibacterial and anti-inflammatory properties. They diminish perifollicular lymphocytic infiltration, biofilm development, and, therefore, microcomedones. Owing to *C. acnes* bacterium resistance, antimicrobial monotherapy is not recommended. To prevent resistance, it is advised to use topical benzoyl peroxide or retinoids concurrently. (16,35,36) In the United States, topical antibiotics and benzoyl peroxide are suggested as the initial therapy for mild acne. (16) Clindamycin is currently the favored topical antibiotic. Adverse effects include xerosis and skin irritation. Other than that, clindamycin is usually well tolerated. Clindamycin can be replaced with topical erythromycin. However, erythromycin is less effective than clindamycin due to increased resistance rates. (16,36) Minocycline is a tetracycline derivative. It has significant antibacterial properties and clears acne within a year's time. The most prevalent adverse effect is a headache. The FDA has authorized it, but the European Union has not. (16)

Azelaic acid, a natural dicarboxylic acid, is commonly present in grains like barley, rye, and wheat. It contains comedolytic, anti-inflammatory, antibacterial, anti-keratolytic, and antioxidant properties. It can be useful for reducing hyperpigmentation following an inflammatory process. It treats both inflammatory and non-inflammatory types of mild to moderate acne. Irritation, burning sensation, erythema, pruritus, and stinging are all undesirable side effects. It remains safe for use when pregnant or nursing. (16,35,36)

The most frequently administered over-the-counter topical acne medication is salicylic acid, which is both a comedolytic and keratolytic. It also has minor antibacterial and anti-inflammatory effects. For better outcomes, it may be paired with topical benzoyl peroxide.

(16,36) At greater dosages, it can be used for surface chemical peeling. Adverse effects involve xerosis, erythema, pruritus, and peeling. (16)

Although not approved in the EU, topical dapsone is approved by the FDA. This sulfone medication shows moderate efficacy in reducing inflammatory acne lesions. It is not advised to pair with benzoyl peroxide as it might cause orange discoloration. However, this is reversible. An adverse effect is skin irritation.

Sulphur has modest bactericidal and keratinolytic effects. By itself, it can cure mild to severe acne. However, the outcomes improve when paired with sodium sulfacetamide or topical benzoyl peroxide. Additionally, it is frequently mixed with sulfacetamide to disguise the sulfur scent. Sodium sulfacetamide is bacteriostatic and significantly reduces acne lesions (up to 78% over a 12-week duration). Adverse effects include xerosis, astringency, and pruritus. (16)

Clascoterone is a breakthrough topical therapy. It has been approved by the FDA, however, not yet in the EU. It is the very first topical antiandrogen, including anti-inflammatory and antiandrogenic properties. It is utilized to treat acne ranging from moderate to severe. Common adverse effects include local irritation and erythema. (16)

**Table 2.** Overview of topical therapeutics used in acne treatment and the effect that they exhibit (16,35,36)

Topical therapeutics	Effect			
	Comedolytic	Anti-inflammatory	Keratolytic	Antimicrobial
<b>Benzoyl peroxide</b>	+/-	+	-	-
<b>Retinoids</b> (e.g. adapalene, tretinoin)	+	+	-	-
<b>Azelaic Acid</b>	+	+	+	+
<b>Salicylic Acid</b>	+	+	+	*bacteriostatic *fungistatic
<b>Antibiotics</b> (e.g. clindamycin)	-	+	-	+
<b>Dapsone</b>	-	+	-	-
<b>Sulfur and sodium sulfacetamide</b>	-	-	+	+

### 3.2.3.2 Systemic treatments

Systemic therapeutics are generally indicated in moderate to severe acne or when local treatments are ineffective. However, COCP is recommended as the initial therapy for PCOS women. (16)

Oral antibiotics are recommended for moderate to severe acne and have an antimicrobial and anti-inflammatory mechanism of action. Common adverse effects consist of photosensitivity and gastrointestinal complaints. (16) Because of bacterial resistance, oral antibiotics should be taken for up to half a year, with concomitant use of topical retinoids or benzoyl peroxide to speed up the results and minimize the length of therapy. (35,36) Lyme cycline or doxycycline are the antibiotics of choice. However, due to contraindications

such as pregnancy and allergies, other systemic antibiotics like macrolides (erythromycin, azithromycin), TMP/SMX, penicillins (amoxicillin), and cephalexin can be considered. (16,36)

As previously mentioned, COCP is the initial line of therapy in PCOS women. It can be used long-term without the risk of developing bacterial resistance. COCP with spironolactone can enhance the antiandrogenic effect and improve acne. Adverse reactions involve fluctuating emotions, breast discomfort, and an increased risk of thromboembolism. (16,35)

Isotretinoin is a vitamin A derivative of first generation. It is recommended for severe nodular or moderate acne unresponsive to other medications. It decreases sebaceous gland size and action by sebocyte apoptosis, lowers inflammation, restores follicular keratinization, and diminishes *C. acnes* quantity. It may lead to remission. It is strongly teratogenic, particularly during the first trimester, and must be used in conjunction with contraceptives. Adverse effects may include xerosis, cheilitis, dry eyes, and muscular pains. During therapy, liver enzymes and lipid levels should be monitored. (16,35)

### 3.2.3.3 Procedural Therapies

Photodynamic treatment uses photosensitizing chemicals that eliminate bacteria and lower oil secretion. It is used to treat severe acne and acne that has failed to respond to prior therapies. Adverse effects include erythema, oedema, and photosensitivity. Blue-light treatment uses blue light to eradicate *C. acnes* bacteria while causing no skin damage. It treats mild to moderate acne. Erythema and xerosis are among the negative side effects. A chemical peel removes the skin's top layer and aids in eliminating debris from pores. Based on the peel's potency, it is used in mild to severe acne. Typical adverse effects are redness, peeling, and even scarring. Intralesional steroidal injections provide anti-inflammatory effects and reduce oil formation. It treats moderate to severe acne; potential adverse effects are localized atrophy. (16)

## 3.2.4. Androgenic alopecia

### 3.2.4.1 Hormonal therapies

Spironolactone may be a substitute for finasteride in FPHL patients. The starting dose is generally 50 mg daily for one month, followed by 100-200 mg afterward. To have the optimum benefits, it should be utilized for at least a year. It is typically recommended in combination with other treatments, particularly topical minoxidil. The research found that regrowth of hair or stability of losing hair occurred in a varying percentage of participants, from 44% to 74%. Women experiencing thinning hair, hirsutism, or acne respond much better to spironolactone versus women with hair loss alone. (21,29,37)

Bicalutamide has been successfully used in treating FPHL in PCOS patients, particularly those who are unresponsive to COCs and spironolactone. (29)

Flutamide was demonstrated to be more successful compared to finasteride or spironolactone in AGA. Due to the possibility of toxicity to the liver, blood transaminase levels should be checked monthly. Flutamide demonstrated a substantial decrease in Ludwig hair loss scores. (21,29,37)

Finasteride is available in oral and topical form. One mg of oral finasteride can be used daily. (20) Research in PCOS patients indicated that the medication may be begun even with greater dosages (2.5-5 mg daily). (29) Discontinuing medication causes perceived benefits to disappear as well as any potential negative effects to be cancelled. The adverse effects comprise a reduction in sexual desire, low blood pressure, and vertigo. (20) Topical finasteride has fewer adverse reactions yet a more varied effect of treatment. (20)

#### 3.2.4.2 Non-hormonal therapies

Topical minoxidil is considered the initial treatment in female AGA. It is a potassium channel blocker, and while the precise mechanism of action in hair loss is uncertain, it is thought to promote angiogenesis and vasodilation. Furthermore, it contains anti-androgenic and inflammatory properties and extends the anagen stage of the hair growth lifecycle. It comes in two concentrations: 2% and 5% solutions and 5% foam. According to certain research, the 5% show better results. Throughout the initial several months of therapy, telogen phase hair shedding may increase. The negative effects involve hypertrichosis and aggravation of pre-existing hirsutism. Additionally, scalp pruritus and peeling might appear. It should be taken for a year to achieve the best outcomes, and if effective, it should be continued permanently. (21,29,37)

Minoxidil can be used as an off-label oral therapy for AGA. It can induce retention of fluid, hypertrichosis, and low blood pressure if used along with another antihypertensive. (29,37)

Platelet rich plasma (PRP) is made from the blood of a patient using a centrifuge. Platelets are enriched with chemokines while also adding cytokines and factors of growth. This is then injected into areas of interest. A study showed superior results when PRP is combined with topical minoxidil versus only using minoxidil. (20,37) Platelet lysate (PL) treatment is the same as PRP, except that it contains a greater amount of growth hormones. It is assumed to substitute PRP since the benefits are more rapid and efficient when it comes to boosting hair



number width, and anagen rates. Adverse effects include minor hemorrhage, pain, and headache. (20)

Low- Level Laser Therapy (LLLT) has been shown to enhance circulation around follicles, decrease apoptosis, and prolong the hair growth period. It's a light treatment provided using helmets or caps. In short-term studies, it produced outcomes that resembled minoxidil. Adverse effects include mild urticaria, paresthesia, and scalp discomfort. (20)

Hair transplantation surgery involves taking hair follicles from the occipital region ('donor site') in locations where there is no balding and transplanting them to regions afflicted by balding. Some of the adverse effects are itching, scarring, scalp discomfort, haemorrhaging, and infections. AGA patients had graft survival rates exceeding 90%. The complete outcome is usually observed after approximately one year. (20,37) However, loss of hair will persist beyond the transplant sites, necessitating ongoing care following the surgery. (21)

Microneedling uses tiny needles to create small skin wounds. It can help treat hair loss by boosting growth hormones, promoting hair follicle development, increasing collagen and elastin, and allowing better absorption of treatments like minoxidil or PRP. A study found that using microneedling with minoxidil improved hair growth in the frontal area, the most common androgenic baldness location in women. (37)

Ketokonazole, an antifungal medicine containing anti-inflammatory properties, decreases the number of *Malassezia* and can diminish DHT levels in the skin. It is advised for female AGA patients suffering from seborrheic dermatitis or sebopsoriasis. (37)

### 3.2.5. *Acanthosis Nigricans*

The treatment strategy for managing AN consists of correcting the fundamental conditions and administering local or systemic drugs. It is crucial to deal with elevated insulin levels. AN is mainly a cosmetic concern but can point to other underlying conditions. (23)

Local treatment for AN includes retinoids, lactic acid and chemical peels, and calcipotriole. Lactic acid is an exfoliating chemical that, when combined with a retinoid (often tretinoin), may effectively treat AN. (23) Trichloroacetic acid (TCA) is a surface chemical exfoliator that causes the epidermis to freeze, with subsequent inflammation and stimulation of wound repair processes, resulting in skin regeneration. TCA 15% remains secure, readily accessible, inexpensive, and simple to prepare. (23) Calcipotriol suppresses cell proliferation while facilitating conversion by raising calcium within the cell and cyclic GMP concentrations in keratin cells. One research conducted indicated that the drug is a secure and easily tolerated alternate therapy for AN whenever an etiological therapy isn't possible or required. (23)

The main systemic treatment option for AN is isotretinoin, which has been found to effectively manage widespread AN, however, recurrence is possible. (23) Metformin was shown to be beneficial in the therapy of AN and IR over a 6-month period. (23)

#### **4. Discussion**

Recognizing dermatological conditions in PCOS is essential to prevent severe long-term consequences.

The pilosebaceous unit, which refers to the hair follicle, shaft, and sebaceous gland, is implicated in disorders such as hirsutism, acne, and AGA. The ovaries, adrenal glands, and, to a lesser extent, the sebaceous glands and epidermis create androgens using cholesterol. The skin converts circulating 17-ketosteroids into dihydrotestosterone, the most potent endogenous androgen, by 5 $\alpha$ -reductase. Both testosterone and DHT bind to keratinocytes in the hair follicle's external root sheath and act via AR found in the sebaceous epithelium. (9)

PCOS is a challenging condition whose pathogenesis is poorly understood. However, based on available research, PCOS women had greater concentrations of inflammatory markers. These indicators are associated with long-term metabolic conditions and a higher probability of ischemic cardiovascular illness. Furthermore, data shows that being overweight and IR are linked to inflammation in PCOS. These conditions might play a vital part in the initial development of PCOS pathophysiology. Hyperandrogenism is also associated with an elevated leukocyte count, indicating that persistent mild inflammation in PCOS may be influenced by androgen hormone concentrations alongside obesity. Two studies associated bone morphogenic protein (BMP) and polycystic ovary syndrome, raising the question of whether BMP is responsible for dermatologic manifestations in PCOS. (38, 39) All of this generates plenty of questions regarding future research directions. Further PCOS studies should emphasize uncovering the specific molecular processes that relate obesity, insulin resistance, and androgen levels to inflammation since this may provide novel treatment strategies. Understanding the immediate effect of androgenic hormones on the immune system and inflammatory mechanisms and uncovering new genetic variants and epigenetic alterations can help us know PCOS pathophysiology.

Assessing the efficacy of anti-inflammatory therapies, lifestyle changes, and drugs that target insulin resistance and testosterone levels is of utmost importance. Identifying acne, hirsutism, and alopecia in PCOS patients enables tailored therapies to deal with skin-related issues and underlying metabolic disorders, enhancing general well-being and quality of life.

Treatments like oral contraceptives and anti-androgen medications, which target hormonal imbalances and reduce androgen levels, align with current PCOS guidelines for managing symptoms like acne and hirsutism. Similarly, lifestyle changes such as weight loss, dietary adjustments and exercise improve insulin sensitivity and lower androgen levels, supporting the recommendation of lifestyle interventions as first-line therapy for PCOS-related dermatological symptoms. (38)

The growing amount of research backing up the application of hormonal, lifestyle, and cosmetic therapies shows that present recommendations might have to be updated to reflect the positive effects of integrated strategies. Yet, while certain therapies are compatible with standard guidelines, doctors must take into account age, associated comorbidities, and individual desires when developing individual therapy regimens, emphasizing the significance of the individual approach.

The benefits of hormone therapy include the regulation of menstrual periods and the reduction of androgens (which may improve acne and hirsutism). This treatment option has received much research and is extensively used. Still, it might not be recommended for women who have past experiences of VTE, certain malignancies, or hepatic conditions. It may cause an increase in weight, mood fluctuations, and a higher risk of cardiovascular disease. It is beneficial in an array of PCOS phenotypes, including hyperandrogenism. It has been utilized on young patients predominantly. Antiandrogens work directly to prevent androgenic action and may assist with acne, seborrhea, and hirsutism. The disadvantages include high potassium levels, menstruation irregularity, and breast discomfort. Antiandrogens are not recommended during pregnancy since there is a risk of teratogenic effects in the male fetus. It is helpful for PCOS phenotypes with significant hyperandrogenism and appropriate for reproductive-age women. Antiandrogens should be taken with caution in women with renal impairment or those using potassium-sparing diuretics.

The benefits of insulin sensitizers include enhanced sensitivity to insulin and control of weight. They may assist in subtly lowering androgen levels, thus alleviating skin problems. They help manage the metabolic elements of PCOS. However, they have limitations, such as vomiting and loose stool, and they cannot manage hyperandrogenic signs as successfully as hormonal treatment. They are very useful in IR, and are appropriate for all ages. They benefit obese patients and those with metabolic syndrome.

Locally applied retinoids reduce acne and improve the appearance of the skin whilst exhibiting fewer side effects versus systemic medications. Limitations are irritation to the skin, xerosis, and sensitivity to light.

In overweight individuals, lifestyle adjustments such as eating habits and physical activity could enhance insulin sensitivity and general metabolic state. The issue is that it necessitates strong dedication and persistence. The effects might be slow and might not have an immediate impact on hyperandrogenism. This approach works across all phenotypes, specifically ones with IR. It is also advantageous to people who have metabolic syndrome, diabetes, or are at risk of developing cardiovascular disease.

Treatment ought to be chosen based on the individual's PCOS phenotype, years of age, childbearing intentions, comorbidities, and personal choices. Combining therapies, such as lifestyle changes and medication, frequently produces the best results.

## **5. Conclusion**

Polycystic ovary syndrome is a complex endocrinological condition that significantly impacts women of childbearing age, reducing quality of life and life expectancy. Its multifactorial nature, involving endocrinological, genetic, metabolic, dermatological, and environmental factors, which complicates both diagnosis and treatment. This review has explored the diagnostic criteria, pathophysiology, and therapeutic options for the dermatological manifestations of PCOS, with a focus on hyperandrogenism, hirsutism, acne, and AGA.

The diagnostic criteria for PCOS have evolved to include four distinct phenotypes, each characterized by varying degrees of hyperandrogenism, oligo-anovulation, and PCOM. Understanding these phenotypes is crucial for accurate diagnosis and personalized treatment plans. The review also underscores the importance of addressing dermatological conditions in PCOS to prevent long-term consequences and improve patients' overall well-being.

For the treatment of hyperandrogenism, a multi-faceted approach is essential. Combined oral contraceptives are the first line of therapy for patients who are unwilling to become pregnant, as they reduce androgen production and bioavailability. Additional therapies, such as GnRH agonists or antagonists and insulin sensitizers like metformin, offer alternative strategies for managing hormonal imbalances. Antiandrogens and 5-alpha-reductase inhibitors provide targeted treatments for hyperandrogenic symptoms but require careful consideration of their side effects and contraindications.

Hirsutism, a common and distressing symptom of PCOS, can be managed with a mix of pharmacological treatments and aesthetic procedures. COCPs, often combined with

spironolactone or cyproterone acetate, form the cornerstone of medical therapy. For patients unresponsive to these treatments, options like finasteride and GnRH agonists/antagonists may be considered. Non-hormonal methods such as mechanical epilation, chemical depilation, and laser treatments offer additional avenues for symptom relief.

Acne in PCOS patients can be effectively controlled by combining topical and systemic therapies. COCPs remain a primary treatment, complemented by local agents like retinoids, benzoyl-peroxide, and antibiotics. In cases of moderate to severe acne, systemic antibiotics and retinoids may be necessary. A stepwise approach ensures that treatment is tailored to the severity of the condition, with a focus on minimizing adverse effects.

Androgenic alopecia, another manifestation of PCOS, responds relatively well to both hormonal and non-hormonal treatments. Spironolactone, finasteride, and flutamide offer hormonal therapeutic options, while topical and oral minoxidil provide effective non-hormonal treatments. The appropriate treatment is determined by the patient's response and tolerance to treatment.

In conclusion, managing the dermatological manifestations of PCOS requires a comprehensive, individualized approach. By combining hormonal therapies, topical and systemic treatments, and cosmetic procedures, clinicians can effectively address the diverse symptoms of PCOS. Ongoing research and clinical practice should continue to refine these strategies, aiming to boost life quality for women suffering from this common condition.

## **6. Summary**

Polycystic ovarian syndrome is a complicated and prevalent metabolic condition affecting women of childbearing years. The pathophysiology is not fully understood. The thesis focuses on the complex relationship between PCOS and dermatological conditions. The emphasis is on understanding how PCOS affects the state of the skin, resulting in acne, hirsutism, and baldness. The fundamental hormonal disturbances and inflammation mechanisms that cause those cutaneous conditions in PCOS individuals are reviewed. Furthermore, numerous therapy approaches, spanning from hormone medications to lifestyle changes, are being evaluated for their effectiveness in treating PCOS-related skin issues. The emphasis is on encouraging interaction among dermatologists and endocrinologists in order to customize therapies and improve the general health of those who suffer from PCOS-related skin symptoms.

## 7. Literature Cited

1. Waghmare SV, Shanoo A. Polycystic Ovary Syndrome: A Literature Review With a Focus on Diagnosis, Pathophysiology, and Management. *Cureus* 2023; 15(10):e47408.
2. De Leo V, Musacchio MC, Cappelli V, Massaro MG, Morgante G, Petraglia F. Genetic, hormonal and metabolic aspects of PCOS: an update. *Reprod Biol Endocrinol.* 2016;14(1):38.
3. Azziz R. Polycystic Ovary Syndrome. *Obstet Gynecol.* 2018;132(2):321–36.
4. Lentscher JA, Decherney AH. Clinical Presentation and Diagnosis of Polycystic Ovarian Syndrome. *Clin Obstet Gynecol.* 2021;64(1):3–11.
5. Hoeger KM, Dokras A, Piltonen T. Update on PCOS: Consequences, Challenges, and Guiding Treatment. *J Clin Endocrinol Metab.* 2021;106(3):e1071–83.
6. Fahs D, Salloum D, Nasrallah M, Ghazeeri G. Polycystic Ovary Syndrome: Pathophysiology and Controversies in Diagnosis. *Diagnostics.* 2023;13(9):1559.
7. Aggarwal M, Chakole S. Prevalence of Polycystic Ovarian Syndrome and Its Link to Obesity in Adolescent Girls. *Cureus* 2023;15(9):e45405.
8. Christ JP, Cedars MI. Current Guidelines for Diagnosing PCOS. *Diagnostics.* 2023;13(6):1113.
9. Lee AT, Zane LT. Dermatologic Manifestations of Polycystic Ovary Syndrome: *Am J Clin Dermatol.* 2007;8(4):201–19.
10. Spritzer PM, Marchesan LB, Santos BR, Figuera TM. Hirsutism, Normal Androgens and Diagnosis of PCOS. *Diagnostics.* 2022;12(8):1922.
11. Gainder S, Sharma B. Update on management of polycystic ovarian syndrome for dermatologists. *Indian Dermatol Online J.* 2019;10(2):97.
12. Khan A, Karim N, Ainuddin JA, Faheem MF. Polycystic Ovarian Syndrome: Correlation between clinical hyperandrogenism, anthropometric, metabolic and endocrine parameters: Polycystic Ovarian Syndrome. *Pak J Med Sci* 2019;35(5).

13. Carmina E, Dreno B, Lucky WA, Agak WG, Dokras A, Kim JJ, et al. Female Adult Acne and Androgen Excess: A Report From the Multidisciplinary Androgen Excess and PCOS Committee. *J Endocr Soc.* 2022;6(3):bvac003.
14. Rao A, Douglas SC, Hall JM. Endocrine Disrupting Chemicals, Hormone Receptors, and Acne Vulgaris: A Connecting Hypothesis. *Cells.* 2021;10(6):1439.
15. Gainer S, Sharma B. Update on management of polycystic ovarian syndrome for dermatologists. *Indian Dermatol Online J.* 2019;10(2):97.
16. Kim HJ, Kim YH. Exploring Acne Treatments: From Pathophysiological Mechanisms to Emerging Therapies. *Int J Mol Sci.* 2024;25(10):5302.
17. Vujovic A, Del Marmol V. The Female Pattern Hair Loss: Review of Etiopathogenesis and Diagnosis. *BioMed Res Int.* 2014;2014:1-8.
18. Redler S, Messenger AG, Betz RC. Genetics and other factors in the aetiology of female pattern hair loss. *Exp Dermatol.* 2017;26(6):510-7.
19. Vinay K, Sawatkar G, Dogra S. Hair manifestations of endocrine diseases: A brief review. *Indian J Dermatol Venereol Leprol.* 2018;84(5):528.
20. Bajoria PS, Dave PA, Rohit RK, Tibrewal C, Modi NS, Gandhi SK, et al. Comparing Current Therapeutic Modalities of Androgenic Alopecia: A Literature Review of Clinical Trials. *Cureus* 2023; 15(7):e42768.
21. Carmina E, Azziz R, Bergfeld W, Escobar-Morreale HF, Futterweit W, Huddleston H, et al. Female Pattern Hair Loss and Androgen Excess: A Report From the Multidisciplinary Androgen Excess and PCOS Committee. *J Clin Endocrinol Metab.* 2019;104(7):2875–91.
22. Alshareef I, Assiri S, Alosaimi AK, Alhothali OS, Alsulami RR, Alkidaiwi S, et al. Acanthosis Nigricans Presenting as Skin Tags: A Case Report. *Cureus* 2023; 15(1):e33706.
23. Piske M. An approach to acanthosis nigricans. *Indian Dermatol Online J.* 2014;5(3):239.

24. Singh S, Pal N, Shubham S, Sarma DK, Verma V, Marotta F, et al. Polycystic Ovary Syndrome: Etiology, Current Management, and Future Therapeutics. *J Clin Med*. 2023 Feb 11;12(4):1454.
25. Bologna JL, editor. *Dermatology*. U: Reynolds R. In: *Hypertrichosis and Hirsutism*. 4<sup>th</sup> ed. Edinburgh: Elsevier; 2018. P. 1188- 202
26. Sharma A, Welt CK. Practical Approach to Hyperandrogenism in Women. *Med Clin North Am*. 2021;105(6):1099-116.
27. Lee AT, Zane LT. Dermatologic Manifestations of Polycystic Ovary Syndrome: *Am J Clin Dermatol*. 2007;8(4):201-19.
28. Hussein RS, Abdelbasset WK. Updates on Hirsutism: A Narrative Review. *Int J Biomed*. 2022;12(2):193–8.
29. Klein EJ, Oh CS, Karim M, Shapiro J, Lo Sicco K. A practical approach to the management of hair loss in patients with polycystic ovary syndrome. *J Eur Acad Dermatol Venereol*. 2023;37(8):1480–9.
30. Agrawal N. Management of hirsutism. *Indian J Endocrinol Metab*. 2013;17(7):77.
31. Mikiel D, Olszewska B, Polańska A, Adamski Z, Żaba R, Dańczak-Pazdrowska A. Principles of management of women with hirsutism – a dermatologist’s perspective. *Dermatol Rev*. 2020;107(5):424–40.
32. Williams T, Mortada R, Porter S. Diagnosis and Treatment of Polycystic Ovary Syndrome. *Am Fam Physician*. 2016;94(2):106-13.
33. Martin KA, Anderson RR, Chang RJ, Ehrmann DA, Lobo RA, Murad MH, et al. Evaluation and Treatment of Hirsutism in Premenopausal Women: An Endocrine Society Clinical Practice Guideline. *J Clin Endocrinol Metab*. 2018;103(4):1233–57.
34. Szczesnowicz A, Szeliga A, Niwczyk O, Bala G, Meczekalski B. Do GLP-1 Analogs Have a Place in the Treatment of PCOS? New Insights and Promising Therapies. *J Clin Med*. 2023;12(18):5915.



35. Bagatin E, Freitas THPD, Rivitti-Machado MC, Ribeiro BM, Nunes S, Rocha MADD. Adult female acne: a guide to clinical practice. *An Bras Dermatol*. 2019;94(1):62–75.
36. Tan AU, Schlosser BJ, Paller AS. A review of diagnosis and treatment of acne in adult female patients. *Int J Womens Dermatol*. 2018;4(2):56–71.
37. Starace M, Orlando G, Alessandrini A, Piraccini BM. Female Androgenetic Alopecia: An Update on Diagnosis and Management. *Am J Clin Dermatol*. 2020;21(1):69–84.
38. Sekhon AK, Zergham AS, Tserenpil G, Mebasher A, Malik BH. The Association Between Polycystic Ovary Syndrome and Its Dermatological Manifestations. *Cureus [Internet]*. 2020; 12(2): e6855.
39. Rudnicka E, Suchta K, Grymowicz M, Calik-Ksepka A, Smolarczyk K, Duszewska AM, et al. Chronic Low Grade Inflammation in Pathogenesis of PCOS. *Int J Mol Sci*. 2021;22(7):3789.