

Alopecia Areata - Current and Emerging Therapies

Sterk, Hanna Theresa

Master's thesis / Diplomski rad

2024

Degree Grantor / Ustanova koja je dodijelila akademski / stručni stupanj: **University of Rijeka, Faculty of Medicine / Sveučilište u Rijeci, Medicinski fakultet**

Permanent link / Trajna poveznica: <https://um.nsk.hr/um:nbn:hr:184:886605>

Rights / Prava: [In copyright](#)/[Zaštićeno autorskim pravom.](#)

Download date / Datum preuzimanja: **2024-07-26**



Repository / Repozitorij:

[Repository of the University of Rijeka, Faculty of Medicine - FMRI Repository](#)



UNIVERSITY OF RIJEKA

FACULTY OF MEDICINE

**INTEGRATED UNDERGRADUATE AND GRADUATE UNIVERSITY STUDY
OF MEDICINE IN ENGLISH**

Hanna Theresa Sterk

ALOPECIA AREATA – CURRENT AND EMERGING THERAPIES

GRADUATION THESIS

Rijeka, 2024

UNIVERSITY OF RIJEKA

FACULTY OF MEDICINE

**INTEGRATED UNDERGRADUATE AND GRADUATE UNIVERSITY STUDY
OF MEDICINE IN ENGLISH**

Hanna Theresa Sterk

ALOPECIA AREATA – CURRENT AND EMERGING THERAPIES

GRADUATION THESIS

Rijeka, 2024

Thesis mentor: Assoc. Prof. Sandra Peternel, MD, PhD

The graduation thesis was graded on 21.06.2024 in Rijeka, before the Committee composed of the following members:

1. Prof. Kristina Pilipović, MD, PhD (Committee Head)
2. Prof Hrvoje Jakovac, MD, PhD
3. Prof. Srđan Novak, MD, PhD

The graduation thesis contains 26 pages, 8 figures, 1 table, 54 references.

TABLE OF CONTENTS

INTRODUCTION	1
AIMS AND OBJECTIVES	1
LITERATURE REVIEW	2
1. Classification and disease severity	2
2. Etiopathogenesis	3
3. Clinical features	6
4. Diagnosis	7
4.1. Trichoscopy	7
4.2. Histopathology	9
5. Treatment	10
5.1. Steroids	10
5.1.1. Intralesional corticosteroids	10
5.1.2. Topical corticosteroids	11
5.1.3. Systemic glucocorticoids	11
5.2. Topical immunotherapy	11
5.3. Methotrexate	12
5.4. Cyclosporine	12
5.5. Immunomodulators	12
5.6. Minoxidil	13
5.7. Janus Kinase Inhibitors	13
5.7.1. Mechanism of action	14
5.7.2. Characteristics	15
5.7.3. Side effects	16
5.7.4. Laboratory parameters	16
5.7.5. Contraindications	16
5.7.6. Baricitinib	17
5.7.7. Ritlecitinib	17
5.8. Management	18
6. Prognosis	19
CONCLUSION	20
SUMMARY	21
LIST OF REFERENCES	22
CURRICULUM VITAE	26

List of abbreviations

AA	= Alopecia areata
α -MSH	= α - melanocyte stimulating hormone
CNV	= Copy number variations
CPK	= Creatinine phosphokinase
DPCP	= Diphenylcyclopropenone
EMA	= European Medicines Agency
FDA	= US Food and Drug Administration
GSH-Px	= Glutathione peroxidase
GWAS	= Genome-wide association studies
HF	= Hair follicle
HLA	= Human leukocyte antigen
IFN- γ	= Interferon- γ
IgE	= Immunoglobulin E
IL	= Interleukin
IP	= Immune privilege
JAK	= Janus Kinase
JAKi	= Janus Kinase inhibitor
MCH	= Melanin-concentrating hormone
MCHR2	= Melanin-concentrating hormone receptor 2
MCHR2AS1	= Melanin-concentrating hormone receptor 2 antisense RNA 1
MDA	= Malondialdehyde
MHC	= Major histocompatibility complex
NK	= Natural killer cells
SALT	= Severity of Alopecia Tool Score
SADBE	= Squaric acid dibutyl ester
SOD	= Erythrocyte superoxide dismutase
STAT	= Signal transducer/ activator of transcription
TEC	= Thyrosine kinase expressed in hepatocellular carcinoma
TGF- β 1	= Transforming growth factor- beta 1
TYK2	= Thyrosine kinase 2

INTRODUCTION

Alopecia areata (AA) is an autoimmune disorder that leads to patchy hair loss on the scalp and any other hair-bearing body area. It belongs to the non-scarring types of alopecia, and its clinical manifestation can vary in amount and size of patches, sometimes even affecting the entire body (1).

Approximately 2% of the general population is affected by AA and the onset mostly happens between the ages of 21 and 40 years, whereby an early onset is often associated with a higher risk for a more extensive form of AA (2).

The normal hair growth follows a specific cycle which consists of three phases. The first phase is the anagen phase, which is a phase of active hair growth lasting approximately four to eight years and containing most of the hairs. It is followed by the catagen phase, a short phase of follicular regression lasting around three weeks, which contains around 1-2% of hairs. The final phase is the telogen phase, a resting phase during which hairs fall out. Approximately 10-15% of hairs are in this phase and it lasts around three months.

In AA, normal hair growth is disrupted in some areas, which leads to the classical clinical picture (3). The diagnosis is primarily based on clinical manifestations. AA affects the physical appearance but can furthermore also have a significant effect on the psychological health and the quality of life of affected patients. Hairs are an important external factor of an individual's identity, and hair loss can result in emotional distress, anxiety and depression. Additionally, the patients can have a low self-esteem and poor body image. All of this can decrease the quality of life of patients (4).

Currently, there is no cure for AA. The existing treatment options focus on hair regrowth and therefore also the improvement of psychological well-being. Current treatment options have limited efficacy, can often induce several side effects and have high recurrence rates. New understandings in the pathophysiology of AA lead to newly emerging therapy options, which offer hope for more effective treatments. (2)

AIMS AND OBJECTIVES

This thesis aims to analyse the current and emerging therapies in the treatment of AA. Furthermore, the literature review intends to contribute recommendations for the treatment based on current guidelines.

LITERATURE REVIEW

1. Classification and disease severity

The severity of AA can be determined using the Severity of Alopecia Tool Score (SALT). The SALT score helps to standardize the quantification of hair loss across the different quadrants of the head (5). It works by measuring the amount of hair loss in four scalp regions: the right profile, left profile, vertex and posterior regions. The right and left profile regions each represent 18% of the total scalp area, the vertex region accounts for 40%, and the posterior region accounts for 24% (Figure 1). The sum of percentages is used to classify the extent of AA, with SALT0 indicating no hair loss and SALT100 indicating complete hair loss (100%) (2). Mild AA can be defined as SALT below 20, moderate AA as a SALT score of 21 – 49, and severe AA as SALT score higher than 50. (6)

The SALT II score is based on the original score, but the scalp areas are further subdivided into smaller segments, each accounting for 1%. This helps to get a more precise assessment of smaller patches.

According to SALT score, the therapeutic goal of AA should be $SALT \leq 20$, meaning 20% or less of scalp hair loss. Furthermore, SALT score results can be used to establish treatment options for each patient individually. For a SALT score of more than 50%, systemic therapies are advised (5).

A limitation of the SALT score is that it only encounters scalp hair and does not include facial hair such as eyelashes, eyebrows or bears, as well as body hair.

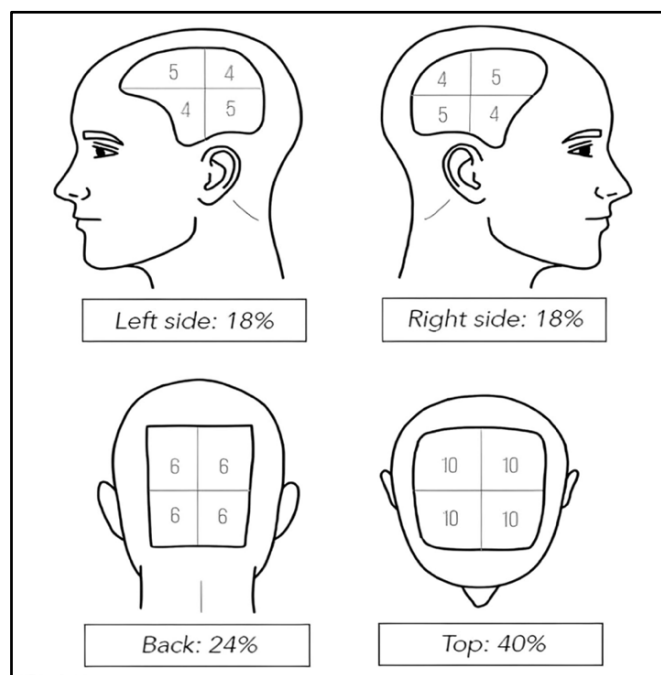


Figure 1 SALT score (7)

Besides the classification of AA according to SALT, it can be also categorized based on location and pattern of hair loss (Figure 2) (5). Patchy AA is the most common form and is characterized by circular patches distributed on the scalp or beard, which can be unifocal or multifocal (8). Diffuse AA involves hair loss distributed all over the head whereas AA reticularis describes hair loss distributed in a netlike pattern without clearly demarcated patches. In some cases, a melanocytic nevus is located in the patch, which characterizes perinevoid AA.

In AA ophiasis, hair loss follows a band-like pattern and is limited to the lower occipital and temporal regions of the scalp. When the top of the scalp is involved while the sides and back are spared, it is called AA sisaipho (9).

AA totalis is characterized by the total loss of hair on the scalp, whereas AA universalis, involves the whole body hair (5).

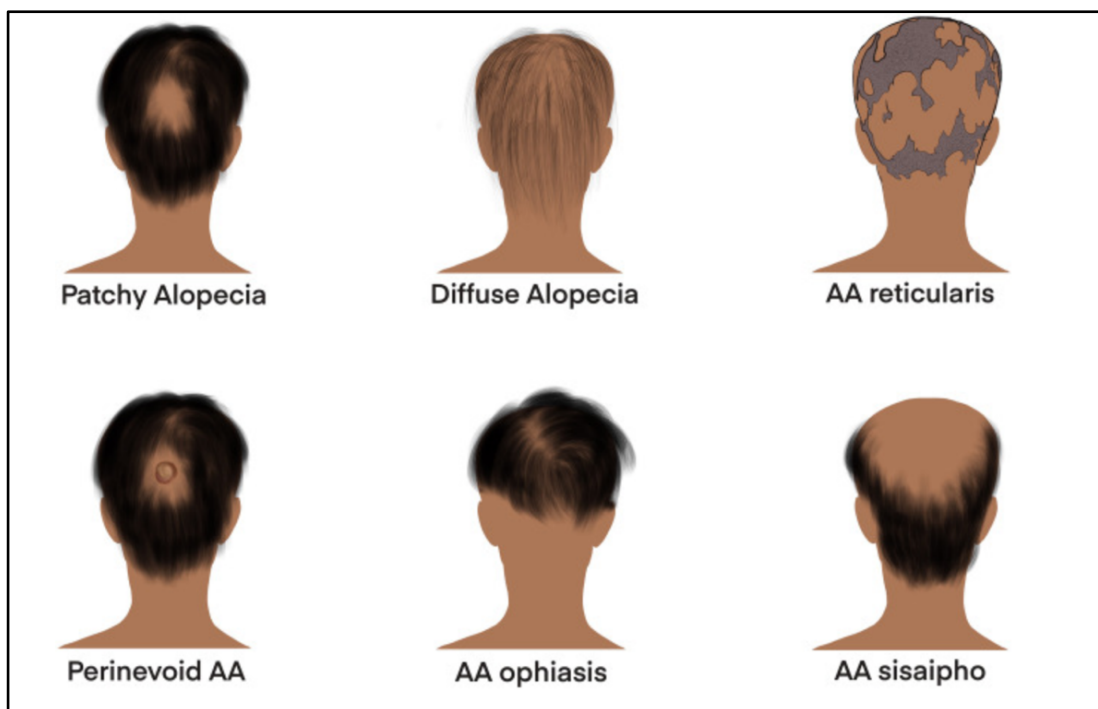


Figure 2 Classification of Alopecia areata (9)

Depending on the disease duration, AA can be classified into acute and chronic forms. Acute AA is defined with a duration of less than one year. If it persists for longer than one year, it can be called chronic. (6)

2. Etiopathogenesis

The etiopathogenesis of AA is not fully understood yet, various factors seem to contribute to the development of the disease. Genetics, the immune system, oxidative stress, allergy and

microbiota can play a role or be associated with AA.

The contribution of genetics in the pathophysiology of AA has been widely discussed in various genetic epidemiology studies. These have shown that there is an increased risk for first-degree relatives, which is estimated as the following: 7,1% for siblings, 7,8% for parents, and 5,7% for offspring. For the general population, the approximated lifetime risk is 2%. Furthermore, the risk for identical twins is estimated at 42-55%, whereas the risk for dizygotic twins is 0-10%. (10)

In genome-wide association studies (GWAS) and their meta-analysis, 14 genomic regions were identified, in which many associated genes were found. These include genes related to immune functions (e.g. interferon- γ production and T-cell activation), human leukocyte antigen (HLA) genes and hair follicle-related genes.

In contrast to many other chronic diseases, AA appears to have a polygenic cause. However, with the expansion of cohort size in the future GWAS, it should help to identify the genetic contributors to fully understand the etiopathogenesis of AA and to improve the therapeutic approaches. (11)

Recent genome-wide analyses of copy number variations (CNV) have identified duplications in genes related to melanin-concentrating hormone receptor 2 (MCHR2) and its antisense RNA 1 (MCHR2AS1). This suggests a potential role for melanin-concentrating hormone (MCH) signaling in the development of AA. Furthermore, a computational analysis combining CNV and gene expression studies revealed that the ATG4B and SMARCA2 genes potentially contribute in the development of AA in autophagy and chromatin remodeling. (1)

Besides genetic factors, also the immune system is involved in the development of AA. A central element in the pathophysiology may be a defect in the immune privilege (IP) system. IP is associated with different areas in the body, which include brain, retina, cornea, central nervous system, placenta, testicles, and hair follicles (10).

Hair follicles (HF) are IP sites which prevent an autoimmune response against autoantigens expressed in the HF, especially in the bulge region to the hair bulb (3). This happens through various mechanisms that act on different levels. First, immune cell recruitment and trafficking can be restricted. IP mechanisms at this level can include the absence of lymphatic vessels, leading to restriction of antigen presenting cells and activated lymphocyte migration, reduced proinflammatory chemokine expression which reduces the chemotaxis of pathogenic inflammatory cell, and the formation of extracellular matrix barriers which allows inflammatory cells to enter the tissues and reduces antigen presenting cells (12). Second, there can be a reduced antigen presentation. This can occur due to the decrease or even absence of

major histocompatibility complexes (MHC) class I or class II, latter of which is by Langerhans cells, leading to the reduced or absent presentation of antigens to CD4⁺ and CD8⁺ T cells, and the reduction or even lack of expression of β 2 microglobulins (13). And third, there can be active immunosuppression through the local production of immunosuppressants such as interleukin (IL) -10, transforming growth factor- β 1 (TGF- β 1), or α -melanocyte stimulating hormone (α -MSH) (12).

The breakdown of hair follicle IP is a crucial precursor for the pathogenesis of AA because it leads to increased exposure of HF-associated autoantigens and, therefore to inflammation, which is a precondition for AA.

Studies have demonstrated that Interferon- γ (IFN- γ) and CD8⁺ NKG2D⁺ T cells also play a role and are highly essential in the pathogenesis of AA. In those studies, IFN- γ was injected intravenously into mice and induced AA-like hair loss, whereby IFN- γ deficient mice have shown resistance to AA. Furthermore, CD8⁺ NKG2D⁺ T cells were identified to produce INF- γ via Janus kinase (JAK) 1 and JAK2 pathways and additionally have a positive feedback loop. The production of IFN- γ can trigger and enhance the production of the proinflammatory factor IL-15, which furthermore binds to CD8⁺ NKG2D⁺ T cells and induces positive feedback. However, the trigger leading to IFN- γ production by cutaneous T and NK cells in patients suffering from AA has not been fully understood.

Oxidative stress can trigger the increase of NKG2D ligands, leading to the breakdown of IP and thereby promotes AA. On the one hand, reduced presence of glutathione peroxidase (GSH-Px) and erythrocyte superoxide dismutase (SOD) have been detected both in lesions and blood cells of AA patients. On the other hand, there is an increased concentration of malondialdehyde (MDA). Meta-analysis has stated that AA is associated with higher levels of oxidative stress.

Allergies, and especially atopic diseases like atopic dermatitis, are seen in patients with AA. Several studies have shown that there are increased serum IgE levels in AA patients and eosinophils, as well as mast cells, were distinguished to be present in AA lesions.

Furthermore, the gut and skin microbiome are associated with various extraintestinal diseases. The initial connection between alopecia and the gut microbiome was made in a study involving mice. In this study, an antibiotic-triggered dysbalance provoked the development of alopecia. Besides this, two patients suffering from AA universalis experienced a fecal transplant in the treatment of *Clostridium difficile*. These patients had a significant hair regrowth 8 weeks after the transplantation (10). The link between the microbiome and autoimmunity is thought to involve a dysbiosis or disruption of the microbiome, leading to T-cell dysregulation and

immune system activation (14). Further investigations revealed differences in the gut microbiome between AA patients and healthy individuals. Specific bacterial species, including Actinobacteria and Candidiate division TM7, are present in higher levels in AA patients, while Bacteroidetes and Fusobacteria in lower levels. For instance, butyrate is a short-chain fatty acid produced by Bacteroidetes, which is crucial for the differentiation of regulatory T cells (15).

3. Clinical features

As already described previously, AA presents with patchy hair loss. The patches are round, smooth and well demarcated. Furthermore, they occur according to different patterns of hair loss, as for example AA universalis, totalis or patchy AA (16). The skin of affected patches appears normal and smooth (7).

Besides the hair loss, patients also suffer from increased hair shedding, which can mainly be seen on the periphery of patches. If multiple hairs can be extracted by gently pulling on the hair, it is indicative for active and progressive hair loss. Latest is called positive hair pull test (17).

Exclamation mark hairs can often be found in AA. They occur at the periphery of lesions and can be seen by the naked eye (17).

Furthermore, patients suffering from AA can also have nail abnormalities. These abnormalities occur with an incidence of 7-66% and are most commonly represented by nail pitting (Figure 4b) (18). Besides nail pitting, trachyonychia (Figure 4a) or red spots on the lunula can occur. The latter of which is not so common (occurs only in 5,1%), but specific for severe AA (19).

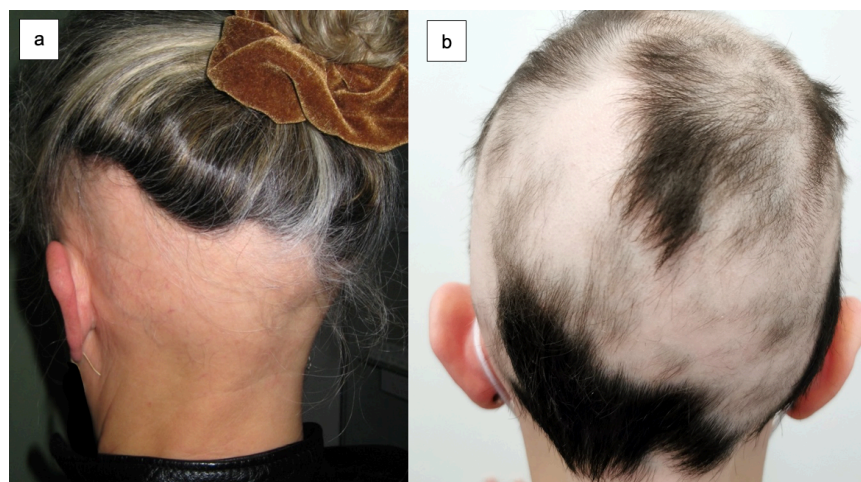


Figure 3 Patterns of hair loss; a: AA ophiasis; b: multilocular AA

(Source: S. Peternel, Clinical Hospital Center Rijeka)

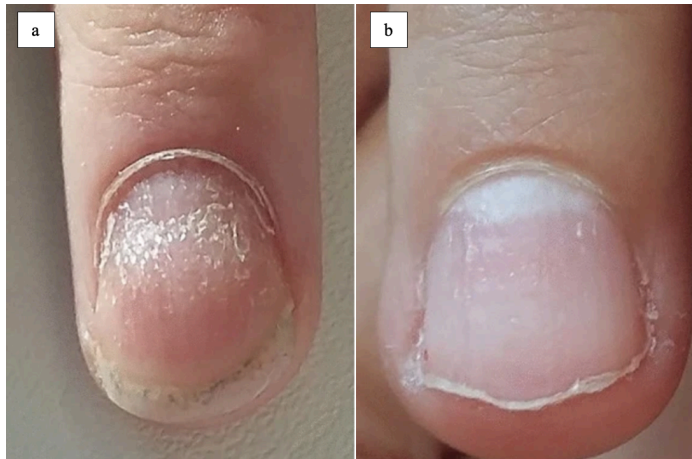

Figure 4 Nail abnormalities; a: Trachyonychia, b: Nail pitting (3)

4. Diagnosis

4.1. Trichoscopy

Trichoscopy is a simple, fast and non-invasive diagnostic method for hair loss, which is referred to as dermoscopy of hair and scalp. Besides making a diagnosis, it can evaluate the disease activity and severity, and may also be used for therapeutic monitoring of hair loss (20).

Frequent findings in AA include yellow dots, black dots, exclamation mark hairs, broken hairs, tapered hairs, vellus hairs, coudability hairs, upright regrowing hairs, pigtail hairs, and Pohl-Pinkus constrictions.

Dilated infundibula of HF filled with sebum manifest as yellow dots on trichoscopy (21). Organized in groups of one, two or three, they correlate with the number of hairs per follicular unit (22). Yellow dots differ in color (ranging from yellow to yellow-pink, yellow-brown or white), shape (polycyclic or round) and size. Furthermore, they can also appear as dots with a double border and homogenous color. In yellow dots, the hair can be miniaturized, cadaverous or dystrophic (23). Yellow dots can be found in 60-94% of patients with AA and the frequency increases with increasing age (24). Moreover, they serve as severity marker because their prevalence increases in chronic forms in which they are regularly distributed. They are highly sensitive for AA, but have a low specificity, since they can also be found in other types of alopecia (Figure 5a) (20).

Black dots characterize pigmented hairs, which are broken at the scalp surface with the root still attached to the follicle opening. They remind of comedos (21) and result from inflammatory damage to the hair follicles, which stops the mitotic activity and weakens the proximal portions of hair shafts, leading to breakage after emerging from the follicle openings (25). Black dots differ in size and may be grouped as two or three dots, which demonstrate hair shafts in one

follicular unit affected by the disease. They are characteristic for AA and indicative for an active disease, where a higher number stands for a poorer prognosis. Furthermore, they are negative predictive marker for treatment response (Figure 5b) (20).

Exclamation mark hairs are broken hairs, characterized by thinness and hypopigmentation at the proximal portion and thickness and hyperpigmentation at the distal portion (26). They originate from a temporary cellular degeneration phase, which happens between a precortical keratinocyte and a flawed cortical differentiation phase. With a length of 1-5mm, they are typically found peripherally in active lesions and are visible to the naked eye as well as under the trichoscope (20). The mean prevalence accounts for 39%, they designate activity and severity of AA and serve as negative prognostic marker (Figure 5c) (27).

Broken hairs occur either due to breakage of previously weakened hair shafts, or due to fast growth of partially damaged hairs. They are short in length and the hair shaft is normal. Only the distal end is irregular (20). Predominantly they can be found in acute AA (21) and are negative prognostic markers (Figure 5c) (20).

Tapered hairs are alike exclamation mark hairs. They also have a fine proximal and thicker distal end, but the difference is in length. Tapered hairs are longer and can even grow outside of the trichoscopy visual field (20). They can be found around lesions and seen with the naked eye. Tapered hairs are activity indicators and serve as negative predictive marker for hair regrowth (27). Usually they can be found in the initial stages of AA and before black dots and exclamation marks (Figure 5d) (20).

Coudability hairs are hairs that easily bend when the scalp is pressed, resulting in a twist of the axis and causing the hair shaft to become damaged and narrow. They have a thin proximal end, which may be the result of a rapid anagen-to-catagen transition (28). Coudability hairs are pathognomonic for AA and are related to the inflammatory activity of the disease (Figure 5e) (29).

Vellus hairs are indicative for regrowth and a good response to treatment. The proximal ends are pigmented and the thickness stays the same along the shaft, but they vary in length depending on the time of growth (30). Vellus hair is typically seen in long-term AA (20).

Upright regrowing hairs are healthy hairs, whose ends are thick, well pigmented and tapered. They are marker which indicate regrowth and positive response to therapy. Most commonly they are seen in children, because their hair growth is more extensive (20).

Pigtail hairs are short in length and curly. They are indicators for hair regrowth (31) and more common in children than in adults (Figure 5f) (20).

The term “Pohl-Pinkus constrictions” describes the narrowing of a hair shaft alongside its

length, resulting in constrictions. They are caused by a sudden suppression in mitotic and metabolic activity in the hair follicle, triggered by various internal and external factors. In AA they are relatively rare (2–10%) (Figure 5g) (32).

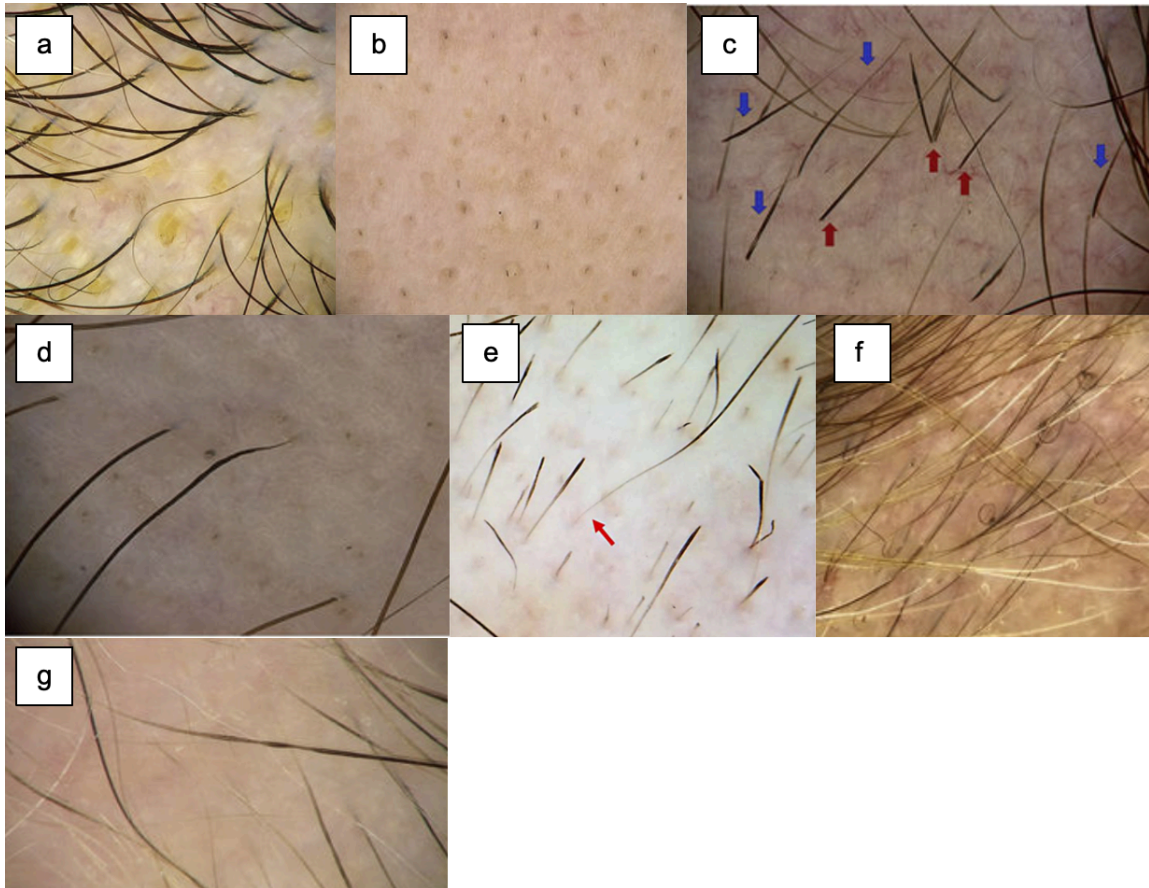


Figure 5 Trichoscopy; a: yellow dots; b: black dots; c: exclamation mark hairs (blue arrows), broken hairs (red arrows); d: tapered hairs; e: coudability hairs; f: pigtail hairs; g: Pohl-Pinkus constrictions (20)

4.2. Histopathology

Histopathology can be performed by a skin biopsy with findings that vary according to the stage of the disease.

In acute AA, the most common histopathological finding is peribulbar lymphocytic infiltrate, which can also be called “swarm of bees”. Besides this, eosinophils, melanin and lymphocytes in fibrous tracts may be found and are crucial for the diagnosis, if peribulbar lymphocytic infiltration is absent. Miniaturization of HF and a higher percentage of catagen/telogen hairs can also be detected. In most cases, the anagen terminal hairs are affected by inflammation (16).

In chronic AA, almost every follicle is in the telogen phase or diminished with an anagen phase morphology. This results in non-inflammatory alopecia and conservation of sebaceous glands (33).

5. Treatment

In the treatment of AA, there are several different drugs that can be applied. Generally, they can be divided into topical and systemic therapies.

Currently, the only drugs approved by the European Medicines Agency (EMA) for the treatment of AA are baricitinib and ritlecitinib. Other systemic drugs such as methotrexate, cyclosporine or corticosteroids are used off-label.

Treatment goal is to achieve hair regrowth, regain hair density and improve the psychological health. (6)

5.1. Steroids

Steroids have a main role in the treatment of AA and in patchy AA they are often used as first line therapy. They can be applied intralesionally, topically or systemically.

5.1.1. Intralesional corticosteroids

Intralesional steroid injections are best used in patients with either SALT <25 or isolated patches of hair loss (34). For intralesional injections, triamcinolone acetonide is used. It is administered every four to six weeks on the scalp at concentrations of 5 – 10 mg/ml and for eyebrows at concentrations of 2,5 – 5 mg/ml (34). Regrowth usually occurs in 60 – 67% of patients and can be seen after six to eight weeks. A study has shown, that there is similar hair regrowth regardless the concentration of triamcinolone acetonide, but there is a higher risk for cutaneous atrophy at higher concentrations (11).

Possible side effects of intralesional steroids are usually limited to skin changes. These include post-inflammatory hypo- or hyperpigmentation, atrophy, telangiectasis and striae. They are all reversible except striae, since the latter occur after long-term administration of high doses in always the same region (35). In the case of eyebrow treatment with intralesional corticosteroids, cataract or elevation of intraocular pressure can occur (34).

Intralesional corticosteroids are standardly used for patients with clinical signs of active inflammation, which include, for example, positive hair pull test or exclamation point hairs (7).

5.1.2. Topical corticosteroids

Topical steroids are usually used in children younger than ten years or adults who do not tolerate intralesional injections. Betamethasone dipropionate 0,05% is most commonly used and applied daily for three months. If there is improvement being observed after three months, the use of betamethasone will be gradually reduced. If not, the therapy will be stopped (36). The side effects of topical corticosteroids are similar to the side effects of intralesional corticosteroids. These include local skin atrophy, teleangiectasis, dyspigmentation and folliculitis (34).

5.1.3. Systemic glucocorticoids

Systemic glucocorticoids as prednisolone can be used in the treatment of AA and promote hair growth, but also induce many side effects. Because of the side effects and the high recurrence rate after stopping the therapy, they are not commonly used in the treatment of AA (36).

5.2. Topical immunotherapy

Topical immunotherapy is the preferred first line therapy in patients with extensive chronic AA (34). It is performed by using diphenylcyclopropenone (DPCP) or squaric acid dibutyl ester (SADBE) (10), both of which are contact allergens inducing a contact dermatitis (34). The mechanism of action is not fully comprehended, but it is supposed that an immunomodulatory effect on the peribulbar infiltrate plays a central role (34). They are applied to the scalp weekly and hair growth can be seen after three months of treatment. (36) The success rate accounts 60 – 70% and it is usually used for patients with SALT50 or higher (10).

At the beginning of the treatment, the patient must undergo sensitization, in which 2% DPCP is applied on a small, barely visible region on the scalp. One week after the sensitization, 0,001% DPCP I applied unilaterally, and the dose will be increased until the optimal dose for the patient is reached. This dose can be identified when the patient has tolerable dermatitis lasting for 36 hours after the treatment. After achievement of a response on the treated side, the contact allergen can be applied bilaterally. Once hair regrowth is reached, the weekly time span between the single treatments can be prolonged until it will be discontinued. In case the treatment with DPCP fails, an attempt with SADBE can be started. (7) After six months of treatment, hair regrowth occurs in 30% of patients and after 32 months it increased to 78% (34).

Limitations of this type of treatment are that it induces allergic contact dermatitis and that it must stay on the scalp for 48 hours, covered by a protective cap to prevent light exposure

(37). It is contraindicated in pregnancy and frequent adverse effects incorporate pigmentary changes and vitiligo, especially in patients with dark skin, eczema, blistering, lymph node enlargement and flu-like symptoms (7).

5.3. Methotrexate

Methotrexate is an immunosuppressant, which is known to be effective in different inflammatory and autoimmune disorders, as it is in AA. The analysis of 16 selected studies showed that the complete response in adults was 44,7%, meaning they had hair regrowth of 100%. A good or complete response, defined as hair regrowth of 50-100%, was seen in 69,3% of adults. In comparison to the stand-alone therapy with methotrexate, the combination therapy with corticosteroids had significantly better results. The most frequent side effects are hepatic and hematological side effects. Due to the high recurrence rate after reducing or stopping the treatment with methotrexate, a longer period of treatment should be considered in case the patient tolerates the therapy well (38).

5.4. Cyclosporine

Cyclosporine is an immunosuppressant, which is commonly used in the treatment of AA. It can be administered orally as monotherapy, or in combination with corticosteroids.

Studies have shown that the overall response rate among the patients was 65% and the results were better the lower the SALT score was. The combined therapy of cyclosporine and corticosteroids showed beneficial results in severe AA and furthermore decreased the relapses. Besides that, in combination with corticosteroids, cyclosporine can be used in lower doses, which decreases the risk for severe side effects, such as nephrotoxicity or hypertrichosis. The optimal duration of the treatment is not defined yet, but the first treatment success can be observed after 0,69 – 5,8 months (39).

5.5. Immunomodulators

Dupilumab, which is a humanized monoclonal antibody, can be used as immunomodulator for treating allergic diseases. It is currently approved by the US Food and drug administration (FDA) for the treatment of atopic dermatitis, asthma, chronic rhinosinusitis with nasal polyposis, prurigo nodularis and eosinophilic esophagitis.

A randomized, placebo-controlled clinical trial including 60 patients suffering from moderate to severe AA, found out that after 24 weeks, patients treated with dupilumab achieved disease stabilization, while patients in the placebo group experienced a worsening of AA. After 48 weeks of treatment with dupilumab, 32,5% of patients achieved 30% improvement in SALT

score (SALT30), 22,5% achieved 50% improvement in SALT score (SALT50) and 15% of patients achieved 75% improvement in SALT score (SALT75). Patients in the placebo group had a worse outcome. Additionally, patients with higher IgE levels and comorbid atopic dermatitis responded better to the treatment in comparison to those with lower IgE levels. Specifically, among patients having IgE levels ≥ 200 IU/ml, 53,8% achieved SALT30, 46,2% achieved SALT50 and 38,5% achieved SALT75. IgE levels also served as a predictive value for the efficacy of dupilumab treatment with an accuracy of 83%. However, also paradoxical effects of dupilumab were being observed in which the treatment induced exacerbation or reactivation of AA. Dupilumab appears to be a promising treatment for AA, but more studies are needed to make a conclusion regarding long-term effectiveness and safety (40).

5.6. Minoxidil

Minoxidil can be applied topically or systemically. Its mechanism of action is not completely understood, but it is supposed that minoxidil induces vasodilation, angiogenesis, and the proliferation of follicular dermal papillae. By this, it increases the anagen phase duration of the hair cycle and consequently enhances the length and thickness of new hair. As topical treatment, 5% minoxidil can be applied once or twice daily (41). In the treatment of AA, minoxidil as stand-alone therapy is insufficient and can be used as adjuvant therapy to help sustain hair growth induced by other drugs (37). It has only mild side effects such as dermatitis and pruritus and is not difficult to use (7).

5.7. Janus Kinase Inhibitors

Severe AA, when patients have SALT50 or higher, can also be treated with Janus kinase inhibitors (JAKi).

Janus kinase inhibitors belong to the emerging therapies in the treatment of AA and work by inhibiting the Janus kinase (JAK) and signal transducer/ activator of transcription (STAT) pathway (42). The JAK-STAT pathway includes a complex system of protein kinases, where extracellular mediator molecules regulate the expression of certain cell functions. These cell functions include for instance mitosis, differentiation, apoptosis or the formation of the immune system. The specific mechanism of action of JAKi is responsible for several advantages and decreases the occurrence of widespread side effects (43).

Baricitinib was the first JAKi approved by the FDA for the treatment of AA (44).

5.7.1. Mechanism of action

Various signaling molecules like growth factors and cytokines can be found in the extracellular space. They are dependent on transmembrane receptors for nuclear transcription of genes and cell signaling. First, cytokines couple with transmembrane receptors on their extracellular domain, which leads to conformational changes and phosphorylation on the intracellular domain of the receptor. After that, the phosphorylated JAK dimers transphosphorylate their terminal tyrosine residues, which causes dimerization and phosphorylation of inactive STAT units. These phosphorylated units translocate to the nucleus and mediate transcription of genes, which are associated with the specific cytokine pathway. JAKi act by preventing JAK phosphorylation (Figure 6) (43).

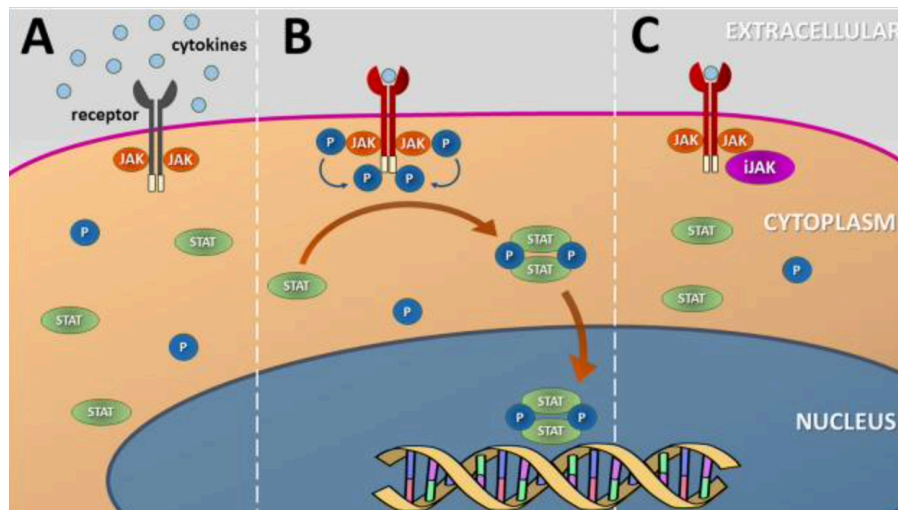


Figure 6 Mechanism of action of JAKi (43)

There are four different JAK enzymes involved in the JAK-STAT pathway, which are JAK1, JAK2, JAK3 and Tyrosine Kinase 2 (TYK2). Furthermore, seven STAT enzymes called STAT1, STAT2, STAT3, STAT4, STAT5a, STAT5b and STAT6 are part of the pathway. Their distribution in the tissues depends on the transmembrane receptors and types of cells involved in the signaling (44).

JAKi can selectively inhibit different groups of cytokines, depending on which JAK enzyme is involved, which is a great benefit in comparison to other immunosuppressants (Figure 7) (43).

JAK	Cytokines and growth factors
JAK1	IFN α , IFN β , IFN γ , IL-2, IL-4, IL-6, IL-7, IL-9, IL-10, IL-11, IL-13, IL-15, IL-19, IL-21, IL-22, IL-27, IL-28, IL-29, IL-31, IL-35, Ciliary neurotrophic factor (CNTF), Oncostatin-M (OSM), Cardiotrophin (CT-1)
JAK2	IFN γ , IL-3, IL-5, IL-6, IL-10, IL-11, IL-13, IL-12, IL-19, IL-22, IL-23, IL-27, IL-35, granulocyte-macrophage colony stimulating factor (GM-CSF), erythropoietin (EPO), thyroid peroxidase (TPO), leptin, myeloproliferative leukemia (MPL) viral oncogene, prolactin, growth hormone (GH)
JAK3	IL-2, IL-4, IL-7, IL-9, IL-13, IL-15, IL-21
TYK2	IFN α , IFN β , IL-10, IL-11, IL-12, IL-19, IL-22, IL-23, IL-27, IL-28, IL-29

Figure 7 Major cytokines and growth factors affected by various JAK subtypes (43)

5.7.2. Characteristics

Janus Kinase inhibitors are small molecules that are well absorbed in the intestines and permeate the skin effectively. Since they are drugs that do not need to be metabolized to achieve their effect, their fast absorption together with their brief plasma peaks and short elimination half-lives, results in a quick clinical response (43).

They can be categorized into first and second generations. The first generation includes, for instance, tofacitinib or baricitinib, which are considered non-selective. In contrast, the second generation including upadacitinib, abrocitinib or ritlecitinib, is more selective for specific subtypes of JAK (Figure 8). Furthermore, JAKi vary in their inhibition and binding sites. Some JAKi inhibit the receptor reversibly, while others inhibit covalently (45).

Drug	Inhibitory concentration (IC ₅₀)	Metabolism	Plasma half-life
Tofacitinib	JAK1: 2.9 nM	Hepatic CYP3A4 > CYP2C19	6 to 8h
	JAK2: 1.2 nM		
	JAK3: 1.1 nM		
	TYK2: 42 nM		
Baricitinib	JAK1: 4.0 nM	Hepatic CYP3A4	10 to 13h
	JAK2: 6.6 nM		
	JAK3: 787 nM		
	TYK2: 61 nM		
Ruxolitinib	JAK1: 6.4 nM	Hepatic CYP3A4	3 to 4h
	JAK2: 8.8 nM		
	JAK3: 487.0 nM		
	TYK2: 30.0 nM		
Ritlecitinib	JAK1: 1.638 nM	Hepatic: CYP450; Serum: glutathione-S-transferase	2 to 3h
	JAK2: 1.507 nM		
	JAK3: 0.3 nM		
	TYK2: 3.779 nM		
Abrocitinib	JAK1: 29 nM	Hepatic CYP2C19 > CYP2C9 > CYP3A4 > CYP2D6	3 to 5h
	JAK2: 803 nM		
	JAK3: > 10.000 nM		
	TYK2: 1.259 nM		

Figure 8 Pharmacological characteristics of the main JAKi (43)

5.7.3. Side effects

Overall, the safety profile of JAKi in adults, as well as children, is good. The most common side effects include headache, nasopharyngitis, and nausea. (43)

A study involving patients with the age of 50 years and older suffering from rheumatoid arthritis, with at least one cardiovascular risk factor, has revealed that side effects in these patients are more common in comparison to TNF inhibitors (46). Consequently, the EMA recommended in 2023 to use JAKi in the following groups of patients only when no other therapies are possible: patients older than 65 years, patients with major cardiovascular problems, smokers or patients who have smoked for an extended time, patients with increased risk for cancer, and patients with an increased risk for venous thromboembolism (47).

5.7.4. Laboratory parameters

During the treatment with JAKi, several laboratory parameters should be assessed regularly to prevent and manage potential adverse effects. Firstly, a complete blood count is important, since JAKi can induce cytopenias, especially in patients above the age of 65 years. In the case of neutropenia, lymphopenia, anemia or thrombocytopenia, the treatment with JAKi should be stopped (43). Furthermore, the lipid profile, including total cholesterol, HDL, LDL and triglyceride levels should be checked, as the treatment with JAKi can increase serum lipid levels (48). If necessary, antilipidemic drugs should be considered (43). Additionally, creatinine phosphokinase (CPK) levels could be elevated, although it is normally not associated with myopathy. The patients should be checked for symptoms of rhabdomyolysis, such as myalgia, cramps and dark urine (48). Liver function should also be checked regularly, since JAKi can induce elevated transaminase levels.

5.7.5. Contraindications

JAKi have several contraindications that need careful consideration before their prescription. The main contraindication is the difficulty in diagnosing inflammatory diseases. Diseases like alopecia, atopic dermatitis or psoriasis can mimic serious diseases with cutaneous manifestations, such as cutaneous T-cell lymphoma, or infections such as syphilis, tuberculosis or Crohn's disease. In these conditions, JAKi can lead to serious consequences. Other contraindications include altered kidney function, hypersensitivity to drug components, altered liver function, neutropenia, anemia and thrombocytopenia (43).

5.7.6. Baricitinib

Baricitinib belongs to the first generation of JAKi (44) and predominantly inhibits JAK1 and JAK2 (49). It is available in oral formulation (44) with a bioavailability of 80% and a half-life of 12 hours. Baricitinib was certified by the EMA for the treatment of AA in adults in 2022.

Two phase 3 randomized clinical trials (BRAVE-AA1 and BRAVE-AA2), including 1200 patients with severe AA (SALT>50), were performed. In these studies, one group of patients received 4 mg of baricitinib, the second group received 2 mg and the third group received placebo (2). They have shown that the optimal dose of baricitinib is 4 mg daily, with 38,8% of the patients achieving SALT20 after 36 weeks of treatment (46). The regrowth of hair on the scalp, as well as eyebrows and eyelashes, increased during the treatment with baricitinib until week 52 in both trials (50).

The continuation of those two studies until week 104 was carried out to show the long-term efficacy and safety of baricitinib. Patients treated with baricitinib 4 mg showed a maintenance efficacy of 90,7% and patients treated with baricitinib 2 mg 89,2% respectively. The percentage of patients with SALT ≤10 also increased until week 104. Moreover, the regrowth of eyebrows and eyelashes rose from 70% in week 52 to 80% in week 104 with baricitinib 4 mg (50). To conclude, the long-term treatment of patients with severe AA with baricitinib is necessary to observe its maximum effect (50).

For patients at the age of ≥75 years, or patients with chronic or recurrent infections, a daily dose of 2 mg can be considered as optimal. Furthermore, 2 mg can be used as maintenance dose for patients who have achieved a control of the disease with 4 mg baricitinib (46).

Besides for the treatment of AA, baricitinib is also approved for the treatment of moderate to severe atopic dermatitis, rheumatoid arthritis, and COVID-19 infections in adults who need supplemental oxygen, non-invasive and invasive mechanical ventilation or extracorporeal membrane oxygenation (49). Common side effects of baricitinib include headache, upper respiratory tract infections, and urinary tract infections (51).

5.7.7. Ritlecitinib

Ritlecitinib belongs to the second generation JAKi and it selectively inhibits JAK3 and the tyrosine kinase expressed in hepatocellular carcinoma (TEC). It is approved by the FDA and EMA for the treatment of severe AA in patients older than 12 years and is administered orally in a dose of 50 mg daily (46).

A randomized, placebo-controlled, double-blind and multicenter phase 2b/3 trial assessed the efficacy and safety of ritlecitinib. The study was conducted on 677 patients of ages older than 12 years with at least SALT50 and an active episode of AA lasting from six months to ten years.

The patients were randomly grouped into 5 groups (Table 1):

Table 1 Results according to different dosages of ritlecitinib (52)

Group	Ritlecitinib daily dose	SALT ≤20 at week 24
1	50 mg	23,4%
2	30 mg	14,3%
3	10 mg	1,7%
4	50 mg with 200 mg loading dose previously	30,6%
5	30 mg with 200 mg loading dose previously	22,3%
6	Placebo	1,5%

At week 24, 23,4% of group 1 patients reached SALT≤20, 14,3% of group 2, 1,7% of group 3, 30,6% of group 4, 22,3% of group 5 and 1,5% of group 6 (52). Every group receiving ritlecitinib showed a significantly higher response in comparison to the placebo group (2). The results therefore show that ritlecitinib is effective in the treatment of AA.

The most frequent adverse effects of ritlecitinib include upper respiratory tract infections, nasopharyngitis, headache, acne and diarrhea. Besides that, in 2% of patients rare adverse events like herpes zoster infection, pulmonary embolism and breast cancer were reported (53).

5.8. Management

The treatment of AA should be adjusted to the severity of the disease. For mild AA with a single patch, intralesional corticosteroids or topical corticosteroids are the treatment of choice. Intralesional injections are preferred over topical administration due to their higher effectiveness. In case of multiple patches, the first line therapy is the same as for single lesions, but topical immunotherapy can also be advised. Additionally, minoxidil can serve as adjuvant therapy. If there are multiple patches and AA is moderate or severe, or if there is unresponsiveness to the local treatments, systemic therapies are reasonable. As systemic treatment, JAKi or immunosuppressants as cyclosporine or methotrexate can be used. Latter

can be used alone or in combination with systemic corticosteroids and are more effective in preventing relapses (6).

6. Prognosis

AA is a chronic disease, which has an unpredictable course. During the first year, the chance for a spontaneous remission of single lesions approximately accounts 70%. There are various potential prognostic factors which indicate a poor outcome. First, an early onset, particularly in children under the age of six indicates a poor prognosis. In adults, the most crucial prognostic factor is the severity of AA at the onset (7). The duration of the active disease also plays an important role. If AA persists longer than 5 years, the chance of hair regrowth is 2% and after 10 years AA is considered irreversible. The involvement of eyelashes, eyebrows and non-scalp hair is indicative for a severe course of the disease (54) and nail pitting, as well as trachonychia are even associated with a higher risk of developing AA totalis or AA universalis. A history of atopic diseases like atopic dermatitis, allergic conjunctivitis, allergic rhinitis and asthma are also negative prognostic factors (17). Individuals with trisomy 21 have a higher prevalence of 9% for the development of AA, and the risk of developing AA totalis or AA universalis is estimated with 40% (7).

CONCLUSION

AA is an autoimmune disorder which is characterized by non-scarring hair loss. The hair loss can range from small single lesions to complete loss of scalp hair or even total body hair. The pathogenesis of AA is not fully understood yet, but various factors including genetics, the immune system, oxidative stress, allergies and the skin and gut microbiome seem to be involved. Furthermore, AA can have significant psychological impacts on the patient due to its visible symptoms and unpredictable course.

The treatment of AA is challenging and the type of treatment depends on the severity of the disease. Mild cases can be treated with topical therapies as intralesional corticosteroid injections, whereas more severe cases often need systemic therapy. In these cases, immunosuppressants as methotrexate or cyclosporine, biologicals or JAKi can be used. All these drugs promote hair regrowth even though their efficacy varies.

JAKi represent a new class of drugs for the treatment of AA. They act on the JAK-STAT pathway involved in the immune response. Two representatives of JAKi are baricitinib and ritlecitinib, which are both approved by the EMA and have shown a very good efficacy in clinical trials. However, future studies are required to evaluate their long-term efficacy and safety.

The prognosis of AA is unpredictable and various factors as age at onset, disease severity at onset, duration of the disease and the presence of comorbidities affect the prognosis.

SUMMARY

AA is an autoimmune disorder characterized by non-scarring hair loss. Its pathogenesis is not clear, but may include various factors like a genetic predisposition, immune system dysfunction, oxidative stress, allergies and the skin and gut microbiome. AA can affect individuals of all ages and has its peak incidence in the second and third decades of life.

Clinically, it presents with patchy hair loss which can advance to total scalp hair loss (AA totalis) or complete loss of body hair (AA universalis). Nail involvement is also commonly associated. The course of the disease is unpredictable, and early disease onset and severe initial presentation are negative prognostic factors.

The diagnosis is mainly clinical and based on the pattern of hair loss. Additionally, trichoscopy or in some cases a scalp biopsy can be performed.

The treatment is adjusted to the severity of AA. Mild and unifocal cases can be treated with topical therapies, preferably with intralesional corticosteroids. In more severe cases, systemic therapies are indicated, including immunosuppressants such as methotrexate or cyclosporine. Recently, JAKi like baricitinib and ritlecitinib have emerged as promising new treatments for severe cases of AA.

To conclude, AA is challenging due to its unpredictable course and the potential psychological impact on the patients. The emerging therapies offer new hope for patients with severe AA to achieve hair regrowth and improvement of the quality of life.

Key-words: Alopecia areata, autoimmune disease, JAK inhibitors

LIST OF REFERENCES

1. Zhou C, Li X, Wang C, Zhang J. Alopecia Areata: an Update on Etiopathogenesis, Diagnosis, and Management. *Clinic Rev Allerg Immunol*. 2021;61(3):403–23.
2. Gupta AK, Wang T, Polla Ravi S, Bamimore MA, Piguet V, Tosti A. Systematic review of newer agents for the management of alopecia areata in adults: Janus kinase inhibitors, biologics and phosphodiesterase-4 inhibitors. *J Eur Acad Dermatol Venereol*. 2023;37(4):666–79.
3. Sterkens A, Lambert J, Bervoets A. Alopecia areata: a review on diagnosis, immunological etiopathogenesis and treatment options. *Clin Exp Med*. 2021;21(2):215–30.
4. Hunt N, McHale S. The psychological impact of alopecia. *BMJ*. 2005;331(7522):951–3.
5. King BA, Senna MM, Ohyama M, Tosti A, Sinclair RD, Ball S, et al. Defining Severity in Alopecia Areata: Current Perspectives and a Multidimensional Framework. *Dermatol Ther (Heidelb)*. 2022;12(4):825–34.
6. Dhurat R, Sharma R. A Practical Approach to the Treatment of Alopecia Areata. *Indian Dermatol Online J*. 2022;13(6):725–8.
7. Fatani MIA, Alkhalifah A, Alruwaili AFS, Alharbi AHS, Alharithy R, Khardaly AM, et al. Diagnosis and Management of Alopecia Areata: A Saudi Expert Consensus Statement (2023). *Dermatol Ther (Heidelb)*. 2023;13(10):2129–51.
8. Sibbald C. Alopecia Areata: An Updated Review for 2023. *J Cutan Med Surg*. 2023;27(3):241–59.
9. Olayinka J (Jadé) T, Richmond JM. Immunopathogenesis of alopecia areata. *Curr Res Immunol*. 2021;2:7–11.
10. Alhanshali L, Buontempo MG, Lo Sicco KI, Shapiro J. Alopecia Areata: Burden of Disease, Approach to Treatment, and Current Unmet Needs. *Clin Cosmet Investig Dermatol*. 2023; 16: 803–20.
11. Gilhar A, Etzioni A, Paus R. Alopecia Areata. *N Engl J Med*. 2012;366(16):1515–25.
12. Bertolini M, McElwee K, Gilhar A, Bulfone-Paus S, Paus R. Hair follicle immune privilege and its collapse in alopecia areata. *Exp Dermatol*. 2020(8):703–25.
13. Joyce JA, Fearon DT. T cell exclusion, immune privilege, and the tumor microenvironment. *Science*. 2015;348(6230):74–80.
14. Skogberg G, Jackson S, Åstrand A. Mechanisms of tolerance and potential therapeutic interventions in Alopecia Areata. *Pharmacol Ther*. 2017;179:102–10.
15. Moreno-Arrones OM, Serrano-Villar S, Perez-Brocal V, Saceda-Corralo D, Morales-Raya C, Rodrigues-Barata R, et al. Analysis of the gut microbiota in alopecia areata:

identification of bacterial biomarkers. *J Eur Acad Dermatol Venereol.* 2020;34(2):400–5.

16. Darwin E, Hirt P, Fertig R, Doliner B, Delcanto G, Jimenez J. Alopecia areata: Review of epidemiology, clinical features, pathogenesis, and new treatment options. *Int J Trichol.* 2018;10(2):51.

17. Olsen EA, Roberts J, Sperling L, Tosti A, Shapiro J, McMichael A, et al. Objective outcome measures: Collecting meaningful data on alopecia areata. *J Am Acad Dermatol.* 2018;79(3):470-8.e3.

18. Spano F, Donovan JC. Alopecia areata: Part 1: pathogenesis, diagnosis, and prognosis. *Can Fam Physician.* 2015;61(9):751–5.

19. Roest Y, Middendorp H, Evers A, Kerkhof P, Pasch M. Nail Involvement in Alopecia Areata: A Questionnaire-based Survey on Clinical Signs, Impact on Quality of Life and Review of the Literature. *Acta Derm Venerol.* 2018;98(2):212–7.

20. Gómez-Quispe H, Muñoz Moreno-Arrones O, Hermosa-Gelbard Á, Vañó-Galván S, Saceda-Corralo D. Tricoscopia en la alopecia areata. *Actas Dermosifiliogr.* 2023;114(1):25–32.

21. Waśkiel A, Rakowska A, Sikora M, Olszewska M, Rudnicka L. Trichoscopy of alopecia areata: An update. *J Dermatol.* 2018;45(6):692–700.

22. Rudnicka L, Olszewska M, Rakowska A, Czuwara J. Alopecia Areata. In: Rudnicka L, Olszewska M, Rakowska A, editors. *Atlas of Trichoscopy* [Internet]. London: Springer London; 2012 [cited 2024 Feb 21]. p. 205–20. Available from: https://link.springer.com/10.1007/978-1-4471-4486-1_16

23. El-Bakry O, El-Sherif R, Seleit I. Dermoscopy in hair disorders. *Menoufia Med J.* 2014;27(4):762.

24. Amer M, Helmy A, Amer A. Trichoscopy as a useful method to differentiate tinea capitis from alopecia areata in children at Zagazig University Hospitals. *Int J Dermatol.* 2017;56(1):116–20.

25. Pirmez R, Tosti A. Trichoscopy Tips. *Dermatol Clin.* 2018;36(4):413–20.

26. Miteva M, Tosti A. Hair and scalp dermatoscopy. *J Am Acad Dermatol.* 2012;67(5):1040–8.

27. Waśkiel-Burnat A, Rakowska A, Sikora M, Olszewska M, Rudnicka L. Alopecia areata predictive score: A new trichoscopy-based tool to predict treatment outcome in patients with patchy alopecia areata. *J Cosmet Dermatol.* 2020;19(3):746–51.

28. Pirmez R. Revisiting Coudability Hairs in Alopecia Areata: The Story behind the Name. *Skin Appendage Disord.* 2016;2(1–2):76–8.

29. Kibar M, Aktan Ş, Lebe B, Bilgin M. Trichoscopic findings in alopecia areata and their relation to disease activity, severity and clinical subtype in Turkish patients. *Aust J*

Dermatol. 2015;56(1):e1-6.

30. Jha AK, Udayan UK, Roy PK, Amar AKJ, Chaudhary RKP. Dermoscopy of alopecia areata—a retrospective analysis. *Dermatol Pract Concept*. 2017;53–7.

31. Ocampo-Garza J, Tosti A. Trichoscopy of Dark Scalp. *Skin Appendage Disord*. 2019;5(1):1–8.

32. Lobato-Berezo A, Olmos-Alpiste F, Pujol RM, Saceda-Corralo D. Pohl-Pinkus Constrictions in Trichoscopy. What Do They Mean? *Actas Dermosifiliogr (Engl Ed)*. 2019;110(4):315–6.

33. Yoon TY, Lee DY, Kim YJ, Lee JY, Kim MK. Diagnostic Usefulness of a Peribulbar Eosinophilic Infiltrate in Alopecia Areata. *JAMA Dermatol*. 2014;150(9):952.

34. Rossi A, Muscianese M, Piraccini BM, Starace M, Carlesimo M, Mandel VD, et al. Italian Guidelines in diagnosis and treatment of alopecia areata. *G Ital Dermatol Venereol*. 2019;154(6):609-23.

35. Chu TW, AlJasser M, Alharbi A, Abahusseini O, McElwee K, Shapiro J. Benefit of different concentrations of intralesional triamcinolone acetonide in alopecia areata: An intrasubject pilot study. *J Am Acad Dermatol*. 2015;73(2):338–40.

36. Lepe K, Syed HA, Zito PM. Alopecia Areata. In: StatPearls [Internet]. Treasure Island (FL): StatPearls Publishing; 2024 [cited 2024 Feb 25]. Available from: <http://www.ncbi.nlm.nih.gov/books/NBK537000/>

37. Strazzulla LC, Wang EHC, Avila L, Lo Sicco K, Brinster N, Christiano AM, et al. Alopecia areata. *J Am Acad Dermatol*. 2018;78(1):15–24.

38. Phan K, Ramachandran V, Sebaratnam DF. Methotrexate for alopecia areata: A systematic review and meta-analysis. *J Am Acad Dermatol*. 2019;80(1):120-127.e2.

39. Nowaczyk J, Makowska K, Rakowska A, Sikora M, Rudnicka L. Cyclosporine With and Without Systemic Corticosteroids in Treatment of Alopecia Areata: A Systematic Review. *Dermatol Ther (Heidelb)*. 2020;10(3):387–99.

40. Guttman-Yassky E, Renert-Yuval Y, Bares J, Chima M, Hawkes JE, Gilleaudeau P, et al. Phase 2a randomized clinical trial of dupilumab (anti-IL-4R α) for alopecia areata patients. *Allergy*. 2022;77(3):897–906.

41. Ramos PM, Anzai A, Duque-Estrada B, Melo DF, Sternberg F, Santos LDN, et al. Consensus on the treatment of alopecia areata – Brazilian Society of Dermatology. *An Bras Dermatol*. 2020;95:39–52.

42. Chapman S, Kwa M, Gold LS, Lim HW. Janus kinase inhibitors in dermatology: Part I. A comprehensive review. *J Am Acad Dermatol*. 2022;86(2):406–13.

43. Miot HA, Criado PR, De Castro CCS, Ianhez M, Talhari C, Ramos PM. JAK-STAT pathway inhibitors in dermatology. *An Bras Dermatol*. 2023;98(5):656–77.

44. Haughton RD, Herbert SM, Ji-Xu A, Downing L, Raychaudhuri SP, Maverakis E. Janus kinase inhibitors for alopecia areata: A narrative review. *Indian J Dermatol Venereol Leprol.* 2023;89:799–806.
45. Shawky AM, Almalki FA, Abdalla AN, Abdelazeem AH, Gouda AM. A Comprehensive Overview of Globally Approved JAK Inhibitors. *Pharmaceutics.* 2022;14(5):1001.
46. Rudnicka L, Arenbergerova M, Grimalt R, Ioannides D, Katoulis AC, Lazaridou E, et al. European expert consensus statement on the systemic treatment of alopecia areata. *J Eur Acad Dermatol Venereol.* 2024;38(4):687–94.
47. Chen Y, Zhu H, Shen Y, Zhu Y, Sun J, Dai Y, et al. Efficacy and safety of JAK inhibitors in the treatment of alopecia areata in children: a systematic review and meta-analysis. *J Dermatol Treat.* 2022;33(8):3143–9.
48. Saeki H, Akiyama M, Abe M, Igarashi A, Imafuku S, Ohya Y, et al. English version of Japanese guidance for the use of oral Janus kinase (JAK) inhibitors in the treatments of atopic dermatitis. *J Dermatol.* 2023;50(1):e1-e19.
49. Freitas E, Guttman-Yassky E, Torres T. Baricitinib for the Treatment of Alopecia Areata. *Drugs.* 2023;83(9):761–70.
50. Senna M, Mostaghimi A, Ohyama M, Sinclair R, Dutronc Y, Wu WS, et al. LONG-TERM efficacy and safety of baricitinib in patients with severe alopecia areata: 104-WEEK results from BRAVE-AA1 and BRAVE-AA2. *J Eur Acad Dermatol Venereol.* 2024;38(3):583–93.
51. Faria S, Freitas E, Torres T. Efficacy and safety of baricitinib in patients with alopecia areata: evidence to date. *Drugs Context.* 2023;12:2023-6–2.
52. King B, Zhang X, Harcha WG, Szepietowski JC, Shapiro J, Lynde C, et al. Efficacy and safety of ritlecitinib in adults and adolescents with alopecia areata: a randomised, double-blind, multicentre, phase 2b–3 trial. *The Lancet.* 2023;401(10387):1518–29.
53. Sardana K, Bathula S, Khurana A. Which is the ideal JAK inhibitor for alopecia areata – Baricitinib, tofacitinib, ritlecitinib or ifidancitinib - Revisiting the immunomechanisms of the JAK pathway. *Indian Dermatol Online J.* 2023;14(4):465.
54. Meah N, Wall D, York K, Bhojrul B, Bokhari L, Asz-Sigall D, et al. The Alopecia Areata Consensus of Experts (ACE) study part II: Results of an international expert opinion on diagnosis and laboratory evaluation for alopecia areata. *J Am Acad Dermatol.* 2021;84(6):1594–601.

CURRICULUM VITAE

Hanna Theresa Sterk was born on August 28th, 1998 in Ravensburg, Germany. From 2005 to 2009 she attended the elementary school in Waltenhofen and moved in 2009 to the Gymnasium Isny, from which she graduated with her high school diploma in 2017.

In August 2017 she started a voluntary social year in the organization Deutsches Rotes Kreuz, Rettungsdienst Bodensee-Oberschwaben gGmbH, within which she did the education as a paramedic. After completion of the voluntary social year, she continued working for the company as a paramedic, until she started studying at the University of Rijeka, Croatia, in October 2018. Since October 2018, Hanna Theresa Sterk has been studying human medicine at the Faculty of Medicine in Rijeka. In addition to her regular student obligations, she worked as a paramedic during the semester breaks and absolved professional practices in several subjects, such as Internal Medicine and Dermatology in German hospitals.

Hanna Theresa Sterk will receive her diploma in July 2024.