

Brain Abscess

Tunc, Tayma Ahmet

Master's thesis / Diplomski rad

2024

Degree Grantor / Ustanova koja je dodijelila akademski / stručni stupanj: **University of Rijeka, Faculty of Medicine / Sveučilište u Rijeci, Medicinski fakultet**

Permanent link / Trajna poveznica: <https://um.nsk.hr/um:nbn:hr:184:434381>

Rights / Prava: [In copyright](#)/[Zaštićeno autorskim pravom.](#)

Download date / Datum preuzimanja: **2024-11-23**



Repository / Repozitorij:

[Repository of the University of Rijeka, Faculty of Medicine - FMRI Repository](#)



UNIVERSITY OF RIJEKA
FACULTY OF MEDICINE

UNIVERSITY INTEGRATED UNDERGRADUATE AND GRADUATE STUDY OF
MEDICINE IN ENGLISH LANGUAGE

Tayma Ahmet Tunç

BRAIN ABSCESS

GRADUATION THESIS

Rijeka, 2024

UNIVERSITY OF RIJEKA
FACULTY OF MEDICINE

UNIVERSITY INTEGRATED UNDERGRADUATE AND GRADUATE STUDY OF
MEDICINE IN ENGLISH LANGUAGE

Tayma Ahmet Tunç

BRAIN ABSCESS

GRADUATION THESIS

Rijeka, 2024

Thesis mentor: Assoc. prof. Đurđica Cekinović Grbeša, MD, PhD

The thesis was graded on 18.06.2024 graduation 2024, before the Committee composed of the following members:

1. Prof. Ivica Pavić, MD, PhD (Committee Head)

2. Assoc. prof. Irena Slavuljica, MD, PhD

3. Prof Marina Bubonja Šonje, MD, PhD

The graduation thesis contains 34 pages, 3 figures, 0 tables, 31 references.

I want to thank my parents, brothers, my Anne Anne and my cats for their never-ending support and love.

Sizi Seviyorum

Furthermore, I want to thank all the friends I made on the way here.

And finally thank you Sarah.

Table of contents

<u>LIST OF ABBREVIATIONS</u>	<u>6</u>
<u>INTRODUCTION.....</u>	<u>7</u>
<u>AIMS AND OBJECTIVES</u>	<u>8</u>
HISTORY	9
ETIOLOGY AND GENESIS.....	10
MOST FREQUENTLY ISOLATED PATHOGENS	11
PATHOGENESIS.....	11
CLINICAL FEATURES	13
DIAGNOSTICS.....	15
TREATMENT.....	17
MEDICAL MANAGEMENT:	17
SURGICAL MANAGEMENT:	18
COMPLICATIONS OF THE DISEASE	19
PROGNOSIS	21
OUTCOMES AND COMPLICATIONS:	21
<u>CASE REPORT</u>	<u>23</u>
<u>DISCUSSION</u>	<u>26</u>
CONNECTION TO PRIOR DIAGNOSIS:	28
<u>CONCLUSION.....</u>	<u>29</u>
<u>SUMMARY</u>	<u>30</u>
<u>LITERATURE CITED</u>	<u>31</u>
<u>CV</u>	<u>34</u>

List of abbreviations

- **1H-MRS:** Proton Magnetic Resonance Spectroscopy
- **ADC:** Apparent Diffusion Coefficient
- **AVM:** Arteriovenous Malformation
- **BA:** Brain Abscess
- **CNS:** Central Nervous System
- **CRP:** C-Reactive Protein
- **CSF:** Cerebrospinal Fluid
- **CT:** Computed Tomography
- **CVID:** Common Variable Immunodeficiency
- **DAMP:** Danger-Associated Molecular Patterns
- **DWI:** Diffusion-Weighted Imaging
- **eGFR:** Estimated Glomerular Filtration Rate
- **HHT:** Hereditary Hemorrhagic Telangiectasia
- **ICP:** Intracranial Pressure
- **IL:** Interleukin
- **LP:** Lumbar Puncture
- **MRI:** Magnetic Resonance Imaging
- **MyD88:** Myeloid Differentiation Primary Response 88
- **NF- κ B:** Nuclear Factor kappa-light-chain
- **NLR:** Nod-Like Receptors
- **PAMP:** Pathogen-Associated Molecular Patterns
- **TLR:** Toll-Like Receptors
- **WBC:** White Blood Cell

Introduction

The human brain, with its intricate network of neurons and supporting systems, is both a marvel of complexity and vulnerability. Despite its robust defenses, the central nervous system can fall prey to various pathogens, occasionally resulting in the formation of a brain abscess. This encapsulated accumulation of pus within the brain parenchyma comprises pathogens, immune response components, necrotic tissue, pus, and a fibrous capsule. Brain abscesses, though relatively rare, pose significant clinical challenges due to its potential severity and the complexity of the pathogenesis (1,2).

Incidence rates of brain abscesses range from 0.4 to 0.9 cases per 100,000 people annually in developed countries. This localized infection accounts for 8% of intracranial masses (also called intracranial space-occupying lesions) and is associated with the 53% of case mortality. Brain abscess most frequently develops in middle-aged men (aged from 30 to 50 years), but certain populations are particularly vulnerable, including individuals with compromised immune systems (such as those with HIV/AIDS or undergoing chemotherapy), patients with chronic conditions like diabetes, individuals with congenital heart disease, and those who have experienced head trauma or neurosurgical procedures. (3)

Understanding the pathogenesis of brain abscess is complicated, given the intricate interactions among microbial virulence factors, human defenses, and the dynamic brain microenvironment (1).

The diverse array of etiological agents—from fungi and bacteria to parasites—underscores the need for a sophisticated approach to diagnosis and therapy of brain abscess (2).

Within the realm of scholarly research, attention is drawn to compelling case reports detailing the experiences of patients with recurring brain abscesses. By amalgamating insights from diverse sources, this approach aims to identify trends, address knowledge gaps, and outline future research directions. Ultimately, this comprehensive strategy seeks to advance understanding of both solitary brain abscesses and their recurring counterparts, fostering a more nuanced comprehension of the diagnostic and treatment paradigms in these intricate neuroinfectious diseases.

Aims and objectives

This graduation thesis aims to provide a comprehensive review of brain abscesses, covering etiology, pathophysiology, clinical presentation, diagnosis, and management. Furthermore, it seeks to explore the epidemiology, risk factors, clinical features, and management strategies related to recurrent brain abscesses, particularly emphasizing the challenges in diagnosis and treatment. In that purpose, it will present a detailed case report of a patient with recurrent brain abscesses, outlining the clinical course, diagnostic workup, treatment modalities, and clinical outcomes, and discussing the underlying predisposing conditions for the recurrence of the brain abscess. Finally, the paper aims to synthesize findings from the review of brain abscesses, and the case report offering insights into an optimal management approach and suggesting future research directions.

The objectives of this thesis are multifaceted, aiming to comprehensively address various aspects related to brain abscesses. Firstly, the review of brain abscesses intends to explore the microbiological spectrum, predisposing factors, and pathophysiological mechanisms underlying their formation, while also analyzing the clinical presentation and discussing diagnostic modalities for accurate diagnosis.

Additionally, the presentation of a detailed case report will provide insights into the clinical history, clinical presentation, radiological findings, and laboratory results of a patient diagnosed with repetitive brain abscesses. The discussion will extend to the diagnostic challenges encountered in the case. The description of treatment modalities implemented, including surgical interventions, antimicrobial therapy, and adjunctive measures, will be followed by a discussion regarding the causes for the recurrent brain abscesses.

Lastly, the discussion and conclusion will synthesize key findings from the review paper and the case report. Common themes, knowledge gaps, and clinical implications will be highlighted, along with recommendations for optimal management approaches and future research directions.

History

Brain abscess has a long history, with ancient civilizations providing early records of symptoms that may be associated with this serious medical conditions. However, due to limited medical knowledge and diagnostic tools, the understanding of brain abscess in ancient times was often rudimentary. The Middle Ages saw a gradual expansion of medical knowledge, but brain abscess was still poorly understood and frequently confused with other neurological disorders. The 16th to 18th centuries marked a period of improvement in the understanding of anatomy and diseases in general. Advancements in microscopy and the recognition of microbial infections contributed to a clearer differentiation between various intracranial lesions, including tumors and abscess. The 19th century witnessed significant progress in medicine, with the advent of diagnostic tools such as X-rays, providing a new perspective on the nature of brain abscesses (1). In a year 1893 a Scottish surgeon Sir William Macewen in his crucial work “Pyogenic infective disease of the brain and spinal cord. Meningitis, abscess of the brain, infective sinus thrombosis!” described 25 cases of brain abscesses and advised draining the abscess and treating the underlying causative sinus infections. His work is now considered as the first most comprehensive description of brain abscess (4).

The 20th century brought about revolutionary changes in the diagnosis and treatment of brain abscesses. The development of computed tomography (CT) and magnetic resonance imaging (MRI) enabled precise visualization of intracranial structures, facilitating accurate identification and localization of brain abscesses. Surgical techniques for drainage and treatment were refined, leading to improved outcomes for patients (1).

In contemporary times, ongoing advancements in neuroimaging, microbiology, and neurosurgical procedures continue to enhance our understanding and management of brain abscesses. Despite historical challenges, the cumulative progress in medical knowledge and technology has significantly improved the diagnosis and treatment of these life-threatening infections (2).

Etiology and genesis

Brain abscesses (BAs) emerge as complex intracranial entity stemming from diverse origins, each pathogenesis weaving a unique narrative of infection and neurological compromise. Arising from pericranial contiguous foci, hematogenous dissemination, or direct inoculation, the etiology of BA unveils a tapestry of infectious pathways and anatomical vulnerabilities.

Pericranial contiguous foci serve as common sources for BA genesis, with sinusitis, middle ear infections, and dental maladies accounting for a substantial proportion of cases. Specific infections, such as ethmoid or frontal sinusitis, perpetrate insidious incursions into the frontal lobe, instigating a cascade of inflammatory sequelae within the cerebral parenchyma. Conversely, hematogenous spread, facilitated by distant loci of infection like lung abscesses or endocarditis, imparts a distinct character to BA, with multifocal lesions often bearing the hallmark of middle cerebral artery distribution. In instances of cryptogenic BA, a covert cardiac source, exemplified by a patent foramen ovale (PFO), may serve as a clandestine conduit for infected emboli, circumventing pulmonary filtration to infiltrate the cerebral vasculature (2).

Direct inoculation, a less common yet also important route of BA acquisition, manifests following head trauma or neurosurgical procedures, engendering focal abscess formation in the wake of cerebral insult. Fungal incursions, characterized by their progression and vascular obstruction, engender a unique spectrum of BA pathology, culminating in thrombotic occlusion of cerebral arterial vessels and consequent infarction.

Contrasting the parenchymal milieu of conventional BA, primary intraventricular abscesses develop within the confines of the ventricular system, evolving gradually from incipient cerebritis or ventriculitis. Pathogens, gaining ingress either hematogenously or through the cerebrospinal fluid (CSF) via the relatively porous choroid plexus, evoke a cascade of inflammatory responses, leading to adhesions and obstructing the ventricular conduits. Such local confinement precipitates the genesis of solitary intraventricular abscesses, their insidious evolution punctuated by the specter of obstructive hydrocephalus and cerebral decompensation (3).

In summation, the genesis and trajectory of BA epitomize the intricate interplay between infectious agents, anatomical vulnerabilities, and systemic predispositions. By unraveling the intricacies of BA pathogenesis, clinicians can navigate the diagnostic and therapeutic

challenges posed by these enigmatic intracranial lesions, endeavoring to mitigate neurological sequelae and preserve cognitive function (1,2).

Most frequently isolated pathogens

Brain abscess is caused by a diverse array of bacterial and fungal pathogens, each contributing to the condition's complexity. *Streptococcus* species, particularly the *Streptococcus milleri* group, are the most common, accounting for approximately 40-50% of cases. These organisms are frequently associated with abscesses originating from dental, sinus, or oropharyngeal infections. *Staphylococcus aureus* (especially methicillin resistant *S.aureus* MRSA), is responsible for about 10-15% of brain abscesses, especially in post-surgical or trauma-related instances. Anaerobic bacteria, such as *Bacteroides* species, contribute to 20-25% of cases, often linked to chronic otitis media or dental infections. Gram-negative organisms, like *Escherichia coli* and *Klebsiella* species, constitute around 10-15%, typically associated with gastrointestinal or urinary tract infections (3).

Fungal pathogens, while less common, are particularly significant for BA in immunocompromised patients. *Aspergillus* species, for instance, are responsible for about 5-10% of brain abscesses in this population, posing considerable treatment challenges due to their invasive nature and resistance to standard antifungal therapies. *Candida* species, contributing to approximately 5% of cases, are notable in patients with prolonged neutropenia or those with indwelling medical devices (2,5).

Understanding the distribution and prevalence of these pathogens is crucial for effective diagnosis and treatment. A broad-spectrum empirical antimicrobial therapy is often initiated and then refined based on culture and sensitivity results to address the specific causative agents involved. This approach ensures comprehensive coverage and improves patient outcomes by targeting the diverse pathogens responsible for BA.

Pathogenesis

Brain abscesses arise from parenchymal infections caused by pyogenic bacteria, initially manifesting as a localized cerebritis that progresses into a suppurative lesion encased within a well-vascularized fibrotic capsule. While Streptococcal strains and *S. aureus* are primary

culprits, numerous other pathogens have also been implicated, showcasing the diverse array of organisms capable of instigating this condition.

At the histological level, the evolution of a BA unfolds through a series of distinct pathological phases. The initial stage, termed early cerebritis, spans days 1–3 and is characterized by the accumulation of neutrophils, tissue necrosis, and edema. Concurrently, there is activation of microglial cells and astrocytes, persisting throughout the abscess development. Following this, the intermediate phase, or late cerebritis, transpires from days 4–9 and is marked by a predominant infiltrate of macrophages and lymphocytes. Lastly, the final stage, known as the capsule stage, commences from day 10 onward and is distinguished by the formation of a well-vascularized abscess wall, effectively isolating the lesion and safeguarding the adjacent normal brain parenchyma from further harm.

Remarkably, alongside its role in containing the infection, the immune response integral to abscess formation also leads to the destruction of surrounding normal brain tissue, reflecting the intricate balance between host defense mechanisms and collateral damage within the brain microenvironment (3).

Activation of the innate immune system within the central nervous system (CNS) is a complex process involving various pathways triggered by the recognition of invading pathogens or tissue damage. Recent research has highlighted a two-signal model of pathogen recognition, primarily mediated by Toll-like receptors (TLRs) and Nod-like receptors (NLRs).

TLRs play a crucial role in sensing invading pathogens by recognizing conserved pathogen-associated molecular patterns (PAMPs) from a diverse range of organisms. Additionally, they can recognize endogenous molecules known as danger-associated molecular patterns (DAMPs), which are released during tissue pathology. TLR2, in particular, has been implicated in regulating bacterial burdens and inflammatory responses during BA development. TLR signaling typically involves the adaptor protein MyD88, leading to the activation of the transcription factor NF- κ B and subsequent production of proinflammatory molecules (6).

On the other hand, NLRs form inflammasomes, which are responsible for processing pro-interleukin-1 β (pro-IL-1 β) and pro-IL-18 into their active forms. IL-1 β and IL-18 play significant roles in the pathophysiology of various neurodegenerative disorders and CNS infections. MyD88-dependent pathways, coupled with the actions of IL-1 and IL-18, represent central points in the innate inflammatory pathway and are crucial for antibacterial immunity.

In the CNS, resident innate immunity primarily relies on the functions of glial cells, including astrocytes and microglia, for the early control of pathogen replication and the recruitment of

adaptive immune cells. Microglia, considered as CNS-resident professional macrophages, are key innate immune effectors that express various pro-inflammatory genes upon activation.

These cells express mRNA for TLR 1-9 which bind both PAMPs and DAMPs, leading to production of proinflammatory cytokines such as IL-6, IL-10, IL-12, and TNF- α . Microglia successfully interact with astrocytes, the most abundant glial cells in the CNS, which also become activated in response to bacterial pathogens, recognizing PAMPs mainly through TLRs 2, 3 and 4 and producing inflammatory cytokines IL-6, IL-8, and TNF- α during neuroinflammation (6,7).

Astrocytes undergo functional alterations in response to pathogen burden, including reductions in gap junction communication. These changes in astrocyte properties are particularly pronounced near the primary inflammatory site in BA, affecting astrocyte function (6).

Given the limited immune surveillance in the CNS and the inability for robust regeneration, tight regulation of the immune response is essential to effectively eradicate bacteria while minimizing damage to surrounding brain tissue. However, excessive immune engagement, visible in BAs can lead to irreversible functional impairment, highlighting the delicate balance required for immune regulation in CNS infections (2).

After an initial infection, the aftermath of BA can result in various outcomes, such as the replacement of the affected area with a fibrotic scar, surgical removal of damaged brain tissue, or the grave consequence of abscess rupture leading to potential fatality. If left undetected or untreated, an abscess can rupture into the ventricular space, presenting a dire scenario with an alarming 80% mortality rate. Notably, the origins of BA commonly stem from direct or indirect cranial infections originating from sites like the paranasal sinuses, middle ear, and dental structures. Additionally, alternative pathways for abscess development include the dissemination of infection from distant sites in the body, such as endocarditis, or through traumatic injury penetrating the skull. After the resolution of a brain abscess, patients may endure enduring complications, including seizures, cognitive decline, and specific neurological impairments contingent on the location of the lesion (5).

Clinical features

In the clinical landscape of brain abscess, a myriad of symptoms and signs herald the intricate interplay between intracranial pathology and neurological compromise, each bearing the

indelible imprint of its unique etiological substrate and anatomical localization. The dynamic spectrum of clinical presentations, ranging from the insidious onset of indolent symptoms to the fulminant progression of neurological sequelae, underscores the formidable diagnostic challenges and therapeutic imperatives inherent to this intracranial pathology.

Symptomatology, often dictated by the size and spatial orientation of any space-occupying lesion in the CNS, manifests as a constellation of neurological deficits and systemic manifestations reflective of intracranial pressure dynamics and cerebral dysfunction. The classical triad of fever, headache (typically severe and ipsilateral to the abscess), and focal neurological deficits, though emblematic of abscess pathology, manifests in less than half of affected individuals with the BA, underscoring the heterogeneous nature of its clinical presentations (7).

Headache, a ubiquitous symptom, afflicts approximately 70% of patients, serving as a harbinger of intracranial pathology and neurovascular compromise. Mental status changes, reflective of cerebral edema and neuronal dysfunction, emerge as a hallmark of BA pathology, affecting approximately 65% of individuals and heralding the insidious progression of neurological compromise (2,3).

Focal neurological deficits, encompassing a spectrum of motor, sensory, and cognitive impairments, each afflict a similar proportion of patients, underscoring the propensity for intracranial lesions to disrupt regional cerebral function and neuronal circuitry (8).

Seizures, a distressing neurological sequela, afflict 25-35% of individuals, underscoring the epileptogenic potential of BA pathology and the propensity for intracranial lesions to incite neuronal hyperexcitability and paroxysmal electrical activity (8).

Nausea and vomiting, reflective of intracranial pressure dynamics and cerebral dysfunction, afflict 40% of patients, heralding the systemic manifestations of intracranial pathology (2,8,9).

Nuchal rigidity and papilledema, though less common, serve as ominous indicators of impending neurological decompensation and intracranial hypertension, necessitating urgent medical intervention to mitigate morbidity and mortality. The sudden exacerbation of headache, often accompanied by emerging signs of meningismus, heralds the catastrophic rupture of the abscess, underscoring the imperative for heightened vigilance and expeditious therapeutic intervention in vulnerable patient cohorts (8).

Fever, though variably present in 50% of cases, underscores the systemic inflammatory response to intracranial infection, serving as a surrogate marker of infectious burden and immune activation (8).

In summation, the clinical manifestations of brain abscess pathology epitomize the intricate interplay between intracranial infection, neurological compromise, and systemic sequelae. By unraveling the complexities of symptomatology, clinicians can navigate the diagnostic and therapeutic challenges posed by this formidable intracranial entity, striving to mitigate morbidity and mortality while preserving neurological function and quality of life.

Diagnostics

Neuroimaging plays a pivotal role in the diagnosis and management of brain abscess. Advanced neuroimaging modalities, including high-resolution computed tomography (CT) and magnetic resonance imaging (MRI), furnish invaluable insights into the precise localization, dimensions, and structural characteristics of the abscess, facilitating targeted therapeutic interventions. From the identification of small, deep-seated lesions amenable to conservative management to the delineation of larger, multifocal abscesses necessitating surgical excision or aspiration, neuroimaging serves as the linchpin of diagnostic and therapeutic decision-making (3).

Typically, a CT scan with contrast is utilized, offering detailed insights into the nature and extent of the lesion. The hallmark finding on CT is a hypodense lesion with a contrast-enhancing ring, aiding in early detection, precise localization, and characterization of the abscess. Additionally, CT imaging assists in identifying associated complications such as hydrocephalus, raised intracranial pressure (ICP), and surrounding infections like subdural empyema and ventriculitis, guiding treatment decisions and monitoring response to therapy.

However, it's noteworthy that corticosteroids can influence the enhancement of the abscess wall on CT scans. In the initial phases, non-contrast CT may reveal low-attenuation abnormalities, while later stages may exhibit a complete peripheral ring enhancement. Magnetic resonance imaging (MRI) features are also instrumental in identifying pyogenic abscesses, with central liquefaction areas displaying high signals and surrounding edematous brain tissue showing low signals on T1-weighted images. The maturity of the abscess can be gauged by the rim formation, which is indicative of collagen deposition and inflammation. MRI findings vary depending on the stage of infection, with early phases showing low T1-weighted signals and high T2-weighted signals, while later phases exhibit better-demarcated low T1-weighted signals and high T2-weighted signals (10).

Advanced MR technology, including diffusion-weighted imaging (DWI) and proton MR spectroscopy (1H-MRS), has revolutionized the diagnosis of BAs, enabling differentiation from necrotic neoplasms and cystic tumors. DWI, with its high sensitivity and specificity, aids in discriminating between different pathologies based on apparent diffusion coefficient (ADC) values. Furthermore, 1H-MRS provides valuable insights into the etiology of abscesses and their response to treatment, facilitating timely implementation of appropriate therapy (10, 11). Three distinct MR-spectroscopic patterns have been identified in pyogenic cerebral abscesses, each linked to different microbial compositions and clinical implications. Pattern A, characterized by lactate, cytosolic amino acids, alanine, acetate, succinate, and lipids, is associated with obligate anaerobes or a mixture of obligate and facultative anaerobes. Pattern B, which includes lactate, cytosolic amino acids, and occasionally lipids, is mainly linked to obligate aerobes and facultative anaerobes. Pattern C, marked by lactate, is particularly linked to abscesses caused by *Streptococcus* species (6,8).

Notably, abscess caused by *Staphylococcus* species exhibit distinctive peaks from lipids and lactate. This spectroscopic differentiation is crucial for early antibiotic selection. Tubercular cerebral abscesses show elevated lipids and phosphoserine. Fungal abscesses typically exhibit cytosolic amino acids, lactate, and a prominent peak for trehalose, a fungal wall component (9,12)

Spectroscopic analysis helps distinguish between early and late cerebritis and capsular formation stages, aiding microbial identification and understanding abscess progression (2,5). Imaging reveals BA locations vary by etiology: traumatic causes often lead to left-sided BAs (64.3%), “rhinogenic” to frontal (83.8%) and parietal (7.1%) regions, otogenic to temporal (47.9%) and cerebellar (45.5%) regions, and cardiac to parietal (57.7%) and frontal (34.6%) regions (2,5,7,12).

As the diagnostic in Fig.1 describes, in patients with suspected BA it is important to promptly search for predisposing conditions and order imaging studies as soon as possible. Additionally, obtaining blood cultures promptly is crucial, and regular laboratory tests should be performed to monitor the patient's condition (12). Routine blood count analysis with leukocyte values and differential blood count, coupled with erythrocyte sedimentation rate (ESR) and the levels of acute-phase reactants, such as C-reactive protein (CRP) or procalcitonin (PCT) can help us to propose the bacterial or fungal etiology of the BA in this initial stage of the management.

Despite the diagnostic advancements, it's crucial to note that lumbar puncture (LP) is contraindicated in BA cases due to the risk of increased intracranial pressure and potential neurological deterioration (13).

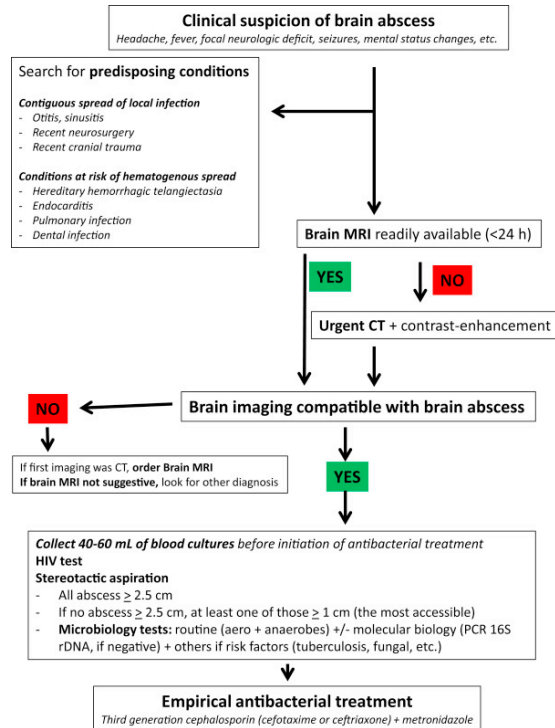


Figure 1. diagnostic algorithm in patient with suspected brain abscess (12)

Treatment

The management of brain abscess constitutes a multifaceted endeavor that intertwines advanced medical interventions with intricate surgical techniques, all orchestrated to navigate the labyrinthine landscape of neurological pathology. Characterized by the peril of heightened intracranial pressure and the specter of significant morbidity and mortality, the management of these intracranial lesions demands meticulous attention to detail and a nuanced understanding of their underlying etiologies, anatomical considerations, and therapeutic modalities.

Medical Management:

Within the realm of medical management, a judicious blend of antimicrobial therapy and adjunctive pharmacotherapy forms the cornerstone of treatment. The decision to pursue

conservative or interventional strategies hinges upon a constellation of factors, including the size, location, and multiplicity of the brain abscess, as well as the presence of concomitant neurological sequelae such as meningitis.

Antimicrobial therapy assumes paramount importance in the medical armamentarium, with the selection of antibiotics guided by the microbiological profile gleaned from blood cultures, cerebrospinal fluid analysis, or intraoperative specimens. However, the formidable barrier posed by the blood-brain barrier necessitates careful consideration of pharmacokinetic principles, as certain antibiotics may exhibit limited central nervous system penetration. Empirical regimens typically encompass broad-spectrum coverage targeting both Gram-positive and Gram-negative organisms, with adjustments made based on culture and sensitivity results (3,14).

For gram-positive bacteria, including Streptococci and Staphylococci, third generation cephalosporins (e.g., ceftriaxone, cefotaxime) or penicillin derivatives (e.g., penicillin G) represent first-line agents, with vancomycin reserved for cases of methicillin-resistant *Staphylococcus aureus* (MRSA) or penicillin allergy. Fungal infections, such as those caused by *Candida* or *Aspergillus* species, mandate aggressive antifungal therapy, often with agents like amphotericin B or voriconazole (14).

Adjunctive pharmacotherapy, including corticosteroids, plays a pivotal role in mitigating the inflammatory cascade associated with abscess formation, thereby ameliorating cerebral edema, and reducing the mass effect on surrounding neural structures. Additionally, in specific etiological contexts, such as *Toxoplasma gondii* infection in immunocompromised HIV-infected individuals, combination therapy with antiparasitic agents (e.g., pyrimethamine, sulfadiazine) and antiretroviral medications may be warranted to suppress disease progression and bolster immune function (12,15,16).

Surgical Management:

Surgical intervention constitutes a critical component of the therapeutic armamentarium, offering targeted eradication of abscesses, decompression of intracranial structures, and relief of mass effect. The selection of surgical approach is predicated upon a meticulous assessment of abscess characteristics, neuroanatomical considerations, and the skill set of the operating team.

Ultrasound- or CT-guided needle aspiration, stereotactic biopsy, burr hole evacuation, and craniotomy represent the principal surgical techniques employed in the management of brain

abscesses, each tailored to the specific needs of the individual patient. While minimally invasive procedures such as needle aspiration may suffice for select cases of superficial or accessible lesions, more extensive interventions such as craniotomy may be warranted for deep-seated or multi-focal abscesses resistant to percutaneous drainage (16).

Intracavitary irrigation with antimicrobial agents, instillation of fibrinolytic agents to facilitate abscess liquefaction, and the use of neuroimaging guidance to ensure precise localization and complete evacuation of purulent material represent key tenets of surgical technique. Additionally, the incorporation of intraoperative neurophysiological monitoring and advanced imaging modalities such as intraoperative MRI or CT aids in real-time assessment of surgical efficacy and mitigation of procedural complications (15,16).

In cases of refractory or recurrent abscess, adjunctive therapies such as hyperbaric oxygen therapy or immunomodulatory agents may be considered to augment antimicrobial efficacy and enhance host immune response. Furthermore, close postoperative surveillance, including serial neuroimaging and monitoring of inflammatory markers, facilitates early detection of treatment failure or disease recurrence, enabling prompt escalation of therapeutic interventions (2,15,16).

In conclusion, the management of brain abscess epitomizes the integration of cutting-edge medical and surgical expertise in the pursuit of optimal patient outcomes. By leveraging a comprehensive understanding of pathophysiological mechanisms, anatomical considerations, and therapeutic modalities, clinicians can navigate the intricacies of this formidable neurological condition, striving to mitigate morbidity and mortality while preserving neurological function and quality (17,18).

Complications of the disease

Complications stemming from a brain abscess, though varied in nature, underscore the neurological sequelae and systemic repercussions that can ensue from this intracranial process. From the specter of recurrent abscess formation to the insidious march of brain damage and the ominous shadow of life-threatening infections, the clinical landscape of abscess-related complications is fraught with peril and uncertainty.

A reoccurring abscess, emblematic of the tenacious nature of intracranial infection, portends a grave prognosis, particularly in individuals with compromised immune function or underlying cyanotic heart disease. The recurrence of abscess formation, though relatively uncommon,

heralds a perilous cycle of microbial resurgence, often necessitating prompt medical intervention to forestall further neurological deterioration and systemic compromise (7).

Brain damage, ranging from mild to severe in its clinical manifestations, represents a poignant testament to the insidious nature of abscess-related pathology. While mild to moderate brain injury may exhibit partial resolution over time, severe neurological deficits are frequently irreversible, imposing a profound and enduring burden on affected individuals. The risk of brain damage is further compounded by delays in diagnosis and initiation of therapeutic interventions, underscoring the critical importance of timely recognition and management of intracranial infection (4,7).

Epilepsy, a debilitating neurological disorder characterized by recurrent seizures, emerges as a distressing sequelae of brain abscess pathology. The epileptogenic potential of intracranial infection, though multifactorial in etiology, underscores the complex interplay between inflammatory cascades, neuronal hyperexcitability, and structural aberrations within the cerebral parenchyma. The management of epilepsy in the context of brain abscess necessitates a multidisciplinary approach, integrating pharmacological interventions, neurosurgical techniques, and adjunctive therapies to optimize seizure control and mitigate neurological morbidity (19).

Meningitis, a life-threatening infection of the meninges enveloping the brain and spinal cord or ventriculitis, the breach of infection into the ventricular system, epitomizes the gravest complication of brain abscess pathology. Characterized by a fulminant course and systemic manifestations of sepsis, meningitis mandates urgent medical intervention to forestall catastrophic neurological sequelae and mitigate systemic compromise. The predilection for meningitis in pediatric populations underscores the imperative for heightened vigilance and expeditious management in vulnerable patient cohorts (20).

In summation, the complications of brain abscess pathology constitute a multifaceted clinical spectrum, spanning from recurrent infection to enduring neurological deficits and life-threatening systemic sequelae. By unraveling the intricacies of abscess-related complications, clinicians can navigate the diagnostic and therapeutic challenges posed by this formidable intracranial entity, striving to mitigate morbidity and mortality while preserving neurological function and quality of life.

Prognosis

Brain abscess, a severe intracranial infection characterized by purulent material accumulation within the brain parenchyma, presents diverse challenges in prognosis and outcomes. Despite advancements in diagnostics and therapeutics, the prognosis remains variable, contingent on various factors including patient demographics, etiology, clinical presentation, and timeliness of intervention.

Factors influencing prognosis include:

The underlying etiology significantly influences prognosis. BA from contiguous infections generally have a more favorable outlook compared to those from hematogenous spread or direct inoculation. Timely intervention and recognition are more feasible with contiguous sources like sinusitis or dental infections (21).

Clinical presentation encompasses a spectrum of neurological deficits and systemic manifestations. Abscesses with subtle symptoms or atypical neurological findings may evade early detection, impacting therapeutic outcomes (3,4).

Timeliness of intervention, including the initiation of appropriate antimicrobial therapy and surgical intervention, is pivotal. Delays in diagnosis or treatment initiation can exacerbate inflammation, foster abscess expansion, and lead to neurological deterioration, resulting in poorer outcomes (21).

Host factors such as age, immunocompetence, comorbidities, and functional status also play crucial roles in the outcome. Immunocompromised individuals may exhibit heightened susceptibility to infection and diminished therapeutic response, leading to poorer prognoses compared to immunocompetent counterparts (21).

Outcomes and Complications

Outcomes are contingent upon infection resolution, preservation of neurological function, and mitigation of systemic sequelae. While some patients may experience complete resolution with minimal deficits, others may endure neurological impairment, recurrent infections, or systemic complications (21)

Neurological sequelae encompass a wide range of deficits, including motor, sensory, cognitive, and behavioral impairments. Severity and persistence hinge upon intracranial inflammation, parenchymal damage, and therapeutic efficacy.

Recurrence of brain abscesses is a complication, often due to persistent or inadequately treated foci of infection. Individuals with compromised immune function or residual anatomical abnormalities may be predisposed, necessitating vigilant surveillance and targeted interventions (8,21).

Systemic complications, such as fever, sepsis or metabolic derangements, may heighten morbidity and mortality risks. Sepsis can lead to multiorgan dysfunction syndrome or septic shock, requiring aggressive management (3,4,21).

In conclusion, the prognosis and outcomes of brain abscess are multifaceted, influenced by various factors. Understanding these complexities aids in tailoring individualized management strategies to optimize outcomes, mitigate complications, and preserve neurological function in affected patients.

Case report

A 51-year-old male presented to the emergency department of the Clinical hospital center in Rijeka in January 2020 with fever up to 39°C, severe headache, and neck pain lasting for several hours prior to admission. Upon examination, he displayed signs of meningeal irritation. Notably, his neurological deficits included an erythematous rash on the neck and face, along with hemangiomas on the tongue and a trace of brown secretion in the throat.

In his anamnesis the patient had a significant medical history of Common Variable Immunodeficiency (CVID) and Hereditary Hemorrhagic Telangiectasia (HHT), and previous episodes of brain abscesses in a year 2003 and 2009.

The initial BA presentation, occurring in 2003, unveiled a BA with radiographic evidence of localized purulence within the brain parenchyma of the left temporal-occipital region, of most probable bacterial etiology. Unfortunately, this abscess, upon neurosurgical excision was not microbiologically analyzed. Despite prompt initiation of broad-spectrum antibiotics and surgical drainage, the patient experienced residual neurological deficits as forgetfulness, indicative of the challenges inherent in managing such cases. Unfortunately, available medical records from this time period were only a short discharge letter from the Department of neurosurgery, unrevealing the clinical presentation, description of the performed diagnostic methods (CT was performed to confirm the BA and on subsequent control MRI the scarified tissue was described in above mentioned region) or applied antimicrobial therapy.

The second episode in 2009 further underscored the patient's susceptibility to infectious complications, as another brain abscess emerged.

With the similar clinical presentation (two week period of fever with headache, followed with the development of somnolence and disorientation) the patient underwent neuroimaging with CT revealing BA in the right thalamus.

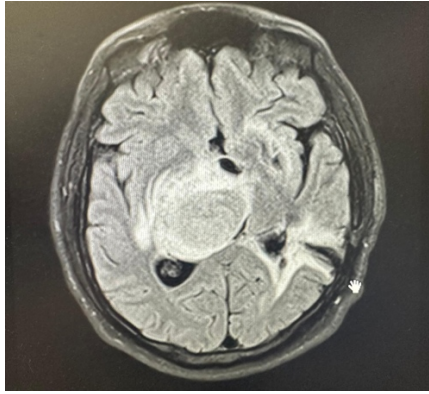


Figure 2: Brain CT displaying in the right supratentorial thalamic and epitalamic, a post-contrast better ring-opacified hypodense lesion, up to 3 cm in diameter, with perifocal edema, compresses the third and ipsilateral ventricles, and pushes them contralaterally. Corresponds to an abscess.

Interestingly, this episode included a notable recurrence of the brain abscess attributed to a fungal etiology. Namely, empiric antimicrobial therapy with parenteral flucloxacillin, ceftriaxone and metronidazole did not encounter the clinical improvement within the first 96h and control MRI revealed the formation of the capsule. Subsequent stereotactic aspiration of the BA and microbiological analysis of the aspirate displayed the growth of *Aspergillus nidulans* antifungal therapy with voriconazole resulted in clinical reconvalescence with radiological confirmation of the complete regression of the BA formation.

In the current, third episode of the disease characterized, as mentioned above, with sudden onset of fever, severe headache and neck stiffness implied prompt neuroradiological assessment. The initial CT scan revealed a 33x27 mm hypodense lesion situated within the left temporoparietal region, a finding highly indicative of a brain abscess. This hypodensity, characteristic of fluid-filled structures, prompted further investigation to delineate the extent and nature of the lesion. Subsequent MRI imaging offered enhanced resolution and detailed characterization of the identified lesion. The MRI findings corroborated the presence of the previously detected abscess while providing additional information regarding its morphology and associated features. Notably, the MRI revealed a larger abscess with a well-defined margin, extending beyond the confines of the initial CT-identified lesion. The presence of surrounding edema, manifested as hyperintense signal intensity on T2-weighted sequences, underscored the severity of the neurological insult and suggested a robust inflammatory response to the infectious process.

3a

3b

3c

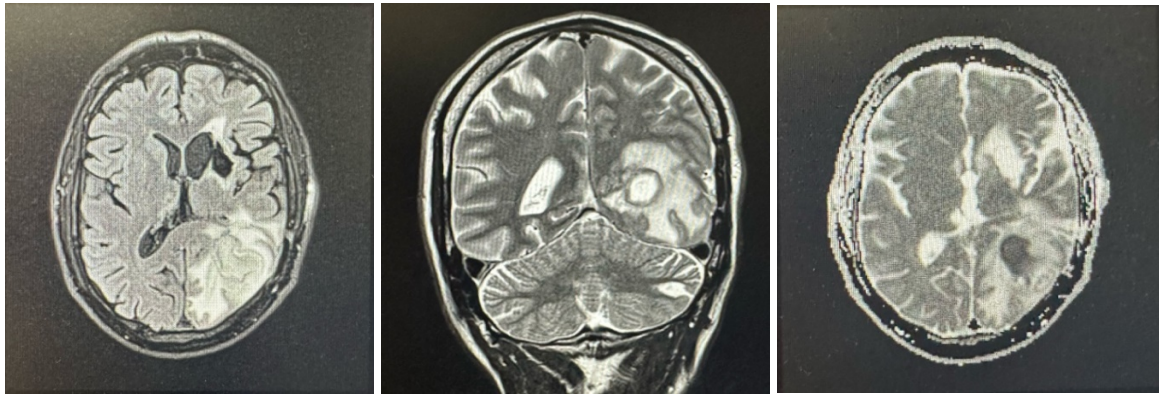


Figure 3: MRI scans of the brain reveal a) an irregular formation in the left temporo-occipital region, measuring up to 32x36x17 mm (anteroposterior x laterolateral x craniocaudal). On T1-weighted images (b) the lesion exhibited hyperintensity in the peripheral region, indicating the presence of potentially enhancing tissue or blood products. In contrast, (c) the T2-weighted images showed hypointensity at the periphery of the lesion, suggesting a complex structure with varying tissue components, possibly including a necrotic core or fibrotic tissue.

Laboratory investigations at admission suggested bacterial etiology of the brain abscess (White Blood Cell Count (WBC): $21.4 \times 10^9/L$ with neutrophil predominance of $19.10 \times 10^9/L$) with normal C-Reactive Protein (CRP) levels of 1.5 mg/L. Empirical antimicrobial therapy with meropenem, vancomycin and caspofungin was followed with neurosurgical debridement and removal of the abscess in which *Actinomyces meyeri* was isolated as an etiological agent of the BA. Subsequent directed antimicrobial therapy with parenteral amoxicillin resulted in both clinical and pathological recovery with radiological confirmation of the complete regression of abscess formation with formed gliomalacia, gliosis in the left corpus striatum, left subcortical cerebellar region, and right thalamic region at control brain MRI performed at 6 months after the medical management.

Upon discharge, he was neurologically stable, afebrile, and had returned to a baseline level of function. The patient left the hospital with a tailored outpatient follow-up plan, including continued intravenous antibiotic therapy, regular immunoglobulin replacement for his CVID, and close monitoring by his primary care physician and neurologist.

Discussion

Recurrent BA in our patient posed additional challenges in treatment due to inherent resistance mechanisms and the immunocompromised state of the patient, stemming from his underlying Common Variable Immunodeficiency (CVID) and Hereditary Hemorrhagic Telangiectasia (HHT). The compromised immune response associated with CVID and the vascular abnormalities characteristic of HHT likely contribute synergistically to the heightened risk of recurrent brain abscesses in this patient (22-24). These recurrences highlight the ongoing risk of infectious complications in patients with underlying immunodeficiency disorders. Management of recurrent brain abscesses necessitates a comprehensive approach, integrating antimicrobial therapy, surgical intervention, and supportive care measures. Challenges such as antimicrobial resistance and intracranial complications emphasize the importance of tailored treatment strategies for each recurrence. A multidisciplinary team is essential in navigating the complexities of these cases, with close monitoring and regular follow-up appointments crucial for assessing treatment response and addressing ongoing management needs.

The initiation of wide spectrum empiric intravenous antibiotic therapy is essential for the survival and outcome of BA. In this case meropenem, a broad-spectrum carbapenem antibiotic, was selected as part of the empiric regimen due to its excellent coverage against a wide range of gram-positive and gram-negative bacteria, including common pathogens associated with brain abscesses such as *Streptococcus* species, *Staphylococcus aureus*, and anaerobic organisms. The decision to include meropenem was driven by the need for rapid and effective antimicrobial coverage to combat the infectious etiology underlying the brain abscess.

Furthermore, vancomycin, a glycopeptide antibiotic, was added to the treatment regimen to provide additional coverage against methicillin-resistant *Staphylococcus aureus* (MRSA) and other gram-positive cocci. Given the potential for nosocomial or healthcare-associated infections in patients with prolonged hospitalizations or previous healthcare exposures, vancomycin was deemed essential for its activity against resistant pathogens commonly encountered in healthcare settings. The combination of meropenem and vancomycin ensured broad-spectrum coverage against both typical and atypical pathogens, addressing the need for empirical therapy while awaiting definitive microbiological results (26, 27).

Additionally, the patient's history of previous BA of fungal etiology, likely attributed to underlying immunodeficiency disorders, prompted the prompt initiation of antifungal therapy with caspofungin. Caspofungin, an echinocandin antifungal agent, was selected for its broad-

spectrum activity against invasive fungal infections, including those caused by *Candida* species and *Aspergillus* species. The inclusion of caspofungin in the treatment regimen aimed to address the potential risk of fungal dissemination or superinfection in the setting of a compromised immune system, thereby ensuring comprehensive antimicrobial coverage (28)

The decision to pursue surgical intervention in the management of BA remains a topic of extensive debate and deliberation among clinicians worldwide. It hinges upon a multitude of factors, each contributing to the overall assessment of the patient's condition and the most appropriate course of action. In the case under consideration, the decision to proceed with surgical drainage and debridement was influenced by a comprehensive evaluation of various clinical and radiological parameters.

In our case, foremost among these considerations was the size and location of the abscess, as revealed by imaging studies. The presence of a sizable hypodense lesion within the left temporoparietal region, indicative of a brain abscess, raised concerns regarding the potential for mass effect and increased intracranial pressure. Such physiological perturbations, if left unaddressed, could precipitate a cascade of neurological deficits, and exacerbate the patient's clinical condition. Thus, the imperative to alleviate intracranial pressure and prevent neurological compromise underscored the urgency of surgical intervention (24).

Furthermore, the anatomical proximity of the abscess to critical neurovascular structures posed additional challenges and considerations. The left temporoparietal region is fraught with intricate neural networks and vital vascular pathways, the disruption of which could have profound implications for neurological function. Given the risk of neurological sequelae associated with abscess expansion and compression of adjacent structures, the decision to pursue surgical drainage and debridement was deemed imperative in safeguarding neurological integrity and optimizing long-term outcomes (25-27).

Moreover, the presence of surrounding edema, as observed on imaging, further accentuated the need for surgical decompression. Edema represents a hallmark feature of intracranial inflammation and is often indicative of an aggressive inflammatory response to the infectious process. Left unchecked, edema can exacerbate intracranial pressure and impede cerebral perfusion, thereby perpetuating a vicious cycle of ischemic injury and neurologic decline. By addressing the underlying source of inflammation through surgical intervention, clinicians sought to mitigate the deleterious effects of edema and expedite the resolution of the abscess.

The surgical approach to brain abscess drainage typically entails the creation of burr holes or craniotomies to access the abscess cavity, followed by meticulous irrigation and debridement

under direct visualization. This approach allows for the thorough evacuation of purulent material and necrotic tissue, thereby facilitating the resolution of infection and preventing abscess recurrence. Additionally, intraoperative cultures and sensitivities enable targeted antimicrobial therapy, further optimizing treatment outcomes and minimizing the risk of microbial resistance (4,8,22)

In summary, the decision to pursue surgical drainage and debridement in the management of BA in our patient was guided by a comprehensive assessment of clinical, radiological, and anatomical considerations. By addressing the underlying source of infection and alleviating intracranial pressure, surgical intervention aimed to optimize neurological outcomes and mitigate the risk of long-term sequelae.

Connection to Prior Diagnosis

The patient's medical history of immunodeficiency disorders profoundly influenced the clinical course and management of the brain abscess. Immunodeficiency disorders are characterized by impaired immune function, predisposing individuals to recurrent infections and heightened susceptibility to opportunistic pathogens. In this case, the underlying CVID likely compromised the immune response to microbial invasion, thereby increasing susceptibility to bacterial and fungal infections. The association between immunodeficiency disorders and the development of brain abscesses underscores the complex interplay between host immune function and infectious pathogenesis. In individuals with immunodeficiency disorders, the impaired immune surveillance and defective immune responses create a conducive environment for microbial proliferation and dissemination. As such, patients with immunodeficiency disorders are at increased risk of developing severe and recurrent infections, including brain abscesses, which necessitate prompt recognition and aggressive management (28, 29).

Furthermore, the presence of Hereditary Hemorrhagic Telangiectasia (HHT) introduces additional considerations regarding vascular malformations and abnormal vessel architecture. HHT is characterized by the development of arteriovenous malformations (AVMs) and telangiectasias throughout the body, including the brain. These vascular abnormalities predispose individuals to bleeding diatheses and vascular complications, raising concerns regarding the pathogenesis and management of intracranial infections such as brain abscesses. The association between HHT and brain abscesses underscores the importance of vigilant monitoring and proactive management in patients with underlying vascular abnormalities. The presence of AVMs and telangiectasias within the cerebral vasculature may serve as potential

sources of infection, facilitating the seeding and dissemination of infectious agents. As such, clinicians must adopt a multidisciplinary approach to the management of brain abscesses in patients with HHT, incorporating neurosurgical consultation, vascular imaging, and infectious disease management to optimize treatment outcomes and minimize the risk of complications (30,31).

In summary, the connection between the patient's prior diagnoses of immunodeficiency disorders and HHT and the development of a brain abscess highlights the intricate interplay between host immune function, vascular abnormalities, and infectious pathogenesis. By elucidating the underlying mechanisms and clinical implications of these associations, clinicians can tailor management strategies to address the unique needs and challenges posed by patients with complex medical histories.

Conclusion

Recurrent brain abscesses represent a difficult challenge in clinical practice, particularly in patients with underlying immunodeficiency disorders such as Common Variable Immunodeficiency (CVID) and Hereditary Hemorrhagic Telangiectasia (HHT). The complex interplay between compromised immune function, vascular abnormalities, and infectious pathogenesis necessitates a multidisciplinary approach for effective diagnosis and management. Through the integration of surgical intervention, empiric and targeted antimicrobial therapy, and long-term immunomodulatory strategies, clinicians can optimize patient outcomes and mitigate the risk of recurrence. The insights gained from the presented case underscore the importance of comprehensive, patient-specific care and highlight the need for continued research to develop novel therapeutic approaches for this challenging clinical entity.

Summary

This thesis provides an extensive review of brain abscesses, emphasizing their etiology, pathophysiology, clinical presentation, diagnosis, and management. The aim is to address challenges in clinical practice, particularly in diagnosing and treating recurrent brain abscesses. A detailed case report is presented, highlighting the clinical course, diagnostic workup, treatment modalities, and outcomes for a patient with multiple brain abscesses. The review underscores the complexity of brain abscess pathogenesis, driven by interactions between microbial virulence factors and human defenses. Etiological agents, ranging from bacteria to fungi, necessitate a nuanced diagnostic and therapeutic approach.

The clinical features of brain abscesses are diverse, often presenting as headaches, fever, and neurological deficits, which complicate early diagnosis. Advanced neuroimaging techniques, such as CT and MRI, are critical for accurate localization and characterization of abscesses, while spectroscopy aids in microbial identification. Management strategies involve a combination of surgical intervention and antimicrobial therapy, tailored to the specific pathogen involved.

The case report illustrates the challenges of recurrent brain abscesses, including difficulties in differentiating them from other intracranial lesions and determining underlying etiologies. It also discusses treatment options, emphasizing the importance of a multidisciplinary approach in managing such complex cases.

The thesis concludes by synthesizing key findings, highlighting common themes and knowledge gaps, and offering recommendations for optimal management and future research.

Literature Cited

1. Brannagan TH, Mozaffar T. Brain abscess. *Archives of Neurology* [Internet]. 2001 Aug 1;58(8):1302. Available from: <https://jamanetwork.com/journals/jamaneurology/article-abstract/780007>
2. Alvis-Miranda HR, Castellar-Leones SM, Elzain MA, Moscote-Salazar LR. Brain abscess: Current management. *Journal of Neurosciences in Rural Practice* [Internet]. 2013 Dec 1;04(S 01):S67–81. Available from: <https://pubmed.ncbi.nlm.nih.gov/24174804/>
3. Patel KS, Clifford DB. Bacterial brain abscess. *the Neurohospitalist* [Internet]. 2014 Jul 10;4(4):196–204. Available from: <https://doi.org/10.1177/1941874414540684>
4. Ko SJ, Park KJ, Park DH, Kang SH, Park JY, Chung YG. Risk Factors Associated with Poor Outcomes in Patients with Brain Abscesses. *Journal of Korean Neurosurgical Society/Journal of Korean Neurosurgical Society/Daehan Sin'gyeong Oegwa Hag'hoeji* [Internet]. 2014 Jan 1;56(1):34. Available from: <https://pubmed.ncbi.nlm.nih.gov/25289123/>
5. Muzumdar D, Jhawar SS, Goel A. Brain abscess: An overview. *International Journal of Surgery* [Internet]. 2011 Jan 1;9(2):136–44. Available from: <https://pubmed.ncbi.nlm.nih.gov/21087684/>
6. Kielian T. Immunopathogenesis of brain abscess. *J Neuroinflammation*. 2004 Aug 17;1(1):16. doi: 10.1186/1742-2094-1-16. PMID: 15315708; PMCID: PMC516022.
7. Bokhari MR, Mesfin FB. Brain abscess [Internet]. *StatPearls - NCBI Bookshelf*. 2022. Available from: <https://www.ncbi.nlm.nih.gov/books/NBK441841/>
8. Bodilsen J, Duerlund LS, Mariager T, Brandt CT, Petersen PT, Larsen L, et al. Clinical features and prognostic factors in adults with brain abscess. *Brain* [Internet]. 2022 Aug 29;146(4):1637–47. Available from: <https://pubmed.ncbi.nlm.nih.gov/36037264/>
9. Bodilsen J, Duerlund LS, Mariager T, Brandt CT, Wiese L, Petersen PT, et al. Risk factors and prognosis of epilepsy following brain abscess. *Neurology* [Internet]. 2023 Apr 11;100(15). Available from: <https://pubmed.ncbi.nlm.nih.gov/36810235/>
10. Omland LH, Nielsen H, Bodilsen J. Update and approach to patients with brain abscess. *Current Opinion in Infectious Diseases/Current Opinion in Infectious Diseases, With Evaluated MEDLINE* [Internet]. 2024 Mar 29; Available from: <https://pubmed.ncbi.nlm.nih.gov/38547383/>
11. Duong MT, Rudie JD, Mohan S. Neuroimaging patterns of intracranial infections: Meningitis, cerebritis, and their complications [Internet]. *U.S. National Library of Medicine*; 2023 [cited 2024 May 18]. Available from: <https://www.ncbi.nlm.nih.gov/pmc/articles/PMC10904173/>
12. Sonnevile R, Ruimy R, Benzonana N, Riffaud L, Carsin A, Tadié J m., et al. An update on bacterial brain abscess in immunocompetent patients. *Clinical Microbiology and Infection* [Internet]. 2017 Sep 1;23(9):614–20. Available from: <https://pubmed.ncbi.nlm.nih.gov/28501669/>
13. Van Crevel H, Hijdra A, De Gans J. Lumbar puncture and the risk of herniation: when should we first perform CT? *Journal of Neurology* [Internet]. 2002 Feb 1;249(2):129–37. Available from: <https://pubmed.ncbi.nlm.nih.gov/11985377/>
14. [Brain abscess--modern diagnostics and therapeutic treatment] [Internet]. *PubMed*. 2009. Available from: <https://pubmed.ncbi.nlm.nih.gov/19522234/>
15. Tang H, Mao T, Gong Y, Mao Y, Xie Q, Wang D, Zhu H, Chen X, Zhou L. Nocardial brain abscess in an immunocompromised old patient: a case report and review of

- literature. *Int J Clin Exp Med*. 2014 May 15;7(5):1480-2. PMID: 24995116; PMCID: PMC4073777.
16. Brouwer MC, Van De Beek D. Epidemiology, diagnosis, and treatment of brain abscesses. *Current Opinion in Infectious Diseases/Current Opinion in Infectious Diseases, With Evaluated MEDLINE* [Internet]. 2017 Feb 1;30(1):129–34. Available from: <https://pubmed.ncbi.nlm.nih.gov/27828809/>
 17. Bokhari MR, Mesfin FB. Brain abscess [Internet]. *StatPearls - NCBI Bookshelf*. 2024. Available from: <https://www.ncbi.nlm.nih.gov/books/NBK441841/>
 18. [The surgical treatment of intracerebral abscesses by using active drainage] [Internet]. *PubMed*. 1993. Available from: <https://pubmed.ncbi.nlm.nih.gov/7701676/>
 19. Kilpatrick C. Epilepsy and brain abscess. *Journal of Clinical Neuroscience* [Internet]. 1997 Jan 1;4(1):26–8. Available from: <https://pubmed.ncbi.nlm.nih.gov/18638919/>
 20. Honda H, Warren DK. Central nervous system infections: meningitis and brain abscess. *Infectious Disease Clinics of North America* [Internet]. 2009 Sep 1;23(3):609–23. Available from: <https://pubmed.ncbi.nlm.nih.gov/19665086/>
 21. Brouwer MC, Coutinho JM, Van De Beek D. Clinical characteristics and outcome of brain abscess. *Neurology* [Internet]. 2014 Mar 4;82(9):806–13. Available from: <https://pubmed.ncbi.nlm.nih.gov/24477107/#:~:text=Case%20fatality%20rate%20decreased%20from,over%20the%20past%2060%20years.>
 22. Yazdani R, Habibi S, Sharifi L, Azizi G, Abolhassani H, Olbrich P, et al. Common variable immunodeficiency: epidemiology, pathogenesis, clinical manifestations, diagnosis, classification, and management. *Journal of Investigational Allergology & Clinical Immunology* [Internet]. 2020 Feb 19;30(1):14–34. Available from: <https://pubmed.ncbi.nlm.nih.gov/30741636/>
 23. Hereditary Hemorrhagic telangiectasia (HHT) [Internet]. *PubMed*. 2024. Available from: <https://pubmed.ncbi.nlm.nih.gov/35201714/>
 24. Ratnaike TE, Das S, Gregson BA, Mendelow AD. A Review of Brain Abscess Surgical Treatment—78 Years: Aspiration versus Excision. *World Neurosurgery* [Internet]. 2011 Nov 1;76(5):431–6. Available from: <https://pubmed.ncbi.nlm.nih.gov/22152572/>
 25. Bandino F, Thota R, Pendolino AL, Chaidas K, Jeyaretna S, Lawrence T, et al. A surgical protocol for sinogenic brain abscess: the Oxford experience and a review of the literature. *Rhinology (Amsterdam Online)/Rhinology* [Internet]. 2022 Jun 21;0(0):0. Available from: <https://pubmed.ncbi.nlm.nih.gov/35726849/>
 26. Baldwin CM, Lyseng-Williamson KA, Keam SJ. Meropenem. *Drugs* [Internet]. 2008 Jan 1;68(6):803–38. Available from: <https://pubmed.ncbi.nlm.nih.gov/18416587/>
 27. Patel S, Preuss CV, Bernice F. Vancomycin [Internet]. *StatPearls - NCBI Bookshelf*. 2023. Available from: <https://www.ncbi.nlm.nih.gov/books/NBK459263/>
 28. Morrison VA. Caspofungin: an overview. *Expert Review of Anti-infective Therapy* [Internet]. 2005 Oct 1;3(5):697–705. Available from: <https://pubmed.ncbi.nlm.nih.gov/16207161/>
 29. Maniglia RJ, Roth T, Blumberg EA. Polymicrobial Brain Abscess in a Patient Infected with Human Immunodeficiency Virus. *Clinical Infectious Diseases/Clinical Infectious Diseases (Online University of Chicago Press)* [Internet]. 1997 Mar 1;24(3):449–51. Available from: <https://pubmed.ncbi.nlm.nih.gov/9114198/>
 30. Zaidi SMH, Bashir M, Choudhry MS, Memon SF, Memon SA. Brain Abscess as a Complication of Hereditary Hemorrhagic Telangiectasia: A Case Report. *Cureus*. 2023 Feb 28;15(2):e35572. doi: 10.7759/cureus.35572. PMID: 37007371; PMCID: PMC10062117.
 31. Themistocleous M, Giakoumettis D, Mitsios A, Anagnostopoulos C, Kalyvas A, Koutsarnakis C. Hereditary hemorrhagic telangiectasia patient presenting with brain

abscess due to silent pulmonary arteriovenous malformation. *Pan Afr Med J.* 2016 Nov 11;25:145. doi: 10.11604/pamj.2016.25.145.11010. PMID: 28292107; PMCID: PMC5326030.

CV

Tayma Ahmet Tunç, born on July 21st 1999, in Gelsenkirchen Germany. He started his educational journey in 2005 in primary school. Afterwards he went on to attend the Ricarda-Huch-Gymnasium in Germany. After finishing with the Abitur in 2017 he started studying in Rijeka in WS18. As interested student he gained a lot of hands on experience in various internships.