

OVERVIEW OF INTERVENTIONAL METHODS IN TREATMENT OF CALCIFIED CORONARY LESIONS

Damm, Christian Alexander

Master's thesis / Diplomski rad

2024

Degree Grantor / Ustanova koja je dodijelila akademski / stručni stupanj: **University of Rijeka, Faculty of Medicine / Sveučilište u Rijeci, Medicinski fakultet**

Permanent link / Trajna poveznica: <https://um.nsk.hr/um:nbn:hr:184:123092>

Rights / Prava: [In copyright](#)/[Zaštićeno autorskim pravom.](#)

Download date / Datum preuzimanja: **2024-09-01**



Repository / Repozitorij:

[Repository of the University of Rijeka, Faculty of Medicine - FMRI Repository](#)



**UNIVERSITY OF RIJEKA
FACULTY OF MEDICINE**

**UNIVERSITY INTEGRATED UNDERGRADUATE AND GRADUATE STUDY OF
MEDICINE IN ENGLISH LANGUAGE**

Christian Alexander Damm

**OVERVIEW OF INTERVENTIONAL METHODS IN TREATMENT OF CALCIFIED
CORONARY LESIONS**

GRADUATION THESIS

Rijeka, 2024

**UNIVERSITY OF RIJEKA
FACULTY OF MEDICINE**

**UNIVERSITY INTEGRATED UNDERGRADUATE AND GRADUATE STUDY OF
MEDICINE IN ENGLISH LANGUAGE**

Christian Alexander Damm

**OVERVIEW OF INTERVENTIONAL METHODS IN TREATMENT OF CALCIFIED
CORONARY LESIONS**

GRADUATION THESIS

Rijeka, 2024

Thesis mentor: **Ass. Prof. Vjekoslav Tomulić, MD, PhD**

The graduation thesis was graded on 14.06.2024 in Rijeka, Croatia, before the Committee composed of the following members:

1. Ass. Prof. David Gobić, MD, PhD (President of the Committee)

2. Ass. Prof. Tomislav Jakljević, MD, PhD

3. Ass. Prof. Zlatko Čubranić, MD, PhD

The graduation thesis contains 36 pages, 8 figures, 2 tables, 76 references.

Table of Contents

1. High-risk calcified coronary lesions and their preparation in interventional cardiology	1
2. Aims and Objectives	2
3. Overview of interventional methods in the treatment of calcified coronary lesions	3
3.1. Assessment of lesion nature	4
3.1.1. Coronary Angiography	4
3.1.2. Intravascular Ultrasound – IVUS	5
3.1.3. Optical Coherence Tomography – OCT	6
3.1.4. Fractional Flow Reserve – FFR	7
3.2. Interventional Techniques and Materials for calcified lesion preparation	8
3.2.1. Ballooning	8
3.2.1.1. Compliant Ballooning	8
3.2.1.2. Semi- and Non-Compliant Ballooning	9
3.2.1.3. Specialty balloons	10
3.2.2. Coronary Atherectomy	13
3.2.2.1. Mechanical Atherectomy Methods	13
3.2.2.2. Photoacoustic Atherectomy Methods	15
4. Discussion	17
5. Conclusion	20
6. Summary	22
7. Appendix	23
8. Literature	24
9. CV	31

List of abbreviations and acronyms

ACC	American College of Cardiology
AHA	American Heart Association
AI	Artificial Intelligence
Atm	Standard Atmosphere (as unit of pressure)
CAD	Coronary Artery Disease
CCTA	Coronary Computed Tomography Angiography
EAPCI	European Association of Percutaneous Cardiovascular Interventions
ELCA	Excimer-Laser Coronary Atherectomy
FD-OCT	Fourier- / Frequency-Domain Optical Coherence Tomography
FFR	Fractional Flow Reserve
FFR _{CT}	Fractional Flow Reserve Computed Tomography Angiography
IVL	Intravascular Lithotripsy
IVUS	Intravascular Ultrasound
JSCAI	Journal of the Society for Cardiovascular Angiography and Interventions
kPa	Kilopascal (as unit of pressure)
OA	Orbital Atherectomy
OCT	Optical Coherence Tomography
OTW	Over-the-Wire
PCI	Percutaneous Coronary Intervention
RA	Rotational Atherectomy
RX	Rapid Exchange
SCAI	Society for Cardiovascular Angiography and Interventions
TD-OCT	Time-Domain Optical Coherence Tomography

1. High-risk calcified coronary lesions and their preparation in interventional cardiology

Percutaneous Coronary Intervention (PCI) was once a newcomer, joining the fight against coronary issues classically solved in the operating theatre. Almost half a century has passed since Andreas Gruentzig performed his first coronary balloon angioplasties, thereby paving the way for new spheres of coronary care (1,2). But time exerts the same effect on medical fields as it does on people: an increase in depth, complexity and broadened scope changes their appearance. Limited resources, shallow knowledge and small emerging centres are replaced by huge networks, and the trial of various strategies leads to new discoveries and resource expansion. Where once a simple method for imaging and intervention was established, now expands a huge field of different approaches and technical possibilities. The ‘newcomer’ has evolved into a tough and experienced individual.

This vast amount of information and techniques may stun newcomers striving to enter and later on master the field. At this point, securing a solid basis and overview of Interventional Cardiology proves to be a challenge – even more so in the complex field of lesion preparation, especially regarding calcified stenoses.

Coronary artery disease and calcification represent huge issues on a population basis. Therefore, research on aetiology and pathomechanisms intensified over the course of the last decades. Up to this date, two subtypes, namely ‘intimal’ and ‘medial’ calcification, are discriminated in coronary artery disease (CAD). Intimal calcification starts with subendothelial deposition of apo B lipids in coronary arteries, leading up to inflammatory processes, resulting in monocyte activation; as described incisively by Caiazzo et al., the metamorphosis of monocytes to macrophages and consequential phagocytic processes culminate in oxidation of the substrates – hence ultimately killing the macrophage as well, resulting in the transition to a so-called ‘foam cell’ (3). Mori and colleagues argue that these foam cells will calcify over time and present with a “larger punctate appearance”; the hereby inflicted oxidative stress moreover causes intimal smooth muscle cells to go into apoptosis, resulting in microcalcifications and conglomeration into bigger, intimal, calcified plaques paving the way to calcium plates and sheets (4).

The subtype of medial calcification, on the other hand, tends to root in more general imbalances: “renal failure, hypercalcemia, hyperphosphatemia, parathyroid hormone abnormalities and duration of dialysis” are the paramount factors related to the medial subtype (4).

Aside from its mechanisms, coronary calcification is on the rise, as stated in the Journal of the Society for Cardiovascular Angiography and Interventions (JSCAI) by Ripley et al. (5).

Commonly known risk factors for coronary calcification overall are age, male gender, obesity, hypertension, hypercholesteremia, diabetes and smoking. In ever ageing societies and with an increase in other risk factors, inclining numbers of calcified lesion coronary interventions over the next years and decades are to be expected.

It can be deduced that this ever-evolving medical field of Interventional Cardiology, broadening and gaining in complexity, will experience rising demand on the patient side. All these developments warrant the need for concise entry points into the field, steep learning curves on the practitioner's side and dedicated curricula, establishing balanced workloads among clinicians, simultaneously ensuring the highest possible quality of care while tackling the increased demand in our societies.

This thesis was written with these factors in mind: an overview is given to introduce the reader to the field of lesion preparation in calcified stenosis. At the same time, evidence for the respective techniques will be discussed, and the call for intensified research should form within the audience to not only broaden the field of lesion preparation in the future but also to streamline processes and enhance efficiency in tomorrow's Interventional Cardiology.

2. Aims and Objectives

This thesis aims to provide interested individuals insight into contemporary methods for lesion preparation in calcified stenoses. As lesion imaging proves to be paramount for successful lesion preparation, the current methods regarding this topic will be presented as well. The techniques for preparation and their corresponding imaging solutions and when to use them best - according to current guidelines and recent data - will be discussed after their presentation. The backbone for general information on materials, techniques and balloons consists of various data and information from textbooks on Interventional Cardiology, marked in the footnotes and accessible via the literature list.

Specific (proposed) mechanisms of action and data were only accessible on the manufacturer's website hence, this information was directly sourced from the producer. However, respective passages are labelled correspondingly.

Societies like EAPCI (European Association of Percutaneous Cardiovascular Interventions), AHA (American Heart Association), ACC (American College of Cardiology) and SCAI (Society for Cardiovascular Angiography and Interventions) evaluated in regard to their guidelines, consensus- and position-papers to display the respective stance on procedures and the level of evidence behind them.

The PubMed database was consulted using the search prompts and filters displayed in Table 1 to display current data and novel findings. Articles retracted when accessing the PubMed

database, and articles only originally and in the complete form available in languages other than English were consequently excluded.

Table 1: PubMed Search Prompts for Corresponding Topics

Topic	Search Prompt	Filters
Coronary Angiography	(((((,Coronary Angiography"[Mesh]) AND "Artificial Intelligence"[Mesh]) NOT "Computed Tomography Angiography"[Mesh]) NOT ("Single Photon Emission Computed Tomography Computed Tomography"[Mesh] OR "Tomography, X-Ray Computed"[Mesh] OR "Multidetector Computed Tomography"[Mesh] OR "Tomography Scanners, X-Ray Computed"[Mesh])) NOT "Tomography, Emission-Computed, Single-Photon"[Mesh]) NOT ("Echocardiography"[Mesh] OR "Echocardiography, Stress"[Mesh])	Free full text last 5 years
Intravascular Ultrasound	(("Ultrasonography, Interventional"[Mesh]) AND "Percutaneous Coronary Intervention"[Mesh]) AND "Vascular Calcification"[Mesh]	Free full text last 5 years
Optical Coherence Tomography	(("Vascular Calcification"[Mesh]) AND "Tomography, Optical Coherence"[Mesh]) AND "Percutaneous Coronary Intervention"[Mesh]	Free full text last 5 years
Fractional Flow Reserve	(("Fractional Flow Reserve, Myocardial"[Mesh]) AND "Angioplasty, Balloon, Coronary"[Mesh])	Free full text last 5 years
Semi- and Non-Compliant Ballooning	(,Vascular Calcification"[Mesh]) AND "Angioplasty, Balloon, Coronary"[Mesh]	Free full text last 5 years
Specialty Balloons	(,Angioplasty, Balloon, Coronary"[Mesh]) AND ("scoring balloon") and (,Angioplasty, Balloon, Coronary"[Mesh]) AND ("cutting balloon")	Free full text last 5 years
Mechanical Atherectomy Methods	("orbital atherectomy") AND ("rotational atherectomy")	Free full text last 5 years
Excimer Laser Atherectomy	("Lasers, Excimer"[Mesh]) AND "Atherectomy, Coronary"[Mesh]	Free full text last 5 years
Intravascular Lithotripsy	"intravascular lithotripsy"	Free full text last 5 years Clinical Trial Meta-Analysis Randomized Controlled Trial Review Systematic Review

3. Overview of interventional methods in the treatment of calcified coronary lesions

No therapeutic method, may it be drug, lifestyle, surgery, or intervention, can stand on its own. The tools that today's medicine feet on may have changed the world's face and humanity in unprecedented ways, but irrespective of that marvelous fact, these tools may not hold

themselves upright on their own. Each of these little wonders, often overlooked and taken for granted today, can only be put up against disease by means of diagnostics and evidence substantiating them. Even if some means should stand on its own, with no human comprehension as to how and why it works, it is in the end just fate, not more than chance holding it upright, rendering humankind clueless after all, in case it should fail. Therefore, diagnosis, comprehension, evidence and therapy should go hand in hand - the same applies to treating calcified coronary lesions.

3.1. Assessment of lesion nature

Various recent publications emphasise using assessment tools more regularly as proof of the inferiority of the human eye, and practitioners' interpretation begins to emerge. Since the introduction of coronary angiography and intervention in the late 1970s, the techniques for actual interventional methods and equipment have progressed and improved, and so have the methods for classifying and assessing the lesion. Assessing lesions is vital for strategy success and provides less biased evidence in the long run. This allows the hypothesis, that today's in-depth assessments are the evidence and cost-effectiveness of tomorrow.

The rationale behind this process is Anatomy and (Patho-)Physiology. Intravascular imaging, which consists of intravascular ultrasound (IVUS) and optical coherence tomography (OCT), can give the practitioner a better understanding of vessel width, lesion type, and extent, with implications regarding the intervention method. Measurement of Fractional Flow Reserve (FFR) can deliver testimony of the lesions' morphology and the significance of its correction. Artificial intelligence's rise and upcoming use in various imaging methods also demonstrate its use in coronary angiography, where deep learning models already “non-invasively and consistently estimate FFR from angiographic images, offering significant clinical potential” (6).

3.1.1. Coronary Angiography

Using the dynamic fluoroscopy method to visualise the blood flow and coronary vessels technically reaches back to the days of x-ray-discovery and found its broader research in the 20th century. When coronary angiography was first used in the late 1950s and Gruenzig's first angioplasty in the late 1970s, it developed into the gold standard of coronary vessel imaging. Actual time application and access to anatomical and functional information still defend its usage today (7).

At the same time, the process of angiography itself was and is subject to constant change and evolution. The introduction of modern software enabling digital image subtraction, minimal radiation exposure, precise steering for imaging systems, on-screen measuring aids, and the

possibility to playback the recorded images modernised the technique to today's digital working standard. With the rise of artificial intelligence (AI), coronary angiography will also make the next step within the 21st century and adapt to today's innovation, even if the processes behind technological leaps need to be understood and critically audited (8–10).

As mentioned previously, the measurement of FFR, which will be presented later in this section, can already be estimated by AI systems using recorded angiography images (6).

Additionally, many more AI technologies are already in development or even final revision to become technologies used in the context of 21st-century coronary angiography, starting with models to reduce unneeded invasive examinations, predicting interventional success or probability of future cardiac events, continuing with calculations for the likelihood of complications, and classifying lesions, reaching up to “fully automated PCI guidance” systems and diagnostic programs extracting the relevant information from angiographic images to find the matching diagnoses (11–18).

This represents the introduction of deep learning systems into the field of angiography to aid and inform the practitioner. Implementing AI in coronary angiography will aid in streamlining processes and decrease workload burden while at the same time improving outcomes and consistency in procedures. This is essential for (chronically) calcified lesions, where examination of the plaque and an individualised procedure is paramount to successful intervention.

3.1.2. Intravascular Ultrasound – IVUS

Ultrasonography has revolutionised medicine since its invention and adaptation in clinical practice. However, due to the laws of physics, spatial resolution is too low to produce satisfying information when using transthoracic techniques. Technological progress allowed the positioning of the ultrasound transducer on a catheter in the late 1980s, which enabled imaging from within the vessel itself. To achieve this, single-element transducers and phased array transducers have been constructed and constitute the two subtypes of IVUS catheters.

Still, the image and its resolution are then limited by the wavelength of sound. The insides of a coronary artery can be assessed by width, pathological change, nature, and extent of the lesion. The shortcomings of resolution can be balanced by the depth of penetration, which is more profound than that of Optical Coherence Tomography (OCT).

In a 2018 EAPCI consensus statement, Räber and colleagues already stated that “There is growing evidence (...) that intravascular imaging guidance by IVUS not only enhances the acute procedural result but also improves clinical outcomes” (19). In the meantime, the great sensitivity of IVUS when compared with coronary angiography alone has been proven and is

associated with better outcomes than angiography-only-PCI (7,20,21). Therefore, it seems especially sensible to advocate for its use in calcified lesions. For example, Jinnouchi et al. report the use of IVUS to assess for stent expansion, vessel dissection and prediction of adverse events like ‘no-reflow’, while Min and colleagues combined IVUS with deep learning algorithms to forecast the probability of stent under expansion which enabled improved interventional outcomes (21,22).

At the same time, due to physical limitations of sound wavelength and the corresponding “150 μm axial resolution”, IVUS often manages to inform about the presence of a calcified plaque but fails to yield details on its surface quality (23). This is especially true when overly dense and thick calcium lesions are examined (20). Consequently, IVUS performs inferior to OCT when factors like stent expansion are assessed: Teng et al. imply that less reliable imaging data of IVUS after RA led to fewer uses of scoring balloon dilatation before stent implantation in comparison to OCT (24).

As a rule of thumb, using IVUS proves beneficial to the patient and the success of the intervention. In calcified coronary lesions, usage of IVUS is justified before and after intervention. At the same time, it conflicts with OCT regarding its detailed advantages and disadvantages, even if the two techniques can be used in tandem.

3.1.3. Optical Coherence Tomography – OCT

The relatively juvenile technique of optical coherence tomography, described first in 1991 made its way from across many other medical implementations into the field of Interventional Cardiology (25).

Similarly to IVUS, OCT ‘scans’ the vessel walls – but facilitates light ray backscattering to acquire the image. Processed by software, this backscattering is rendered into a digital construction of the vessel wall with information on spatial and temporal position. The spatial resolution of this technique, enabled by the shorter wavelength of light, is in the range of 10-20 μm (7). A shortcoming of this high resolution is the interference of erythrocytes - early models of OCT even required the purging of blood in the analysed vessel. As of today, it is sufficient to flush the vessel while the recording is being made. The explanation for this phenomenon lies in the two subtypes of OCT: The earlier model, time-domain OCT (TD-OCT), like IVUS measured echo-times, giving away relevant information about the tissue; this technique necessitated a blocked vessel to prevent erythrocyte interaction, as filtering certain echo-times prior to image construction was not feasible (7,26). The second-generation, Fourier-domain OCT (FD-OCT) records wave-length interference in backscattered rays, enabling the calculation of tissue information in hindsight, thereby allowing the exclusion of specified noise

aside from faster image acquisition and easier handling (26). The use of OCT enables a more precise classification of the lesion, therefore having a direct imperative on treatment and the means used to achieve procedural success. This is particularly subject to the techniques discussed in this paper. Differentiation between thin calcium cap and thick concentric calcium can mean a difference between using balloons or atherectomy. However, not only the basic technique but also size-and length selection can accurately be aided with the use of OCT. Faster pullback speeds enabled by FD-OCT reduce artefacts and produce more accurate measurements than the other compared techniques (7,26).

Using ‘traditional’ means, OCT already helps to improve outcomes and aids the practitioner even in identifying rare complications (27). Asakura et al. in 2019 even described a “Zero-Contrast Optical Coherence Tomography- and Physiology-Guided Percutaneous Coronary Intervention for Severely Calcified Lesion” that was only preceded by a minimal contrast angiography on the day prior and did not use any contrast media during the intervention itself (28). Using deep learning will also enhance the power of OCT in the future as specific programs are already on the way here, for example, with the prediction of stent under-expansion (29).

So, even if it is not widely used in every hospital today, OCT and its evolutionary expansions have already sketched out their future use and abilities.

3.1.4. Fractional Flow Reserve – FFR

Measurement of Fractional Flow Reserve (FFR) stands in contrast to techniques mentioned earlier, as it is a ‘functional’ measurement. Angiography, IVUS and OCT are anatomical imaging techniques, that indicate physiological consequences. Often, these indications are correct, and the following intervention or its omittance proves beneficial. But even though the use of advanced methods like IVUS and OCT showed improved outcomes compared to the practitioner’s eye alone, the interpretation of specific measurements and subsequent implications stay subject to the abilities and expertise of the examiner.

Substantiating this hypothesis is the FAME trial (Fractional flow reserve versus angiography for guidance of PCI in patients with multivessel coronary artery disease), which saw significantly decreased adverse events in the setting of reduced costs and reduced number of implanted stents (30). While anatomical imaging evaluates the visual tightening of a vessel, FFR enables the comparison of pressures proximal and distal to the lesion during pharmaceutically induced maximal vasodilation, allowing a gradient to be calculated, which expresses the pressure drop caused by the lesion (31). Respective numbers can be classified according to significance with an implication regarding lesion dignity (2). Guided by this

classification, an evidence-based approach can be used to make decisions regarding the treatment.

Again, current leaps in technology are noteworthy: Progress in computational tomography resolution and increased computing capacity facilitate computed fluid dynamic simulations, enabling non-invasive FFR-measurement (32). This so-called Fractional Flow Reserve Computed Tomography Angiography (FFR_{CT}) creates a promising outlook on upstream decision making, allowing cardiovascular intervention itself the chance to be more time-effective and targeted (33,34).

3.2. Interventional Techniques and Materials for calcified lesion preparation

After this summary of techniques to discover and assess calcified lesions, the upcoming lines will now present the different means of preparing and manipulating the respective calcifications.

By today's standards, two major techniques can be differentiated in lesion preparation overall, their subclasses each standing out by different mechanistic philosophies behind them: Ballooning on the one side, either with semi- and non-compliant balloons or dedicated, so-called 'specialty'-balloons. Device-based methods of coronary atherectomy, subdivided into mechanical and photo-acoustic devices on the other hand.

In the following lines, each of the respective methods will be explained and described, emphasising their use-cases and advantages as well as disadvantages.

3.2.1. Ballooning

Expandable balloons in their varying forms, either directly on catheters (RX) or by over-the-wire (OTW) methods, whether being used for lesion preparation, stent expansion or post-dilatation, represent the workhorse and build the backbone of intervention (35).

Respective to the qualities of the balloons, sub-classification allows the differentiation into compliant, semi-compliant and non-compliant.

Specific specialty balloons are constructed based on semi- and non-compliant balloons, with features like blades added to increase the punctual load on the plaque; those will also be presented in this section (2).

3.2.1.1. Compliant Ballooning

Compliant balloons adapt to filling pressure by increasing size and therefore, their extension can be measured by filling volume and the pressure exerted upon the surrounding enclosure is lower respectively (36,37). These characteristics allow operation in scenarios where good adaptation of the device is needed, and compliance of the artery is still given. In cases of

calcification, compliant balloons are not feasible to use for lesion preparation. Therefore, compliant balloons will not further be discussed in this paper.

3.2.1.2. Semi- and Non-Compliant Ballooning

Balloon angioplasty using semi- and non-compliant balloons developed with a specific underlying rationale: the vessel must be dilated; the calcified lesion should be disrupted for a stent to hold the lumen within increased diameter. As discussed before, when inflating a compliant balloon with volume, it will expand – and in constrained space will exert pressure on its enclosure. At the same time, pressure will rise within the material, and compliant materials will tend to expand into the direction of the open vessel and have less resistance than further increasing pressure upon the lesion. If the plaque is in the middle of the balloon, it will expand on its distal and proximal end, but at the same time, the lesion still compresses the intermediate part; this phenomenon is also known as `dog-boning` (Figure 1).

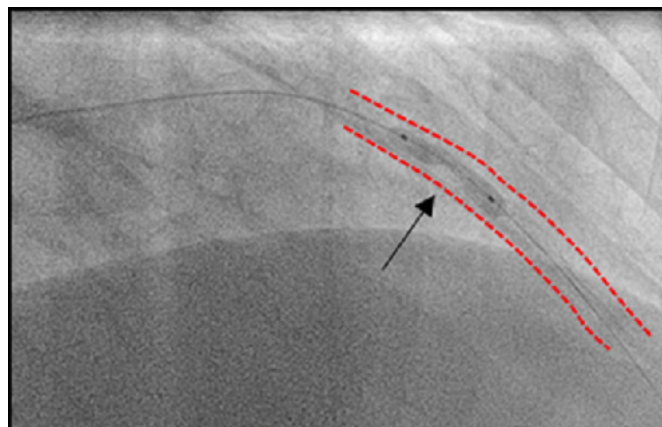


Figure 1: 'Dog-Boning' phenomenon in calcified LAD-lesion

(Source: Neleman T, Ziedses des Plates A, Daemen J. Coronary lithotripsy – a state of the art review - *ClinicalKey: Trends Cardiovasc Med* [Internet]. 2023 May 1 [cited 2024 May 8];33(4):215–22. Available from: <https://www.clinicalkey.com/#!/content/journal/1-s2.0-S1050173822000056>)

Furthermore - if the balloon does not rupture - once a pressure is reached that suffices to displace the plaque or rupture the calcium, the reduced resistance will allow the balloon to increase in size at the place being and overexpand. This will eventually lead to major side effects and damage to the vessel.

Emerging from this thought process, semi- and non-compliant balloons have been constructed: once a certain volume is reached, this type of material will not, or, depending on the pressure increments, will only partially expand. At the same time, the pressure exerted on the constraining surroundings will increase, nevertheless. When the calcified plaque is cracked, the balloon, in its reduced compliance, will not overextend and damage the vessel, therefore preparing the lesion for material implantation or later treatment while reducing the risk for major adverse events. Reasonably, the inflation of this type of balloon is measured in pressure,

namely atmospheres (Atm) or kilopascals (kPa). To ensure proper usage by the practitioner, so-called compliance charts are delivered with every balloon, on which relative size increases and maximal pressure increments are pointed out – therefore allowing the user to adapt balloon type and size towards the measurements made earlier by angiography, IVUS or OCT.

Recent developments in the field are aiming to construct smaller balloons with a better possibility of being delivered to convoluted peripheral coronary arteries, while at the same time enabling higher filling pressures (2).

While textbooks mention balloon pressures in the ranges of “20 atmospheres without overexpansion”, current studies already evaluate a class called “super high-pressure balloon” with pressures in the ranges of 35 Atm, which is a noteworthy demonstration of evolution within this field (2,38). Nylon and polyester are typical materials used for the construction of balloons with low compliance (35,39).

3.2.1.3. Specialty balloons

Contemporary semi- and non-compliant balloons allow for further modifications to be made to them. Namely, different manufacturers develop certain additions out of different schools of thought. Cutting balloons, scoring balloons, and “chocolate” balloons comprise atherotomes, rectangular edges or nitinol restraints fixed on the outer side of the balloon to generate different effects on the vessel wall, respectively (40–42).

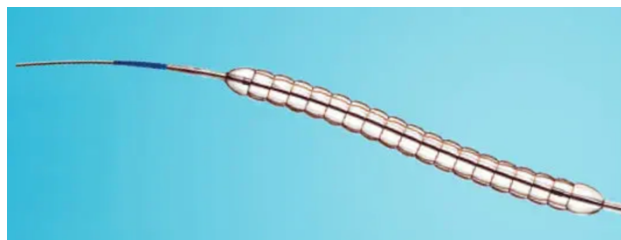

Figure 2: Chocolate XD balloon, Teleflex

(Source: PTA-Katheter - Chocolate XD® - Teleflex Medical - Koronar / Ballon [Internet]. [cited 2024 Apr 7]. Available from: <https://www.medicalexpo.de/prod/teleflex-medical/product-77428-917443.html>.)

To begin with Chocolate balloons, the name is achieved by the ‘cage’ of metal nitinol wiring that separates the semi-compliant balloon into even segments, generating the outer appearance of a chocolate bar. Nitinol is the often-used mixture of Nickel and Titanium, allowing a ‘memory function’ – the tendency of the material mixture to expand into a previous form once reheated (43). The backbone of this construction is a semi-compliant balloon; this allows the material to extend beyond the nitinol cage, exerting higher tissue pressures at those places.

According to Teleflex, a provider of the ‘Chocolate XD’ balloon (Figure 2), this type of inflation “[provides] predictable, uniform, and atraumatic dilatation” (44). A manufacturer of chocolate balloons, Medtronic, producing the ‘Chocolate PTA’ balloon, meant for use in the peripheral

vasculature, explains the balloons' mechanism of function by small dissections generated at the points of maximum extension; the grooves caused by the nitinol cage follow the rationale of interrupting the dissections from propagation (42). Nevertheless, the reduced availability of data regarding the 'Chocolate XD' balloon has to be pointed out, as it is mentioned by textbooks and the United States distributor website, but only one Open-Access paper on PubMed mentions the concomitant use of a Chocolate balloon in the setting of previously performed Rotational Atherectomy, besides taking place in a very specific and confined setting (35,44,45). Regardless of the shortcomings, the approach and respective data, as well as the conclusion in this publication, make further studies seem fruitful. Medtronic explicit note referring to the 'Chocolate PTA' balloon as a tool "intended for balloon dilatation of lesions in the peripheral vasculature, including the iliac, femoral, ilio-femoral, popliteal, infra-popliteal, and renal arteries" allows conclusions about its working mechanism but scientifically hinders statements on the performance on calcified coronary lesions – especially without accompanying data or papers (42).



Figure 3: AngioSculpt Evo balloon, Philips Healthcare

(Source: AngioSculpt Evo Scoring-Balloonkatheter | Philips Healthcare [Internet]. [cited 2024 Apr 7]. Available from: <https://www.philips.ch/healthcare/product/HICGTDASEVOBC/angiosculpt-evo-scoring-balloonkatheter#specifications>

As a contrasting concept to using restraints on the material to increase the punctual load exerted by the balloon, scoring and cutting balloons follow the philosophy of attaching solid material to the balloon, thereby increasing the punctual load exerted upon the lesion at the respective locations. The way scoring balloons achieve this is by attaching rectangular Nitinol or Nylon stripes in a longitudinal, often spiraling way. According to the manufacturer Biotronik, the setting of increasing pressure within the balloon will push these scoring elements into the plaque and reduce slippage, thereby locking the balloon in place; additionally, the top-mounted Nitinol stripes will increase punctual load upon the plaque by around 15-25 times, and once the scoring elements are embedded into the plaque, the balloons qualities mimic traditional balloons by evenly transferring the forces again (40). As often criticized - for the proposed working mechanism, the manufacturer must be cited, as actual data to underline efficacy and

proof for the mechanism are lacking (46). Data from observational studies, however, seem to prove efficacy: reportedly low rates of target lesion failure in calcified lesion preparation, with succeeding stent or drug-coated balloon treatment, seem to underline the proposed utility (47,48). Simultaneously, growing complexity likely enhances material-associated side-effects, especially in the demanding setting of calcified lesions: in a database analysis focused on the ‘Angiosculpt Evo’ scoring catheter (Philips, Figure 3), Dayco et al. state that regardless of the generally low incidence of complications, material failure (tip break, balloon rupture, withdrawal difficulties) posed the most common issue in aforementioned setting (49).

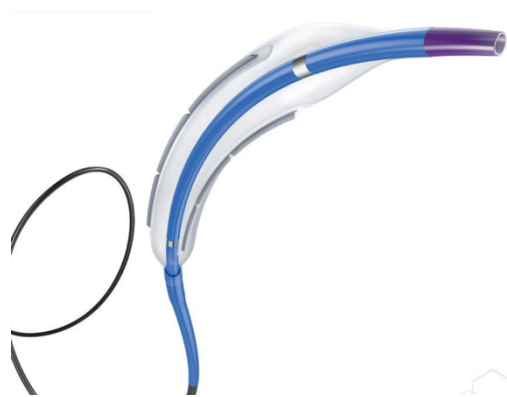

Figure 4: Wolverine balloon, Boston scientific

(Source: WOLVERINE™ Mikrochirurgischer Dilatationskatheter mit Schneidballon | Boston Scientific [Internet]. [cited 2024 Apr 7]. Available from: <https://www.bostonscientific.com/DE-Deutsch/produkte/plaque-modification/wolverine-cutting-balloon.html>)

In cutting balloons, on the other hand, Nitinol elements are replaced with ‘Atherotomes’: sharp blades are mounted in a longitudinal fashion on a non-compliant balloon. It is postulated that these blades will disturb the continuity “of elastic and fibrotic continuity of the vessel wall“ when pressed into the calcific plaque. One example of a cutting balloon would be the ‘Wolverine’ (Boston Scientific, Figure 4) (2). The manufacturer states that these 127 μm atherotomes create microincisions, ‘anchor’ the device and create higher and concentrated forces in the surrounding tissue (50,51). A computational mechanistic model reported by Xiadong, Mitsuo and Kiyotaka builds the backbone for these statements (52).

The Wolverine cutting balloon, as an example, is available in sizes 2.00 - 4.00 mm, with 0.25 mm increments and with blade lengths of 6, 10 and 15 mm can work up to rated pressures of 12 atm; delivery can be made via guidewires bigger than 0.014 in and through 5Fr catheters (50–53). Boston Scientific classifies target lesions for their cutting balloon as “calcifications in discrete or tubular shape in a native vessel sized between 2.00 - 4.00 mm, accessible for the device with light to moderate tortuosity; lesion segment should be non-angulated and have a smooth contour with the absence of a thrombus”, the manufacturer itself postulates a

contraindication for delivery through the “side cell of a stent for the risk of entanglement” (54). Interestingly, Kaneko et al. 2020 were able to capture the broken blade of a Wolverine balloon using IVUS while discussing that “There are limited reports of broken blades of cutting balloons” (27).

3.2.2. Coronary Atherectomy

Whereas the previously described methods rely on mechanically shattering and crushing the plaques but technically leaving it in place to be later on covered and stabilized by a stent, Coronary Atherectomy generally follows the philosophy of removing plaque, either as a singular approach or in combination with later use of dilatation. Albeit not used as often as balloon techniques in the past, the last decade saw an increasing number of patients treated with atherectomy procedures, as manufacturers are able to produce more elaborate devices able to operate within coronary arteries. Subcategories of Coronary Atherectomy encompass mechanical and photoacoustic methods. Mechanical methods can be split up into Rotational (RA) and Orbital Atherectomy (OA), whereas photoacoustic treatments comprise the Excimer Laser (ELCA) and Lithotripsy (IVL) techniques.

3.2.2.1. Mechanical Atherectomy Methods

As mentioned, atherectomy methods bring the benefit of taking calcified material away from the lesion, but also pose certain risks. To understand those, the techniques and philosophy behind must be kept in mind.

Rotational Atherectomy (RA), with the ROTAPRO system (Boston Scientific, Figure 5) as an example, facilitates an oval-shaped burr to target the lesion. This burr has diamond particles embedded on its tip, sanding down the calcium. Pressurized air powers the burr to 160.000 revolutions per minute, thereby producing 2-5 μm particle sizes, which should pass through the coronary capillaries, reducing the risk for a no-reflow situation (2). The basic prerequisite for treatment is a lesion being crossable by the guide wire, the burr and its drive wire. Burr sizes range from 1.25 to 2.50 mm with 0.25 increments, allowing progressive treatment with inclining diameter (55).

However, the technique of rotational atherectomy must be seen as an addition rather than substitution to balloon-based methods, as it usually helps degrade the superficial or particularly hard calcium for subsequent finalization of the intervention using ballooning or stenting techniques (2). In a one-to-one comparison of RA with balloon-based methods, RA amounted to higher stent eccentricity, a factor known to favor restenosis; irrespectively, a higher number

of strategy success was attained at the same time (56). This underlines the importance of RA to be found in the trained practitioner's repertoire for a step-up or bail-out therapy. Nonetheless, a prerequisite for good results is the appropriate utilization of IVUS and OCT for information on lesion type, thickness and extent to consequently make decisions on burr sizing (57).

A shortcoming attributed to the working mechanism of RA is enhanced target vessel occlusion by the guidewire and the burr; certain techniques, like administration of 'cocktails' mixed from vasodilators and heparin, facilitate the alleviation of this situation, but nonetheless, reduction in blood flow takes place and is combined with particle load from calcium abrasion (58).

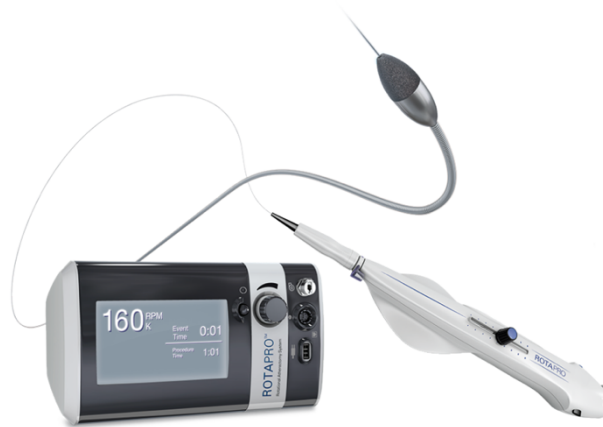

Figure 5: ROTAPRO, Boston scientific

(Source: ROTAPRO™ Rotational Atherectomy System - Boston Scientific - Boston Scientific [Internet]. [cited 2024 May 10]. Available from: <https://www.bostonscientific.com/en-US/products/atherectomy-systems/rotapro.html>)

Major contraindications for RA, namely the ROTAPRO System are specified by Boston Scientific as: Guidewire inaccessible lesions, lesion in last vessel supplying left ventricle, saphenous vein grafts, thrombus being present and “evidence of significant dissection” (59).

In contrast, Orbital Atherectomy (OA), with its representative being the Diamondback 360 (Abbott, previously Cardiovascular Systems Inc., Figure 6), entails two mechanisms: the cylindrically shaped ‘crown’ represents the sanding mechanism and is situated on an imbalanced wire; while the proximal and distal end of the guidewire within the vessel act as ‘fixation points’ and due to the centrifugal force emerging once the wire is rotated, the increase in revolutions will cause enhanced circular movement; for of this reason, the OA device can adapt to different vessel sizes without changing wires or burrs (2). One crown of 1.25 mm, spun at 80.000 or 120.000 revolutions, respectively, can, therefore, be used to adapt to either hardened calcified lesions or increased vessel diameter (60). Abbott claims that the system produces particle sizes of around 2 μm and that the six French compatible tool will treat vessel

sizes between 2.5 and 4.0 mm, with the statement that “pulsatile impact of the crown against deep plaque can create microfractures that modify deep calcium“ (61).

A mechanistic difference between OA and RA that needs to be pointed out is the constant flow of blood, lubricant, and fluid flush during the procedure, allowing the hypothesis that the claimed 2 µm particle size is diluted differently in OA compared to RA. Additionally, OR is a bidirectional method, allowing treatment in advancing, and retracting movements, as Shlofmitz et al. state (62).

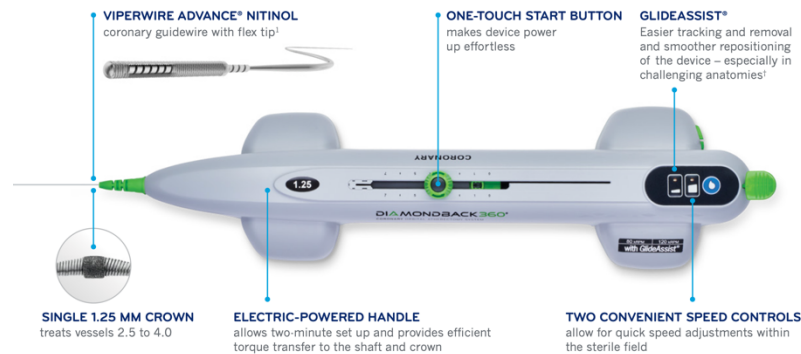


Figure 6: Diamondback 360, Abbott

(Source: Unique Challenges. Individualized Solutions. [Internet]. [cited 2024 Apr 7]. Available from: https://csi360.com/wp-content/uploads/2023/02/EN-7378_A_Coronary-Franchise-Brochure_DIGITAL.pdf)

Contraindications to OA are inability to cross the lesion with the guidewire, lesion within graft or stent, evidence of a thrombus, last vessel supplying the ventricle and coronary dissection within the vessel (60).

3.2.2.2. Photoacoustic Atherectomy Methods

Photoacoustic methods for Atherectomy entail Excimer Laser Coronary Atherectomy (ELCA) and Intravascular Lithotripsy (IVL). In contrast to the aforementioned methods, these techniques rely on different wavelengths and their respective effect on the calcified lesion rather than mechanically manipulating it.

Excimer Laser Coronary Atherectomy has been in use since the early 1990s (53). The ELCA (Philips, Figure 7) is an example of this category. Today, the ELCA emits ultraviolet light with a wavelength in the range of 308 nm, which reduces side effects from “[vapour] bubble formation” found during the prior use of infrared light in the range of 2090nm (53).

In general, emission of this wavelength inside the coronary vessel leads to various effects debriding the vascular enclosure: chemical, mechanical and thermal changes produce a gas bubble at the tip of the catheter; simultaneously the acoustic shockwave interferes with the plaque (53). To avoid damage inflicted by this mechanism, the so-called ‘two-thirds’ rule should

be obeyed: the diameter of the ELCA should not exceed two-thirds of the vessel size as the bubble formed exceeds the of the catheter (53,63). With the sizes 0.9, 1.4, 1.7 and 2.0 mm being available, the manufacturer consequently states the minimum vessel diameter therefore to be 2.0 mm – 3.0 mm, respectively, with guide wire compatibility from 6 to 8F being stated for the sizes accordingly (63). This makes the ELCA a tool for somewhat bigger coronary arteries.



Figure 7: ELCA, Philips healthcare

(Source: Philips - ELCA coronary laser atherectomy catheter [Internet]. [cited 2024 Apr 7]. Available from: <https://www.philips.co.uk/healthcare/product/HGIGTDFELCALASR/elca-coronary-laser-atherectomy-catheter>)

The device is advanced and retracted for 5 to 10 seconds at 25-80 Hz repetition rates; a pause of 5-10 seconds between the runs is needed to reduce unwanted thermal consequences; simultaneous saline flush is recommended to minimize heat and “[vapour] bubble” effects (53). Particle sizes are stated to be below 10 μm (2). Kumbhani and Deepak mention the usefulness of ELCA in saphenous vein grafts and chronic total occlusions as well as other complicated lesions but also point out complication rates (“coronary dissection” and “perforation”) as “not uncommon” (2). Krishnaswamy and Raphael summarise the ELCA method (referring to the ERBAC, AMRO and LAVA studies) as follows: “Data do not support a greater benefit of laser atherectomy compared with PTA alone in ‘all comer’ lesions. However, it does hold a role in the treatment of severely calcified lesions and stent underexpansion.” (53).

In 2021 a new method met FDA approval: Intravascular lithotripsy (IVL) with the ‘Shockwave C²⁺’ catheter (Shockwave Medical, Figure 8) as the example of this category (53).

IVL follows the concept of combining balloon catheters with facilitating acoustic effects on calcium. A balloon, filled with a mixture of water and contrast medium (50:50 ratio) encases electrical elements; subsequent discharge of these elements inside the slightly inflated balloon (4 Atm) leads to vaporisation of the mixture, followed by pulsatile expansion and sound wave generation: this shockwave is transmitted in within the enclosure and foremost exerts its effects onto the surrounding calcifications (53,64). One IVL sequence encompasses ten pulses in combination with a succeeding review of the lesion for gained compliance at 6atm; two

sequences are recommended for each respective lesion site (64). With the newer line of catheters, the maximum number of pulses, previously limited to 80, was expanded to 120 pulses per catheter (53,65). However, if the segment is 12 mm long, the manufacturer still recommends a maximum of 80 cumulative pulses (65).

Strengths of IVL lie in circular calcifications and the ability to be delivered over a workhorse wire; in addition, the broken plaque theoretically stays in place and has reduced risk for emboli (53). Hence, practitioners are advised to abstain from flushing a target vessel. IVL catheters can be brought into place by 5Fr systems and is more voluminous than corresponding balloon systems due to the electrical elements within. Balloon diameters are available from 2.5 – 4.0 mm, with 0.5 mm increments (53,65).



Figure 8: Shockwave C²⁺, Shockwave Medical

(Intravascular Lithotripsy (IVL) | Shockwave Medical [Internet]. 2024 [cited 2024 May 8]. Available from: <https://shockwavemedical.com/technology/intravascular-lithotripsy-ivl/>)

Krishnaswamy and Raphael conclude their summary of IVL and the CAD I-III studies by noting high rates of procedural success embedded within good safety profiles while adding that, up to their point of research, “no randomized data are available to compare IVL with other calcium modification techniques“ (53).

4. Discussion

After now having encountered the major tools and ideas behind them, an overview of the presented techniques and their technical data may give a concise summary. For this overview, Table 2 can be consulted.

Table 2: Overview of Techniques and Example Balloons

Technique	Example	Manufacturer	Length (min-max, mm)	Vessel Width (min-max, mm)	Min. Catheter size (Fr)	Guide wire (in)
Non-compliant balloon	OPN NC	SIS	10 - 20	1.5 – 5.5	6	Rx, 0.014
Chocolate balloon	Chocolate XD	Teleflex	10 – 20	2.0 – 3.5	5	Rx, 0.014
Scoring Balloon	AngioSculpt Evo	Philips	6 - 20	2.0 – 3.5	5	Rx, 0.014
Cutting Balloon	Wolverine	Boston Scientific	6 - 15 (Blade)	2.0 – 4.0	6	RX/OTW
Rotational Atherectomy	Rotapro	Boston Scientific	< 25	2.5 – 5.0	6 - 8	0.009 - 0.014
Orbital Atherectomy	Diamondback 360	Abbott	-	2.50 – 4.00	6	0.012 - 0.014
Excimer Laser Atherectomy	ELCA	Philips	> 20	2.0 – 3.0	6 - 8	Rx/OTW 0.014
Intravascular Lithotripsy	Shockwave C ²⁺	Shockwave Medical	2 – 12	2.5 – 3.0	5	Rx 0.014

Data on the balloons alone already gives a rough overview of each methods’ benefits and their respective limitations. For example, long consecutive lesions (> 15mm) are better managed by techniques like OR, RA or Excimer Laser Atherectomy than with multiple runs of balloons.

As mentioned before, however, prior to encountering the lesion, its assessment is key to understanding the interventional setting and available options. Ali et al. describe three “fundamental barriers” hindering practitioners from managing calcified lesions with greater success: in their eyes, the “lack of a universal algorithm” causes infrequent use of intravascular imaging such as IVUS and OCT and leads to inadequate diagnosis of calcified arteries, cumulating in poor utilization of advanced techniques like RA (66). As of 2023, dedicated SCAI and EAPCI consensus papers put analysis/ assessment before tool selection, encouraging practitioners to make informed and evidence-based decisions on which technique to choose for their plaque modification. The two algorithms can be compared in the appendix (Figure 9 and Figure 10). To put both consensus papers in concise form, a synopsis yields the following recommendations:

The EAPCI consensus puts emphasis on specialty balloons like the cutting or scoring balloons yielding similar effects as super-high-pressure balloons, even though working with lower pressures in the process; high- and super-high pressure balloons allow avoidance of the dog-boning effect and reduce critical side effects while occasionally creating challenges in crossing and recrossing lesions due to their stiffer nature (67). In the SCAI consensus, Riley and colleagues recommend cutting balloons as the primary strategy and point out the advantage of reduced slippage being especially useful in ostial lesions (68). Rheude et al. on the other hand,

demonstrated “comparable stent expansion on intravascular imaging and a trend towards improved angiographic performance” when comparing the scoring balloon ‘NSE Alpha’ (Braun) with the super-high-pressure ‘OPN NC’ (SIS) balloon (38). However, attention must be paid, as the trial was partly financed by SIS and Boston Scientific. On another note, analysing the PREPARE-CALC and ISAR-CALC trials, the comparison of super-high-pressure balloon, modified balloon and RA failed to show significant difference when it came to stent expansion; the super-high-pressure balloon performed better when it came to stent eccentricity and RA demonstrated higher strategy success respectively (56). The controversy in this subgroup of intervention highlights the importance of the practitioner's wise and individually patient-centered choice: trial and error may function in the grey zone; however, a multitude of balloon runs and tormenting one vascular region allows the hypothesis of increased risk for side effects. Apart from promising lower procedural cost and time efficiency, a lesser side effect profile can be expected when the interventionalist’s choices succeed on the first try. In case of ostial intervention or lesion where balloon slippage is to be expected according to the practitioner’s judgement, the use of cutting or scoring balloons seems superior. If the chances for these issues seem minor and access for (super-) high pressure balloons is given, opting for the high-pressure balloon appears non-inferior. Regardless, the evidence to underline these tendencies proves strikingly thin.

Further substantiating this issue, in referral to the comparison between Rotational Atherectomy, Orbital Atherectomy and Intravascular Lithotripsy, Barbato et al. state: “Data on the relative efficacy of RA compared with OA or IVL are not yet available”; on a positive note however, they point out the use of RA as “bailout” strategy in many balloon trials and that RA since “(...) 1987 (...) survived all subsequent developments due to its unique advantages” (67). On behalf of the SCAI, Riley et al. point out similar complication rates between RA and OA, avoiding direct comparisons in their consensus (68). Possible advantages of RA could lie in its extended use and number of patients treated; in contrast, the benefit of OR may lie in one system being able to treat varying lesion diameters without interchanging burrs (67).

While ELCA is mentioned by Barbato et al. mainly as an adjunctive method, Riley and colleagues on behalf of the SCAI point out to missing evidence regarding the latest device version and discrepancy of the actual clinical use of the device: namely the “off-label adaptations to enhance the photoacoustic effects”; therefore they put the focus for ELCA more in the field of fibrotic, rather than severely calcified lesions; irrespectively, one advantage they refer to is the “coronary guide wire compatibility allowing entrance into device-uncrossable lesions” (67,68).

IVL use is encouraged for concentric, circumferential, calcified lesions by the SCAI consensus as promising data on nodular and eccentric lesions are mentioned; moreover, the possibility of guide wire utilization and the “synergistic” application with other mechanical devices is pointed out (68). However, evidence based, comparative trials for IVL are still missing as of today (67). Theoretical advantage, as Dini et al. mention, could come from modification of deep calcium, which remains untouched by RA and OA (46).

Overall, when entering the field of lesion preparation in calcified stenoses, a significant point of critique is the lack of big-scale, evidence-based recommendations, and comparative trials. As mentioned earlier, aside from new techniques and materials, a worthwhile target for research over the following years could be the structured analysis of imaging data gained by IVUS and OCT, with artificial intelligence eventually aiding the process. Evidence of that kind will ensure a better scientific basis and more reliability for crucial decision-making, thereby supporting specialists already in practice and easing the entry for incoming professionals to the field of Interventional Cardiology.

5. Conclusion

After discussing the different techniques, their advantages and the available corresponding data, the subsequently derived algorithms for calcified lesion preparation of EAPCI and SCAI do not differ too much. They reflect the stance of an objective reader after surveying the latest data and empirical consensus statements.

Clinical presentation of the patient with coronary complaints should be objectified by imaging methods like coronary computed tomography angiography (CCTA), which allows pre-planning the intervention and aids in orientation during the procedure later on (67,68). Should CCTA not be available, coronary angiography with balloon expansion evaluation in two or more angles can act as a supplement (67). IVUS and/ or OCT should be used for lesion assessment (19,66–68). If the lesion is not accessible with the imaging catheter, balloon predilatation, or atherectomy methods may facilitate entry to the lesion site for consecutive imaging and treatment (19,67). In the setting of intracoronary images showing circumferential calcium, calcium over 270° and over 5 mm, in a vessel smaller than 3.5 mm or signs of calcified nodules, RA, OA and IVL are recommended (67). Specific discrimination or recommendation between the respective methods are not made at this point and are therefore left to the practitioner’s preference and evaluation. Should the first measures not be sufficient, combination treatment and intensified atherectomy are recommended as step-up measures (67,68). In the absence of circular or long calcium lesions (<180/270°, <5 mm), the use of cutting, non-compliant or high-

pressure balloons is recommended (67). In any case, calcium modification success should be confirmed with another imaging run before stent implantation is approached (19,66–68).

Half a century after the first balloon angioplasties, the field of Interventional Cardiology has evolved into a broad and subspecialised branch. Independent studies and research are needed in the subspecialty of calcified lesion preparation, even more so with respect to ageing populations and the rising risk factor incidence for coronary calcifications. This research and accompanying data will shape the lesion preparation of the future, regardless of which techniques will come out as superior and which tools will not be pursued any longer. These steps will lead to more evidence-based decisions on the practitioner's side and will aid in cost- as well as time-efficiency, reducing the burden of workload in the process.

The years 2023 and 2024 saw up-to-date algorithms with respect to available data emerge on both sides of the Atlantic Ocean, advising logical and empiric approaches to calcified lesions (66–68).

Recent developments in computational power, material science, and artificial intelligence only leave room for our imagination when it comes to the scopes and frontiers of tomorrow's Interventional Cardiology.

6. Summary

Interventional Cardiology has undergone many changes and has become a broad subspecialty. Lesion preparation of calcified stenoses poses a challenge for practitioners. The main risk factors for coronary calcifications are age, male gender, obesity, hypertension, hypercholesteremia, diabetes and smoking. With ageing societies and inclining numbers of risk factors, the ongoing increase in the incidence of coronary calcifications will continue to rise.

Current developments in imaging techniques can aid in assessing calcified lesions, allowing a multitude of implications: application of artificial intelligence, IVUS, OCT and FFR methods can be expected to yield information on coronary calcification phenotypes, their incidence, connection to aetiology and enhance knowledge on risk factors. More objective evidence regarding calcium modification techniques and materials used will be accessible. Quality of care and provider training can be improved.

A multitude of methods and tools to modify coronary calcifications has been developed in the last decades: non-compliant balloons, super-high-pressure balloons, specialty balloons (cutting, scoring), rotational atherectomy, orbital atherectomy, excimer laser atherectomy and intravascular lithotripsy represent the latest options in the interventional cardiologist's armory. However, evidence, especially of comparative type, is sparse and divided into many componential studies, only allowing confined advice on the superiority of one solution.

Practitioner expertise mostly relies on experience and good judgement over the last few years. However, intensified appeals for independent and comparative research have emerged lately, and current developments have led to consensus papers with more concise rules regarding intravascular imaging and consequential decisions on calcium modification technique to be used.

Keywords: interventional cardiology, coronary calcification, calcified stenosis, intravascular ultrasound, optical coherence tomography, fractional flow reserve, super-high-pressure balloon, specialty balloon, cutting balloon, chocolate balloon, scoring balloon, rotational atherectomy, orbital atherectomy, excimer laser atherectomy, intravascular lithotripsy

7. Appendix

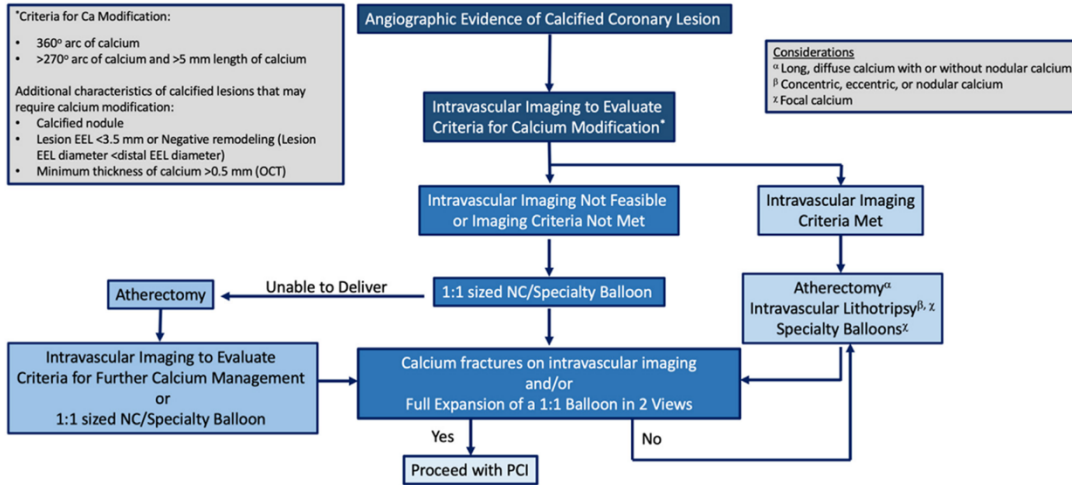
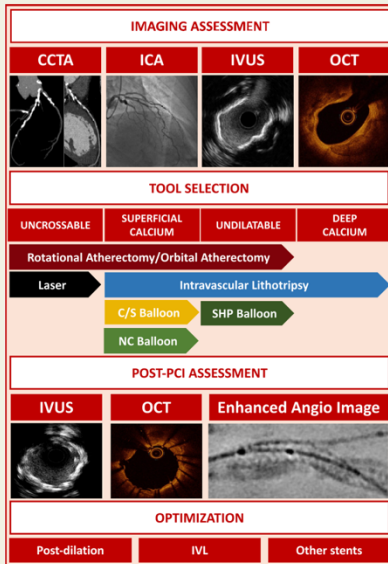


Figure 6. Treatment algorithm for calcified CAD. Ca, calcium; EEL, external elastic lamina; OCT, optical coherence tomography; NC, noncompliant; PCI, percutaneous coronary intervention. *Criteria for calcium modification shown on left.

Figure 9: SCAI Algorithm

(Source: Riley RF, Patel MP, Dawn Abbott J, Bangalore S, Brilakis ES, Croce KJ, et al. SCAI Expert Consensus Statement on the Management of Calcified Coronary Lesions. Journal of the Society for Cardiovascular Angiography & Interventions [Internet]. 2024 [cited 2024 Apr 7];3:101259. Available from: <https://doi.org/10.1016/j.jscai.2023.101259>)

Graphical Abstract



Summary of the main points of the consensus document. In the central section of the figure, the indication for each tool according to the type of calcified lesion is represented. Abbreviations: CCTA, coronary computed tomography angiography; ICA, invasive coronary angiography; IVUS, intravascular ultrasound; OCT, optical coherence tomography; NC, non-compliant; C/S, cutting/scoring PCI; percutaneous coronary intervention; SHP, super-high-pressure; IVL, intravascular lithotripsy.

Figure 10: EAPCI Algorithms

(Source: Barbato E, Gallinoro E, Abdel-Wahab M, Andreini D, Carriè D, Di Mario C, et al. Management strategies for heavily calcified coronary stenoses: an EAPCI clinical consensus statement in collaboration with the EURO4C-PCR group. Eur Heart J [Internet]. 2023 Nov 1 [cited 2024 Apr 7];44(41):4340–56. Available from: <https://dx.doi.org/10.1093/eurheartj/ehad342>)

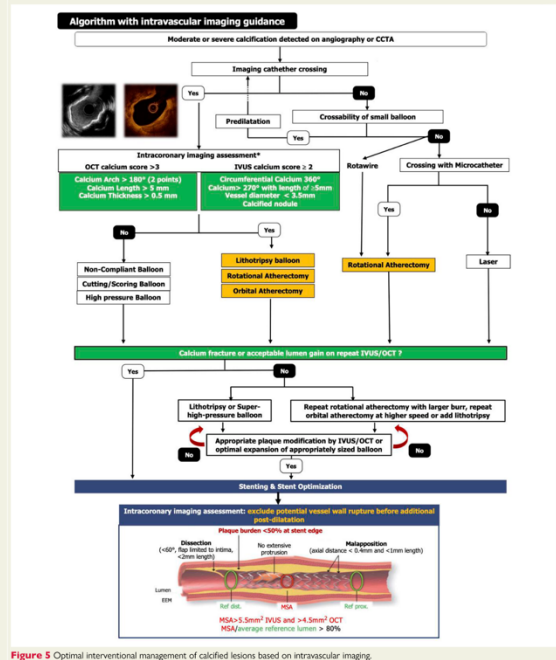


Figure 5 Optimal interventional management of calcified lesions based on intravascular imaging.

8. Literature

1. Williams DO. The birth of interventional cardiology. In: Bhatt DL, editor. *Cardiovascular Intervention: A companion to Braunwald's Heart Disease*. 2nd ed. Philadelphia: Elsevier Inc.; 2024. p. 1–6.
2. Kumbhani DJ, Bhatt DL. Percutaneous Coronary Intervention. In: Libby P, Bonow RO, Mann DL, Tomaselli GF, Bhatt DL, Solomon SD, et al., editors. *Braunwald's Heart Disease: A Textbook of Cardiovascular Medicine* [Internet]. 12th ed. Philadelphia: Elsevier Inc.; 2022. p. 786–803. Available from: www.syntaxscore.com
3. Caiazzo G, Di Mario C, Kedhi E, De Luca G. Current Management of Highly Calcified Coronary Lesions: An Overview of the Current Status. *Journal of Clinical Medicine* 2023, Vol 12, Page 4844 [Internet]. 2023 Jul 23 [cited 2024 Apr 7];12(14):4844. Available from: <https://www.mdpi.com/2077-0383/12/14/4844/htm>
4. Mori H, Torii S, Kutyna M, Sakamoto A, Finn A V., Virmani R. Coronary Artery Calcification and its Progression: What Does it Really Mean? *JACC Cardiovasc Imaging*. 2018 Jan 1;11(1):127–42.
5. Riley RF, Patel MP, Dawn Abbott J, Bangalore S, Brilakis ES, Croce KJ, et al. Standards and Guidelines SCAI Expert Consensus Statement on the Management of Calcified Coronary Lesions. 2023 [cited 2024 Apr 6]; Available from: <https://doi.org/10.1016/j.jscai.2023.101259>
6. Arefinia F, Aria M, Rabiei R, Hosseini A, Ghaemian A, Roshanpoor A. Non-invasive fractional flow reserve estimation using deep learning on intermediate left anterior descending coronary artery lesion angiography images. *Scientific Reports* 2024 14:1 [Internet]. 2024 Jan 20 [cited 2024 Feb 6];14(1):1–16. Available from: <https://www.nature.com/articles/s41598-024-52360-5>
7. Dangas GD, Mehran R. Coronary Angiography and Intravascular Imaging - ClinicalKey. In: Libby P, Bonow RO, Mann DL, Tomaselli GF, Bhatt DL, Solomon SD, et al., editors. *Braunwald's Heart Disease: A Textbook of Cardiovascular Medicine* [Internet]. 12th ed. Philadelphia: Elsevier Inc.; 2022 [cited 2024 Feb 6]. p. 363–84. Available from: <https://www.clinicalkey.com/#!/content/book/3-s2.0-B9780323722193000219>
8. Lopez JJ, Sonka M. Is Deep Learning Coming to Guide Your Coronary Intervention? *JACC Cardiovasc Interv*. 2021 May 10;14(9):1030–2.
9. Molenaar MA, Selder JL, Nicolas J, Claessen BE, Mehran R, Bescós JO, et al. Current State and Future Perspectives of Artificial Intelligence for Automated Coronary Angiography Imaging Analysis in Patients with Ischemic Heart Disease. *Curr Cardiol Rep* [Internet]. 2022 Apr 1 [cited 2024 Feb 7];24(4):365. Available from: [/pmc/articles/PMC8979928/](https://pubmed.ncbi.nlm.nih.gov/38979928/)
10. Howard J, Reiber JHC. Automated analysis of coronary angiograms using artificial intelligence: a window into the cath lab of the future: AI for coronary angiography. *EuroIntervention* [Internet]. 2021 May 1 [cited 2024 Feb 7];17(1):16. Available from: [/pmc/articles/PMC9707463/](https://pubmed.ncbi.nlm.nih.gov/39707463/)
11. Lu H, Yao Y, Wang L, Yan J, Tu S, Xie Y, et al. Research Progress of Machine Learning and Deep Learning in Intelligent Diagnosis of the Coronary Atherosclerotic Heart

- Disease. *Comput Math Methods Med* [Internet]. 2022 [cited 2024 Feb 7];2022. Available from: [/pmc/articles/PMC9064517/](#)
12. Lee HG, Park SD, Bae JW, Moon SJ, Jung CY, Kim MS, et al. Machine learning approaches that use clinical, laboratory, and electrocardiogram data enhance the prediction of obstructive coronary artery disease. *Scientific Reports* 2023 13:1 [Internet]. 2023 Aug 3 [cited 2024 Feb 7];13(1):1–12. Available from: <https://www.nature.com/articles/s41598-023-39911-y>
 13. Baskaran L, Ying X, Xu Z, Al'Aref SJ, Lee BC, Lee SE, et al. Machine learning insight into the role of imaging and clinical variables for the prediction of obstructive coronary artery disease and revascularization: An exploratory analysis of the CONSERVE study. *PLoS One* [Internet]. 2020 Jun 1 [cited 2024 Feb 7];15(6):e0233791. Available from: <https://journals.plos.org/plosone/article?id=10.1371/journal.pone.0233791>
 14. Deng L, Zhao X, Su X, Zhou M, Huang D, Zeng X. Machine learning to predict no reflow and in-hospital mortality in patients with ST-segment elevation myocardial infarction that underwent primary percutaneous coronary intervention. *BMC Med Inform Decis Mak* [Internet]. 2022 Dec 1 [cited 2024 Feb 7];22(1):1–16. Available from: <https://bmcmmedinformdecismak.biomedcentral.com/articles/10.1186/s12911-022-01853-2>
 15. Howard JP, Cook CM, van de Hoef TP, Meuwissen M, de Waard GA, van Lavieren MA, et al. Artificial Intelligence for Aortic Pressure Waveform Analysis During Coronary Angiography: Machine Learning for Patient Safety. *JACC Cardiovasc Interv*. 2019 Oct 28;12(20):2093–101.
 16. Omori H, Kawase Y, Mizukami T, Tanigaki T, Hirata T, Okubo M, et al. Diagnostic Accuracy of Artificial Intelligence-Based Angiography-Derived Fractional Flow Reserve Using Pressure Wire-Based Fractional Flow Reserve as a Reference. *Circulation Journal*. 2023 May 25;87(6):783–90.
 17. Blazejowska E, Zimodro JM, Figatowski T, Brzeski A, Dziubich T, Parzuchowski J, et al. AngioScore: An artificial intelligence tool to assess coronary artery lesions. *Cardiol J* [Internet]. 2023 [cited 2024 Feb 7];30(5):846. Available from: [/pmc/articles/PMC10635723/](#)
 18. Ploscaru V, Popa-Fotea NM, Calmac L, Itu LM, Mihai C, Bataila V, et al. Artificial intelligence and cloud based platform for fully automated PCI guidance from coronary angiography-study protocol. *PLoS One* [Internet]. 2022 Sep 1 [cited 2024 Feb 7];17(9):e0274296. Available from: <https://journals.plos.org/plosone/article?id=10.1371/journal.pone.0274296>
 19. Räber L, Mintz G, Koskinas K, Johnson T, Holm N, Onuma Y, et al. Clinical use of intracoronary imaging. Part 1: guidance and optimization of coronary interventions. An expert consensus document of the European Association of Percutaneous Cardiovascular Interventions | *EuroIntervention*. *EuroIntervention* [Internet]. 2018 Jun [cited 2024 Apr 1];14(6):656–77. Available from: <https://eurointervention.pconline.com/article/clinical-use-of-intracoronary-imaging-part-1-guidance-and-optimization-of-coronary-interventions-an-expert-consensus-document-of-the-european-association-of-percutaneous-cardiovascular-interventions>
 20. Yokoi K, Nakamura D, Mizote I, Shiraki T, Ohtani T, Hikoso S, et al. Comparison of Intravascular Ultrasound and Optical Coherence Tomography Images of Calcified

- Lesions During Rotational Atherectomy. *JACC Cardiovasc Interv.* 2021 Feb 22;14(4):474–5.
21. Jinnouchi H, Sakakura K, Taniguchi Y, Tsukui T, Watanabe Y, Yamamoto K, et al. Intravascular ultrasound-factors associated with slow flow following rotational atherectomy in heavily calcified coronary artery. *Scientific Reports* 2022 12:1 [Internet]. 2022 Apr 5 [cited 2024 Feb 17];12(1):1–10. Available from: <https://www.nature.com/articles/s41598-022-09585-z>
 22. Min HS, Ryu D, Kang SJ, Lee JG, Yoo JH, Cho H, et al. Prediction of Coronary Stent Underexpansion by Pre-Procedural Intravascular Ultrasound–Based Deep Learning. *JACC Cardiovasc Interv.* 2021 May 10;14(9):1021–9.
 23. Neumann FJ, Sousa-Uva M, Ahlsson A, Alfonso F, Banning AP, Benedetto U, et al. 2018 ESC/EACTS Guidelines on myocardial revascularization. *Eur Heart J* [Internet]. 2019 Jan 7 [cited 2024 Feb 18];40(2):87–165. Available from: <https://dx.doi.org/10.1093/eurheartj/ehy394>
 24. Teng W, Li Q, Ma Y, Cao C, Liu J, Zhao H, et al. Comparison of optical coherence tomography-guided and intravascular ultrasound-guided rotational atherectomy for calcified coronary lesions. *BMC Cardiovasc Disord* [Internet]. 2021 Dec 1 [cited 2024 Feb 17];21(1):1–9. Available from: <https://bmccardiovascdisord.biomedcentral.com/articles/10.1186/s12872-021-02103-5>
 25. Huang D, Swanson EA, Lin CP, Schuman JS, Stinson WG, Chang W, et al. Optical Coherence Tomography. *Science* [Internet]. 1991 Nov 11 [cited 2024 Feb 18];254(5035):1178. Available from: <https://pubmed.ncbi.nlm.nih.gov/1609016/>
 26. Adriaenssens T, Fujimoto J, Jang IK. Optical coherence tomography. In: Bhatt DL, Fuster V, editors. *Cardiovascular Intervention: A Companion to Braunwald’s Heart Disease* [Internet]. 2nd ed. Philadelphia, PA: Elsevier Inc.; 2024 [cited 2024 May 14]. p. 319–36. Available from: <https://www.clinicalkey.com/#!/content/book/3-s2.0-B978032387368000026X>
 27. Kaneko U, Kashima Y, Kanno D, Fujita T. First-in-Human Cutting Balloon Broken Blade Fracture Imaged Using Optical Frequency Domain Imaging/High-Definition Intravascular Ultrasound. *JACC Cardiovasc Interv.* 2020 Jul 27;13(14):1718–9.
 28. Asakura K, Minami Y, Shimohama T, Ako J. Zero-Contrast Optical Coherence Tomography- and Physiology-Guided Percutaneous Coronary Intervention for Severely Calcified Lesion. *Circulation Journal* [Internet]. 2019 Oct 25 [cited 2024 Feb 18];83(11):2326. Available from: <http://dx.doi.org/10.1253/circj.CJ-19-0302>
 29. Gharaibeh Y, Lee J, Zimin VN, Kolluru C, Dallan LAP, Pereira GTR, et al. Prediction of stent under-expansion in calcified coronary arteries using machine learning on intravascular optical coherence tomography images. *Scientific Reports* 2023 13:1 [Internet]. 2023 Oct 23 [cited 2024 Feb 18];13(1):1–12. Available from: <https://www.nature.com/articles/s41598-023-44610-9>
 30. Van Nunen LX, Zimmermann FM, Tonino PAL, Barbato E, Baumbach A, Engstrøm T, et al. Fractional flow reserve versus angiography for guidance of PCI in patients with multivessel coronary artery disease (FAME): 5-year follow-up of a randomised controlled trial. *The Lancet* [Internet]. 2015 Nov 7 [cited 2024 Feb

- 21];386(10006):1853–60. Available from: <http://www.thelancet.com/article/S0140673615000574/fulltext>
31. Duncker DJ, Cauty JM. Coronary Blood Flow and Myocardial Ischemia. In: Libby P, Bonow RO, Mann DL, Tomaselli GF, Bhatt DL, Solomon SD, et al., editors. Braunwald's Heart Disease: A Textbook of Cardiovascular Medicine [Internet]. 12th ed. Philadelphia: Elsevier Inc.; 2022 [cited 2024 Feb 21]. p. 609–35. Available from: <https://www.clinicalkey.com/#!/content/book/3-s2.0-B9780323722193000360>
 32. Rajiah P, Cummings KW, Williamson E, Young PM. CT Fractional Flow Reserve: A Practical Guide to Application, Interpretation, and Problem Solving. Radiographics [Internet]. 2022 Mar 1 [cited 2024 Feb 24];42(2):340–58. Available from: <https://pubs.rsna.org/doi/10.1148/rg.210097>
 33. Takagi H, Leipsic JA, McNamara N, Martin I, Fairbairn TA, Akasaka T, et al. Translesional fractional flow reserve gradient as derived from coronary CT improves patient management: ADVANCE registry☆. J Cardiovasc Comput Tomogr [Internet]. 2022 Jan 1 [cited 2024 Feb 24];16(1):19. Available from: </pmc/articles/PMC9719736/>
 34. Kang SH, Kim SH, Kim SH, Chun EJ, Chung WY, Yoon CH, et al. Performance of a Novel CT-Derived Fractional Flow Reserve Measurement to Detect Hemodynamically Significant Coronary Stenosis. J Korean Med Sci [Internet]. 2023 Aug 8 [cited 2024 Feb 24];38(32). Available from: </pmc/articles/PMC10427209/>
 35. Ayatt Y, Toole M, Shroff A. Guide catheters, Guide extenders, Guidewires, Balloons, and Stents. In: Lim MJ, Sorajja P, Kern MJ, editors. Interventional Cardiac Catheterization Handbook, The - ClinicalKey [Internet]. 5th ed. Philadelphia: Elsevier Inc.; 2023 [cited 2024 Feb 27]. p. 139–62. Available from: <https://www.clinicalkey.com/#!/browse/book/3-s2.0-C2019004959X>
 36. Balloon Catheter Design Considerations | Minnesota MedTec [Internet]. 2021 [cited 2024 May 14]. Available from: <https://minnesotamedtec.com/top-3-design-considerations-when-it-comes-to-balloon-catheters/>
 37. Higashida RT, Halbach V V., Dormandy B, Bell J, Brant-Zawadzki M, Hieshima GB. New microballoon device for transluminal angioplasty of intracranial arterial vasospasm. AJNR Am J Neuroradiol [Internet]. 1990 [cited 2024 May 14];11(2):233–233. Available from: </pmc/articles/PMC8334684/?report=abstract>
 38. Rheude T, Rai H, Richardt G, Allali A, Abdel-Wahab M, Sulimov DS, et al. Super high-pressure balloon versus scoring balloon to prepare severely calcified coronary lesions: the ISAR-CALC randomised trial: Balloon-based techniques for calcific CAD. EuroIntervention [Internet]. 2021 Aug 1 [cited 2024 Feb 26];17(6):481. Available from: </pmc/articles/PMC9724952/>
 39. SOLARICE™ FAMILIE Non-compliant und semi-compliant Rapid Exchange PTCA-Balloonkatheter.
 40. AngioSculpt PTCA Advanced scoring balloon technology Larger luminal gain Vascular Intervention // Coronary Scoring Balloon Catheter.
 41. Prep Complex Lesions: WOLVERINE Cutting Balloon - Boston Scientific [Internet]. [cited 2024 Mar 17]. Available from: <https://www.bostonscientific.com/en-US/medical-specialties/interventional-cardiology/coronary-interventions/pci-product-portfolio/wolverine.html#accordion-1721015262-item-1429b6b10b>

42. PTA Balloons - Chocolate | Medtronic [Internet]. [cited 2024 Mar 17]. Available from: <https://europe.medtronic.com/xd-en/healthcare-professionals/products/cardiovascular/pta-balloons/chocolate.html>
43. Nitinol Definition & Meaning - Merriam-Webster [Internet]. [cited 2024 Mar 17]. Available from: <https://www.merriam-webster.com/dictionary/nitinol>
44. Chocolate XD® PTCA Balloon Catheter | US | Teleflex [Internet]. [cited 2024 Mar 17]. Available from: <https://teleflex.com/usa/en/product-areas/interventional/coronary-interventions/chocolate-xd-ptca-balloon-catheter/index.html>
45. Desai R, Mirza O, Martinsen BJ, Kumar G. Plaque modification of severely calcified coronary lesions via orbital atherectomy: Single-center observations from a complex Veterans Affairs cohort. *Health Sci Rep* [Internet]. 2018 Dec 1 [cited 2024 Mar 17];1(12):e99. Available from: <https://onlinelibrary.wiley.com/doi/full/10.1002/hsr2.99>
46. Dini CS, Tomberli B, Mattesini A, Ristalli F, Valente S, Stolcova M, et al. Intravascular lithotripsy for calcific coronary and peripheral artery stenoses. *EuroIntervention*. 2019 Oct 1;15(8):714–21.
47. Sugawara Y, Ueda T, Soeda T, Watanabe M, Okura H, Saito Y. Plaque modification of severely calcified coronary lesions by scoring balloon angioplasty using Lacrosse non-slip element: insights from an optical coherence tomography evaluation. *Cardiovasc Interv Ther* [Internet]. 2019 Jul 16 [cited 2024 Mar 17];34(3):242–8. Available from: <https://link.springer.com/article/10.1007/s12928-018-0553-6>
48. Bonaventura K, Schwefer M, Yusof AKM, Waliszewski M, Krackhardt F, Steen P, et al. Systematic Scoring Balloon Lesion Preparation for Drug-Coated Balloon Angioplasty in Clinical Routine: Results of the PASSWORD Observational Study. *Adv Ther* [Internet]. 2020 May 1 [cited 2024 Mar 17];37(5):2210. Available from: </pmc/articles/PMC7467461/>
49. Dayco JS, Osman H, Almas T, Manasrah N, Saleem A, Alhusain R, et al. Major Complications and Failure Modes of the Angiosculpt Scoring Balloon Catheter: Analysis of the MAUDE Database. *Curr Probl Cardiol*. 2023 Apr 1;48(4):101557.
50. WOLVERINE™ Coronary Cutting Balloon™ Product Details - Boston Scientific [Internet]. [cited 2024 Apr 6]. Available from: <https://www.bostonscientific.com/en-US/products/balloons-cutting/wolverine-cutting-balloon.html#>
51. Prep Complex Lesions: WOLVERINE Cutting Balloon - Boston Scientific [Internet]. [cited 2024 Apr 6]. Available from: <https://www.bostonscientific.com/en-US/medical-specialties/interventional-cardiology/coronary-interventions/pci-product-portfolio/wolverine.html#section2>
52. Zhu X, Umezu M, Iwasaki K. Finite Element Analysis of the Cutting Balloon With an Adequate Balloon-to-Artery Ratio for Fracturing Calcification While Preventing Perforation. *Circ Rep* [Internet]. 2021 Jan 8 [cited 2024 Apr 6];3(1):1–8. Available from: <https://www.bostonscientific.com/en-US/medical-specialties/interventional-cardiology/coronary-interventions/pci-product-portfolio/wolverine.html>
53. Krishnaswamy A, Raphael C. Calcified Lesions. In: Bhatt D, editor. *Cardiovascular Intervention: A Companion to Braunwald's Heart Disease*. 2nd ed. Philadelphia: Elsevier Inc.; 2024. p. 222–34.
54. WOLVERINE™ Cutting Balloon Micro-Surgical Dilatation Catheter - Boston Scientific [Internet]. [cited 2024 Apr 6]. Available from: <https://www.bostonscientific.com/en->

- US/products/balloons-cutting/wolverine-cutting-balloon/wolverine-indications-safety-and-warnings.html
55. ROTAPRO™ Rotational Atherectomy System - Boston Scientific - Boston Scientific [Internet]. [cited 2024 Mar 23]. Available from: <https://www.bostonscientific.com/en-US/products/atherectomy-systems/rotapro.html>
 56. Rheude T, Fitzgerald S, Allali A, Mashayekhi K, Gori T, Cuculi F, et al. Rotational Atherectomy or Balloon-Based Techniques to Prepare Severely Calcified Coronary Lesions. *JACC Cardiovasc Interv*. 2022 Sep 26;15(18):1864–74.
 57. Sakakura K, Ito Y, Shibata Y, Okamura A, Kashima Y, Nakamura S, et al. Clinical expert consensus document on rotational atherectomy from the Japanese association of cardiovascular intervention and therapeutics. *Cardiovasc Interv Ther* [Internet]. 2021 Jan 1 [cited 2024 Feb 18];36(1):1. Available from: </pmc/articles/PMC7829233/>
 58. Sakakura K, Taniguchi Y, Yamamoto K, Tsukui T, Seguchi M, Wada H, et al. Comparison of complications with a 1.25-mm versus a 1.5-mm burr for severely calcified lesions that could not be crossed by an intravascular ultrasound catheter. *Cardiovasc Interv Ther* [Internet]. 2020 Jul 1 [cited 2024 Feb 17];35(3):227. Available from: </pmc/articles/PMC7295824/>
 59. ROTAPRO™ System - Indications, Safety, and Warnings - Boston Scientific [Internet]. [cited 2024 Mar 23]. Available from: <https://www.bostonscientific.com/en-US/products/atherectomy-systems/rotapro/rotapro-indications-safety-and-warnings.html>
 60. Shipman JN, Agasthi P. Orbital Atherectomy. *CSI: Cardiology Update 2016* [Internet]. 2023 Jul 25 [cited 2024 Mar 23];307–307. Available from: <https://www.ncbi.nlm.nih.gov/books/NBK563144/>
 61. Diamondback 360 | Abbott [Internet]. [cited 2024 Mar 23]. Available from: <https://www.cardiovascular.abbott/us/en/hcp/products/percutaneous-coronary-intervention/atherectomy-systems/diamondback-360-precision.html>
 62. Shlofmitz E, Jeremias A, Shlofmitz R, Ali ZA. Lesion Preparation with Orbital Atherectomy. *Interventional Cardiology Review* [Internet]. 2019 Dec 1 [cited 2024 Mar 23];14(3):169. Available from: </pmc/articles/PMC6918479/>
 63. ELCA Coronary laser atherectomy catheter | Philips [Internet]. [cited 2024 Mar 24]. Available from: <https://www.usa.philips.com/healthcare/product/HCIGTDELALASR/elca-coronary-laser-atherectomy-catheter>
 64. Intravascular Lithotripsy (IVL) | Shockwave Medical [Internet]. [cited 2024 Mar 30]. Available from: <https://shockwavemedical.com/technology/intravascular-lithotripsy-ivl/>
 65. ON THE +PLUS SIDE. 2023 [cited 2024 Mar 30]; Available from: www.shockwavemedical.com/IFU
 66. Ali ZA, Shin D, Barbato E. Between a Rock and a Hard Place: A Consensus Statement on the Management of Calcified Coronary Lesions. *Journal of the Society for Cardiovascular Angiography & Interventions* [Internet]. 2024 [cited 2024 Apr 7];3:101265. Available from: <https://doi.org/10.1016/j.jscai.2023.101259>.
 67. Barbato E, Gallinoro E, Abdel-Wahab M, Andreini D, Carrié D, Di Mario C, et al. Management strategies for heavily calcified coronary stenoses: an EAPCI clinical consensus statement in collaboration with the EURO4C-PCR group. *Eur Heart J*

- [Internet]. 2023 Nov 1 [cited 2024 Apr 7];44(41):4340–56. Available from: <https://dx.doi.org/10.1093/eurheartj/ehad342>
68. Riley RF, Patel MP, Dawn Abbott J, Bangalore S, Brilakis ES, Croce KJ, et al. SCAI Expert Consensus Statement on the Management of Calcified Coronary Lesions. *Journal of the Society for Cardiovascular Angiography & Interventions* [Internet]. 2024 [cited 2024 Apr 7];3:101259. Available from: <https://doi.org/10.1016/j.jscai.2023.101259>
 69. Neleman T, Ziedses des Plates A, Daemen J. Coronary lithotripsy – a state of the art review - ClinicalKey. *Trends Cardiovasc Med* [Internet]. 2023 May 1 [cited 2024 May 8];33(4):215–22. Available from: <https://www.clinicalkey.com/#!/content/journal/1-s2.0-S1050173822000056>
 70. PTCA-Katheter - Chocolate XD® - Teleflex Medical - Koronar / Ballon [Internet]. [cited 2024 Apr 7]. Available from: <https://www.medicaexpo.de/prod/teleflex-medical/product-77428-917443.html>
 71. AngioSculpt Evo Scoring-Ballonkatheter | Philips Healthcare [Internet]. [cited 2024 Apr 7]. Available from: <https://www.philips.ch/healthcare/product/HCIGTDASEVOBC/angiosculpt-evo-scoring-ballonkatheter#specifications>
 72. WOLVERINE™ Mikrochirurgischer Dilatationskatheter mit Schneidballon | Boston Scientific [Internet]. [cited 2024 Apr 7]. Available from: <https://www.bostonscientific.com/DE-Deutsch/produkte/plaque-modification/wolverine-cutting-balloon.html>
 73. ROTAPRO™ Rotational Atherectomy System - Boston Scientific - Boston Scientific [Internet]. [cited 2024 May 10]. Available from: <https://www.bostonscientific.com/en-US/products/atherectomy-systems/rotapro.html>
 74. Unique Challenges. Individualized Solutions. [Internet]. [cited 2024 Apr 7]. Available from: https://csi360.com/wp-content/uploads/2023/02/EN-7378.A_Coronary-Franchise-Brochure_DIGITAL.pdf
 75. Philips - ELCA coronary laser atherectomy catheter [Internet]. [cited 2024 Apr 7]. Available from: <https://www.philips.co.uk/healthcare/product/HCIGTDELALASR/elca-coronary-laser-atherectomy-catheter>
 76. Intravascular Lithotripsy (IVL) | Shockwave Medical [Internet]. 2024 [cited 2024 May 8]. Available from: <https://shockwavemedical.com/technology/intravascular-lithotripsy-ivl/>

9. CV

Christian Alexander Damm was born on the 23rd of August 1998 in Nuremberg, Germany. While completing his school education, he already discovered his interest in the medical field. Entering the federal voluntary service after finishing high school at the “Melanchthon-Gymnasium Nuremberg” in 2016, this interest was deepened by the tasks in emergency medical services and teaching first aid courses. After his voluntary year, he was employed in the emergency service and applied for medical school in Rijeka, joining the medical studies in 2018. Aside from various professional practices, witnessing coronary interventions in Neumarkt, Germany in 2020 and St. Gallen, Switzerland in 2023 sparked his enthusiasm for Interventional Cardiology.