

DIAGNOSIS AND TREATMENT OPTIONS OF THE PERSISTENT ARTERIAL DUCTUS (BOTALLI) IN NEONATES

Ben Hamo Jimenez, Noa Mai

Master's thesis / Diplomski rad

2024

Degree Grantor / Ustanova koja je dodijelila akademski / stručni stupanj: **University of Rijeka, Faculty of Medicine / Sveučilište u Rijeci, Medicinski fakultet**

Permanent link / Trajna poveznica: <https://um.nsk.hr/um:nbn:hr:184:234226>

Rights / Prava: [In copyright](#)/[Zaštićeno autorskim pravom.](#)

Download date / Datum preuzimanja: **2024-11-07**



Repository / Repozitorij:

[Repository of the University of Rijeka, Faculty of Medicine - FMRI Repository](#)





medri

UNIVERSITY OF RIJEKA

FACULTY OF MEDICINE

**INTEGRATED UNDERGRADUATE AND GRADUATE UNIVERSITY STUDY OF
MEDICINE IN ENGLISH**

Noa Mai Ben Hamo Jimenez

**DIAGNOSIS AND TREATMENT OPTIONS OF THE PERSISTENT
ARTERIAL DUCTUS (BOTALLI) IN NEONATES**

GRADUATION THESIS

Rijeka, June 2024



medri

UNIVERSITY OF RIJEKA

FACULTY OF MEDICINE

**INTEGRATED UNDERGRADUATE AND GRADUATE UNIVERSITY STUDY OF
MEDICINE IN ENGLISH**

Noa Mai Ben Hamo Jimenez

**DIAGNOSIS AND TREATMENT OPTIONS OF THE PERSISTENT
ARTERIAL DUCTUS (BOTALLI) IN NEONATES**

GRADUATION THESIS

Rijeka, June 2024

Thesis Mentor: Assist. Prof. Lah Tomulić

The graduation thesis was graded on 16.06.2024 in Rijeka, before the Committee composed of the following members:

1. Assoc. Prof. Iva Bilić Čače, MD (President of Committee)
2. Assist. Prof. Ana Milardović, MD
3. Prof. Srđan Banac, MD

The graduation thesis contains 39 pages, 4 figures, 0 tables, 49 references.

Table of Content

- Introduction..... 7**
 - Background and definition..... 7
 - Neonatal cardiovascular system..... 8
 - Significance of PDA 11
- Aims and objectives 12**
- Literature review 12**
 - Circulation before and after birth..... 12
 - Epidemiology 14
 - Pathophysiology and influencing factors of persistence..... 14
 - Clinical manifestation 15
 - Diagnostic modalities..... 16
 - Current treatment methods..... 21
 - Complications and consequences 28
 - Prognosis and outcomes..... 30
- Discussion..... 32**
- Conclusion 33**
- Summary..... 34**
- Literature..... 35**
- Curriculum Vitae 39**

List of abbreviations and acronyms

AKI – Acute Kidney Injury

BNP – Brain-type Natriuretic Peptide

BPD – Bronchopulmonary Dysplasia

cAMP – Cyclic Adenosine Monophosphate

COX – Cyclooxygenase

COX-2 – Cyclooxygenase-2

CT – Computed Tomography

CYP – Cytochrome P450

DA – Ductus Arteriosus

DOL – Days of Life

ECG – Electrocardiography

EPO – Erythropoietin

EP1-4 – E-type Prostanoid Receptor 1-4

hsPDA – Hemodynamically Significant Patent Ductus Arteriosus

IsoPs – Isoprostanes

IVH – Intraventricular Hemorrhage

LOX – Lysyl Oxidase

MDCT – Multi-Detector Computed Tomography

NEC – Necrotizing Enterocolitis

NICU – Neonatal Intensive Care Unit

NSAID – Non-Steroidal Anti-Inflammatory Drug

NTpBNP – N-terminal pro-BNP

PaO₂ – Partial Arterial Oxygen Pressure

PEEP – Positive End-Expiratory Pressure

pBNP – pro- Brain-type Natriuretic Peptide

PDA – Persistent Ductus Arteriosus

PGE₂ – Prostaglandin E₂

PKA – Protein Kinase A

PLIC – Post Ligation Cardiac Syndrome

RDS – Respiratory Distress Syndrome

ROS – Reactive Oxygen Species

TPN – Total Parenteral Nutrition

uIPs – Urinary isoprostanes

VEGF – Vascular Endothelial Growth Factor

VLBW – Very Low Birth Weight

Introduction

Background and definition

Persistent Ductus Arteriosus (PDA) is a common congenital heart defect that presents significant challenges in neonatal care, especially in preterm infants. The ductus arteriosus (DA), which connects the pulmonary artery to the aorta and allows blood to bypass the developing lungs, is an essential fetal blood channel. This vessel usually closes on its own within the first 72 hours after birth as part of the normal body process switching from fetal to neonatal circulation. If the DA is left open or patent, it causes PDA, a disorder that, if left untreated, can have serious consequences. Persistent closure of the DA demands functional processes, such as muscle contraction, and anatomical mechanisms, including morphological and molecular remodelling. It takes complex physiological procedures to close the DA. Within hours of birth, the placental vasodilators withdraw, the circulating prostaglandin E2 (PGE2) significantly decreases, and the newborn's initial breaths increase arterial oxygen partial pressure (PaO₂), all of which contribute to functional closure of the DA (1). Anatomic closure, on the other hand, is more complicated and involves structural alterations such as the migration of smooth muscle cells, the breakdown of the inner elastic layer, and the deposition of the extracellular matrix, which eventually forms a fibrous ligamentum arteriosum. Numerous factors, such as the infant's gestational age and general health status, can affect these processes (2). PDA, a congenital cardiac abnormality that occurs in 10–21 cases of congenital heart disease, is caused by irregularities in the DA's closing operations (3). Hemodynamically significant PDAs (hsPDAs) are associated with multiple factors that impact the shunt volume, ductal size, blood pressure variations, additional clinical symptoms, echocardiographic results, and the effect on other organs. The incidence of PDA in full-term infants is only around 5–10% (4). A PDA is firmly connected and, thereby, more common in preterm infants (4). This is attributed to the immaturity of the processes that control DA closure in preterm newborns. As a result, PDA may cause various hemodynamic abnormalities, such as elevated pulmonary blood flow, reduced systemic blood flow, and possibly even congestive heart failure. Other challenges, such as intraventricular hemorrhage (IVH), necrotizing enterocolitis (NEC), and bronchopulmonary dysplasia (BPD) may worsen as a result of these disruptions (5). PDA management is still a highly discussed and researched subject. The three main categories of treatment options include surgery, medication, and conservative methods. To reduce the symptoms and effects of PDA, conservative therapy may include fluid restriction and respiratory assistance (8). Non-

steroidal anti-inflammatory medications (NSAIDs) like ibuprofen or indomethacin are commonly used as pharmacological therapies because they block prostaglandin synthesis and encourage DA closure (1). Despite their widespread effectiveness, these medications have the potential to cause adverse effects, including gastrointestinal issues and renal impairment (6). When pharmaceutical treatments prove to be unsuccessful or contraindicated, surgical options are taken into consideration. For many years, the only effective treatment for PDA was surgical ligation, which is typically an invasive procedure that involves physical closure of the DA. Less invasive methods like transcatheter device closure have become increasingly common in recent times. These procedures involve inserting a closure device through a catheter, which provides a less traumatic alternative to open surgery and has shown encouraging efficacy and safety results (7). Developments in diagnostic techniques have also enhanced PDA management. The main diagnostic method for PDA is echocardiography, which enables medical professionals to evaluate the ductus size and hemodynamic relevance (2). In conclusion, PDA is a severe clinical problem in the field of neonatology, particularly with premature babies. Even though spontaneous closure frequently occurs, DA management necessitates carefully weighing the advantages and disadvantages of different therapeutic methods. Sustained investigation is essential for improving approaches to PDA diagnosis and treatment, ultimately leading to better outcomes for impacted neonates. This thesis explores the most recent developments and potential future paths in PDA research while offering a thorough analysis of the field's existing diagnostic and treatment modalities.

Neonatal cardiovascular system

The embryonal vascular system changes significantly during pregnancy, with the last changes occurring hours after birth. It is a system perfectly adapted to the conditions inside the mother's womb (1).

Cardiac development is a complex process, which is the first to develop. It involves high molecular signalling, ensuring the timely spatial configuration alterations and actual formation of structures. Genetic or environmental disruptions can interfere with the processes and contribute to the development of congenital heart diseases. The complex progression of the cardiovascular system in embryonic development starts with the wandering of cardiac progenitor cells toward the primitive streak, where they later mature into cardiac myoblasts – undifferentiated cells capable of forming muscle tissue. The primitive streak, located in the posterior part of the embryo, plays a crucial role in the embryonal transformation from a one-

dimensional structure to a multi-dimensional one, giving rise to the three germ layers that will form following embryonic formations. The endoderm, considered the innermost layer, will develop into the digestive system and internal organs. The mesoderm, the middle layer, will emerge into muscular organisations, while the ectoderm, the outermost layer, will form the nervous system and skin. Within the mesoderm, vasculogenesis occurs, a process in which blood islands form vascular arrangements. The coalescence of these blood islands creates the region of embryonic tissue that gives rise to the heart and related structures, which are initially horseshoe-shaped and enveloped by cardiac myoblasts. The top part matures into primitive ventricles and later, the whole structure of the cardiogenic field undergoes a cephalocaudal rotation, ultimately forming a primitive heart tube. It is already connected with vascular structures to secure the respectable development of the cardiac system. During the developmental process, blood is directed into the dorsal part of the aorta via the cranial part of the heart tube, while the channel for venous return is managed by the caudal portion. During this phase, not only does cephalocaudal rotation occur, but also other configuration changes. Relocation of the heart into the thorax is promoted by an anterior shift of the buccopharyngeal membrane and neural tube closure. The primitive heart tube incorporates the endocardium, developing into the endothelial layer; the myocardium equivalent to the muscular bulk; and the external embryonic heart surface is formed by the visceral pericardium, comprising three layers that mirror the structure of the adult human heart (8).

Significant changes in the heart tube occur between approximately days 22 to 23 of embryonic development, resulting in its elongation and the assumption of a cardiac loop configuration. This loop formation involves the caudal portion bending dorsocranially and to the left while the cranial portion bends ventrocaudally and to the right. Typically, this entire process of cardiac loop formation takes about five days, completing by day 28 (8). The heart tube will undergo multiple transformations and divisions as development continues until the mature heart is formed. Developmental processes, such as the formation of the trabeculated portions of the right ventricle, formed by the proximal part of the heart tube, occur. The distal section becomes the truncus arteriosus, which gives rise to critical structures like the proximal portions of the aorta and pulmonary artery, while the central segment develops into the conus cordis, which acts as a precursor for the ventricular outflow tracts. As the loop formation nears completion, trabeculated regions emerge from smooth muscle walls, acting as primitive ventricles. However, their formation is linked to embryonic lethality. Between days 27 and 37, septa form through the fusion of endocardial cushions, originating in crucial structures

such as aortic and pulmonary channels, atrioventricular canals and valves, and atrial and ventricular septa.

At this time, a crest-like arrangement called the septum primum develops from the roof of the common atrium. Another small opening, the ostium primum, is created as the lower portion of the septum primum shifts slightly towards the endocardial cushions. While the endocardial cushions eventually merge, physiological apoptosis leads to perforations, forming the ostium secundum. This opening is mandatory for oxygen supply, facilitating blood flow between the primitive atria. As development progresses, the right atrium expands, giving rise to the septum secundum, which partially covers the ostium secundum, forming the foramen ovale (8). Following birth, elevated oxygen levels lead to the prompt closure of the foramen ovale. Further during the development, a single pulmonary vein evolves near the septum primum, integrating into the left atrium. The atrioventricular canal forms cushions which fuse and eventually divide the canal into left and right orifices around week four of neonatal development. The atrioventricular valves evolve from surrounding edges composed of mesenchymal tissue and are connected to papillary muscles via chordae tendineae. Later on, truncal swelling leads to the division of the aorticopulmonary septum, creating aortic and pulmonary channels and semilunar valves. Swelling of the conus leads to the division of conus cordis creating right and left ventricles, which serve as primitive outflow tracts. The ventricular septum is composed of a muscular part, which is created by the expansion and merging of the ventricular walls and a membranous part formed by the closure of the interventricular foramen. The sinoatrial node, known as the natural pacemaker of the human heart, generates electrical impulses and establishes the normal rhythm and heart rate. In the early stages, it is initially situated in the caudal region of the primitive heart tube. Progressing through developmental changes, the pacemaker role shifts to the sinus venosus, found between the two venae cavae, within the embryonic heart. When the sinus venosus merges with the right atrium, it becomes the sinoatrial node's point of origin (8).

Vascular development involves two main mechanisms: vasculogenesis, where vessels form through the coalescence of angioblasts, and angiogenesis, where vessels sprout from existing ones. Major vessels like the dorsal aorta or the cardinal veins primarily develop through vasculogenesis, while the rest forms via the second mechanism. The vascular endothelial growth factor (VEGF) and other growth factors play an important essential role in these processes.

Around week four and five, the arterial system changes significantly. The formation of

pharyngeal arches initiates the development of aortic arches, each paired with its own cranial nerve and artery. These arches are embedded in the mesenchyme of the pharyngeal arches and originate from the aortic sac, the farthest portion of the truncus arteriosus. The arches subsequently give rise to the left and right dorsal aortae. While initially paired, the dorsal aortae fuse caudally, forming a single vessel. The complex system is influenced by the pharyngeal arches and the vessels that are connected to them, which emerge in a cranial to caudal order. Significant transformations, including the disappearance of the first and second aortic arches, the persistence of the third, fourth, and sixth arches, and the establishment of a definitive arterial pattern, occur by day 27. Additionally, vitelline, and umbilical arteries undergo development, contributing to the supply of derivatives of the foregut, midgut, and hindgut. During the fifth week, three pairs of major veins can be differentiated. The cardinal veins make up the primary venous drainage system; the vitelline veins, transport blood from the yolk sac to the venous sinus; and the umbilical veins, which begin in the chorionic villi bring oxygenated blood to the embryo (9).

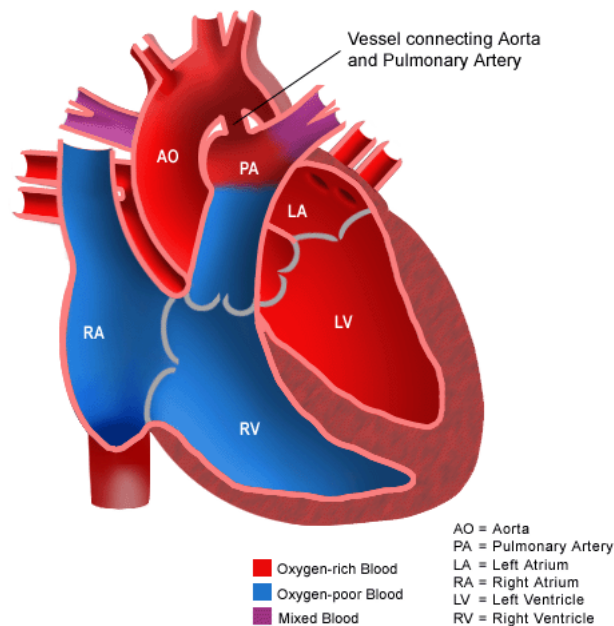


Figure 1. The graphic shows the anatomical connection of the pulmonary artery and the aorta through the PDA. (10)

Significance of PDA

PDA is a severe illness that affects a newborn's immediate health as well as their long-term cardiovascular function. To avoid problems and enhance patient outcomes, early detection

and timely action are essential. The management of PDA has been significantly improved by developments in both pharmaceutical and surgical treatments, highlighting the significance of ongoing research and innovation in this area.

Aims and objectives

The thesis aims to comprehensively address critical aspects of an open PDA, striving to advance both diagnostic and therapeutic outcomes for affected infants. The primary objective is to highlight the epidemiology and clinical manifestation of the condition, as well as the pathophysiology and hemodynamic consequences, for a better understanding. Quintessential of this review is the evaluation of diagnostic approaches, with the intention of appraising existing modalities, such as imaging techniques and biomarkers, but also investigating the newest strategies. Another elementary part focuses on the analysis of pharmacological and surgical interventions, which includes the safety and efficacy of pharmaceutical agents like indomethacin and ibuprofen, as well as assessing the outcomes of surgical methods such as ligation and transcatheter closure. Additionally, the thesis will include emerging therapies, presenting forward-looking perspectives in that field. Furthermore, the research is aiming to contribute to the ongoing evolution of diagnostic and therapeutic approaches for infants with an open PDA.

Literature review

Circulation before and after birth

During pregnancy, the embryo relies on the physiology of the DA. It is a shunt between the pulmonary artery and the aorta, which acts as one of the two routes to bypass the lungs. Throughout fetal development, the main gas exchange occurs in the placenta, from which maternal blood, with a saturation of around 80%, enters via the umbilical vein into the fetal circulation. The oxygenated blood in the fetus passes the ductus venosus located in the liver and is transported further to the right atrium via the inferior vena cava. However, a small amount of blood enters the sinusoids of the liver due to a sphincter mechanism with the target of mixing portal and umbilical circulation. Another mixing occurs in the right atrium, in which desaturated blood coming from the lower limbs meets with the placental blood. From

here, the main route continues by the second mechanism necessary for bypassing the lungs considered as foramen ovale. The foramen ovale is formed by small holes in the septum primum and secundum functioning as walls separating the right and left ventricles. A small portion of blood is kept in the right atrium by the crista dividens, a small structure at the inferior margin of the septum secundum. The deoxygenated blood returning from the head and arms through the superior vena cava mixes with the remaining blood in the right atrium. This mixture then enters the right ventricle, and considering a higher resistance of the pulmonary vessels during fetal development, most of the blood passes straight through the DA and enters the descending aorta taking its path via umbilical arteries to be reoxygenated in the placenta. The remaining blood which did not pass through the DA reaches the lungs via the pulmonary artery to secure an adequate supply and assure growth and maturation (9). From here, the way of return is over the pulmonary vein into the left atrium, following the left ventricle into the aorta.

Hours after birth, the circulatory system changes due to the interruption of the placental blood flow and initial breathing of the newborn. These two mechanisms lead to the contraction of smooth muscles situated in the walls of blood vessels and ducts. Primarily, a functional closure of the DA occurs within minutes after birth ensuring fetal survival. The complete anatomical closure due to fibrous proliferation can last over two to three months. The umbilical arteries are the first to close, followed by the umbilical veins, the DA and the foramen ovale (9).

Within the first 12-24 hours after birth, the DA will spontaneously close due to increased oxygen levels and decreased PGE₂ production, leading to an anatomical change in the smooth muscles (4). Those muscles within the vessel walls are sensitive to oxygen, acetylcholine, bradykinin, and endothelin released from the lungs during initial inflation. Commonly, the DA becomes fibrous within the next 14 days after birth and is closed entirely. Nevertheless it can remain patent with the need for therapeutical treatment (1).

The closure of the foramen ovale is similarly closed by the mechanism of a pressure change induced by the first breaths of a newborn. The left atrium pressure increases while on the right side, the pressure decreases, leading to the adhesion of septum primum and septum secundum (9). This closure, however, is reversible and can take about one year to entirely fuse, although around 25% of the population live with a patent foramen ovale (11).

Epidemiology

Physiologically, the patent DA will close in a term infant during the first 72 hours after birth; this accounts for approximately 90-95%. The prevalence is inversely proportionate to gestation and birth weight in preterm newborns. In a newborn with a gestational age below 28 weeks, the incidence of PDA rises to 70% (1). Furthermore, a very low birth weight (VLBW) of about 1000 grams is associated with the highest risk for a persistent DA and is very common. Generally, PDA is associated with around five to ten percent of congenital heart diseases (1)(3). Infants with neonatal respiratory distress syndrome (RDS), those who were not given prenatal corticosteroids, newborns presenting metabolic acidosis or who were exposed to chorioamnionitis are also less likely to experience ductal closure (12). Furthermore, risk factors include fetal alcohol syndrome, congenital rubella, and Down syndrome (8)(9).

Pathophysiology and influencing factors of persistence

During fetal development, the embryo is highly dependent on the physiological organisation of the vascular system, which becomes, if no chemical and anatomical changes occur, a serious pathological condition after birth. The pathophysiology behind the PDA depends mainly on the cellular action of prostaglandin E₂ and genetic factors that lead to hemodynamic consequences. Throughout fetal development, PGE₂ is continuously synthesised by Cyclooxygenase-2 (COX-2) locally in the DA, which causes its patency. COX-2 is an isoenzyme that is essential for the synthesis of various prostaglandins. The synthesis happens by converting arachnoid acid to prostaglandin G₂ by a cyclooxygenase reaction, which is followed by a peroxidase reaction creating prostaglandin H₂, from which isomerases like PGE₂ are created (10)(11). PGE₂ interacts with four different E-type prostanoid receptors (EP1-4) through paracrine and autocrine mechanisms. Angiogenesis mediated by COX-2 and PGE₂ is primarily driven by the binding of PGE₂ to EP2 and EP4 receptors (17). EP4 can significantly inhibit elastogenesis and decrease the amount of lysyl oxidase (LOX) protein, which catalyses elastic fiber formation via the cross-linking enzyme necessary for duct closure. Furthermore, PGE₂-EP4-cyclic AMP (cAMP)- protein kinase A (PKA) increases hyaluronan-mediated intimal thickening in the DA, which plays an important role since hyaluronan accumulation promotes smooth muscle cell migration into the subendothelial layer. Additionally, cAMP activates Epac, a nucleotide exchange protein that regulates the activity of proteins mandatory for smooth muscle cell migration independent of

hyaluronan accumulation. Disruption in the synthesis, catalysation, formation, or accumulation can result in the pathological condition of a PDA, where the organism is unable to spontaneously close the ductus arteriosus (15).

Clinical manifestation

Depending on the type of shunt, the clinical signs and symptoms can vary. The more common left-to-right shunt is linked to the classic PDA presentation, in which the blood follows a pressure gradient from the aorta's high pressure to the pulmonary artery's lower pressure (1). The pulmonary blood flow of the left-to-right shunt type is elevated, which can result in pulmonary overcirculation and symptoms including heart failure, pulmonary edema, and respiratory distress. It is common in preterm infants and often results in hemodynamic instability. The right-to-left shunt, on the other hand, occurs less frequently and usually indicates more complex cardiac pathology or elevated pulmonary vascular resistance (3). It is associated with significant pulmonary hypertension, where the pressure in the pulmonary artery exceeds the pressure in the aorta, reversing the direction of blood flow. The right-to-left shunt is often related to cyanosis, a bluish skin discoloration, due to a lack of oxygen, because the deoxygenated blood bypasses the lungs and enters the systemic circulation (3). Regardless of shunt direction, the most significant instance of a PDA is a machinery murmur of the heart identified during auscultation. It is a distinctly loud and continuous systolic and diastolic murmur which is loudest at S2 and best heard in the left infraclavicular region. Additionally, a PDA is associated with characteristic bounding peripheral pulses, due to an increased cardiac output of as much as 25% (18). A wide pulse pressure caused by the typical decreased diastolic pressure has been associated with a PDA for a long time, but recent studies confirmed that it is considered a normal finding in the first week of life and has no correlation between patency and severity of a PDA (19). Longer-lasting low diastolic pressure causes hypotension and systemic hypoperfusion which can result in cardiac hypertrophy, renal dysfunction, feeding intolerance, unexplained metabolic acidosis and hemorrhage, depending on the affected organ (20). Moreover, hypoperfusion can lead to volume overload and the onset of congestive heart failure. A common finding caused by excessive blood flow in the pulmonary vasculature is pulmonary edema, potentially leading to respiratory failure. Newborns may also suffer from symptoms like recurrent episodes of apnea and tachypnea and require ventilator support (5).

High-pressure shunts or generally untreated congenital heart diseases are a risk factor for

developing infective endocarditis, which is rare but a serious complication. An additional complication is the Eisenmenger syndrome showing signs of cyanosis and congestive heart failure (21).

Diagnostic modalities

Diagnostic and laboratory testing further enhance the clinical picture, assisting in confirming the suspected diagnosis of a PDA in newborns showing symptoms of a high-pressure shunt. Diagnostic methods include clinical examination, chest radiography, echocardiography, electrocardiography (ECG), cardiac catheterization, and angiography, as well as biomarkers. During clinical examination, findings include the characteristic machinery murmur, which has the highest specificity but lacks responsiveness for a patent DA. As well as hypotension, bounding peripheral pulses and tachypnea or apnea.

Cardiac imaging plays a major role in the diagnosis of patent DA. With the assistance of chest radiography, signs of pulmonary overcirculation showing edema and cardiac hypertrophy may become visible.

The gold standard for PDA diagnostics is echocardiography, which uses sound frequencies that are inaudible to humans to produce images of the heart and vascular systems using ultrasonography technology. A transducer is used in this process to transform mechanical energy into electrical energy and vice versa using piezoelectric crystals (22). The reflected ultrasound echoes construct cardiac images, which are affected by factors like air, bone, or foreign bodies. Functional echocardiography requires ultrasound machines with various modes and Doppler capabilities, along with electrocardiogram gating for assessing systole and diastole. Several transducers with different frequencies are required for imaging at distinct depths, because of the variance in patient size in pediatrics, ranging from newborn to teenager. Newborns and small children rely on high-frequency probes because they focus on a depth of four to five centimeters. In older children or adults, low-frequency probes are considered since they have the ability to focus at a depth of 12-16 centimeter (23). A mid-range transducer is necessary for use with toddlers or small children. In summary, functional echocardiography offers rapid, dependable, and immediate information that is crucial for patient care. It is a non-invasive bedside examination that evaluates cardiac anatomy, estimates pressure gradients across valves and vessels and intracardiac pressures, determines blood flow direction, assesses filling pressure and fluid responsiveness, and measures pressure gradients across defects. Additionally, it provides physiological insights that can profoundly

impact patient management in the intensive care unit and proves invaluable for monitoring therapeutic interventions (23).

Referring to the diagnostic measures in PDA echocardiography provides accurate information to determine the exact location and size of the defect. The diameter of the PDA is typically measured as its narrowest point during end-systole and either expressed as an absolute value in milliliters or referenced to the diameter of the left pulmonary artery or patient body weight (milliliter per kilogram). Assessment of the shunt pattern involves analyzing the directionality and velocity during diastole and systole. For a PDA to result in significant shunting for systemic to pulmonary circulation, the flow must be unrestrictive and left-to-right. PDAs with a diameter less than 1.5mm are considered small due to their typically restrictive nature, causing only a minor increase in pulmonary circulation, and rarely exhibiting echocardiographic signs of a high-volume shunt. Further classification of PDAs with a diameter of at least 1.5 mm as moderate or large is based on the increasing likelihood of a high-volume shunt (22). Additionally, an increased left ventricular and left atrial enlargement indicates an hsPDA (1). Apart from that, various studies have highlighted different echocardiographic criteria for defining an hsPDA, including references to the ratio of the left atrium to the aorta or the importance of the ductal diameter. However, these criteria primarily indicate the presence of a high-volume shunt rather than its clinical significance (22).

Moreover, a prospective study carried out involving 30 cases with suspected PDA revealed that cardiac multi-detector computed tomography (MDCT) angiography outperformed echocardiography in both the detection and evaluation of PDA. While echocardiography detected PDA in 28 out of 30 cases, MDCT successfully identified PDA in all 30 cases, a finding confirmed by cardiac catheterization and/or surgery. This diagnostic method demonstrates a sensitivity and specificity of 100% for detecting PDA. Origins were found to be the innominate artery in four cases, the inferior surface of the aortic arch in eleven cases, and the aortic isthmus in fifteen cases, being the most common location for a defect. The most prevalent morphological type was cone-shaped, followed by tubular, elongated, complex, and window-shaped being the least common.

MDCT serves as a noninvasive imaging tool for assessing complex cardiovascular morphology, particularly extracardiac associations, the aortopulmonary collateral vessels and the anatomy of the pulmonary artery. MDCT angiography displays exceptional qualitative and quantitative information about various defects. While conventional angiography remains the gold standard for cardiac imaging, it carries the risk of invasiveness, potentially leading to

mortality of up to 1% of newborns (24). The diagnostics of PDA and the planning of percutaneous closure are significantly enhanced by the capabilities of MDCT. It assesses essential information such as morphology and size and potential complications, including thrombosis, aneurysms, and calcifications. With millisievert (mSv) doses and short acquisition times, MDCT is now easily achievable, reducing the amount of pediatric imaging that requires general anesthesia. In the management of clinically unstable children, especially in intensive care settings, it is shown to be particularly beneficial. Multiplanar and three-dimensional images derived from CT data are effective in illustrating both normal and pathologic cardiovascular structures in patients with congenital heart disease (24).

Biomarkers represent an alternative diagnostic approach, represented by brain-type natriuretic peptide (BNP) and N-terminal pro-BNP (NTpBNP). BNP, a member of the natriuretic peptide family alongside structurally similar peptides, share a distinctive biochemical structure characterized by an amino-acid ring and a disulfide bridge between two cysteine molecules. The primary source of BNP synthesis and secretion is the ventricular myocardium. Initially produced as a prehormone (proBNP), BNP undergoes cleavage upon release into the bloodstream yielding two fragments: the biologically active amino acid BNP, representing the C-terminal fragment, and the inactive amino acid N-terminal fragment NT-proBNP, both continually present in blood. Increased synthesis and secretion of both peptides are primarily triggered by myocardial wall stress. BNP has a half-life of 20 minutes, while NT-proBNP has a half-life of 120 minutes, resulting in approximately six times higher serum levels than BNP (25). Furthermore, a study demonstrated that the serum NT-proBNP concentration could accurately predict the onset of BPD or death in very preterm infants with PDA, regardless of the persistence of PDA (26).

In summary, BNP and NTpBNP are biomarkers that can be used to estimate a hsPDA or to triage newborns at risk of PDA for screening echocardiograms on the second or third day of life.

Isoprostanes (IsoPs) are a distinct class of prostaglandin-like chemicals which are mainly considered as biomarkers of oxidative stress. They arise *in vivo* by the peroxidation of arachidonic acid triggered by free radicals, using a nonenzymatic mechanism (27).

IsoPs are highly connected to ductal constriction or dilation, depending on the concentration of thromboxane and EP4 receptors. A study by Chen *et al.* pointed out that oxygen exposure increases IsoPs levels in newborn mouse lungs by activating thromboxane A2 receptors, leading to the constriction of DA. Thromboxane A2 is a well-known vasoconstrictor that is

triggered during periods of tissue damage and inflammation, it also features prothrombotic qualities since it promotes platelet activation and aggregation (28). Simultaneously it was observed that by the mediation of PGE2 receptor EP4 IsoPs can induce vasodilation of preterm isolated DA. Either way, these processes lend plausibility to the idea that oxygen and oxidative stress have a physiopathological effect during the transitional phase of the circulatory system in both sick and healthy newborns. Furthermore, considering that preterm newborns produce a lot of reactive oxygen species (ROS) and have an underdeveloped antioxidant system, diseases like NEC, IVH, and BPD are mostly associated with oxidative stress. On the other hand, in low to moderate concentrations, ROS contribute physiologically to the cellular and tissue maturation that occurs during the fetal and neonatal stages, leading to the conclusion that free radicals can be both harmful and helpful substances (29).

Another study comes to the conclusion that early assessment of urinary isoprostanes (uIPs) is a trustworthy, non-invasive biomarker for predicting hsPDA in premature newborns, thereby facilitating prompt diagnosis, treatment, and management of the condition (30). The study is concentrated on newborns with RDS who are between 23 and 33 weeks of gestational age. To test uIP levels, researchers took urine samples on the second and tenth days of life (DOL). To diagnose hsPDA, they performed echocardiography 24 to 48 hours after birth. Of the 60 newborns included in the study, 55% had hsPDA. Ten percent needed surgery, and forty-five percent needed ibuprofen therapy for closure. The findings demonstrated a substantial drop in uIPs levels between the second and tenth DOL. Higher uIPs levels on the second DOL were substantially linked to the development of hsPDA, according to adjusted regression analysis. With 82% sensitivity and 73% specificity, an uIPs threshold of 1627 ng/mg of creatinine was found to predict hsPDA (30).

In conclusion, uIPs, which can be easily measured in urine samples, are particularly good PDA biomarkers and help predict the start of hsPDA in premature neonates (29).

The majority of biomarkers associated with PDA persistence are inflammatory markers, such as different interleukins (IL). IL-6, -8, and -12 have pro-inflammatory functions, which means they encourage diseases. For instance, IL-6 promotes vascular remodelling and pulmonary morbidity, while IL-8 is also linked to angiogenesis. In addition to its pro-inflammatory properties, IL-12 has anti-angiogenic properties. However, IL-10 is associated with the anti-inflammatory function of pulmonary morbidity and vasculature remodelling. In one study, the persistence of PDA was linked to high levels of the previously mentioned inflammatory

markers, with the exception of IL-12 (31). This data may also suggest a connection to early pulmonary morbidity. In the same study, erythropoietin (EPO) was considered a biomarker for a persistent PDA and failure of pharmacological therapy, suggesting its potential as a guiding tool for treatment decisions. Briefly, EPO is a hormone with vasoconstrictive properties and, most importantly, stimulates erythropoiesis. According to the study, postnatal circumstances, especially hypoxia, have an impact on EPO levels. Notably, there were strong negative associations between median pH and EPO levels, confirming that postnatal hypoxia, as opposed to prenatal circumstances, is the primary factor influencing EPO levels. This gives evidence to the theory that EPO levels on the second DOL are more indicative of postnatal than prenatal problems. Recombinant EPO has also been related to increased airway resistance and lung inflammation in earlier investigations, which is consistent with the link between high EPO levels and subsequent lung illness in very preterm newborns.

Early detection of high EPO levels could assist in the identification of PDA infants who are at a lower risk of spontaneous ductal closure. Additionally, it may provide quick pharmaceutical treatments, avoiding the need for recurrent echocardiograms and enabling surgical treatment in cases where medicine is unlikely to be beneficial. Besides many limitations of the study, including the small number of participants and single-center design, it highlights the potential of EPO as a predictive biomarker for PDA. In order to assess the clinical usefulness of EPO and other biomarkers in the treatment of PDA in preterm newborns, as well as to comprehend the biological mechanisms underlying these relationships, more research is required. Gaining insight into this connection has the potential to greatly improve clinical procedures and the outcomes for these susceptible patients (31).

The diagnosis of PDA in newborns is improved by combining clinical examination, advanced imaging techniques, and biomarker analysis. The gold standard for PDA diagnosis is still echocardiography, which offers comprehensive and crucial information about the abnormality. This is complemented by further anatomical and morphological information provided by chest radiography and MDCT angiography. Furthermore, biomarkers help guide early and targeted therapeutic decisions including BNP, NTpBNP, EPO, and IsoPs. These biomarkers provide vital information on the physiological and pathological status.

Concluding, a comprehensive diagnostic approach guarantees accurate diagnosis and effective management of PDA, improving outcomes for affected newborns.

A clinical score for recognizing and monitoring hspDA was the goal of a study published in

2017 by *Frontiers in Pediatrics*. Clinical indications were noted and compared to echocardiographic results in a group of 154 preterm infants, yielding a brief clinical score with 84% sensitivity and 80% specificity. This non-invasive index may help identify preterm infants that need PDA treatment by enabling accurate diagnosis and focused echocardiography use. The score is derived from six clinical and echocardiographic criteria. The left atrial-to-aortic root velocity ratio (2 points for 1.5 m/s or 1 point for 1.3-1.5 m/s) and the ductal diameter (2 points for 1.5mm, 1 point for 1.0-1.5mm) are two of the echocardiological measures. An additional criterion for scoring is the Doppler flow pattern, where a continuous or pulsatile flow is worth one point and an end-diastolic reversal is worth two points. Two points are given for clinical heart failure symptoms; if any are present, no points are expressed. Every instance of elevated oxygen consumption and systemic hypoperfusion must be recorded with one point; absences result in zero points. Typically, newborns with hsPDA scored two or higher points. The overall score may drive clinical decision-making for additional care and treatment by estimating the likelihood of hsPDA (32).

Current treatment methods

The best way to treat a PDA is still up for debate; anyhow, there are several approaches, including conservative methods like cooling or feeding modalities, pharmaceutical approaches, and surgery.

Conservative care may be adequate to support a gestationally more developed infant until the duct closes on its own. In order to treat pulmonary edema, conservative therapy involves carefully limiting fluid intake (110 to 130 ml/kg/d while observing urine output) and raising peak expiratory pressure (PEEP). Since there is little proof that diuretics enhance outcomes for extremely premature children, they could prevent PDA closure, and they might create electrolyte imbalances that can be challenging to treat, diuretics are contentious.

Preterm newborns with a symptomatic PDA benefit from pharmacological treatment with medication like ibuprofen, indomethacin, or acetaminophen/paracetamol (1).

Pharmaceutical therapy is mainly correlated to cyclooxygenase inhibitors like ibuprofen and indomethacin. The classes of COX inhibitors, which cover a big therapy spectrum, includes aspirin, NSAIDs, and COX-2 selective NSAIDs. Within the class of NSAIDs, indomethacin and ibuprofen are most effective in the closure of a persistent PDA by inhibiting the cyclooxygenase enzyme. As a consequence of this inhibition, arachidonic acid cannot be converted into prostaglandins, which lowers vasodilation essential in maintaining the DA

open (33). Generally, it has been demonstrated that ibuprofen administered orally and intravenously is equally effective. Ibuprofen has to be given three times, 10 mg/kg for the first dose, 5 mg/kg for the second dose given after 24 hours, and 5 mg/kg for the third dose given after another 24 hours (34).

Indomethacin is given intravenously to reduce the risk of gastrointestinal bleeding (18). The dosages comprise 0.2 mg/kg first, then again at 0.1–0.2 mg/kg depending on the infant's age and response, and finally at 0.1–0.2 mg/kg after a further 12–24 hours while keeping the same parameters in mind (34). When compared side by side, indomethacin and ibuprofen show comparable efficacy (70%) for the first three doses of treatment. About 25% of cases, particularly in the most preterm newborns, reopen after treatment. Some suggest administering an additional dose of indomethacin 24 hours following the third dose due to the high rate of reopening (18). Anyhow, it is important to distinguish between immediate and long-term impacts of the pharmacological treatment with indomethacin and ibuprofen. The short-term effects of ibuprofen medication include no noticeable changes to cerebral, mesenteric, or renal blood flow, as well as an improved renal safety profile with less rise in serum creatinine and less decrease in urine output. Studies on the long-term effects of ibuprofen have revealed an increased incidence of chronic lung disease (6). It also carries the potential risk of bilirubin displacement, which, in the event that serum ibuprofen concentrations are elevated, can result in kernicterus. In general, ibuprofen has less well-established long-term neurodevelopmental data than indomethacin. On the other hand, compared to ibuprofen, indomethacin causes a higher incidence of oliguria, decreased cerebral, mesenteric, and renal blood flow, and increased renal toxicity in the short term. Long-term impacts include a decreased risk of developing chronic lung disease and a lower incidence of brain injury known as periventricular leukomalacia, which improves neurodevelopmental outcomes, especially in male newborns (6).

Acetaminophen, often known as paracetamol, is another common medicine used in the treatment of PDA. It is thought that paracetamol is inhibiting prostaglandin H2 synthetase (cyclooxygenase) at its peroxidase site, hence reducing prostaglandin synthesis.

The recommended dosage of paracetamol for PDA treatment, which can be given any route without further complications, is 15 mg/kg every six hours for a duration of three to seven days (34). Paracetamol is linked to a lower increase in blood creatinine concentration, less oliguria, and lower bilirubin levels when compared to ibuprofen and indomethacin. In extremely premature newborns, it has been administered as a rescue therapy after

indomethacin treatment failed, and in nearly half of cases, ductus closure or decrease has been achieved. Its efficacy ranges from 70% to 81% when used as a primary treatment; better success rates are shown when the treatment starts during the first week of life (18). Several reports claim that treatment can start as early as two or three days old, and in certain situations, complete closure is achieved. Anyhow, Increased liver enzyme concentrations have been observed in preterm newborns treated with as few as four doses of paracetamol. However, after the medicine was stopped, these enzyme levels normalized. Although preterm newborns' immature hepatic cytochrome P-450 (CYP) enzymes may shield them from short-term toxicity, there is still a chance of liver damage. Hence, prudence is advised (18). To ensure both efficacy and safety, more research is required to determine the ideal dose and course of treatment for paracetamol. Longer treatment durations are associated with better outcomes, according to current research, although patient-specific considerations must always be taken into account.

In summary, paracetamol offers a better side effect profile and equivalent efficacy when compared to standard NSAIDs for the treatment of PDA. In order to decide the optimal course of action for each child, neonatologists and pediatric cardiologists should weigh clinical criteria and echocardiographic characteristics while including paracetamol in their customized treatment plans (35). Generally, the most effective way to monitor neonates receiving pharmacological therapy in between doses is to use echocardiography to see if ductal closure has already occurred.

More invasive methods of treating a PDA include surgical ligation and cardiac catheterization. There are many clinical criteria that must be ensured to perform surgical ligation, one of the most important being a hsPDA, which results in a substantial blood shunt that impairs organ function and causes symptoms. Additionally, in the event that conservative medical therapy fails, ligation is taken into consideration. Also referred to in this therapy method are infants whose PDA is so severe that they need continuous breathing support or cannot be weaned off ventilation. Clinical signs of severe physiological stress, such as growth restriction, dyspnea, and heart failure, are considered as inclusion criteria too. Furthermore, if there is evidence of a considerable left-to-right shunt and the ductal diameter is greater than 2 mm, this is also referred to the criterion for ligation (7). Surgical therapy offers advantages such as prompt closure, decreased problems, and enhanced results. By immediately closing the PDA surgically, symptoms can be reduced and the infant's condition can be stabilized. Ligation can lower the risk for IVH, NEC and chronic lung disease by sealing the PDA.

Furthermore, for infants who do not respond to medical therapy, ligation can improve outcomes by avoiding prolonged exposure to the symptoms of a significant PDA (36). However, surgical correction can be contraindicated, mainly because of severe pulmonary vascular diseases. Additionally, temporary intraoperative occlusion of the PDA does not essentially reverse the underlying pulmonary vascular disease and may not be recommended if elevated pulmonary arterial pressures do not reduce and aortic pressure does not rise as a result. Furthermore, ductus closure without concurrent repair of ductal-dependent lesions, such as aortic valve atresia, mitral valve atresia with hypoplastic left ventricle, pulmonary artery hypoplasia, pulmonary atresia, severe aortic coarctation, tricuspid atresia, and transposition of the great arteries, is contraindicated and potentially fatal. The patient's incapacity to endure general anesthesia and concurrent uncontrolled sepsis are further contraindications (37).

Nevertheless, to guarantee the greatest results, it requires careful preoperative planning, a precise surgical technique, and exceptional postoperative care. Blood tests, cross-matches, and assessments are carried out beforehand. Antibiotics, usually gentamicin, are administered ahead of surgery in order to prevent sepsis. It is preferable to have post-ductal invasive arterial monitoring. Two peripheral intravenous cannulas are necessary, and the IV fluids under consideration should include enough sodium supplementation. Enteral feeding should be stopped six hours prior to surgery in critically ill newborns because it may raise the risk of aspiration and feeding intolerance. Regardless, a total parenteral nutrition (TPN) bag is prepared in order to ensure stability and proper nutritional intake after surgery, promoting repair and recovery. For sedation, morphine at 20–30 $\mu\text{g}/\text{kg}$ is administered; in addition to that, a vecuronium infusion is used (36). Vecuronium infusions support muscle relaxation and provide optimal surgical conditions. Another infusion composing milrinone at 0.3 $\text{g}/\text{kg}/\text{min}$ has to be prepared for post-operative use. Furthermore, cerebral, pre-, and post-ductal saturation probes are positioned. Since 2010, PDA ligations in preterm neonates have been performed in the neonatal intensive care unit (NICU) to reduce handling, hypothermia risk, and ventilation disturbances (36). The surgery is performed in a theatre on both post-term and term newborns. For stability during operation, the baby must be ready at least half an hour beforehand. Selecting the right incubator is essential; the surgery environment is prepared by the NICU staff, who make sure it is peaceful and in absence of parents. They set up the equipment and prepare the infant in accordance with standard guidelines, making sure that all monitoring probes and wires are in place. If the baby is in a Babytherm, the overhead heater is

switched on, and the baby is kept warm with a transwarmer and covered in bubble wrap. During surgery, a specialized nurse ensures correct monitoring and management. A small incision is made on the left side of the chest to access the DA, subsequently, the DA is properly isolated and sealed with a tie or clip (36). TPN and vancomycin are continuously infused during this procedure. Monitoring for problems such as respiratory instability, hypotension, and pneumothorax is part of post-operative care. Following surgery, all neonates get 0.3 g/kg/min of milrinone as an infusion to support hemodynamics, avoid pulmonary hypertension, enhance cardiac function, reduce myocardial oxygen use, and optimize fluid balance (36). Chest X-rays, blood gas analysis, ongoing antibiotics, cardiac echo, sufficient analgesia, prompt feed resumption and removal of the chest drain are all part of routine care. Potential complications can include pneumothorax, damage to the recurrent laryngeal nerve, incomplete duct ligation, ligation of the incorrect vessel, unmasking of aortic coarctation, compression of the left main bronchus, acute blood loss, and post-ligation impaired LV contractility or cardio-respiratory syndrome. Although there is a chance of vocal cord paralysis, it is not frequently evaluated until symptoms continue even after extubation. Moreover, worldwide incidence rates of Post Ligation Cardiac Syndrome (PLIC) range from 30% to 8%. Low cardiac output, poor circulation, hypotension, and severe left ventricular fibrillation are all symptoms of the illness. However, it appears that classic PLIC is becoming less common. Post-Ligation Cardiac-Respiratory Syndrome is undoubtedly more common than previously thought, though. This can be seen as a relative whiteout on a chest X-ray, relative hypertension, and worsening respiratory function 12-48 hours following surgery. In extremely preterm newborns, this is noticed after the PDA catheter is closed. Most likely, increased systemic vascular resistance and compromised diastolic function are the mechanisms generating pulmonary edema (36).

A retrospective cohort study that looked at preterm newborns who were not responding to medication was conducted to investigate hsPDA. It was discovered that there was no statistically significant difference in the death rates between PDA ligation recipients and non-recipients. The requirement for surgical ligation was linked to factors such as low gestational age, low Apgar score at 5 minutes, histologic chorioamnionitis, and PDA ductal diameter over 2.0 mm (7). According to the study, early surgical ligation was related to a lower risk of severe NEC and IVH compared to late ligation, but both had similar mortality. On the other hand, there was a higher chance of NEC (stage III), IVH (grade III), culture-proven sepsis, and extended mechanical breathing (> 4 weeks) in the late ligation group. Due to possible side

effects like hemorrhage, coarctation, hemodynamic compromise, retinopathy of prematurity, nerve injury, and neurodevelopmental impairment, surgical closure of PDA is still debatable. Notwithstanding these reservations, the research indicates that prompt ligation could shorten the time of infection exposure and mitigate the negative consequences of extended PDA patency, including problems with pulmonary circulation, edema, and heightened ventilator support. The retrospective design of the study, the limited sample size (233 patients), and the fact that only one skilled surgeon performed the surgeries are among its shortcomings. Large prospective multicenter trials with long-term follow-up are needed for future studies in order to fully understand the prognosis of preterm neonates with hsPDA who do not respond to medication (7).

For children who weigh more than 5 kg, transcatheter procedures involving the implantation of an occluding coil are an option. Trials involving developing products are being conducted to achieve catheter-based PDA closure in smaller patients (18).

Increasingly, the PDA is being closed via the percutaneous approach. For the majority of PDA cases in both adults and children, transcatheter occlusion is emerging as the preferred therapeutic option due to its efficacy as an alternative to surgical intervention. After the first few months of birth, catheterization is a successful therapeutic option and is considered the most common therapy for a PDA after the first birthday. As catheterization techniques progress, it has also been shown to be possible to successfully seal abnormalities in smaller infants. While several methods and tools have been developed over the past forty years for PDA occlusion, the rates of definitive closure remain substantially below surgical rates. Furthermore, patients with certain body sizes are not suitable for catheter-based closure (37). There are three common devices used for catheterization: the Gianturco spring occluding coils, the Amplatzer duct occluder and the Rashkind ductus occlusion device.

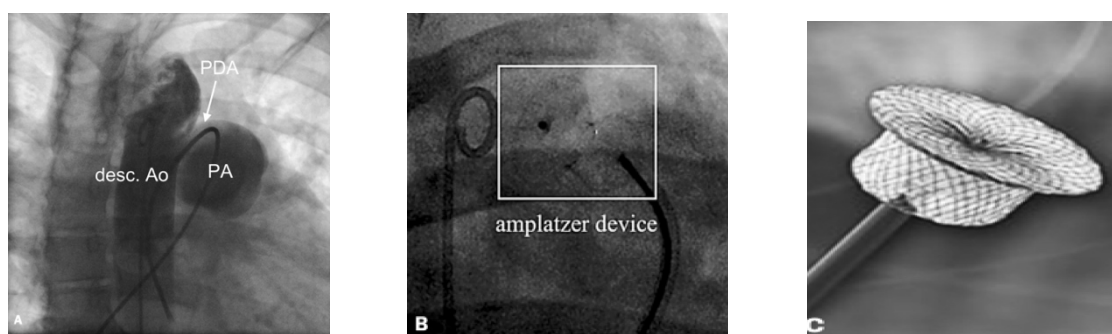


Figure 2. A) shows catheter from pulmonary artery (PA) through PDA to proximal descending aorta (desc. Ao.). B) Amplatzer closure device shown in postclosure angiography of PDA. C) Close-up picture of Amplatzer device. (38)

The most common devices for several years are the Gianturco spring occluding coils, first introduced in 1992. The coils either enter the arterial or venous system and are delivered to the ductus. This method is limited to a ductal diameter of 4-5mm and is most suitable for ducts with a minimal internal diameter of 2.5mm. With experienced surgeons and proper patient selection, catheterization is associated with low morbidity and effectiveness of 75-100%. The Amplatzer duct occluder II, a nitinol flexible mesh with a symmetrical design to provide conformability, has been approved since a major disadvantage was that a part of the previous occluder was protruding into the descending aorta, causing a partial obstruction of the lumen. The new device is generally more suitable for larger ducts and additionally more reliable. Finally, the Rashkind ductus occlusion device consists of a two-umbrella system that is delivered to the ductus either through the venous or arterial system. Its success rate is 83%, although it is not approved for use in the United States.

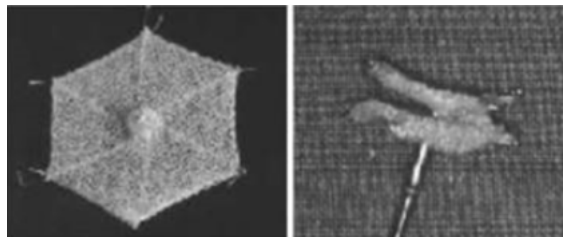


Figure 3. Picture of Rashkind ductus occlusion device. (39)

In summary, during catheterization, the PDA is typically completely occluded. A tiny residual left-to-right shunt may occasionally persist, but it normally closes within a few days or weeks due to thrombus formation. An unusual left-to-right shunt may continue through a partially occluded PDA, although it will always be much smaller than it was prior to occlusion. Any residual defect should be treated, generally with a second catheter surgery, due to the long-term risk of endocarditis. A persistent ductus after occlusion attempts has seldom resulted in hemolysis or endocarditis. The limited procedural risks associated with PDA occlusion by catheter rely on the experience of the treating physician, device embolization, blood vessel damage, bleeding at the access site, infection, and stroke. Following the closure of the PDA, no extra precautions or restrictions are required and if pulmonary hypertension is not present, there is no need for exercise limitation. In the chance of bacteremia caused by either surgery or a catheter, the majority of doctors advise antibiotic prophylaxis for six to twelve months after closure. Recanalization and recurrence of a left-to-right shunt following PDA ligation

are extremely unusual, however there are accounts of these events (37). It is advisable to get follow-up echocardiograms and echocardiography 2-3 weeks following the procedure, until full closure is confirmed, if a PDA has been closed using interventional radiologic procedures (37).

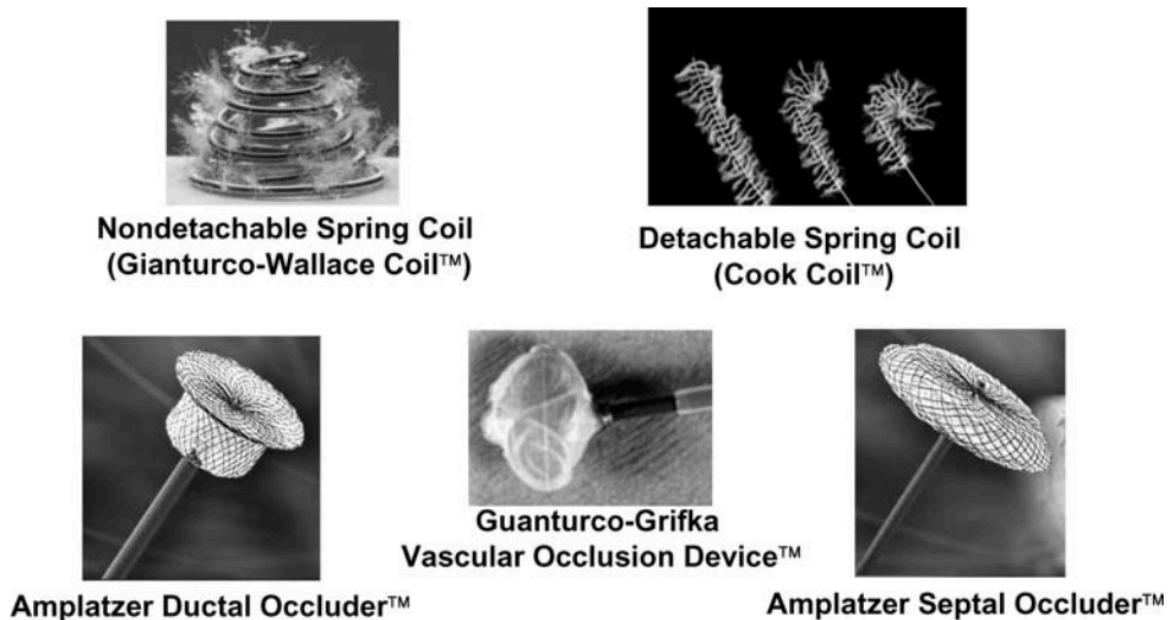


Figure 4. Closure devices for percutaneous use of PDA. (40)

Complications and consequences

Complications include the Eisenmenger phenomenon, right heart failure (RHF) and surgical complications like the closure of the aorta or recurrent laryngeal nerve injury (1).

Eisenmenger syndrome is an uncommon condition with symptoms caused by a major shunt malfunction resulting in shunt inversion due to pulmonary vascular remodelling and vasoconstriction. Worsening exertional dyspnea, edema, palpitations, syncope, dizziness and increasing cyanosis are typical symptoms, which appear if PDA is left untreated. Furthermore, there may be ascites, right upper quadrant pain, dermatological signs, and digital clubbing (41). RHF is characterized by symptoms that come from impairment of vena cava flow or dysfunction of the right heart's components, mostly the right ventricle, but also the tricuspid valve and right atrium. Because of this malfunction, the right heart cannot sufficiently pump blood to the lungs at normal central venous pressures (42). In relation to surgical complications, it is possible for the aorta to be closed due to unintentional clipping. Moreover, the left recurrent laryngeal nerve is susceptible to the same circumstances. Therefore, the

surgeon must employ significant caution in order to prevent those mistakes (1). Consequences associated with systemic undercirculation include disorders like hypotension, IVH, NEC, and acute kidney injury (AKI). Or consequences can be either due to the effects of pulmonary overcirculation, correlating with pulmonary edema, hemorrhage and hypertension as well BPD. Increased pulmonary blood flow from the left-to-right shunt is the cause of pulmonary edema. Pulmonary hemorrhage is also related to an increase in flow, especially when the duct diameter is larger (12). BPD is a chronic lung disease that mainly affects preterm or low-birth-weight babies. It is characterized by lung inflammation and scarring, which is frequently brought on by extended use of oxygen therapy and mechanical ventilation. Breathing difficulties, chronic respiratory issues, and an elevated risk of lung infections can all result from BPD (43). A 4.5-fold increased risk of BPD was observed in newborns with PDA who were diagnosed within the first week of life in a research involving 865 VLBW babies. The duration of the PDA and the requirement for mechanical ventilation may have an impact on the risk of BPD and other chronic lung problems. In a study of 423 newborns under 27 weeks gestation, a significant relationship between moderate-to-large PDA and BPD was seen only when the PDA lasted seven or more days (26). According to another study, the risk of BPD was only elevated by moderate-to-large PDAs in newborns who needed mechanical ventilation for ten or more days (44). It appears that BPD development requires extended exposure to both PDA and mechanical ventilation. In preterm newborns with BPD, pulmonary hypertension has a significant role in morbidity and mortality rates. Moderate or large PDAs are furthermore linked to clinically severe hypotension, necessitating vasoactive treatment. Hypotension may be resistant to vasopressor therapy in certain instances and may continue even after the PDA is surgically ligated. This could be brought on by low cortisol, cardiac dysfunction, or aberrant vascular tone. Due to the potential for hemodynamic instability in newborns with large PDAs, shunts appear also to be connected to an elevated risk of IVH. There is little evidence that connects the lower cerebral blood flow and oxygenation observed in infants with severe PDAs to IVH. Additionally, it is believed that a higher risk of NEC in preterm infants may result from reduced blood supply to the abdominal aorta via ductal steal through larger PDAs. Nevertheless, there is insufficient evidence to prove beyond a reasonable doubt that the circulatory instability linked to PDA raises the risk (12). Generally, NEC, which can affect any portion of the gastrointestinal tract and is characterized by gut wall necrosis of varying thickness, is often one of the most dangerous illnesses affecting the gastrointestinal tract in newborns (45). AKI risk is higher in neonates

with significant PDAs. According to a secondary analysis of the AWAKEN cohort research, which reported 526 VLBW children, infants with PDA had an incidence of AKI that was almost two times higher than infants without PDA (46). The study found no evidence that the PDA management technique (pharmacologic treatment versus transcatheter intervention or conservative care) affected the risk of AKI. Other studies have connected the risk of AKI to medical treatment with nonselective COX inhibitors, namely indomethacin (12).

There are various conditions associated with reopening of PDA, including, hypoxia, acidosis and sepsis. Preterm babies typically do not experience the same level of hypoxia and morphological remodelling as term babies, and the DA frequently stays open for several days following birth. Because the preterm ductus does not develop an intramural vasa vasorum until after 26 weeks of gestation, it is unable to achieve the hypoxia required for morphological remodelling unless luminal flow is completely stopped. As a result, the preterm ductus is still sensitive to reopening and receptive to vasodilators. Moreover, hypoxia causes an increase in pulmonary artery pressure, which can reverse the DA's normal shutting process and cause it to open or reopen. Acidosis impairs the contraction of the ductal muscle, which might lead to reopening, as it affects the function of smooth muscles, including the DA. Inflammatory mediators may be released as a result of systemic inflammation in sepsis. These mediators have the ability to upset the DA's regular operations and organization, encouraging reopening (47).

Prognosis and outcomes

The prognosis is favourable for infants with an isolated PDA, but in premature newborns, other comorbidities affect the prognosis. Most children have a normal life expectancy after PDA closure; anyhow, spontaneous closure is extremely uncommon after the first three months of life. The amount of blood flowing through the PDA correlates to morbidity and mortality. If left untreated, it may result in premature mortality and pulmonary hypertension. Furthermore, RDS can occur in premature newborns with PDA. Surgical complications can result in death, damage to the phrenic nerve and pulmonary artery, obstruction of the descending aorta, and injury to the recurrent laryngeal nerve. The majority of individuals who receive PDA ligation or other medical therapy recover well. However, the prognosis frequently depends on the presence of other conditions. Indomethacin therapy achieves effective closure in 80–90% of neonates. In the event that the ductus reopens, even newborns

receiving medical treatment with ibuprofen may need surgery to close. Adults who do not have fixed pulmonary hypertension always need surgical closure, although the condition of the pulmonary vasculature must be determined prior to the procedure (1).

There is the possibility that the PDA can be so insignificant that adults with older age get an unintentional discovery obtained during physical examination or echocardiography screening.

Two examples are a 28-year-old and a 37-year-old woman (38). A 28-year-old sports instructor with no cardiac history visited the outpatient clinic for a cardiac screening for congenital heart disease because her brother had a bicuspid aortic valve. She was symptom-free and had a great capacity for exercise. Physical examination revealed a young woman in good health. Her blood pressure was 110/60 mmHg and her heart rate was 60 beats per minute. There was a persistent left subclavicular murmur, grade 2/6, with the first and second heart sounds being normal. No symptoms of venous congestion were present. There were no abnormalities seen on the chest X-ray or ECG. However, a little shunt from the proximal descending aorta to the major pulmonary artery was observed during the echocardiographic test and the PDA was officially diagnosed. The patient's PDA was successfully closed percutaneously using a four-loop, 5 mm coil that was inserted from the aortic side.

The other patient, a 37-year-old lady with a history of PDA, went to the emergency department with palpitations, collapse, and dyspnea. In 1993, an attempt was made to percutaneously seal the PDA, but the shunt was too big to be closed with the devices available at the time. She did not visit the outpatient clinic again until she started experiencing the previously mentioned symptoms. Moreover, she had to cease working due to increasing limitations on her everyday tasks. Upon physical examination, the patient's blood pressure was 155/70 mmHg and heart rate was 83 beats/min. In addition to the typical first and second heart sounds, there was a persistent murmur in the second left intercostal region that was indicative of a third heart sound. The sounds of breathing were typical and no symptoms of venous congestion were present. The ECG revealed a normal sinus rhythm along with indications of hypertrophy or dilatation of the left ventricle and left atrial dilatation.

Paroxysmal atrial fibrillation was detected by the cardiac rhythm monitor. Cardiomegaly and enlarged pulmonary vascular markings were seen on the chest X-ray. Echocardiography revealed a large, continuous flow from the aorta to the pulmonary artery via the PDA. The maximum flow rate of 4.5 m/sec suggested that the pulmonary artery pressure was high. With an end-diastolic diameter of 82 mm and an endsystolic diameter of 65 mm, the left ventricle was dilated. The ductal diameter measured 11 mm. These results (left ventricular volume

overload and pulmonary hypertension) allowed the PDA to be effectively closed with an Amplatzer ductus occluder. During follow-up, the small residual shunt that was still visible on the echocardiogram the day after the intervention closed. The left ventricular dimensions decreased to an end-systolic diameter of 57 mm and an end-diastolic diameter of 64 mm during an 18-month follow-up period. There had been no noticeable rise in the left ventricle's systolic performance. Nevertheless, following treatment, the patient reported feeling significantly better. She was able to carry out her work as usual and showed no symptoms. It was advised that these two patients undergo endocarditis prophylaxis for six months following their treatments (38).

Discussion

A cohort study examined a group of newborns born before 28 weeks of gestation. They classified the newborns according to whether the ductus closed spontaneously, if a PDA occurred, or if a PDA became resistant to ibuprofen (48). Compared to infants with ibuprofen-resistant PDA, those who responded well to the first round of ibuprofen treatment had greater gestational ages, higher rates of BPD and IVH, and lower rates of sepsis. The study found that higher gestational age independently increased the likelihood of PDA closure with ibuprofen treatment while decreasing the likelihood of developing ibuprofen-resistant PDA.

Furthermore, there was a significant increase in the probability of ibuprofen failure in closing PDA in cases of sepsis occurring within the first three days of life. This demonstrates that infections can adversely affect the course of PDA treatment. The reason why ibuprofen-resistant PDA is more common in extremely preterm infants than in more mature preterm infants is, however, unknown. It is possible that the increased expression of prostaglandin receptors in these patients explains why the DA is less sensitive to cyclooxygenase inhibition. Moreover, the administration of ibuprofen and indomethacin may be reversed by the vasodilator agents nitric oxide and carbon monoxide production being increased. Lower gestational ages predict both PDA and ibuprofen-resistant PDA among the clinical features, but sepsis alone predicts an ibuprofen-resistant PDA (48).

In a pilot investigation, the effect of in-utero aspirin exposure near delivery on preterm baby outcomes, namely the burden of hsPDA, was investigated (49). The study discovered that preterm babies whose mothers used aspirin had a considerably decreased incidence of hsPDA. The newborns have also shown increased susceptibility to postnatal pharmaceutical therapy for PDA. According to the study, aspirin's early and irreversible inactivation of the COX

enzyme may change the prostaglandin milieu that is produced locally within the premature DA, resulting in PDA closure and increased responsiveness to pharmacological therapy. The study group's infants experienced more liberal advancement of enteral feeds and faster attainment of full enteral nutrition because they had earlier definitive PDA closure and lower cumulative doses of ibuprofen. Notably, the study group did not experience any incidents of gastrointestinal hemorrhage. Additionally, the study group demonstrated a tendency towards a decreased rate of surgical ligation, suggesting that prenatal aspirin exposure may be beneficial in lowering the incidence of hsPDA resistance to treatment. While there has not been much research on the cardiovascular morbidity of preterm infants exposed to aspirin in utero, this pilot study raises the possibility that aspirin exposure close to preterm delivery may have an impact on lowering the incidence of hsPDA and enhancing response to PDA treatment. However, considering the study's limitations, including its retrospective nature and limited cohort size, more expansive prospective trials are needed to show a direct cause-effect connection between maternal aspirin consumption and premature cardiac morbidity (49).

Conclusion

The management of hsPDA in preterm newborns remains a difficult element of neonatal care. A substantial improvement in the early diagnosis and treatment of hsPDA is shown by the suggested clinical diagnostic score. This non-invasive score yields a sensitivity of 84% and a specificity of 80% by combining standardized clinical indicators with echocardiographic measures, making it easier to precisely identify neonates that require intervention. More precise monitoring of the hemodynamic importance of PDA is made possible by the scoring system's ongoing evaluation of specified clinical parameters. This strategy reduces the number of needless echocardiogram assessments, which eases the burden on the medical community and the vulnerable preterm babies who have to have these operations performed. The application of this clinical diagnostic score may ultimately result in more focused and efficient treatment plans, enhancing the general prognosis for premature newborns with hsPDA. To ensure the wider applicability of this scoring system, future research should concentrate on testing it across various infants and situations. Furthermore, investigating how to combine this score with newly developed biomarkers and cutting-edge imaging methods may improve the accuracy and consistency of hsPDA diagnosis even further. The neonatal care community can significantly improve the prognosis and quality of life for preterm newborns affected by this illness by further refining and validating this diagnostic tool.

Summary

In neonatal care, PDA remains a major problem, especially for preterm infants. This thesis reviews the current knowledge on PDA, emphasizing the difficulties and disagreements surrounding its diagnosis and management. Normally, the DA, crucial for fetal development, closes shortly after birth; in premature infants, it frequently stays patent. Severe side effects from hsPDA can include heart failure, respiratory distress, and an elevated risk of various morbidities like IVH, BPD, and NEC. Pharmacological therapies, typically NSAIDs like indomethacin and ibuprofen, are frequently used. However, there is a risk of renal impairment and gastrointestinal problems. Another alternative is surgical closure, but it is usually saved for situations where pharmacological therapy is ineffective. Echocardiography plays a crucial role in detecting and assessing PDA; it determines the presence and severity, makes treatment decisions, and evaluates the effectiveness of therapy. Nonetheless, various descriptions of hsPDA are used, which emphasize the necessity of standardized testing and therapeutic approaches. Early indomethacin administration as a preventive measure, to avoid PDA problems has been investigated in recent research. Emerging pharmaceutical treatments and the development of less invasive surgical methods present promising paths toward enhancing outcomes for preterm newborns with PDA.

In conclusion, while enormous progress has been achieved in understanding and managing PDA, more research is required to produce standardized, evidence-based guidelines for diagnosis and therapy. Balancing the benefits and risks of PDA therapies is crucial to optimize the health and development of preterm infants.

Keywords: Echocardiography, hypoxia, hsPDA, ibuprofen resistance, indomethacin, patent ductus arteriosus, preterm infants

Literature

1. Gillam-Krakauer M, Mahajan K. Patent Ductus Arteriosus. In: StatPearls [Internet]. Treasure Island (FL): StatPearls Publishing; 2024 [cited 2024 Feb 21]. Available from: <http://www.ncbi.nlm.nih.gov/books/NBK430758/>
2. Hu XL, Wang H, Hou C, Hou M, Zhan SH, Pan T, et al. Echocardiographic assessment of intimal thickness growth of patent ductus arteriosus in neonates and analysis of influencing factors. *Int J Cardiovasc Imaging*. 2022 Feb 2;38(7):1443–52.
3. Moss and Adams' heart disease in infants, children, and adolescents: including the fetus and young adult. 10th ed. Philadelphia: Wolters Kluwer; 2022.
4. Maheshwari A, Singh R, Vaidya R, Ashwath R. Patent Ductus Arteriosus: A Diagnostic and Treatment Dilemma. *Newborn*. 2022 Mar 31;1(1):58–66.
5. Dice JE, Bhatia J. Patent Ductus Arteriosus: An Overview. *J Pediatr Pharmacol Ther*. 2007 Jan 1;12(3):138–46.
6. Gal P. Patent ductus arteriosus: indomethacin, Ibuprofen, surgery, or no treatment at all? *J Pediatr Pharmacol Ther JPPT Off J PPAG*. 2009 Jan;14(1):4–9.
7. Lee JH, Lee HJ, Park HK, Ahn JH, Kim HS, Jang HJ, et al. Surgical ligation of patent ductus arteriosus in preterm neonates weighing less than 1500g: a 9-year single center experience. *J Cardiothorac Surg*. 2020 Jun 17;15(1):144.
8. Mathew P, Bordoni B. Embryology, Heart. In: StatPearls [Internet]. Treasure Island (FL): StatPearls Publishing; 2024 [cited 2024 Feb 20]. Available from: <http://www.ncbi.nlm.nih.gov/books/NBK537313/>
9. Sadler TW. Langman's medical embryology. 13th edition. Philadelphia: Wolters Kluwer; 2015. 407 p.
10. Patent Ductus Arteriosus (PDA) - Cardiothoracic Surgery [Internet]. [cited 2024 Jun 11]. Available from: <https://lsom.uthscsa.edu/ct-surgery/patient-care/congenital-heart/conditions-we-treat/patent-ductus-arteriosus-pda/>
11. Koutroulou I, Tsivgoulis G, Tsalikakis D, Karacostas D, Grigoriadis N, Karapanayiotides T. Epidemiology of Patent Foramen Ovale in General Population and in Stroke Patients: A Narrative Review. *Front Neurol*. 2020 Apr 28;11:281.
12. Patent ductus arteriosus (PDA) in preterm infants: Clinical features and diagnosis [Internet]. [cited 2024 Jun 4]. Available from: <https://medilib.ir/uptodate/show/5057>
13. Delany DR, Gaydos SS, Romeo DA, Henderson HT, Fogg KL, McKeta AS, et al. Down syndrome and congenital heart disease: perioperative planning and management. *J Congenit Cardiol*. 2021 Dec;5(1):7.
14. Yazigi A, De Pecoulas AE, Vauloup-Fellous C, Grangeot-Keros L, Ayoubi JM, Picone O. Fetal and neonatal abnormalities due to congenital rubella syndrome: a review of

literature. *J Matern Fetal Neonatal Med.* 2017 Feb;30(3):274–8.

15. Yokoyama U, Minamisawa S, Ishikawa Y. The Multiple Roles of Prostaglandin E2 in the Regulation of the Ductus Arteriosus. In: Nakanishi T, Markwald RR, Baldwin HS, Keller BB, Srivastava D, Yamagishi H, editors. *Etiology and Morphogenesis of Congenital Heart Disease* [Internet]. Tokyo: Springer Japan; 2016 [cited 2024 Mar 1]. p. 253–8. Available from: http://link.springer.com/10.1007/978-4-431-54628-3_35
16. Zarghi A, Arfaei S. Selective COX-2 Inhibitors: A Review of Their Structure-Activity Relationships. *Iran J Pharm Res IJPR.* 2011;10(4):655–83.
17. De Paz Linares GA, Opperman RM, Majumder M, Lala PK. Prostaglandin E2 Receptor 4 (EP4) as a Therapeutic Target to Impede Breast Cancer-Associated Angiogenesis and Lymphangiogenesis. *Cancers.* 2021 Feb 24;13(5):942.
18. Gillam-Krakauer M, Reese J. Diagnosis and Management of Patent Ductus Arteriosus. *NeoReviews.* 2018 Jul;19(7):e394–402.
19. Bin-Nun A, Kasirer Y, Mimouni F, Schorrs I, Fink D, Hammerman C. Wide Pulse Pressure Is Not Associated with Patent Ductus Arteriosus in the First Week of Life. *Am J Perinatol.* 2019 Nov;36(13):1401–4.
20. Kumar V, Abbas AK, Aster JC, Perkins JA, editors. *Robbins basic pathology.* Tenth edition. Philadelphia, Pennsylvania: Elsevier; 2018. 935 p.
21. Mahajan OA, Agrawal G, Acharya S, Kumar S. Infective Endocarditis in Patient With Uncorrected Patent Ductus Arteriosus: A Case Report From Rural India. *Cureus.* 2022 Nov;14(11):e32004.
22. Jain A, Shah PS. Diagnosis, Evaluation, and Management of Patent Ductus Arteriosus in Preterm Neonates. *JAMA Pediatr.* 2015 Sep 1;169(9):863.
23. Tissot C, Muehlethaler V, Sekarski N. Basics of Functional Echocardiography in Children and Neonates. *Front Pediatr.* 2017 Dec 1;5:235.
24. Gad SA, Shaban EA, Dawoud MM, Youssef MA. Diagnostic performance of 320 cardiac MDCT angiography in assessment of PDA either isolated or associated with duct dependent congenital heart disease. *Egypt J Radiol Nucl Med.* 2021 Dec;52(1):255.
25. Weber M. Role of B-type natriuretic peptide (BNP) and NT-proBNP in clinical routine. *Heart.* 2005 Oct 26;92(6):843–9.
26. Potsiurko S, Dobryanskyy D, Sekretar L. Patent ductus arteriosus, systemic NT-proBNP concentrations and development of bronchopulmonary dysplasia in very preterm infants: retrospective data analysis from a randomized controlled trial. *BMC Pediatr.* 2021 Dec;21(1):286.
27. Cracowski JL, Durand T, Bessard G. Isoprostanes as a biomarker of lipid peroxidation in humans: physiology, pharmacology and clinical implications. *Trends Pharmacol Sci.* 2002 Aug;23(8):360–6.

28. Rucker D, Dhamoon AS. Physiology, Thromboxane A2. In: StatPearls [Internet]. Treasure Island (FL): StatPearls Publishing; 2024 [cited 2024 May 29]. Available from: <http://www.ncbi.nlm.nih.gov/books/NBK539817/>
29. Dani C, Pratesi S. Patent ductus arteriosus and oxidative stress in preterm infants: a narrative review. *Transl Pediatr.* 2020 Dec;9(6):835–9.
30. Coviello C, Tataranno ML, Corsini I, Leonardi V, Longini M, Bazzini F, et al. Isoprostanes as Biomarker for Patent Ductus Arteriosus in Preterm Infants. *Front Pediatr.* 2020;8:555.
31. Olsson KW, Larsson A, Jonzon A, Sindelar R. Exploration of potential biochemical markers for persistence of patent ductus arteriosus in preterm infants at 22-27 weeks' gestation. *Pediatr Res.* 2019 Sep;86(3):333–8.
32. Kindler A, Seipolt B, Heilmann A, Range U, Rüdiger M, Hofmann SR. Development of a Diagnostic Clinical Score for Hemodynamically Significant Patent Ductus Arteriosus. *Front Pediatr.* 2017 Dec 22;5:280.
33. Qureshi O, Dua A. COX Inhibitors. In: StatPearls [Internet]. Treasure Island (FL): StatPearls Publishing; 2024 [cited 2024 May 30]. Available from: <http://www.ncbi.nlm.nih.gov/books/NBK549795/>
34. Hamrick SEG, Sallmon H, Rose AT, Porras D, Shelton EL, Reese J, et al. Patent Ductus Arteriosus of the Preterm Infant. *Pediatrics.* 2020 Nov 1;146(5):e20201209.
35. Kardasevic M, Mesihovic-Dinarevic S, Kecalovic AH. Therapeutic Modalities in the Treatment of Persistent Ductus Arteriosus in Premature Babies: Report of Two Cases. *Med Arch Sarajevo Bosnia Herzeg.* 2021 Dec;75(6):467–70.
36. Patent ductus arteriosus (PDA) : surgical ligation [Internet]. [cited 2024 Jun 3]. Available from: <https://www.clinicalguidelines.scot.nhs.uk/nhsggc-guidelines/nhsggc-guidelines/neonatology/patent-ductus-arteriosus-pda-surgical-ligation/>
37. Patent Ductus Arteriosus (PDA) Treatment & Management: Approach Considerations, Conservative Management, Pharmacologic Management. 2023 Jun 30 [cited 2024 Jun 3]; Available from: <https://emedicine.medscape.com/article/891096-treatment#d11?form=fpf>
38. Wiyono SA, Witsenburg M, de Jaegere PPT, Roos-Hesselink JW. Patent ductus arteriosus in adults: Case report and review illustrating the spectrum of the disease. *Neth Heart J Mon J Neth Soc Cardiol Neth Heart Found.* 2008 Aug;16(7–8):255–9.
39. Optimal Design Studies for Occlusion Devices | Chemical Engineering [Internet]. [cited 2024 Jun 11]. Available from: <https://www.che.iitb.ac.in/group/jayesh-bellare-research-group/article/optimal-design-studies-occlusion-devices>
40. Patent Ductus Arteriosus Closure. [cited 2024 Jun 11]; Available from: <https://onlinelibrary.wiley.com/doi/10.1111/j.1540-8183.2006.00172.x>
41. Basit H, Wallen TJ, Sergent BN. Eisenmenger Syndrome. In: StatPearls [Internet].

Treasure Island (FL): StatPearls Publishing; 2024 [cited 2024 Jun 4]. Available from: <http://www.ncbi.nlm.nih.gov/books/NBK507800/>

42. Right heart failure: Causes and management - UpToDate [Internet]. [cited 2024 Jun 5]. Available from: https://www.uptodate.com/contents/right-heart-failure-causes-and-management?search=hypoxia+and+PDA+reopening&source=search_result&selectedTitle=13%7E150&usage_type=default&display_rank=13
43. Read by QxMD [Internet]. [cited 2024 Jun 5]. Bronchopulmonary dysplasia. Available from: <https://read.qxmd.com/read/16650652/bronchopulmonary-dysplasia>
44. Mirza H, Garcia J, McKinley G, Hubbard L, Sensing W, Schneider J, et al. Duration of significant patent ductus arteriosus and bronchopulmonary dysplasia in extremely preterm infants. *J Perinatol*. 2019 Dec;39(12):1648–55.
45. Fox TP, Godavitarne C. What really causes necrotising enterocolitis? *ISRN Gastroenterol*. 2012;2012:628317.
46. Guillet R, Selewski DT, Griffin R, Rastogi S, Askenazi DJ, D'Angio CT, et al. Relationship of patent ductus arteriosus management with neonatal AKI. *J Perinatol Off J Calif Perinat Assoc*. 2021 Jun;41(6):1441–7.
47. Avery's Diseases of the Newborn [Internet]. Elsevier; 2018 [cited 2024 Jun 5]. Available from: <https://linkinghub.elsevier.com/retrieve/pii/C20130003209>
48. Dani C, Bertini G, Corsini I, Elia S, Vangi V, Pratesi S, et al. The fate of ductus arteriosus in infants at 23-27 weeks of gestation: from spontaneous closure to ibuprofen resistance. *Acta Paediatr Oslo Nor* 1992. 2008 Sep;97(9):1176–80.
49. Fridman E, Mangel L, Mandel D, Beer G, Kapusta L, Marom R. Effects of maternal aspirin treatment on hemodynamically significant patent ductus arteriosus in preterm infants - pilot study. *J Matern-Fetal Neonatal Med Off J Eur Assoc Perinat Med Fed Asia Ocean Perinat Soc Int Soc Perinat Obstet*. 2022 Mar;35(5):958–63.

Curriculum Vitae

Noa Mai Ben Hamo Jimenez was born on the 14th of October 1998 in Dortmund, Germany. Her academic career started in 2017 when she finished the Abitur at Dortmund's Helene-Lange-Gymnasium. Following that, in 2018, she enrolled at the University of Medicine in Rijeka, Croatia, to pursue her education with the goal of becoming a doctor. Her clinical experience started in 2016 when she completed a nursing internship in Dortmund. Several volunteer practicals in Germany were conducted after that, such as an Erasmus+ program at Heinrich-Braun-Klinikum in Zwickau in 2022 or experience in pediatric cardiology. Most recently, in the summer of 2023, she was employed as an obstetric assistant at Gemeinschaftskrankenhaus Herdecke.

Noa Mai Ben Hamo Jimenez will receive her diploma in July 2024 and will further participate in a two-months internship at the University Clinic for Pediatric and Adolescents in Vienna.