

Burn injuries and their surgical treatment

Hilpert, Juljan

Master's thesis / Diplomski rad

2024

Degree Grantor / Ustanova koja je dodijelila akademski / stručni stupanj: **University of Rijeka, Faculty of Medicine / Sveučilište u Rijeci, Medicinski fakultet**

Permanent link / Trajna poveznica: <https://um.nsk.hr/um:nbn:hr:184:069650>

Rights / Prava: [In copyright](#)/[Zaštićeno autorskim pravom.](#)

Download date / Datum preuzimanja: **2024-08-31**



Repository / Repozitorij:

[Repository of the University of Rijeka, Faculty of Medicine - FMRI Repository](#)



**UNIVERSITY OF RIJEKA
FACULTY OF MEDICINE**

**INTEGRATED UNDERGRADUATE AND GRADUATE UNIVERSITY
STUDY OF
MEDICINE IN ENGLISH LANGUAGE**

Juljan Hilpert

BURN INJURIES AND THEIR SURGICAL TREATMENT

GRADUATION THESIS

**Rijeka, 2024
UNIVERSITY OF RIJEKA
FACULTY OF MEDICINE**

**UNIVERSITY OF RIJEKA
FACULTY OF MEDICINE**

**INTEGRATED UNDERGRADUATE AND GRADUATE UNIVERSITY
STUDY OF
MEDICINE IN ENGLISH LANGUAGE**

Juljan Hilpert

BURN INJURIES AND THEIR SURGICAL TREATMENT

GRADUATION THESIS

**Rijeka, 2024
UNIVERSITY OF RIJEKA
FACULTY OF MEDICINE**

Thesis mentor: Aleksandra Pirjavec Mahić, MD, PhD, Professor

The graduation thesis was graded on 12.06.2024 in Rijeka, before the Committee composed of the following members:

1. Damir Grebić, MD, PhD, Professor (Committee head)
2. Harry Grbas, MD, PhD, Professor
3. Marko Zelić, MD, PhD, Professor

The graduation thesis contains 37 pages, 0 figures, 5 tables, 70 references.

Acknowledgement

I would like to express my gratitude to my mentor, Professor Aleksandra Pirjavec Mahić, for her guidance and support throughout this thesis.

Furthermore, I want to extend a special thank you to my grandmother Luise and my cousin Roman for always being there for me, as well as to my entire family for their support and encouragement

Table of content

<u>I. INTRODUCTION</u>	0
1.1 BACKGROUND INFORMATION ON BURN INJURIES AND THEIR IMPACT ON PATIENTS	1
1.2 SIGNIFICANCE OF SURGICAL TREATMENT CARE AND RECONSTRUCTION IN BURN INJURY MANAGEMENT	1
1.3 PURPOSE AND OBJECTIVES OF THE THESIS	1
<u>II. OVERVIEW OF BURN INJURIES</u>	2
2.1 DEFINITION AND CLASSIFICATION OF BURN INJURIES	2
2.1.1 SKIN:	2
2.1.2 CLASSIFICATION:	3
2.1.3 MECHANISM:	3
2.2. EPIDEMIOLOGY AND PREVALENCE OF BURN INJURIES	4
2.3 ETIOLOGY AND COMMON CAUSES OF BURN INJURIES	6
2.3.1 THERMAL BURNS	6
2.3.2 ELECTRICAL BURNS.....	8
2.3.3 CHEMICAL BURNS.....	8
2.3.4 RADIATION CONTACT	9
<u>III. SURGICAL MANAGEMENT OF BURN INJURIES</u>	9
3.1 INITIAL ASSESSMENT AND STABILIZATION OF BURN PATIENTS	9
3.2 SURGICAL INTERVENTIONS IN BURN CARE	10
3.2.1 ROLE OF SURGICAL INTERVENTIONS IN BURN INJURY CARE.....	10
3.2.2 IMMEDIATE SURGICAL INTERVENTION FOR DEEP BURNS	10
3.2.3 BURN WOUND EXCISION BENEFITS	11
3.2.4 CONSIDERATIONS FOR SURGICAL EXCISION.....	11
3.3 BURN WOUND EXCISION TECHNIQUES	12
3.4 BLOOD LOSS MANAGEMENT IN BURN WOUND EXCISION	13
3.5 SPECIAL CASES AND CONSIDERATIONS FOR SURGICAL EXCISIONS	14
3.5.1 LARGE BURNS	14
3.5.2 MASSIVE BURNS.....	15
3.5.3 EXCISIONS ON THE HEAD AND FACE.....	16
3.5.4 FACIAL EXCISION AND WOUND CLOSURE.....	16
3.5.5 EYELID.....	17
<u>IV. SKIN GRAFTING AND TISSUE EXPANSION</u>	18
4.1 TECHNIQUES OF WOUND CLOSURE	18
4.2 DERMAL REPLACEMENT	19
4.3 CULTURED EPIDERMAL AUTOGRAFT	20
4.4 SKIN PROCUREMENT	21
4.5 DONOR SITE	21
<u>V. CHALLENGES IN SURGICAL TREATMENT CARE</u>	22
5.1 INFECTION	22
5.2 INFECTION AND REJECTION OF ALLOGRAFT SKIN	23

<u>VI. ADVANCES IN SURGICAL RECONSTRUCTION TECHNIQUES.....</u>	<u>23</u>
6.1 EMERGING TECHNOLOGIES AND INNOVATIONS IN BURN RECONSTRUCTION.....	23
6.2 TISSUE ENGINEERING IN BURN CARE.....	25
<u>VII. DISCUSSION OF POTENTIAL AREAS FOR FURTHER RESEARCH AND ADVANCEMENTS.....</u>	<u>26</u>
<u>VIII. SUMMARY OF KEY FINDINGS AND CONCLUSION</u>	<u>29</u>
<u>IX. LITERATURE.....</u>	<u>31</u>
<u>X. CV.....</u>	<u>37</u>

List of abbreviations and acronyms

AI: Artificial Intelligence

AR: Augmented Reality

ARS: Acute Radiation Syndrome

BICS: Burn Intensive Care Unit

CEA: Cultured Epithelial Autografts

CRISPR: Clustered Regularly Interspaced Short Palindromic Repeats

DNA: Deoxyribonucleic Acid

ECM: Extracellular Matrix

GH: Growth Hormone

HAMC: Hyaluronic Acid-Methylcellulose

IV: Intravenous

ML: Machine Learning

NPWT: Negative Pressure Wound Therapy

PDLLA: Poly-DL-Lactic Acid

PVA: Polyvinyl Alcohol

TBSA: Total Body Surface Area

TERM: Tissue Engineering and Regenerative Medicine

VAC: Vacuum-Assisted Closure

VR: Virtual Reality

. Introduction

1.1 Background information on burn injuries and their impact on patients

Burn injuries are a significant global health issue that can have devastating consequences for individuals and their communities. These injuries occur due to exposure to thermal, chemical, electrical, or radiation sources, resulting in damage to the skin and underlying tissues. The impact of burn injuries extends beyond the physical damage, affecting patients psychologically, emotionally, and socially. The pain, disfigurement, and functional impairments associated with burns can lead to long-term physical and psychosocial challenges, impacting the overall well-being and quality of life of affected individuals.

1.2 Significance of surgical treatment care and reconstruction in burn injury management

Surgical treatment care and reconstruction play a critical role in the comprehensive management of burn injuries. Surgical interventions aim to remove devitalized tissue, promote wound healing, restore function, and improve aesthetic outcomes. Debridement, wound excision, skin grafting, flap reconstruction, and microsurgery are among the techniques used in burn surgery to facilitate healing and functional recovery. These surgical interventions are essential for reducing the risk of infection, preventing contractures, improving range of motion, and enhancing the appearance of scars.

1.3 Purpose and objectives of the thesis

This thesis purpose is to provide a comprehensive exploration and analysis of the surgical treatment care of burn injuries.

The thesis aims to provide a thorough review of the current literature and research on surgical management strategies for burn injuries, including debridement techniques, wound excision, and grafting procedures.

Furthermore, examine the significance of surgical interventions in terms of their impact on wound healing and functional restoration and explore the challenges and advancements in surgical techniques, including emerging technologies, tissue engineering, and regenerative medicine, that enhance burn reconstruction outcomes.

Lastly the thesis tries to identify future directions and potential areas for further research in the field of surgical treatment care and reconstruction of burn injuries, highlighting the importance of continued training for healthcare professionals.

By tackling these goals, this thesis hopes to expand understanding, add to the collection of existing research, and offer insightful advice for clinical practice and improve on surgical treatment outcome of burn injury.

II. Overview of Burn Injuries

2.1 Definition and classification of burn injuries

2.1.1 Skin:

The skin covers the human body and serves as its first line of protection. It is the largest organ of the human body and the epidermis and dermis are its two main constituent layers. The primary constituents of the epidermis are keratinocytes, which progress through several phases beginning at the basal layer and ending at the stratum spinosum, stratum granulosum, stratum lucidum, and stratum corneum. By generating melanin, melanocytes shield the skin from sunlight, and Langerhans cells use phagocytose and antigen presentation to ward off invaders. As a result, isolated epidermal lesions heal via regeneration without leaving scars, however this can cause alterations in the skin's pigmentation because of melanocyte depletion. (1)

Melanocytes provide protection against sunlight by producing melanin and Langerhans cells protect against intruders by phagocytose and antigen presentation. These layers provide protection against fluid as well as electrolyte loss. It allows for perception of the surroundings by touch, temperature, and pain. Skin also contributes to one's identity and can give an insight into an individual history by scars or stage of aging. The connection between the epidermis and the dermis is called basement membrane zone and is done via epidermal rete ridges those interlocks with the dermal papillae. The main connection between those two structures are the keratinocyte-derived collagen VII anchoring fibrils which extend into the dermis. (2)

However, due to their importance for stability of the skin these anchoring fibrils can need up to months to mature in healing after burn injuries even slight touches can lead to tearing and blistering up to epidermal loss.

The dermis can be divided into the superficial papillary dermis and the deeper reticular dermis. It consists mainly of collagen fiber for resistance against stretching and tensile forces while elastic fibers give elasticity. Here originate the organelles of the skin such as sweat glands, hair follicles and sebaceous glands. They then continue through the layers of the epidermis. Sensory nerve endings are stationary in the dermis and give signals about pain, vibration, touch, etc.

2.1.2 Classification:

Burn injuries result from denaturation of proteins by heat, chemical or physical properties. These factors are high temperature, electricity, friction, radiation, and chemicals. The burn injury depend on the amount of body surface area, location of the burn injury, temperature, and time of exposure. These factors also have a synergistic effect between them which can lead to more serious injuries. (3)

Burn injuries can be therefore classified by the causative factor, the injury depth, and the percentage of coverage on the body surface area. This determines the degree of injury. They can be partial or full-thickness injury depending on the depth. Partial thickness only penetrates up to the parts of the dermis whereas full thickness penetrates through the whole skin and often injury underlying subcutaneous tissue.

Depending on the depth of injury the recovery can take from 10-14 days in superficial partial thickness (limited to epidermis and upper part of dermis) up to 3-6 weeks in deep partial thickness burns and can heal with a very low chance of scarring up to high chance of hypertrophic scarring, respectively. Full thickness burns usually need surgical procedures to secure adequate healing due to extensive damage to all the layers of skin involved.(4) (5)

2.1.3 Mechanism:

Burn injuries usually occur due to contact with liquids, solid objects or gases which are hot enough to heat up the basal layer of the epidermis up to 44°C.(6)

Cell necrosis happens after an hour of exposure to 45°C because the temperature and length of exposure work in concert. Protein denaturation and integrity loss of the plasma membrane result from this. The degree of necrosis decreases with increasing distance from the necrotic center, starting at the center of the injury and spreading outward.

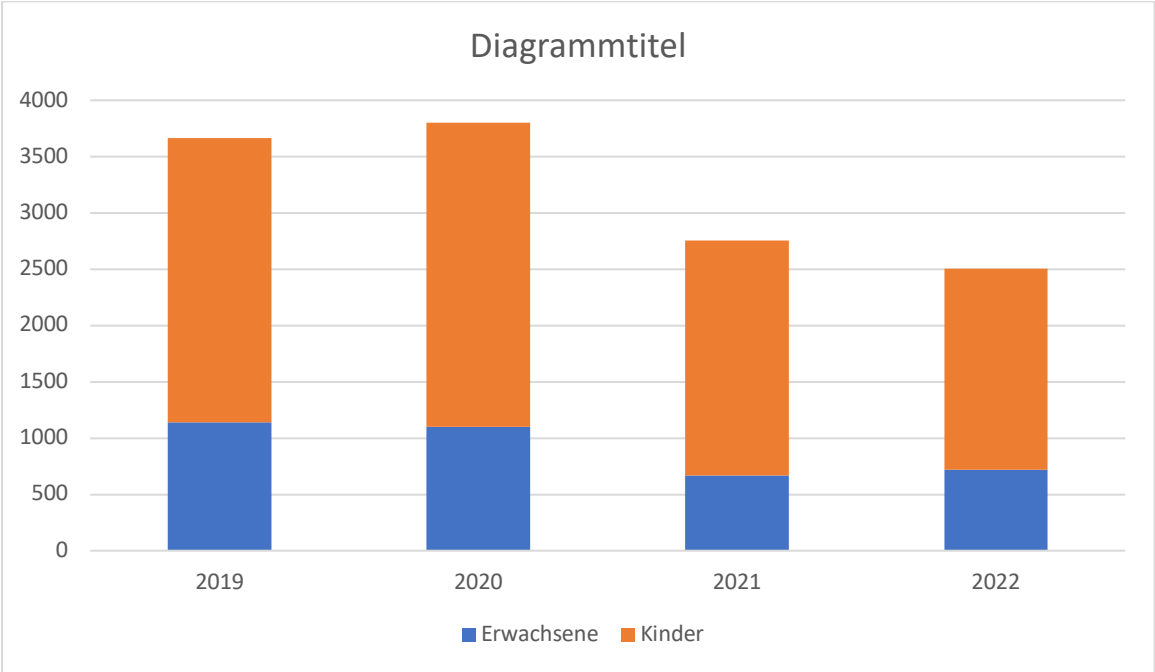
Necrosis and permanent tissue damage are present in the center, where the zone of coagulation is located. It is surrounded by the stasis zone, which is made up of both living and

dead cells. Vascular transudate, capillary vasoconstriction with vasoconstrictive agents, and local inflammatory responses Vulnerability to ischemia owing to reduced tissue perfusion and designates the "at-risk" area, which, depending on the course of treatment, may either recover or turn into necrosis with hypoperfusion.(7).

Except in cases of severe sepsis or protracted hypoperfusion, the zone of hyperemia is characterized by dilated blood vessels brought on by inflammatory reactions and increased blood flow to healthy tissue without risk of necrosis. (8)

2.2. Epidemiology and prevalence of burn injuries

The Burn Registry records patients who require inpatient treatment mainly due to thermal or chemical injuries. It also includes patients with rare extensive skin conditions that have similar injury types and pathophysiology. The inclusion criteria vary between children and adults. In adults, only patients who require treatment in the Burn Intensive Care Unit are included, while all inpatient children with thermal or chemical injuries are captured. In 2022, a total of 2504 burn patients were documented, with 71% being children. Some children under 16 years were treated and documented in adult centers (n=5), while young adults aged 16-19 years were treated in pediatric centers (n=17). Your clinic documented 717 adults and 1787 children last year. The case numbers from previous years are shown in the following graph.



(9)

The age distribution varies across different specialized clinics. The tables below illustrate the average age in years (mean) and the percentage distribution across different age groups. One patient did not have valid age information in the registry in 2022.

Adult (n=717)	16-20	21-40	41-60	61-80	>80
2022	10%	30%	35%	17%	7%

Children (n=1787)	0-1	2-3	4-6	7-9	9-15
2022	54%	18%	9%	10%	10%

Differences in burn injury distribution according to sex (9)

2022	male	female
Adults (n=717)	69%	31%
Children (n=1787)	60%	40%

The context of the accident reflects the cause in which the injury occurred. Multiple selections are not possible. The information here is sorted in descending order based on prevalence. (9)

Cause in 2022	Adults (%)	Adults (n)	Children (%)	Children (n)
Flame (including flash burn)	44%	319	5%	89
Scald	21%	154	70%	1245
Fat burn (including oil)	3%	24	4%	65
Blistering skin diseases	3%	20	<1%	3
Explosion (heat wave)	2%	17	1%	11
Contact with solid	2%	13	14%	252
Contact with liquid solid	2%	12	1%	26
Electricity: low voltage	2%	12	1%	11
Acid	1%	9	<1%	3

Cause in 2022	Adults (%)	Adults (n)	Children (%)	Children (n)
Electricity: high voltage	1%	6	<1%	4
Lye	1%	5	<1%	2
Pure IHT	<1%	3	0%	0
Frostbite	<1%	1	<1%	3
Lightning	0%	0	0%	0
Other	1%	4	1%	22

2.3 Etiology and common causes of burn injuries

2.3.1 Thermal burns

2.3.1.1 Flash and flame burns

Flash and flame burns, which account for about half of admissions to regional burn centers, are caused by intense heat from explosions involving flammable substances like natural gas, propane, and gasoline. Gasoline emits highly flammable vapors that can accumulate in enclosed spaces, leading to explosive situations. Victims often describe incidents involving improper handling of gasoline. It is often used as a fire accelerant for burning trash or starting fires in an uncontrolled environment such as outdoors.

Flash burns usually damage the entire exposed skin, penetrating the dermis according to the type and quantity of fuel used. Even while these burns typically heal without requiring a lot of skin grafting, they can nevertheless cause thermal injuries to the upper airway and cover huge areas. On the other hand, flame burns are typically either deep dermal or full-thickness in depth and are caused by continuous exposure to high heat. House fires, negligent smoking, mishandling flammable chemicals, car crashes, and clothes caught fire from space heaters or stoves are among the causes. Due to circumstances like intoxication, confusion from carbon monoxide poisoning, and loss of consciousness, victims of house fires are more likely to sustain deeper injuries because they may be exposed to convective heat inside burning rooms. Such injuries may appear shallow to the untrained eye but are actually full-thickness burns and must be treated as such in a timely manner.

2.3.1.2 Scalds

Hot water scalds are a prevalent cause of burns in the western world, with little change in their incidence despite educational efforts. The severity of scald injuries depends on factors like water temperature, duration of contact, and skin thickness. Water at 140°F can cause deep dermal burns in just 3 seconds, while boiling water can cause severe burns unless the contact is brief. Scalds often result in a mix of superficial and indeterminate dermal burns, especially in clothed areas where heat is retained.

Immersion scalds, although they may involve lower water temperatures, can still cause deep injuries due to prolonged exposure. (10) (11) Non-accidental scald burns can happen to vulnerable people, like small children, the elderly, or those with impairments. (12) (13) Hot oils and grease frequently result in deep cutaneous or full-thickness wounds, often following a distinct pattern of injury progression. Tar and asphalt burns, typically encountered in roofing work, can also result in severe burns, with initial evaluation focusing on tar removal. Partial thickness scald burns can often be managed non-operatively initially, with excision and grafting considered if healing is not progressing after 10-14 days. Early excision may result in smaller areas needing surgery and faster healing compared to delayed excision. (12)

2.3.1.3 Contact burns

Burns from contact with hot metals, plastic, glass, or embers are frequently little but have the potential to pierce deeply. The material's temperature and the length of contact determine how severe the burn is. For example, molten materials or prolonged exposure to heating blankets can result in burns extending below the dermis penetrating underlying structures such as into fat and muscle. Accidents involving heavy objects which are common in industrial work environment may lead to both contact burns and crush injuries, requiring consideration of extensive tissue damage. Contact burns from hot mufflers or in traffic accidents may necessitate excision and grafting, with some cases requiring surgical intervention with extensive flap coverage of the affected area. (14)

In domestic settings, commonly affect palms and fingers by contact burns, particularly in toddlers who inadvertently touch hot surfaces like woodstoves or oven doors. (15) While intermediate-depth palm burns can heal with proper wound care and therapy, deep burns may lead to permanent disability if not treated promptly. The decision to perform excision and grafting should consider the unique sensory nerve endings in glabrous skin, with an initial observation period and splinting recommended before surgical intervention.

2.3.2 Electrical burns

Electrical burns result from the body acting as a conductor, generating intense heat. Low voltage injuries typically cause minor damage, except when a child chews on an electrical connection¹, leading to severe mouth burns. High voltage injuries, common in occupations like construction and electrical work, can cause deep tissue destruction despite small surface wounds. Resistance from dry or calloused skin offers some protection, but high resistance within the body exacerbates harm, causing deep muscle damage (16), particularly in areas with less dissipation of electrical current-like fingers and hands. Arc electrical burns often occur at joints where the current takes the shortest path. Early surgery may be necessary for severe tissue damage, with careful monitoring for compartment syndrome. Definitive operations are typically performed within days to prevent bacterial contamination and assess tissue necrosis (17), with caution advised against overly aggressive interventions that may worsen outcomes.

2.3.3 Chemical burns

Burns, often caused by strong chemical agents such as acids or alkalis, typically occur due to improper use of harsh chemicals which are usually either industrial accidents, assaults, or inappropriate handling of such agents. Acid burns tend to form a protective barrier on the skin, limiting further penetration, while alkali burns continue to damage the skin until neutralized. Initial treatment involves flushing the affected area with water for at least 15–20 minutes to dilute the chemical. Attempts to neutralize acids with alkalis or vice versa are unsafe and can worsen the injury. Dry chemical burns should be brushed off rather than washed. Chemical burns may initially appear superficial but can be deep, requiring careful observation. Hydrofluoric acid burns are particularly severe, penetrating deep tissues and causing systemic effects due to fluoride toxicity. (18) To prevent serious injuries prompt treatment is essential because it reduces tissue damage and risk of potential complications like amputation. Intra-arterial infusion of calcium ions can alleviate pain and minimize tissue destruction in Hydrofluoric acid burns. (19)

2.3.4 Radiation contact

The main types of harmful radiation are beta (β), gamma (γ), and alpha (α) rays. Positively charged helium ions, or "alpha particles," are relatively heavy and have a limited airborne range. Their high energy levels mean that they can cause severe tissue damage if breathed or consumed, but they are unable to penetrate the keratin layer of the skin. In contrast, because of their limited penetration depth into tissues (about 1 cm), beta particles are negatively charged electron beams that can travel farther in the air and inflict superficial lesions similar to sunburn. (20)

Originating from sources such as X-rays and naturally occurring decay of radioisotopes like iridium-192 (^{192}Ir) and cobalt-60 (^{60}Co), gamma rays can penetrate deeply into tissues and travel many meters through the atmosphere. As such, they have the potential to cause severe harm to critical organs such as the lungs and bone marrow. Gamma radiation exposure can result in systemic symptoms known as Acute Radiation Syndrome (ARS) in addition to deep skin burns. (20)

III. Surgical Management of Burn Injuries

3.1 Initial assessment and stabilization of burn patients

Burn injuries can penetrate the skin depending on the cause and therefore, injure different layers of skin and even extend into underlying structures or tissue like fat, muscle, and bone. (21) Burns that only involve the epidermis are typically red and painful but don't blister, resembling sunburns. These superficial burns usually heal within a few days as the dead epidermis sheds and new skin cells regenerate. When burns extend into the papillary dermis, they form blisters which can take up to 2-3 weeks to heal. Usual they heal without scarring if adequate treated and cared for. Deeper burns, reaching into the reticular dermis, appear pink and white and take longer to heal, often requiring more than 3 weeks. Full-thickness burns, marked by a charred appearance of the skin and affecting the entire dermis and subcutaneous tissue, require early extensive excision and grafting. If treatment is done in a timely manner short and long-term complications such as infection and scarring can be prevented, respectively. Intermediate-depth burns are more challenging to manage, as their healing potential may vary, and initial assessments can be only about 70% accurate. (22)

Therefore, careful monitoring and evaluation by experienced healthcare professionals are crucial for determining the appropriate treatment course.

3.2 Surgical Interventions in Burn Care

3.2.1 Role of surgical interventions in burn injury care

Surgical intervention is an essential component of multidisciplinary burn treatment and care. Early excision and grafting significantly improve survival rates and outcomes for burn patients. An inflammatory response is triggered by burned tissue when the eschar zone borders the zone of living tissue beneath it. Eschar separation and granulation tissue formation result from the attraction of polymorphonuclear leukocytes by the bacteria present in the eschar. These leukocytes release inflammatory mediators and proteolytic enzymes. This localized inflammatory reaction may become systemic in cases of significant burns. The release of mediators from the burn site includes proteinoids, thromboxane, histamine, cytokines, and tumor necrosis factor; blood levels of these mediators rise in direct proportion to the surface area of the burn. Until these mediators are released, the hypermetabolic response—which is marked by elevated protein catabolism, energy expenditure, weight loss, poor wound healing, and immunological suppression—continues.. (23)

3.2.2 Immediate Surgical Intervention for Deep Burns

Immediate surgical intervention is necessary once a burn is identified as "deep," referring to full-thickness or deep partial-thickness wounds that are unlikely to heal within three weeks. These burns, often resulting from flame or contact injuries, require prompt excision to prevent complications. Research by Heimbach et al. demonstrated that deep partial-thickness burns did not progress to full-thickness burns when infection was controlled with topical antimicrobials. However, these burns, despite healing eventually, were associated with persistent blistering, itching, hypertrophic scarring, and poor functional outcomes. This prompted research comparing non-operative treatment for burns of unknown depth that covered less than 20% of the total body surface area (TBSA) versus early excision and grafting. The study found that early surgery resulted in shorter hospital stays, reduced costs, and less time off work, although it required more blood products. Conversely, non-operative treatment led to more late-stage grafts and a higher incidence of hypertrophic scarring. (24)

3.2.3 Burn Wound Excision Benefits

Early treatment of burn wounds by excision and closure with skin grafting have proven effective in reducing infections, shortening hospital stays, and improving survival rates in burn patients of all ages. (25) In order to facilitate dressing changes, avoid burn wound infection, and prepare the wound bed for autografting, burn eschar must be removed from deep burn lesions. Rather than waiting for eschar separation, early burn wound excision is advised to remove ischemic, necrotic, and possibly contaminated tissue. This recommendation is based on small, randomized trials and observational studies. If sufficient tissue remains after excision, skin or soft tissue covering can be applied. If not, interim bandages or tissue substitutes are employed until final reconstruction is feasible.

The burn eschar was not removed until it separated on its own from the site of burn injury, exposing granulation tissue appropriate for grafting, before the advantages of early removal were realized. This method's drawn-out procedure frequently resulted in burn wound infection. Topical agents were used to control bacterial colonization but were generally ineffective as they did not penetrate the eschar. (26)

3.2.4 Considerations for Surgical Excision

Hemodynamic and resuscitative parameters, particularly managing the considerable blood volume loss during and after the excision of extensive TBSA burns, must be regulated for patients to endure general anesthesia and the stress of excision and grafting. While early burn wound excision and closure are beneficial, they do not completely eliminate the hypermetabolic response. This response must be managed separately to optimize patient outcomes. (23)

Effective eschar removal is crucial for preventing complications and initiating healing, particularly in extensive burns covering over 50% of the total body surface area (TBSA). Immediate or early eschar removal within 24 hours can reduce the inflammatory response and related complications. (27) While surgical debridement is effective, it involves risks such as blood loss and anesthesia complications and often requires general anesthesia. Non-surgical methods, relying on autolytic processes and daily care, are slower and can lead to infection and scarring but are more selective and avoid surgery.

3.3 Burn Wound Excision Techniques

Burn wound excision is essential for creating a suitable bed for autografts or biological dressings. Sharp debridement and excision are the mainstays of most of today's treatments; an excision knife or a dermatome are most frequently employed. However, alternative methods such as hydro-surgery or enzymatic debridement are being further investigated.

Tangential Excision

The most popular method, tangential excision, involves removing burned tissue one at a time until exposed, vascularized, live tissue is revealed. For superficial partial-thickness burns, this approach normally works well; but, for deep partial-thickness and full-thickness burns, total excision is necessary to provide a substantial tissue bed for autografting. The process, firstly described by Janzekovic, employs instruments like the Humby knife and Goulian-Weck dermatome, which achieves even, layer-by-layer excision by applying pressure to the burn wound until viable tissue is reached. (28) This method usually preserves the bodily proportions better than facial excision and leads to decreased pain, hospital stays and follow up procedures. Care must be taken to avoid excessive pressure that can lead to uneven excision or damage to viable tissue.

Sharp Debridement

Using sharp handheld instruments such as the Humby knife and Goulian-Weck dermatome, sharp debridement involves applying pressure to the burn wound and excising tissue in a controlled manner. This method is effective but requires precision to avoid removing healthy tissue or causing deeper-than-intended excision. (29)

Fascial Excision

Fascial excision is the removal of skin and subcutaneous tissue all the way down to the fascia; it is reserved for particularly large, deep, and potentially fatal burns or invasive burn wound infections. This method reduces blood loss by controlling deeper perforating vessels, but it results in permanent loss of cutaneous sensation, lymphedema, and contour deformities. (30)

Hydrosurgery

Hydrosurgery, suitable for partial-thickness burns, uses high-pressure water jets to debride necrotic tissue while preserving more dermal tissue, potentially reducing scarring.

Though promising, more extensive trials are needed to validate its routine use. In a trial comparing hydrosurgery with conventional debridement, hydrosurgery preserved more dermis and resulted in better scar assessments, though some patients noticed no difference. (31) (32)

Enzymatic Debridement

Selective enzymatic debridement, such as using NexoBrid derived from bromelain in pineapple stems, shows promise. Clinical trials indicate that NexoBrid reduces time to debridement, the need for surgery, the area of burn excised, and the necessity for autografting. (33)

Special Considerations for Hand Burns

Hand burns, affecting 30-60% of burn patients, require special attention due to the risk of burn-induced compartment syndrome (BICS), which may necessitate emergency escharotomy. The complex anatomy of the hand complicates surgical interventions, often leading to delayed or unnecessary procedures. (34)

Need for Improved Debridement Methods

There is a significant need for a non-invasive, effective, and fast debriding agent that combines the benefits of surgery with the safety of non-surgical methods. Such an agent would allow early and accurate burn depth diagnosis and treatment, improving overall patient outcomes.

3.4 Blood loss management in Burn wound excision

Performing excision within 24 hours of injury significantly reduces blood loss. During this period, vasoactive metabolites like thromboxane, a potent vasoconstrictor, are abundant, which helps limit hemorrhage. A study of 318 pediatric patients with burns over 30% TBSA showed that early excision resulted in an average blood loss of 0.4 mL/cm² excised, compared to 0.75 mL/cm² when performed between days 2 and 16, and 0.49 mL/cm² after day 16. (35) Early excision halved blood loss without adversely affecting mortality, which was 5% for burns averaging 60% TBSA.

Several factors can increase blood loss during burn excision, including older age, male gender, larger body size, extensive full-thickness burns, high wound bacteria counts, total area excised, and longer operative times. (36)

Several strategies can help reduce blood loss during burn excision in the operating room:

1. **Tourniquets:** Particularly effective for extremities, especially hands and fingers. They minimize blood loss but can make it difficult to determine the proper depth of excision. Briefly releasing the tourniquet can help verify adequacy before reapplying it.
2. **Pre-debridement Tumescence:** Injecting a saline solution containing epinephrine into the burn wound induces local vasoconstriction, reducing blood loss. This technique is useful for areas like the trunk, scalp, and face. The solution typically consists of 1.6 mL of 1:1000 epinephrine in 500 mL of 0.45% saline (0.8 mL for pediatric patients). Using one-way syringes or pneumatic infusers can simplify the injection process. (37)
3. **Topical Applications:** Applying epinephrine solutions (1:10,000 to 1:20,000), thrombin, fibrin sealant, autologous platelet gel, or calcium-enriched alginate sheets can help control bleeding. (38)
4. **Immediate Bandaging:** After surgical excision, the exposed wound should be covered with sponges soaked in epinephrine solution. The limb should be elevated for around 10 minutes to diminish bleeding after excision. (38)

These methods collectively help manage blood loss during burn excision, enhancing patient outcomes and surgical efficiency.

3.5 Special cases and considerations for surgical excisions

3.5.1 Large burns

Patients with deep burns covering more than 40% of their total body surface area (TBSA) face significant challenges, particularly in finding enough donor sites for skin grafts. Early, near-total excision of burned tissue within the first few days is crucial. Autografts, taken from the back, buttocks, and posterior thighs at a thickness of 8-10/1000 inches and meshed at a 4:1 ratio, are applied to the wound bed. Fresh allografts are preferred as protective overlays. (39)

Dermal replacements like Integra, although expensive, offer excellent results. Integra is a bilaminar composite consisting of a neodermis made from bovine collagen and shark cartilage chondroitin-6-sulfate, with a silicone layer acting as a neoepidermis. It can be applied to various body parts, including the abdomen and thighs. Hemostasis techniques, such as topical epinephrine and electrocautery, are essential during the procedure. Integra is usually

secured with VAC Therapy or elastic netting and often covered with Acticoat and other protective layers. The neodermis vascularizes in 2-3 weeks, indicated by a straw color and telangiectatic vessels. (40)

The second stage involves removing the silicone layer and applying a 6/1000 inch autograft, which can be meshed up to 3:1. For severely burned patients, staged replacement of the silicone layer with thin autografts may improve long-term outcomes and cosmetic results. However, the effectiveness of Integra in patients with burns over 70% TBSA is debated due to the high infection risk. Initial treatment involves excising all burn wounds and covering them with autografts and allografts. Patients return for additional grafting as donor sites heal.

3.5.2 Massive Burns

For patients undergoing massive burn excisions, maintaining body temperature is crucial due to their high risk of rapid heat loss from exposure and lack of intact skin. In order to prevent heat loss by evaporation, the operating area should be warmed to 32°C. Various techniques can be used to maintain normothermia. These include heating all IV fluids and irrigation solutions, employing space blankets, aluminum foil wraps, plastic sheeting, and infrared heaters. In addition to active heating techniques like infrared or ceramic heaters, insulating blankets, warm sterile blankets, and forced air warming systems can all be utilized. (41)

As an extension of the burn intensive care unit, the burn operating room needs to be roomy, well-ventilated, heated, and well-lit. It must minimize evaporative heat loss and be equipped with filtered warm water and pressurized gas connections for shower heads and dermatomes. The surgical bed should have ceiling brackets for hanging irrigation solutions and equipment, and for suspending extremities. Reliable vascular access is essential, with lines securely sutured to prevent dislodgment during surgery.

When treating a patient with extensive burns, the shoulders, back, buttocks, and upper thighs are treated while the patient is in a prone posture. Usually, wide-meshed autografts are put on top of allografts. If autografts are insufficient, other skin substitutes such as Integra, xenograft, or cryopreserved allografts can be used, though dermal replacements are prone to infection, especially on posterior surfaces. To secure grafts and prevent shearing, silk sutures are used along the posterior axillary lines. After initial excision, the patient is turned to a supine position, and techniques such as tourniquets, epinephrine claysis, and direct pressure are employed to reduce blood loss during debridement.

Once donor sites heal, patients undergo further autografting to replace non-adherent or infected grafts. The use of recombinant human growth hormone (GH) in massively burned children has shown a 25% acceleration in donor site healing, reducing hospital stays and costs. (42) GH-treated patients also required less albumin, indicating improved protein balance. Mortality rates dropped significantly in non-operatively treated patients. While two European studies found increased mortality in critically ill GH-treated adults, this was not observed in North American pediatric patients. Other anabolic agents, such as oxandrolone, have also demonstrated improved wound healing and protein kinetics, further supporting burn recovery. However, these pharmacological agents are supplementary to early excision and wound coverage. (43)

3.5.3 Excisions on the head and face

Scalp and skull burns present significant challenges due to the potential involvement of vital organs. These injuries fall into two groups: those that merely damage soft tissue and those that involve the calvarium. Debridement, skin grafting, and flap covering are the methods used to treat scalp burns that do not involve bone. Treatment for burns that reach the bone depends on the severity and depth of the damage. In children especially, bone loss less than 2 cm usually heals on its own, whereas adult bone regeneration is less consistent. Debridement and covering the wound without damaging nearby tissues are the main goals of first care. Tissue expanders or bone grafts should wait till after the acute period. In surgical debridement, necrotic soft tissue and bone are removed while the cerebral layers are preserved. A drill with a diamond-head is frequently used for accuracy in this process. The excision stops at a depth suitable for skin graft application. Antibiotic prophylaxis is essential to prevent central nervous system infections, and clotting agents like thrombin foam or gel are used in cases of cerebrospinal fluid leaks. (44)

3.5.4 Facial excision and wound closure

Burns injuries on the face are highly challenging by affecting vital structures such as the upper airway, eyes, and ears and can have devastating consequences for the injured. Successful management requires careful attention to detail, skillful excision, appropriate coverage, and thorough postoperative care. With a maximum waiting period of 18 days, early excision is generally preferred to prevent contractures and produce superior aesthetic

outcomes, albeit no large, randomized trials have compared grafting after eschar separation and granulation to early excision and grafting.

When excision and grafting are planned, the selection of donor sites is crucial. Ideally, for the best aesthetical outcome, donor skin should come from above the nipple line due to matching skin tones, with the scalp being an excellent choice despite the risk of hair follicle transplantation. The upper back can also be used as an alternative. Unmeshed sheet grafts are preferred for facial application, but in limited availability of suitable donor sites it might be necessary to cover the site temporarily with unmeshed allograft.

The main method for excising facial burns is using a Goulian/Weck knife, particularly for tangential excision to preserve viable dermal elements. Tools like the Versajet can be used for precise excision, especially in contoured areas. (31) Significant blood loss during excision can be mitigated by using epinephrine claysis, epinephrine-moistened sponges, topical thrombin, and electrocautery for hemostasis. (38,45)

Grafts should mimic the face's aesthetic units and be used as single continuous pieces across adjacent cosmetic areas to reduce seams. Securing grafts can be done with staples, sutures, glues, or fibrin sealant, which helps minimize fluid collections and reduces the need for other securing methods. Medical-grade glues like Histoacryl are effective for securing graft edges.

Post-grafting care involves positioning tubes and lines away from grafts, using septal ties for endotracheal tubes, and frequently checking grafts for movement or need for drainage due to fluid collection. In cases of extensive soft tissue injury without underlying bone, flap coverage with regional or free tissue transfer may be considered. If sinuses are exposed, free vascularized omental transfers can be used to fill dead spaces, similar to facial trauma management. (46)

Overall, detailed and careful management of facial burns, including early excision, appropriate donor site selection, and meticulous graft placement and postoperative care, is crucial for preserving function and achieving the best possible cosmetic outcomes. (47,48)

3.5.5 Eyelid

Early excision and grafting are essential for deep burns affecting the eyelids to prevent cicatricial ectropion, which can lead to incomplete lid closure and expose the eyes to risks like desiccation and corneal ulceration, potentially jeopardizing vision. This condition is particularly critical in unconscious ventilated patients. Once a diagnosis is made, immediate management entails releasing scars and putting split-thickness skin grafts to the upper lids and

full-thickness skin grafts to the lower lids. Large face burns frequently involve the eyelids. To preserve eye moisture and avoid exposure keratitis, preventative measures including frequent use of ocular lubricants should be taken, especially in patients who are unconscious. Early tarsorrhaphy (a bedside procedure) or relaxation of closed eyelids may be required in cases of burn ectropion. Additionally, if eyelid contraction results in corneal exposure and irritation—a condition that can be treated with a range of surgical techniques, including skin grafts and local flaps—acute relaxation of the upper and lower eyelids may be considered. When there is a loss of full-thickness of the eyelid, the inner lining of the lid may need to be rebuilt using specific materials. (49,50)

IV. Skin grafting and tissue expansion

4.1 Techniques of wound closure

Techniques of wound closure depends on the depth and degree of injury. Therefore, for full-thickness burns wound closure typically involve excision and grafting, using either full-thickness or split-thickness autografts. Full-thickness autografts include more of the dermal layer, offering better cosmetic outcomes and less scarring due to their flexibility and elasticity. However, their increased dermal content can compromise their viability during the graft take phases of imbibition, inosculation, and neovascularization. Additionally, donor sites for full-thickness grafts must be closed or grafted as they lack dermis.

Split-thickness autografts are primarily used for extensive burns and are easier to manage and more viable for covering large areas.

Different grafting techniques are employed based on the size and location of the burns. Sheet grafts, which are used for small burns without meshing, provide better cosmetic and functional outcomes but have a risk of seroma or hematoma formation, which can be managed through rolling or aspiration. These grafts are generally placed perpendicular to the limb axes to reduce the risk of contractures, except possibly on the dorsum of the hand and forearm.

For larger burns with limited donor sites, meshed grafts are employed. These autografts can be meshed to expand their coverage. Common mesh ratios are 2:1 and 4:1. The 2:1 meshing is easy to handle, allows fluid drainage, but leaves a visible diamond pattern on the healed area. The 4:1 meshing covers larger areas but requires an allograft overlay in a

sandwich pattern to reduce graft loss. This technique is reserved for massively burned patients due to handling difficulties and poor cosmetic results.

The Meek technique involves cutting autografts into small squares and expanding them uniformly. This method can expand grafts from ratios of 1:3 to 1:9 but also requires an allograft overlay and shares similar drawbacks with high-ratio meshing. (51–55)

4.2 Dermal replacement

The dermis is crucial for providing skin with flexibility, elasticity, and strength. When full-thickness burns are excised, the entire dermis is removed, resulting in the formation of scar tissue that lacks these properties. Dermal replacements have emerged as a promising solution, offering characteristics similar to the natural dermis and improving healing outcomes.

Integra, a widely used dermal replacement in burn treatment, consists of a porous matrix made of glycosaminoglycan and cross-linked bovine collagen. This matrix is applied to the wound bed following excision of the damaged tissue. Integra functions as a scaffold, promoting cellular invasion and capillary development within the wound. This process is crucial for effective healing as it supports the formation of new tissue and blood vessels, facilitating the integration of the matrix into the wound bed.

The integration of Integra into the wound bed typically takes two to three weeks. During this period, the matrix allows for the infiltration of fibroblasts, endothelial cells, and other critical components necessary for tissue regeneration. Once the matrix is fully integrated and stable, a thin split-thickness autograft is applied on top of it. This autograft covers the newly formed dermal layer, providing an epidermal layer to complete the skin's structure.

Although the use of Integra is generally safe and effective, there is a slight increase in the risk of infection associated with its application. This is due to the foreign nature of the matrix, which can potentially serve as a substrate for bacterial growth if not managed properly. Therefore, meticulous wound care and monitoring are essential to mitigate this risk.

To further support the engraftment process and enhance the outcomes, negative-pressure wound therapy (NPWT), also known as vacuum-assisted closure (VAC) therapy, can be employed. VAC therapy involves the application of a controlled negative pressure environment to the wound, which helps to draw out excess fluids, reduce edema, and promote better perfusion. This negative pressure aids in stabilizing the graft, enhancing the adherence of the Integra matrix and the subsequent split-thickness autograft to the wound bed.

Moreover, NPWT can help in reducing the bacterial load and promoting a moist wound environment, which is conducive to faster and more effective healing. (40)

Another dermal analog used for treating full-thickness burns is Alloderm, derived from cadaveric dermis stripped of cells and epithelial elements. Applied to the wound bed after excision, Alloderm serves as a natural scaffold for tissue regeneration. It is typically covered with a split-thickness skin graft. Clinically, Alloderm shows favorable results due to its natural properties, reduced immunogenicity, and effective integration, improving both aesthetic and functional outcomes for burn patients.(56)

In summary, dermal replacements like Integra and Alloderm provide structural support and enhance the functional properties of healed skin, despite some risk of infection. These materials represent significant advancements in burn treatment, offering improved outcomes for patients. (57)

4.3 Cultured epidermal autograft

When more than 90% of the total body surface area (TBSA) is injured, cultured epidermal autograft (CEA) is essential for handling patients with extensive burns since traditional skin transplants from unaffected areas are insufficient. (58) CEA involves harvesting small full-thickness skin samples from unburned areas, which are then cultured *ex vivo* with murine fibroblasts to promote growth. The process takes about three weeks, producing sheets of keratinocytes that are 2-8 cells thick.

CEA significantly reduces mortality in massively burned patients, as demonstrated by Munster's research. However, the fragility of these thin grafts makes them prone to shearing and blistering, particularly on posterior surfaces like the back, buttocks, and lower extremities. This fragility partly explains the varied long-term engraftment rates of 5-50% reported in the literature.

Comparative studies, such as one by Barret and colleagues, have shown that while CEA offers better cosmetic results than widely meshed autografts with allograft overlays, it also involves longer hospital stays and more reconstructive surgeries. (59) Despite these challenges and the high cost, CEA has shown promising results, especially when used with allograft dermis, achieving over 72% graft take according to Sood and colleagues.

Advances in tissue engineering, including successful trials with fetal skin constructs and bilaminar cultured skin substitutes, indicate significant future improvements in burn treatment outcomes. (60)

4.4 Skin procurement

A number of factors must be taken into account while selecting the ideal donor site for skin grafts, such as reducing patient discomfort and matching the recipient area's color. Donor sites often cause more pain than the original burn wounds or graft areas. For aesthetic reasons, it is important to select grafts that closely match the color of the recipient site, especially for areas visible in day-to-day life like the face and neck.

Although there are few suitable donor sites for patients with severe burns, the axilla, mons pubis, and scrotum are usually good choices. These areas, despite their irregular surfaces, can provide useful skin grafts, especially when tumescence is applied. In extreme cases the soles of the feet can be used but need additional preparations. The first layer, the stratum corneum, is removed and cannot be used due to a lack of viable epithelial cells.

In case of severely burned patients' multiple operations will be required for adequate wound coverage due to the limited availability of donor sites. The time it takes for donor sites to heal, which depends on the proliferation and migration of epithelial cells from hair follicles, sweat glands, and oil glands deep in the dermis, is a crucial factor in the timing of repeat grafting procedures. (61)

4.5 Donor site

In order to facilitate healing after obtaining a skin graft, the donor site wound must be carefully managed. Smaller donor sites can be treated with hydrocolloid fiber dressings, alginate sheets, or adherent or occlusive dressings like Opsite or Biobrane, which may lessen pain and provide a moist healing environment. (62) Using gauze impregnated with oil-based ointments, such Xeroform, or dressings made of a mixture of lanolin, petrolatum, olive oil, and Sudan red are further options. (63) Acticoat, Acticoat Absorbent, and Aquacel Ag are examples of silver-impregnated dressings that work well in minimizing bacterial overgrowth. (64) These dressings can be placed directly to the donor site or as an intermediate layer. The process of epithelialization from the residual epithelial elements is the major mechanism of healing of skin transplant donor sites. The depth of the procurement, the donor site's vascularity, wound care, and the patient's general health all affect how long a wound takes to heal. (65,66)

V. Challenges in Surgical Treatment Care

5.1 Infection

Burn wounds are highly susceptible to colonization by opportunistic organisms, originating from both endogenous and exogenous sources. Factors influencing the possibility of invasive infection of the burn wound include patient-specific variables like age, extent, and depth of the injury, as well as microbiological factors which include the kind and number of organisms, their ability to produce enzymes and toxins, and their motility. These infections are categorized based on the causative organisms, the invasion depth, and the response of affected tissue. Effective diagnosis and treatment require a thorough understanding of the burn wound's pathophysiology and the pathogenesis of different types of infection.

Gram-positive bacteria typically shifts to gram-negative bacteria as the predominant flora during the course of the development of the burn wound which reflects the historical patterns of burn wound infections. Early diagnosis of gram-positive cellulitis is possible through clinical and culture surveillance, with beta-hemolytic streptococci's susceptibility to penicillin reducing its prevalence as a burn wound pathogen. However, the rise of resistant species like *Pseudomonas aeruginosa* poses new challenges due to intrinsic and acquired resistance mechanisms. Despite this, advancements in topical antimicrobial treatments and early excision of burn wounds have significantly lowered the incidence of invasive infections.

Nonetheless, patients with extensive burns who have difficulty achieving wound closure remain at risk for various bacterial and nonbacterial infections. Therefore, daily examination of the entire burn wound by the attending surgeon is crucial. Any change in the wound's appearance should prompt a biopsy for evaluation. While quantitative cultures can identify predominant organisms, they are not useful for diagnosing invasive infections. Histologic examination of biopsy specimens is the only reliable method for distinguishing between wound colonization and invasive infection and helps in identifying the specific histologic changes associated with bacterial, fungal, and viral infections. This facilitates the selection of appropriate therapy.

Changes in local and systemic therapy are necessary for invasive burn wound infections, and urgent surgical removal of infected tissue is necessary for fungal and bacterial infections. Burn wound impetigo, frequently brought on by *Staphylococcus aureus*, can develop even after wound healing or grafting. It presents as tiny superficial abscesses that require surgical debridement. (67,68)

5.2 Infection and rejection of allograft Skin

Allograft skin, while effective as a wound covering, contains Langerhans cells that express class II antigens, leading to immune rejection and acute inflammatory reactions, which can cause wound infections, therefore, skin banks must conduct microbial cultures before releasing tissue for transplantation. Typically, these grafts last 2–3 weeks, though survival up to 67 days has been noted in immunosuppressed burn patients. (53) However, advancements in immunonutrition, critical care, and aggressive wound closure have made graft persistence less predictable.

To prevent rejection, various methods have been tried. Reducing antigen expression by treating allografts with ultraviolet light and glucocorticoids has shown some success in extending graft survival, though its effectiveness is not well-established. Pharmacologic immunosuppression has also been explored. Initial trials using azathioprine and antithymocyte globulin in children improved survival but caused neutropenia, and results were inconsistent.

More recent studies with cyclosporin A have shown promise in prolonging allograft survival in patients with severe burns, though rejection often occurred shortly after stopping treatment. Further research on these and new immunosuppressive agents is needed. (69)

VI. Advances in Surgical Reconstruction Techniques

6.1 Emerging technologies and innovations in burn reconstruction

The degree of the skin injury as well as the kind and size of the nanoparticles determine how well they work in treating burns. Affected skin has compromised its ability to act as a barrier, making it more susceptible to absorbing bigger particles into the body. For topical drug delivery, biodegradable, non-toxic, and non-immunogenic nanocarriers are ideal. In order to prevent systemic absorption, they should release the medication in a regulated manner with therapeutic benefits restricted to the wound site. Nanocarriers should have mucoadhesive properties to increase their residence time on the skin. Whether the nanocarriers are from synthetic or natural sources, the matrix composition is important to minimize side effects and provide proper metabolic and biodegradation profiles. Nanoparticles should be chosen for their size and kind in order to reduce systemic absorption and limit pharmacological activity to the wound site.

Polymeric nanoparticles can be created from natural, semi-synthetic, or synthetic polymers and have a size range of 10 to 1000 nm. Drugs can be bonded to the surface of the nanoparticle matrix or encapsulated within it, depending on the type of polymer. The chemical makeup, size of the particles, and viscosity of the formulation of these nanoparticles determine their capacity to penetrate epidermal layers. They have many benefits, including high drug loading capacity, controlled drug release, stability, ease of manufacture, and a variety of sizes and forms. Organic polymers, like chitosan, are biocompatible and biodegradable but may vary between batches and can be immunogenic. Synthetic polymers have predictable properties due to their known chemical composition.

Chitosan, a polysaccharide derived from chitin, is notable for its non-toxicity, biocompatibility, biodegradability, antimicrobial activity, and low immunogenicity. It is used in various industries and has properties that enhance wound healing. Studies have shown chitosan's ability to support the activity of fibroblasts, macrophages, and leukocytes, improving wound healing. Researchers have developed chitosan-based nanoparticles and biomaterials that encapsulate therapeutic agents, such as fibroblast growth factor, to enhance their stability and efficacy in wound healing. These formulations have demonstrated controlled drug release, reduced degradation, and improved wound healing in various studies. Metal nanoparticles, especially silver nanoparticles (AgNPs), are widely used for their antimicrobial properties. AgNPs can disrupt microbial cell membranes and interfere with DNA replication and protein synthesis. They are produced by physical, chemical, or biological methods and have been incorporated into various wound treatment materials, showing high antimicrobial activity and biocompatibility.

Nanogels, composed of nanoscale hydrogel particles, can absorb large amounts of water or biological fluids. They are biocompatible and prevent enzymatic drug degradation but may risk leakage if particle sizes are smaller than the pore meshes. Studies on silver sulfadiazine-loaded nanogels have shown effective controlled drug release and improved therapeutic efficacy in burn wound models.

Acute or chronic wound dressings offer protection and aid in the healing process. Ideal dressings manage exudate, maintain a moist environment, allow gas exchange, and are easy to use and cost-effective. Modern dressings, often made from synthetic polymers, offer advantages over traditional dressings by maintaining a humid environment and accelerating healing. Antimicrobial dressings, designed to prevent infections, may contain agents like silver, iodine, or natural products. These dressings should be used for a limited time to minimize resistance.

Various studies have developed innovative wound dressings, such as chitosan/PVA scaffolds loaded with silver or selenium and cerium-crosslinked alginate films. These formulations showed strong antimicrobial activity and improved physical properties, making them suitable for antibacterial wound dressings. (70)

6.2 Tissue engineering in burn care

As an interdisciplinary area tissue engineering and regenerative medicine (TERM) combines biology and engineering with clinical practice to improve wound healing and skin regeneration, particularly in cases of acute and chronic thermal injuries. To produce scaffolds that enable skin regeneration, this field makes use of cutting-edge biomaterials, sophisticated technologies like electrospinning, recombinant proteins, and 3D printing, as well as techniques for adding autologous cells. A notable approach involves alpha-gal nanoparticles, which harness natural antibodies to accelerate healing and reduce scarring.

In tissue engineering, biomaterials can be synthetic (polylactic acid and polyglycolic acid) or natural (collagen, hyaluronic acid, elastin, chitin, and fibrin). Natural biomaterials are favored for their biocompatibility and biodegradability, while synthetic polymers offer predictable properties. Steffens et al. developed poly-D,L-lactic acid (PDLLA) scaffolds via electrospinning, integrating laminin-332 to support cell growth and skin regeneration. Dermal and epidermal regeneration is significantly enhanced when mesenchymal stem cells and keratinocytes are added to these scaffolds.

Recombinant proteins, such as elastin-like polypeptides, are examples of novel therapeutics. Recombinant human tropoelastin was investigated by Xie et al. to increase skin suppleness in burn injuries, demonstrating new elastin fiber production without significant improvement in flexibility. Severe burns often require skin substitutes for effective treatment, examples of which are biocompatible structures which need to be 3 dimensional for effective use.

Hydrogels of hyaluronic acid methylcellulose (HAMC) have been studied for 3D bioprinting, demonstrating their potential for cell transport and scaffold architectures.

Gholipourmalekabadi et al. created a bi-layer scaffold that supported mesenchymal stem cells' development and expression of growth factors by utilizing decellularized human amniotic membrane and silk fibroin. By using decellularized pig skin and human blood cells to make a composite gel, Kuna et al. considerably sped up the healing of mice's wounds.

Human dermal fibroblasts coupled with decellularized skin extracellular matrix (ECM) to create bio-inks has demonstrated remarkable vitality and potential for skin regeneration.

Growth factor delivery, such as using bFGF-loaded alginate microspheres in composite hydrogels, has also demonstrated beneficial effects on tissue repair, enhancing wound recovery and dermal regeneration.

Overall, TERM leverages advanced materials and technologies to improve burn wound treatment, although challenges like infection susceptibility and functional limitations of compromised skin tissue must be addressed to ensure the success of these innovative therapies. (70)

VII. Discussion of potential areas for further research and advancements

The future of surgical treatment for burn injuries holds immense promise, driven by continuous advancements in technology, materials science, and regenerative medicine. Future research is likely to focus on improving outcomes through more effective wound healing, scar reduction, and functional restoration. Here are several key areas where significant advances are anticipated:

Advanced Biomaterials and Scaffolds:

Future research will likely focus on developing new biomaterials that mimic the natural extracellular matrix more closely. These materials will not only support cell adhesion, proliferation, and differentiation but also promote angiogenesis and reduce scarring. Innovations in biocompatible and bioactive materials, including smart polymers that can respond to environmental stimuli, will enable more adaptive and effective wound healing solutions.

Enhanced Stem Cell Therapies:

Stem cell therapy is expected to advance significantly, with a focus on optimizing the delivery and integration of stem cells to enhance tissue regeneration. Research into induced pluripotent stem cells (iPSCs) could allow for the creation of patient-specific stem cells, reducing the risk of immune rejection. Combining stem cells with gene editing technologies like CRISPR could further enhance their regenerative capabilities, potentially correcting genetic defects and enhancing their therapeutic potential.

3D Bioprinting and Tissue Engineering:

3D bioprinting is poised to revolutionize burn treatment by enabling the production of complex tissue structures that might be able to replicate human skin. Advances in bioprinting technology will improve the precision and scalability of creating skin grafts, incorporating multiple cell types, vascular structures, and even hair follicles. Research will focus on improving the bio-inks used in 3D printing to ensure they provide the necessary support for cell survival and integration post-transplantation.

Gene Therapy and Regenerative Medicine:

Gene therapy holds potential for treating severe burns by directly modifying the genetic material of cells to enhance their regenerative properties. This approach could be used to upregulate growth factors, cytokines, or other proteins essential for wound healing. Regenerative medicine strategies may also involve the use of exosomes or other cell-derived vesicles that can deliver therapeutic molecules directly to the wound site, promoting healing and reducing inflammation.

Smart Dressings and Sensors:

The development of smart dressings embedded with sensors will enable real-time monitoring of the wound environment. These dressings can detect changes in pH, temperature, and moisture levels, providing valuable data to guide treatment decisions. Future smart dressings could also deliver drugs, growth factors, or other therapeutics in a controlled manner, responding dynamically to the wound's needs to optimize healing conditions.

AI and Machine learning in Burn care

The integration of artificial intelligence (AI) and machine learning (ML) in burn care holds the potential to revolutionize the field by enhancing diagnosis, treatment planning, and outcome prediction. AI algorithms can analyze extensive data from sensors, patient records, and imaging technologies to provide highly personalized treatment recommendations. These algorithms can predict complications before they arise and monitoring the healing progress in real-time, ensuring timely interventions.

Machine learning models are particularly valuable in simulating various treatment scenarios. By evaluating different strategies, these models help clinicians choose the most effective approach tailored to the individual needs of each patient. This ability to simulate outcomes can lead to more precise and effective treatment plans.

In addition to treatment planning, AI and ML can assist in real-time decision-making during surgeries, offering insights and recommendations based on vast amounts of medical data and previous cases. These technologies also aid in formulating comprehensive rehabilitation plans, ensuring that recovery processes are optimized for the best possible outcomes.

Overall, the application of AI and ML in burn care promises to enhance precision, efficiency, and patient outcomes, making these technologies indispensable tools in modern medical practice.

Nanotechnology:

Nanotechnology offers exciting possibilities for burn treatment, including the development of nanoparticle-based drug delivery systems that can target specific cells or tissues. Nanoparticles can be engineered to deliver growth factors, antibiotics, or other therapeutics directly to the wound site, enhancing their effectiveness and reducing side effects. Nanofibrous scaffolds can also provide structural support for cell growth and tissue regeneration. (70)

Virtual and Augmented Reality:

The use of virtual reality (VR) and augmented reality (AR) in surgical training and planning is expected to grow significantly in the coming years. These cutting-edge technologies offer immersive training environments that allow surgeons to practice and refine their skills in a risk-free setting. VR can simulate a wide range of surgical scenarios, enabling practitioners to gain experience with complex procedures and rare cases that they might not encounter frequently in real life. This hands-on, experiential learning can lead to improved skills, confidence, and precision in performing intricate surgeries.

In addition to training, AR can play a crucial role during actual surgical procedures. By overlaying digital information onto the real-world surgical field, AR can provide real-time guidance and enhanced visualization for surgeons. For example, AR can display critical data such as patient vitals, 3D models of anatomy, or the precise location of tumors and blood vessels, directly onto the surgical site. This integration of digital information helps surgeons make more informed decisions, increasing the accuracy and safety of the procedures. Overall, the adoption of VR and AR in surgery holds great promise for advancing surgical education and improving patient outcomes.

VIII. Summary and conclusion

Burn injuries, impacting the body's largest organ—the skin—are complex and necessitate specialized care. The skin's structure, comprising the epidermis and dermis, plays a crucial role in protection and healing. Superficial burns, limited to the epidermis, generally heal without scarring but may alter pigmentation. Deeper burns involving the dermis require more intensive treatment due to the presence of essential structures like sweat glands, hair follicles, and nerve endings.

Burns are classified by their cause, depth, and the body surface area affected. Partial-thickness burns, which penetrate the dermis, typically heal within weeks, while full-thickness burns extend through all skin layers, often requiring surgical intervention. The severity of burns is influenced by the temperature of the causative agent and the exposure duration, leading to protein denaturation and cell death. Epidemiological data from 2022 highlighted that a significant number of burn patients, especially children, required inpatient treatment, indicating the necessity for targeted interventions.

Thermal burns are prevalent, resulting from flash and flame exposures, scalds, and contact with hot objects. Electrical burns vary from minor to severe, necessitating prompt surgical intervention, while chemical burns, often from industrial incidents, require immediate flushing. Radiation burns, depending on the type and extent of exposure, range in severity. Effective management of burn injuries involves initial assessment and stabilization, followed by early excision and grafting, critical for deep burns to prevent complications and promote healing. Techniques such as tangential excision, sharp debridement, and enzymatic debridement are employed based on burn characteristics. Special cases, like large burns, require maintaining body temperature and minimizing infection risks, with meticulous care for burns on the head, face, and eyelids to preserve function and aesthetics.

Wound closure for full-thickness burns involves autografts, with full-thickness grafts offering better cosmetic outcomes and split-thickness grafts preferred for extensive coverage. Techniques like sheet grafts, meshed grafts, and the Meek technique are used based on burn size and location. Dermal replacements such as Integra and Alloderm enhance healing but carry infection risks. Cultured Epidermal Autografts (CEA) are vital for extensive burns, reducing mortality but requiring multiple surgeries and long hospital stays.

Selecting donor sites and managing donor wounds with occlusive dressings promote healing and reduce pain. Infection management is crucial, with early excision and topical antimicrobials reducing risks, although extensive burns still carry infection risks, necessitating regular examination.

Advances in surgical reconstruction techniques are emerging, with nanoparticles, particularly polymeric and metal nanoparticles, showing promise for controlled drug release and antimicrobial properties. Tissue engineering and regenerative medicine leverage biomaterials, 3D bioprinting, and stem cell therapies to support skin regeneration. Innovations include alpha-gal nanoparticles, PDLA scaffolds, and bi-layer scaffolds for improved healing, alongside research into gene therapy, smart dressings with sensors, and the integration of AI and ML for personalized treatment.

Future research in burn care aims to develop advanced biomaterials, optimize stem cell therapies, enhance 3D bioprinting, and explore gene therapy. Smart dressings, nanotechnology-based drug delivery systems, and virtual and augmented reality in surgical training and planning hold significant promise for improving wound healing, reducing scarring, and enhancing functional restoration.

Overall, continuous advancements in burn care, driven by interdisciplinary collaboration and technological innovations, aim to significantly improve patient outcomes and quality of life.

IX. Literature

1. Tyack ZF, Pegg S, Ziviani J. Postburn dyspigmentation: its assessment, management, and relationship to scarring--a review of the literature. *J Burn Care Rehabil.* 1997;18(5):435–40.
2. Compton CC, Press W, Gill JM, Bantick G, Nadire KB, Warland G, et al. The generation of anchoring fibrils by epidermal keratinocytes: a quantitative long-term study. *Epithelial Cell Biol.* 1995;4(3):93–103.
3. Vivó C, Galeiras R, del Caz MDP. Initial evaluation and management of the critical burn patient. *Med Intensiva.* 2016;40(1):49–59.
4. Deitch EA, Wheelahan TM, Rose MP, Clothier J, Cotter J. Hypertrophic Burn Scars: Analysis of Variables. *J Trauma Inj Infect Crit Care.* 1983 Oct;23(10):895–8.
5. Shpichka A, Butnaru D, Bezrukov EA, Sukhanov RB, Atala A, Burdukovskii V, et al. Skin tissue regeneration for burn injury. *Stem Cell Res Ther.* 2019 Dec;10(1):94.
6. Martin NA, Falder S. A review of the evidence for threshold of burn injury. *Burns.* 2017 Dec;43(8):1624–39.
7. Zawacki BE. Reversal of Capillary Stasis and Prevention of Necrosis in Burns: *Ann Surg.* 1974 Jul;180(1):98–102.
8. Hettiaratchy S, Dziewulski P. Pathophysiology and types of burns. *BMJ.* 2004 Jun 12;328(7453):1427–9.
9. Priv.-Doz. Dr. Oliver C. Thamm. Jahresbericht 2023. deutsches Verbrennungsregister; 2023.
10. Ding YL, Pu SS, Pan ZL, Lu X, Miao SG, Han CM, et al. Extensive scalds following accidental immersion in hot water pools. *Burns.* 1987 Aug;13(4):305–8.
11. Walker AR. Fatal tapwater scald burns in the USA, 1979–1986. *Burns.* 1990 Feb;16(1):49–52.
12. Desai MH, Rutan RL, Herndon DN. Conservative Treatment of Scald Burns Is Superior to Early Excision: *J Burn Care Rehabil.* 1991 Sep;12(5):482–4.
13. Bird PE, Harrington DT, Barillo DJ, McSweeney A, Shirani KZ, Goodwin CW. Elder Abuse: A Call to Action. *J Burn Care Rehabil.* 1998 Nov;19(6):522–7.
14. Gibran NS, Engrav LH, Heimbach DM, Swiontkowski MF, Foy HM. Engine block burns: Dupuytren's fourth-, fifth-, and sixth-degree burns. *J Trauma.* 1994 Aug;37(2):176–81.
15. Yanofsky NN, Morain WD. Upper extremity burns from woodstoves. *Pediatrics.* 1984 May;73(5):722–6.

16. Chilbert M, Maiman D, Sances A, Myklebust J, Prieto TE, Swiontek T, et al. Measure of Tissue Resistivity in Experimental Electrical Burns: *J Trauma Inj Infect Crit Care*. 1985 Mar;25(3):209–15.
17. Mann R, Gibran N, Engrav L, Heimbach D. Is immediate decompression of high voltage electrical injuries to the upper extremity always necessary? *J Trauma*. 1996 Apr;40(4):584–7; discussion 587-589.
18. Bertolini JC. Hydrofluoric acid: a review of toxicity. *J Emerg Med*. 1992;10(2):163–8.
19. Siegel DC, Heard JM. Intra-arterial calcium infusion for hydrofluoric acid burns. *Aviat Space Environ Med*. 1992 Mar;63(3):206–11.
20. Bhattacharya S. Radiation injury. *Indian J Plast Surg Off Publ Assoc Plast Surg India*. 2010 Sep;43(Suppl):S91-93.
21. Forage AV. THE HISTORY OF THE CLASSIFICATION OF BURNS (DIAGNOSIS OF DEPTH). *Br J Plast Surg*. 1963 Jul;16:239–42.
22. Yeong EK, Mann R, Goldberg M, Engrav L, Heimbach D. Improved accuracy of burn wound assessment using laser Doppler. *J Trauma*. 1996 Jun;40(6):956–61; discussion 961-962.
23. Herndon DN, Tompkins RG. Support of the metabolic response to burn injury. *Lancet Lond Engl*. 2004 Jun 5;363(9424):1895–902.
24. Heimbach DM. Early burn excision and grafting. *Surg Clin North Am*. 1987 Feb;67(1):93–107.
25. Saaiq M, Zaib S, Ahmad S. Early excision and grafting versus delayed excision and grafting of deep thermal burns up to 40% total body surface area: a comparison of outcome. *Ann Burns Fire Disasters*. 2012 Sep 30;25(3):143–7.
26. Xiao-Wu W, Herndon DN, Spies M, Sanford AP, Wolf SE. Effects of delayed wound excision and grafting in severely burned children. *Arch Surg Chic Ill 1960*. 2002 Sep;137(9):1049–54.
27. Greenwood JE. Advantages of immediate excision of burn eschar. *Anaesth Intensive Care*. 2020 Mar;48(2):89–92.
28. Janzekovic Z. Once upon a time ... how west discovered east. *J Plast Reconstr Aesthetic Surg JPRAS*. 2008;61(3):240–4.
29. Evans AJ. Use of the humby knife in the excision of burns. *Br Med J*. 1952 Nov 1;2(4791):979.
30. Daugherty THF, Ross A, Neumeister MW. Surgical Excision of Burn Wounds: Best Practices Using Evidence-Based Medicine. *Clin Plast Surg*. 2017 Jul;44(3):619–25.

31. Klein MB, Hunter S, Heimbach DM, Engrav LH, Honari S, Gallery E, et al. The Versajet water dissector: a new tool for tangential excision. *J Burn Care Rehabil.* 2005;26(6):483–7.
32. Kakagia DD, Karadimas EJ. The Efficacy of Versajet™ Hydrosurgery System in Burn Surgery. A Systematic Review. *J Burn Care Res Off Publ Am Burn Assoc.* 2018 Feb 20;39(2):188–200.
33. Giudice G, Filoni A, Maggio G, Bonamonte D, Vestita M. Cost Analysis of a Novel Enzymatic Debriding Agent for Management of Burn Wounds. *BioMed Res Int.* 2017;2017:9567498.
34. Mataro I, Lanza A, Di Franco S, Di Franco L, Sangiuolo M, Notaro M, et al. Releasing Burn-Induced Compartment Syndrome by Enzymatic Escharotomy-Debridement: A Case Study. *J Burn Care Res Off Publ Am Burn Assoc.* 2020 Sep 23;41(5):1097–103.
35. Desai MH, Herndon DN, Broemeling L, Barrow RE, Nichols RJ, Rutan RL. Early burn wound excision significantly reduces blood loss. *Ann Surg.* 1990 Jun;211(6):753–9; discussion 759-762.
36. Hart DW, Wolf SE, Beauford RB, Lal SO, Chinkes DL, Herndon DN. Determinants of blood loss during primary burn excision. *Surgery.* 2001 Aug;130(2):396–402.
37. Husain S, Ofodile FA. Tumescence technique for burn wound debridement: a cost effective method of reducing transfusion requirements. *J Coll Physicians Surg--Pak JCPSP.* 2006 Mar;16(3):227–8.
38. Snelling CF, Shaw K. The effect of topical epinephrine hydrochloride in saline on blood loss following tangential excision of burn wounds. *Plast Reconstr Surg.* 1983 Dec;72(6):830–6.
39. Sahin I, Alhan D, Nişancı M, Ozer F, Eski M, Işık S. Auto-/homografting can work well even if both autograft and allograft are meshed in 4:1 ratio. *Ulus Travma Ve Acil Cerrahi Derg Turk J Trauma Emerg Surg TJTES.* 2014 Jan;20(1):33–8.
40. Taupin P, Gandhi A, Saini S. Integra® Dermal Regeneration Template: From Design to Clinical Use. *Cureus.* 2023 May;15(5):e38608.
41. Driver J, Fielding A, Mullhi R, Chipp E, Torlinski T. Temperature management of adult burn patients in intensive care: findings from a retrospective cohort study in a tertiary centre in the United Kingdom. *Anaesthesiol Intensive Ther.* 2022;54(3):226–33.
42. Przkora R, Herndon DN, Suman OE, Jeschke MG, Meyer WJ, Chinkes DL, et al. Beneficial effects of extended growth hormone treatment after hospital discharge in pediatric burn patients. *Ann Surg.* 2006 Jun;243(6):796–801; discussion 801-803.

43. Gus EI, Shahrokhi S, Jeschke MG. Anabolic and anticatabolic agents used in burn care: What is known and what is yet to be learned. *Burns J Int Soc Burn Inj.* 2020 Feb;46(1):19–32.
44. Hunt J, Purdue G, Spicer T. Management of full-thickness burns of the scalp and skull. *Arch Surg Chic Ill 1960.* 1983 May;118(5):621–5.
45. Foster K, Greenhalgh D, Gamelli RL, Mazingo D, Gibran N, Neumeister M, et al. Efficacy and safety of a fibrin sealant for adherence of autologous skin grafts to burn wounds: results of a phase 3 clinical study. *J Burn Care Res Off Publ Am Burn Assoc.* 2008;29(2):293–303.
46. Acikel C, Peker F, Ulkur E. Skin grafting of the naso-orbital region as a single aesthetic unit. *Burns J Int Soc Burn Inj.* 2001 Nov;27(7):753–7.
47. Engrav LH, Heimbach DM, Walkinshaw MD, Marvin JA. Excision of burns of the face. *Plast Reconstr Surg.* 1986 May;77(5):744–51.
48. Horch RE, Jeschke MG, Spilker G, Herndon DN, Kopp J. Treatment of second degree facial burns with allografts--preliminary results. *Burns J Int Soc Burn Inj.* 2005 Aug;31(5):597–602.
49. Barrow RE, Jeschke MG, Herndon DN. Early release of third-degree eyelid burns prevents eye injury. *Plast Reconstr Surg.* 2000 Mar;105(3):860–3.
50. Jiaqi C, Zheng W, Jianjun G. Eyelid reconstruction with acellular human dermal allograft after chemical and thermal burns. *Burns J Int Soc Burn Inj.* 2006 Mar;32(2):208–11.
51. McGovern KP, Rizzo JA. Major Burn Injury Successfully Treated With Cultured Epithelial Autografts, a Case Series Presentation: Establishing Standard Clinical Practices. *J Burn Care Res Off Publ Am Burn Assoc.* 2023 May 2;44(3):709–14.
52. Meek CP. Successful microdermagrafting using the Meek-Wall microdermatome. *Am J Surg.* 1958 Oct;96(4):557–8.
53. Calota DR, Nitescu C, Florescu IP, Lascar I. Surgical management of extensive burns treatment using allografts. *J Med Life.* 2012 Dec 15;5(4):486–90.
54. Alexander JW, MacMillan BG, Law E, Kittur DS. Treatment of severe burns with widely meshed skin autograft and meshed skin allograft overlay. *J Trauma.* 1981 Jun;21(6):433–8.
55. Kreis RW, Mackie DP, Vloemans AW, Hermans RP, Hoekstra MJ. Widely expanded postage stamp skin grafts using a modified Meek technique in combination with an allograft overlay. *Burns J Int Soc Burn Inj.* 1993 Apr;19(2):142–5.
56. Sheridan R, Choucair R, Donelan M, Lydon M, Petras L, Tompkins R. Acellular

allodermis in burns surgery: 1-year results of a pilot trial. *J Burn Care Rehabil.*

1998;19(6):528–30.

57. McEwan W, Brown TLH, Mills SM, Muller MJ. Suction dressings to secure a dermal substitute. *Burns J Int Soc Burn Inj.* 2004 May;30(3):259–61.

58. Munster AM. Cultured skin for massive burns. A prospective, controlled trial. *Ann Surg.* 1996 Sep;224(3):372–5; discussion 375-377.

59. Barret JP, Wolf SE, Desai MH, Herndon DN. Cost-efficacy of cultured epidermal autografts in massive pediatric burns. *Ann Surg.* 2000 Jun;231(6):869–76.

60. Sood R, Roggy D, Zieger M, Balledux J, Chaudhari S, Koumanis DJ, et al. Cultured epithelial autografts for coverage of large burn wounds in eighty-eight patients: the Indiana University experience. *J Burn Care Res Off Publ Am Burn Assoc.* 2010;31(4):559–68.

61. Nițescu C, Calotă DR, Florescu IP, Lascăr I. Surgical options in extensive burns management. *J Med Life.* 2012;5(Spec Issue):129–36.

62. Whitaker IS, Prowse S, Potokar TS. A critical evaluation of the use of Biobrane as a biologic skin substitute: a versatile tool for the plastic and reconstructive surgeon. *Ann Plast Surg.* 2008 Mar;60(3):333–7.

63. Johnson KL, Papac N, Hirshburg JM. Xeroform Gauze Bolster: A Cost-Effective Alternative to Synthetic Skin Grafts. *Cureus.* 2023 Sep;15(9):e45307.

64. Shi C, Wang C, Liu H, Li Q, Li R, Zhang Y, et al. Selection of Appropriate Wound Dressing for Various Wounds. *Front Bioeng Biotechnol.* 2020;8:182.

65. Demirtas Y, Yagmur C, Soylemez F, Ozturk N, Demir A. Management of split-thickness skin graft donor site: a prospective clinical trial for comparison of five different dressing materials. *Burns J Int Soc Burn Inj.* 2010 Nov;36(7):999–1005.

66. Higgins L, Wasiak J, Spinks A, Cleland H. Split-thickness skin graft donor site management: a randomized controlled trial comparing polyurethane with calcium alginate dressings. *Int Wound J.* 2012 Apr;9(2):126–31.

67. Church D, Elsayed S, Reid O, Winston B, Lindsay R. Burn wound infections. *Clin Microbiol Rev.* 2006 Apr;19(2):403–34.

68. Ladhani HA, Yowler CJ, Claridge JA. Burn Wound Colonization, Infection, and Sepsis. *Surg Infect.* 2021 Feb;22(1):44–8.

69. Takasato F, Morita R, Schichita T, Sekiya T, Morikawa Y, Kuroda T, et al. Prevention of allogeneic cardiac graft rejection by transfer of ex vivo expanded antigen-specific regulatory T-cells. *PloS One.* 2014;9(2):e87722.

70. Souto EB, Ribeiro AF, Ferreira MI, Teixeira MC, Shimojo AAM, Soriano JL, et al. New Nanotechnologies for the Treatment and Repair of Skin Burns Infections. *Int J Mol Sci.* 2020 Jan 8;21(2):393.

X. CV

Juljan Hilpert was born on March 21, 1997, in Gießen, Germany. He successfully completed his Abitur in 2016 in Fulda. Following this, he began studying Mathematical Biometry at the University of Ulm. However, he decided not to continue with this program in 2017. In 2018, he redirected his academic focus towards medicine and began his studies at the University of Rijeka in Croatia. He is set to complete his medical degree in 2024.