

Therapeutic Genicular Nerve Block for Chronic Pain Management in Patients with Knee Osteoarthritis

Orlić Karbić, Vlasta; Šustić, Alan

Source / Izvornik: **Acta clinica Croatica, 2023, 62., 34 - 39**

Journal article, Published version

Rad u časopisu, Objavljena verzija rada (izdavačev PDF)

<https://doi.org/10.20471/acc.2023.62.s4.5>

Permanent link / Trajna poveznica: <https://um.nsk.hr/um:nbn:hr:184:925105>

Rights / Prava: [Attribution-NonCommercial 4.0 International/Imenovanje-Nekomercijalno 4.0 međunarodna](#)

Download date / Datum preuzimanja: **2025-01-26**



Repository / Repozitorij:

[Repository of the University of Rijeka, Faculty of Medicine - FMRI Repository](#)





THERAPEUTIC GENICULAR NERVE BLOCK FOR CHRONIC PAIN MANAGEMENT IN PATIENTS WITH KNEE OSTEOARTHRITIS

Vlasta Orlić Karbić¹ and Alan Šustić^{1†}

¹Clinic of Anaesthesiology, Intensive Care and Pain Medicine, Clinical Hospital Center Rijeka, Department of Anesthesiology, Resuscitation, Emergency and Intensive medicine, Faculty of Medicine, University of Rijeka, Rijeka, Croatia

SUMMARY – Background: Therapeutic genicular nerve block (TGNB) is both an effective and safe treatment procedure for pain related to chronic osteoarthritis of the knee (OA). It is most common amongst the elderly. It is characterized by joint stiffness, pain and disability.

Aim: The aim of this study was to examine the analgesic and functional impact of ultrasound-guided TGNB in patients with chronic knee OA and to evaluate the efficacy of local anesthetics and corticosteroids.

Patients and methods: The study included 20 patients. Pain was assessed according to the numerical pain scale (NRS), and improvement of the functional capacity was assessed according to the WOMAC Index (Western Ontario and McMaster Universities Osteoarthritis Index). SLGN, SMGN and IMGN were identified, and 3 mL of a mixture of local anesthetic (ropivacaine 0.75%) and corticosteroid (triamcinolone 40 mg) were applied to each nerve.

Results: The average NRS value before TGNB was 5.1, and the WOMAC score was 58.55. After the TGNB was performed, NRS was 2.4 (47% decrease in pain intensity) and WOMAC was 30.1 (51% decrease in the intensity of ailment).

Conclusion: TGNB is effective and not harmful in treating pain and enhances the functional capacity in patients with knee OA. The clinical benefits of corticosteroid administration suggest that it may be an appropriate adjuvant in TGNB for knee OA.

Conflict of interest:

The authors declare no conflict of interest.

Key words: *chronic pain; knee osteoarthritis; genicular nerves; ultrasound; therapeutic genicular nerve block; NRS; WOMAC index*

Introduction

Knee osteoarthritis (OA) is a degenerative joint disease which is typically a result of wear and tear of the articular cartilage of the knee¹. It is most prevalent among elderly patients². Based on the etiology, knee osteoarthritis can be subdivided into primary and sec-

ondary. Primary osteoarthritis is characterized by degeneration of articular cartilage without any clear reason. Secondary osteoarthritis is usually a result of an atypical concentration of force throughout the joint, or it can be the outcome of post-traumatic causes or abnormal articular cartilage³.

Common clinical signs of knee OA include pain that worsens with activity, joint rigidity and tumescence and pain after prolonged sitting or resting. The treatment for knee OA starts with conservative methods and advances to surgical treatments when conven-

Correspondence to:

Assist Prof Vlasta Orlić Karbić, MD, PhD

Email: vlastaok@gmail.com

tional medicine fails⁴. Patients with OA are usually treated with several pharmaceutical and nonpharmaceutical interventions, generally in combination^{4,5}.

Therapeutic genicular nerve block (TGNB) is a successful and secure procedure in treating pain in knee OA⁶. The corticosteroids are usually added as an adjuvant to local anesthetic because they strengthen the prolongation of the analgesic effect, despite their questionable analgesic effect on peripheral nerve block. However, one study advocated an addition of corticosteroids to local anesthetic in TGNB because it had a similar effect as RF ablation of genicular nerves⁷.

Several studies have reported the successful performance of ultrasound guided TGNB^{6,8}. This procedure is based on the recent anatomical research showing that genicular nerves are usually followed by genicular arteries. Ultrasound-guided TGNB yielded convincing minimization of pain intensity and better function of the knee joint^{6,8}.

The aim of our study was to determine the efficacy of the addition of corticosteroids to local anesthetic during ultrasound-guided TGNB.

Patients and methods

This study was conducted from November 2021 to April 2022 at the Clinical Hospital Center Rijeka. All of the patients who were a part of the study gave written consent for inclusion in the study. Patients aged 47 through 85 years of age who showed symptoms of knee pain were included in the study. After clinical and radiological assessments, the study comprised enrolled senior patients who had chronic knee pain (i.e., moderate or strong knee pain intensity that lasted over 3 months) and radiologically evaluated tibiofemoral OA according to the Kellgren-Lawrence grade 2-4. The intensity of pain was assessed according to the numerical pain scale NRS (1-10 points), and functional capacity was assessed according to the WOMAC Index (Western Ontario and McMaster Universities Osteoarthritis Index).

The following patients were excluded from the study: patients with acute knee pain, previous knee surgery, connective tissue diseases that had an impact on the knee, severe neurological or mental diseases, prior therapy that included hyaluronic acid injections or steroids, sciatica, use of anticoagulant therapy, and patients previously treated with electroacupuncture.

All patients were instructed in the use of the NRS, ranging from 0 to 10 (0 = no pain, 10 = worst pain imaginable), and how to complete the WOMAC questionnaire.

Every participant was laid down on their back (supine position) with a pillow placed under the back side of the knee (popliteal fossa) to ease unpleasantness. The knee was sterile draped and clothed. A 12 MHz linear transducer (LOGIQ S7, GE Healthcare, Chicago, Illinois, US) was equipped with a sterile plastic cover. The ultrasound probe was then placed alongside the femur and tibia, and both the epicondyles were identified. The genicular arteries are usually located near the junctions of the epicondyle and the shafts of the long bones. The exact position of genicular arteries was verified with color Doppler ultrasound. Respectively, the target points of the GNB should be beside each genicular artery due to the superior lateral, superior medial and inferior medial genicular artery travelling alongside each genicular nerve. Following the use of color Doppler to establish the genicular artery, the needle was introduced “in-plane” of the ultrasound probe in the long-axis view. The correct needle-tip placement close to a genicular nerve was additionally confirmed by sensory nerve stimulation performed with a nerve stimulator (Braun, Kranenborg, Germany), and 3 mL injection volume was administered, with a total of 9 mL of ropivacaine 0.75% (Ropivacaine Molteni 7.5 mg/ml, L Molteni & C Firenza, Italia) and triamcinolone 40 mg (Kenalog, Krka, Novo Mesto, Slovenia) in the vicinity of the superior lateral, superior medial and inferior medial genicular nerves.

Following the successful performance of GNB and the alleviation of the pain, every patient was instructed to reduce the usage of formerly given analgesics.

The study was approved by Ethical Committee and is in accordance with the ethical standards of the Helsinki Declaration. Written signed and dated informed consent was obtained from each participant.

Statistical analysis

Twenty patients who had chronic knee pain due to OA and Kellgren-Lawrence grade 2-4 based on radiologist evaluation were enrolled into the study. The study was completed by all participants.

Following the successful performance of the GNB, data collected from all participants was evaluated. The majority of the patients did not experience any unpleasantness or severe pain during the procedure. Additional medication was not needed by any patient after the procedure was performed. Additionally, no postprocedural complications were reported.

The demographic characteristics of the participants are shown in Table 1.

Table 1. The demographic characteristic of the patients

DEMOGRAPHIC CHARACTERISTIC OF THE PATIENTS	
Average age of patients (years)	71.7
Gender (m/f)	18 (90%) / 2 (10%)
BMI (kg/m ²)	32.9
NRS	5.1
WOMAC score	58.5

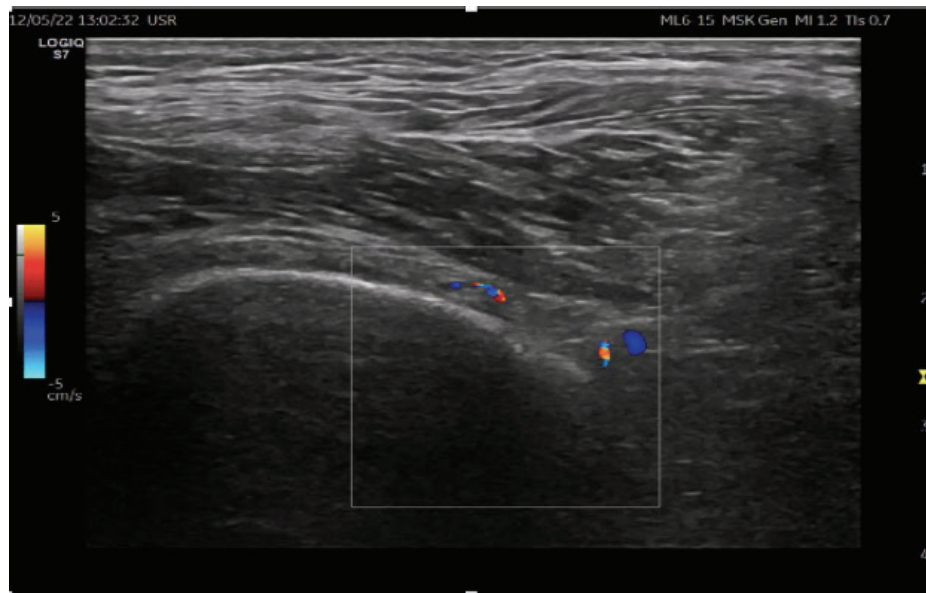


Figure 1. Ultrasound-guided identification of GNB target sites (SGN and the accompanying genicular artery).

The primary results comprised the changes from baseline levels of knee pain and four weeks after TGNB, measured using NRS. The baseline values of NRS ranged from 4–8 (average value 5.1) before TGNB was performed. Four weeks after the block, the NRS values ranged from 1 to 4 (average value 2.4; a 47% reduction in pain intensity). Secondary results included measurement of knee functional changes using the WOMAC (Western Ontario and Mc Master Universities Osteoarthritis Index) score⁹. The baseline WOMAC score values before TGNB were 44 to 96 (average value 58.55). The measured WOMAC scores values four weeks after TGNB ranged from 14 to 55 (average value 30.1; a 51% functional improvement in knee function).

Discussion

TGNB can be successfully performed under ultrasound guidance. The genicular arteries (superior lateral, superior medial and inferior medial) can be effortlessly identified using color Doppler, and serve as the landmarks for genicular nerves^{8,10}. However, the genicular nerves usually travel alongside the genicular arteries and are visible on the ultrasound scans. In our study, the position of the needle tip was additionally confirmed by nerve stimulation.

Bony landmarks are commonly used for the targeting of the genicular nerves using fluoroscopy, as the genicular nerves are situated in their vicinity. These landmarks determine the average position of the genicular nerves, but some anatomic variations

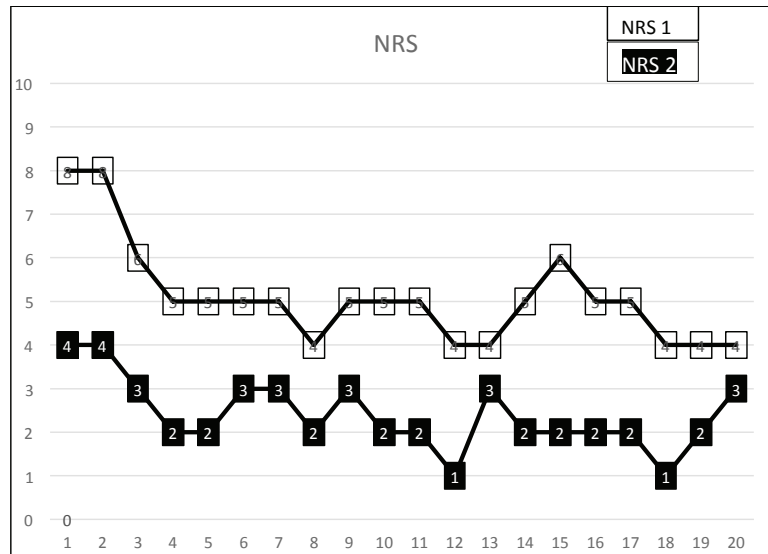


Figure 2. The values of NRS pain scores of patients before and after undergoing TGNB. NRS 1 is the baseline value before TGNB, NRS 2 is the value after TGNB was performed.

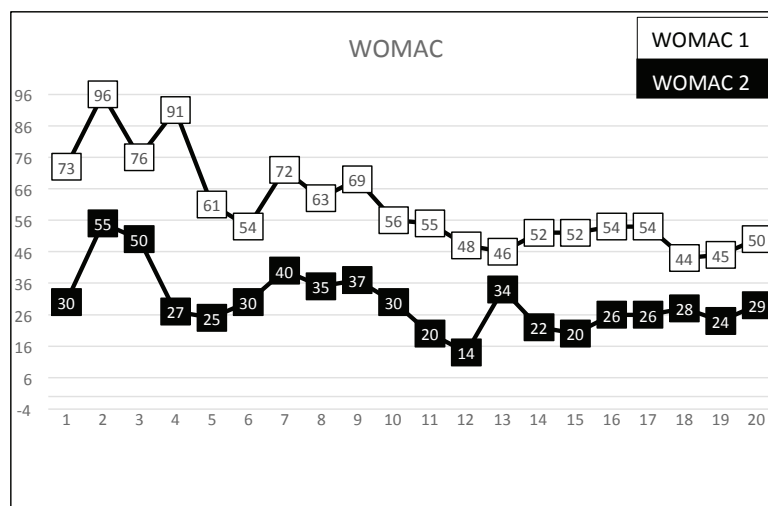


Figure 3. The WOMAC scores patients before and after receiving TGNB. WOMAC 1 is the baseline value before TGNB, WOMAC 2 is the value after TGNB was performed.

are present in certain cases. Additionally, the determination of these bony landmarks using fluoroscopy is occasionally very complex due to the fact that there can be some anatomical variations. Ultrasound for the imaging of the genicular nerves usually uses genicular arteries because they are situated alongside each other, representing an alternative for bony landmarks. Because of the real-time ultrasound display,

the successfulness of this method is increased¹⁰.

The administration of corticosteroids for pain control for TGNB is important because it influences the procedure success rate. In several meta-analyses, corticosteroids, mostly dexamethasone, have been used with local anesthetics for peripheral nerve blocks^{7,8}. The usage of corticosteroids provides longer and more extended postoperative analgesia, prolongs

its analgesic duration, and lowers the pain scores in comparison with local anesthetic alone⁸. The addition of a corticosteroid, particularly in TGNB, enables functional improvement and reduction of knee pain. Qudsi-Sinclair *et al.* reported that knee pain that can last for up to 6 months was alleviated by an addition of corticosteroids in patients who still felt pain even after total knee replacement arthroplasty (TKRA). The same effect can be achieved with a genicular nerve radiofrequency⁷. In addition, the central sensitization of dorsal horn neurons, which are the main cause of chronic pain development, can be decreased with the use of corticosteroids (also known as “wind down phenomena”). Subsequently, TGNB depletion in concentrations of proinflammatory substances (substance P and nerve growth factor in the synovium) was observed. The blockade of pain stimuli conduction in afferent C fibers of the joint was also depleted after TGNB¹¹.

Alterations in nociceptive processing and neuroplastic brain pathway mechanisms represent an indirect way in which corticosteroids achieve better results in peripheral nerve block¹². This observation led to Afridi *et al.*¹³ reporting that a single corticosteroid shot in the greater occipital nerve produced two possible outcomes. The first possible result was a complete response, e.g., being pain free in 22% patients, an effect lasting for about 20 days. The second possible result was a reduction of pain in over 30% patients, lasting for about 45 days in patients who were showing symptoms of an initial headache prior to the injection.

Thus, prolonging the outcome of local anesthetic usage and improving the knee function in the short-term may be achieved with the addition of a corticosteroid during TGNB for chronic knee pain¹². In any case, the effects of local anesthesia alone were still far better than the previously mentioned inclusion of corticosteroids¹⁴. If the potential harmful influences are considered, local anesthetics containing corticosteroids could be beneficial in the course of TGNB for chronic knee OA^{12,14}.

This study had numerous limitations. Firstly, the concentration of postprocedural plasma cortisol was not assessed. Even though a single dose of corticosteroids was used, depression in cortisol levels could still have developed in several cases. However, neither the optimal steroid dose or optimal type is currently known, so our data would therefore need to be validated in future studies.

Secondly, patients were followed up for four weeks after the study was carried. Studies carried out recently have generally performed follow-up on the patients for approximately 3 months to judge the short-term outcomes. Therefore, a longer follow-up might be necessary to evaluate the effect on pain intensity resulting from TGNB as well as functional improvement among patients who have chronic knee OA.

References

1. Peat G, McCarney R, Croft P. Knee pain and osteoarthritis in older adults: A review of community burden and current use of primary health care. *Ann Rheum Dis*. 2001;60:91-7.
2. Crawford DC, Miller LE, Block JE. Conservative management of symptomatic knee osteoarthritis: A flawed strategy? *Orthop Rev (Pavia)*. 2013;5:e2.
3. Cisternas MG, Murphy L, Sacks JJ, Solomon DH, Pasta DJ, Helmick CG. Alternative methods for defining osteoarthritis and the impact on estimating prevalence in a US population-based survey. *Arthritis Care Res (Hoboken)*. 2016;68:574-80.
4. Hochberg MC, Altman RD, April KT, Benkhalti M, Guyatt G, McGowan J, *et al.* American College of Rheumatology 2012 recommendations for the use of nonpharmacologic and pharmacologic therapies in osteoarthritis of the hand, hip, and knee. *Arthritis Care Res (Hoboken)*. 2012;64:465-74.
5. Dobson F, Hinman RS, Hall M, Marshall CJ, Sayer T, Anderson C, *et al.* Reliability and measurement error of the Osteoarthritis Research Society International (OARSI) recommended performance-based tests of physical function in people with hip and knee osteoarthritis. *Osteoarthritis Cartilage*. 2017;25:1792-6.
6. Huang Y, Deng Q, Yang L, Ma J, Wang Z, Huang D, *et al.* Efficacy and Safety of Ultrasound-Guided Treatment for Chronic Pain in Patients with Knee Osteoarthritis: A Systematic Review and Meta-Analysis. *Pain Research and Management*. 2020;2020:2537075. doi: 10.1155/2020/2537075.
7. Qudsi-Sinclair S, Borrás-Rubio E, Abellan-Guillén JF, Padilla Del Rey ML, Ruiz-Merino G. A comparison of genicular nerve treatment using either radiofrequency or analgesic block with corticosteroid for pain after a total knee arthroplasty: A double-blind, randomized clinical study. *Pain Pract*. 2017;17:578-88.
8. Fonkoue L, Steyaert A, Kouame JEK, Bandolo E, Lebleu J, Fossoh H, *et al.* A Comparison of Genicular Nerve Blockade With Corticosteroids Using Either Classical Anatomical Targets vs Revised Targets for Pain and Function in Knee Osteoarthritis: A Double-Blind, Randomized Trial. *Pain Medicine*. 2021;22(5):1118-26.
9. Fulk A, Benbuazza K, Amine B, Maaroufi H, Bahiri R, Lazrak N, *et al.* Translation and validation of Moroccan Western Ontario and Mc Master Universities (WOMAC) osteoarthritis index in knee osteoarthritis. *Reumatol Int*. 2008;28:677-83.
10. Standing S. Gray's anatomy: The anatomical basis of clinical practice. In: Beninger B, eds. *Pelvic Girdle and Leg*. London, UK: Elsevier Publishing; 2016:1383-400.

11. Lewis RN. The use of combined suprascapular and circumflex (articular branches) nerve blocks in the management of chronic arthritis of the shoulder joint. *Eur Acad Anaesthesiol.* 1999;16:37-41.
12. An K, Elkassabany NM, Liu J. Dexamethasone as adjuvant to bupivacaine prolongs the duration of thermal antinociception and prevents bupivacaine-induced rebound hyperalgesia via regional mechanism in a mouse sciatic nerve block model. *PLoS One.* 2015;10(4):e0123459.
13. Afridi SK, Shields KG, Bhola R, Goadsby PJ. Greater occipital nerve injection in primary headache syndromes--prolonged effects from a single injection. *Pain.* 2006;122:126-9.
14. Kim DH, Choi SS, Yoon SH, Lee SH, Seo DK, Lee IG, et al. Ultrasound-Guided Genicular Nerve Block for Knee Osteoarthritis: A Double-Blind, Randomized Controlled Trial of Local Anesthetic Alone or in Combination with Corticosteroid. *Pain Physician.* 2018;21:41-51.

Sažetak

TERAPEUTSKI BLOK GENIKULARNOG ŽIVCA ZA LIJEČENJE KRONIČNE BOLI KOD PACIJENATA S OSTEOARTRITISOM KOLJENA

V. Orlić Karbić i A. Šustić[†]

Terapijski genikularni blok (TGNB) siguran je i učinkovit terapijski postupak u liječenju kronične boli povezane s osteoartritisom (OA) koljena. Uobičajeno OA koljena pogađa osobe starije životne dobi, a karakterizira ga bol, otok i ukočenost zahvaćenog zgloba.

Cilj je prikazati učinkovitost TGNB pod kontrolom ultrazvuka, i sigurnu primjenu kombinacije lokalnog anestetika i kortikosteroida u liječenju bolesnika sa kroničnom boli uslijed OA koljena procjenom analgetskog učinka i poboljšanja funkcijske sposobnosti ispitanika

Ispitanici i metode Prikazom je obuhvaćeno 20 bolesnika. Intenzitet boli je procijenjen koristeći numeričku skalu boli (NRS), a funkcijski kapacitet primjenom WOMAC indeksa (Western Ontario and Mc Master Universities Osteoarthritis Index). Pri izvođenju TGNB ultrazvukom se prikazu SLGN, SMGN i IMGN, i na svaki aplicira 3 ml mješavine lokalnog anestetika (ropivacain 0,75%) i kortikosteroida (triamcetan 40 mg).

Rezultati Prosječna vrijednost NRS prije izvođenja TGB iznosila je 5,1, a vrijednost WOMAC scora 58,55. Nakon učinjenog TRG prosječna je vrijednost NRS bila 2,4 (47% smanjenje intenziteta boli), a WOMAC scora 30,1 (51% smanjenje intenziteta tegoba).

Zaključak Ultrazvučno vođena TGNB je sigurna, učinkovita i lako primjenjiva metoda u liječenju kronične boli i poboljšanju funkcijskog kapaciteta u bolesnika s OA koljena. Štoviše, primjena kortikosteroida sugerira kako su prikladan adjuvans lokalnom anestetiku pri izvođenju TGNB.

Ključne riječi: *kronična bol, osteoartritis koljena, genikularni živci, ultrazvuk, terapijski genikularni blok, NRS, WOMAC indeks*