

Treatment of war injuries of the upper extremity during war in south-western Croatia :Running head: War Injuries of the Upper Extremity

Cicvarić, Tedi; Uravić, Miljenko; Štalekar, Hrvoje; Šustić, Alan; Protić, Alen; Tadin, Tomislav

Source / Izvornik: **Acta Chirurgica Croatica, 2011, 8, 43 - 52**

Journal article, Published version

Rad u časopisu, Objavljena verzija rada (izdavačev PDF)

Permanent link / Trajna poveznica: <https://urn.nsk.hr/urn:nbn:hr:184:031702>

Rights / Prava: [In copyright](#) / [Zaštićeno autorskim pravom.](#)

Download date / Datum preuzimanja: **2025-02-20**



Repository / Repozitorij:

[Repository of the University of Rijeka, Faculty of Medicine - FMRI Repository](#)



TREATMENT OF WAR INJURIES OF THE UPPER EXTREMITY DURING WAR IN SOUTH-WESTERN CROATIA

Running head: War Injuries of the Upper Extremity

Authors:

Tedi Cicvarić M.D., Ph.D.¹

Miljenko Uravić M.D., Ph.D.¹

Hrvoje Štalekar M.D., Ph.D.¹

Alan Šustić M.D., Ph.D.²

Alen Protić M.D.²

Tomislav Tadin M.D., M.Sc.³

¹ Department of Surgery, University Hospital Rijeka, Rijeka, Croatia

² Department of Anesthesiology and IC, University Hospital Rijeka, Rijeka, Croatia

³ Ultrasound Diagnostic Service, Health Centre Rijeka, Rijeka, Croatia

Correspondence to:

Tedi Cicvarić, M.D., Ph.D.

Division of Traumatology, Department of Surgery, University Hospital Rijeka

Tome Strizica 3, 51 000 Rijeka, Croatia

Phone: +385 51 407 474

Mobile: +385 91 2658 175

Fax: +385 51 407 377

Home: Drage Scitara 3, 51 000 Rijeka, Croatia

E-mail: tedi_cicvaric@yahoo.com

Abstract

Objectives

The aim of this study was to analyze the epidemiology, treatment and incidence of complications among the patients with upper extremity war injury.

Methods

In retrospective study, 123 patients with war injuries of the upper extremity have been analyzed. The results of treatment were assessed according to the rate of: complications, amputations, fracture healing and mortality.

Results

Complications appeared in 17.9% of cases. Traumatic amputations were present in 19.4% of

cases and in 2.4% of cases amputation was performed due to III C open fracture. Satisfactory bone healing was achieved in 49 of 55 patients available to follow up. Mortality rate was 2.4%.

Conclusion

Self-inflicted injuries resulted in 41.6% amputation rate. High-energy war injuries of the upper extremity could be treated between 6 and 12 hours after injury without an increase in complication rate, compared to treatment up to 6 hours from injury. In selected cases primary reconstruction of war injury could be performed.

Keywords

Croatia, treatment outcome, upper extremity, war injuries, war surgery, wound healing

Liječenje ratnih ozljeda gornjih ekstremiteta tijekom rata u jugozapadnoj Hrvatskoj

Sažetak

Podloga

Cilj ove studije bio je analizirati epidemiologiju, liječenja i učestalost komplikacija kod bolesnika s ratnim ozljedama gornjih ekstremiteta.

Metode

U retrospektivnoj studiji analizirana su 123 bolesnika s ratnim ozljedama gornjih ekstremiteta. Rezultati liječenja procijenjeni su na temelju učestalosti komplikacija i amputacija, sanacije prijeloma i mortaliteta.

Rezultati

Komplikacije tijekom liječenja pojavile su se u 17,9% bolesnika. Traumatske amputacije nastale su kod 19,4% ozljeđenika, a kod 2,4% ranjenika amputacija je učinjena zbog otvorenog prijeloma III C stupnja. Zadovoljavajuće cijeljenje prijeloma postignuto je kod 49 bolesnika, od 55 koji su bili kontrolirani do završetka liječenja. Mortalitet je u ovoj skupini ranjenika iznosio 2,4%.

Zaključak

Samoozljede su rezultirale s učestalošću amputacija od 41,6%. Ratne ozljede nastale prijenosom velike količine energije mogu se liječiti u razdoblju između 6 i 12 sati nakon ozljede, bez porasta komplikacija u odnosu na ranjenike liječene unutar 6 sati od ozljede. U posebno indiciranim slučajevima može se učiniti i primarna rekonstrukcija ratnih ozljeda gornjeg ekstremiteta.

Ključne riječi

Hrvatska, ishod liječenja, gornji ekstremitet, ratne ozljede, ratna kirurgija, cijeljenje rane

Introduction

The incidence of the upper extremity injuries in the Second World War was 26% [1]. In modern wars the incidence of extremity injuries was over 75% with more than 1/3 associated with bone fractures [2]. The number of injured during combat usually exceeds the capability of medical service and these patients require proper triage and

treatment. During war history, the treatment of upper extremity war injuries was changing from amputation as a life-saving procedure, to salvage and reconstructive procedures with aggressive rehabilitation to regain hand function [3]. Despite the progress in the treatment and development of surgical reconstructive techniques in the Vietnam and Korean War, there has been an increase in amputation rate of extremity with a decrease in the mortality rate of the wounded in comparison to the Second World War [4]. The nature of combat injuries is also changing because of the development of different weapons and changing of fighting tactics [5].

The aim of this study was to analyze the outcome and incidence of complications in the treatment of the wounded with upper extremity injury during the war in Croatia.

Materials and Methods

This research was carried out as a retrospective study. We analyzed 123 consecutive patients with upper extremity injuries caused by gunshot or explosive weapons, 103 out of whom were followed up to the end of the treatment. All the patients were treated at our Division of Traumatology from August 1991 until December 1995. This group of injured represents 18.7% of 658 wounded persons treated in our University Hospital (UH) during the same period.

The wounded were treated on the principles of war surgery [1]. Most of the wounded were treated in War Hospitals (WH) by mobile surgical teams [6]. After surgery, the wounded were transported to UH. Some of the wounded were transported directly to UH because of the short distance from the battlefield.

During the initial treatment, each wounded had received tetanus prophylaxis (tetanus toxoid and tetanus immune globulin 250–500 I.U.) and combined antibiotic therapy (penicillin G, gentamycin, metronidazole). After diagnostic procedures, the wounded were treated in the operating room. In the aseptic environment all foreign bodies, necrotic and devitalized tissue were removed [7]. Wounds were copiously irrigated with saline solution. During the debridement pneumatic tourniquet was used, but it was inflated only in case of massive bleeding [7]. The fasciotomy and epimysiotomy were performed in cases of massive tissue destruction

or vessel injuries [2, 8]. The wounds were mainly left open, drained and covered with chlorhexidine solution dressing. Wounds with massive tissue destruction were explored after 24 to 48 hours [2]. Isolated, low-energy soft tissue injuries were covered with sterile dressing without debridement being performed. The control of the local and general signs of infection was performed daily [2, 9, 10].

In selected cases, the primary wound closure with flaps was a method of choice to preserve hand function [8, 11, 12]. The indications for primary wound closure were: debridement performed within 12 hours from the injury, successful debridement without questionable areas left, tissue defect with exposure of the bone, tendons, vessels or nerves, isolated injury of upper extremity, no signs of shock or chronic diseases, and an available experienced surgical team.

Blood vessels were repaired with end-to-end anastomosis or autologous vein graft. The synthetic graft was not used [13].

Open fractures of upper extremity were classified according to Gustilo [14]. Fractures were primarily treated with external fixation. The CMC (Croatian Medical Corps, Instrumentaria, Zagreb, Croatia) and Zagreb I and II (Hospitalia, Zagreb, Croatia) used external fixators [15, 16]. Intraarticular fractures were managed with additional Kirschner wires or lag screws to restore the articular surface. When small external fixators for hand were not available, the stabilization of the fracture was achieved with Kirschner wires [8, 11, 17] and with plaster-of-Paris splints [8, 12].

Nerves were explored only in cases when they were in the zone of debridement. In case of nerve lesion away from the zone of tissue necrosis, the treatment was conservative until the wound healed. When nerve function did not recover, the exploration was done after 3 to 4 months [18]. Tendon injuries frequently resulted with a defect that required surgical reconstruction (two-stage tendoplasty) after the wound healed.

The amputation of upper extremity was indicated in case of extensive injuries with obvious non-viable or necrotic tissue and incurable life-threatening infection [1].

The patients were classified according to: age, gender, mechanism (explosive or gunshot projectile) and severity of injury, anatomic region of injury, type of injured tissue, time having passed

from injury to primary surgical treatment, range of surgical treatment, duration of hospitalization and duration of treatment.

The results of treatment were assessed as follows:

1. Mortality rate

2. Complications

As a complication we consider every condition or illness that was likely to jeopardize the process of treatment and recovery.

3. Amputation

Amputation was determined as the loss of a part of the extremity including more than one phalanx of the finger.

4. Fracture healing

Malposition, non-union or chronic posttraumatic osteomyelitis (OM) was considered a poor result. The judgment was made according to clinical findings and X-ray.

Statistical analysis

All values were presented as the mean value \pm standard deviation. Statistical analysis was done with software Statistica 4.3 (StatSoft. inc.), using Mann-Whitney U test and Wilcoxon match pairs test.

Results

The average age of the wounded was 32.6 (\pm 14.2) years, ranging from 7 to 89 years. There were 115 (93.5%) males and 8 (6.5%) females. Most of the wounded were soldiers 83 (67.5%) and 40 (32.5%) were civilians including 8 (6.5%) children under 18 years of age. The relation between explosive and gunshot injuries was 76 (61.8%) : 47 (38.2%). High-energy injury was present in 104 (84.6%), and low-energy injury in 19 (15.4%) patients. Accidental self-inflicted injuries were present in 36 cases (29.3%), among children in 7 of 8 cases (87.5 %). The localization of injuries is shown in Figure 1 and the type of injury in Figure 2. Concomitant injuries of other body regions were present in 61 (49.6%) of the wounded. Urgent surgery was performed in 23 wounded (18.7%) because of the life-threatening injuries of other body regions. All the wounded treated in WH (83 or 67.5%) survived the transport to UH. In general 122 (99.2%) wounded were managed within 12 hours from injury, among whom 98 (79.7%) within the first 6

hours. Primary therapeutic and surgical procedures during admission are shown in Table 1.

The reconstruction of the arteries was performed in 6 (4.9%) patients: 5 (4.1%) with autologous vein graft, and in one with end-to-end anastomosis. Arterial bleeding and distal ischemia were obvious in all 6 patients and arteriography was not indicated. A temporary shunt was used in 1 (0.9%) patient.

Out of 69 patients with 3rd degree open fractures, 55 were followed till the end of bone healing. Satisfactory healing was achieved in 49. At the end of the treatment an unacceptable position of the bone was present in 6 wounded.

External fixation was used for fracture stabilization in all 35 patients who sustained long bone fractures. A correction of external fixation was necessary in 5 cases due to unsatisfactory reduction. The delayed union and non-union were an indication for additional surgery in 9 patients (bone grafting and plate fixation in 4 cases, bone grafting and external fixation in 2 cases, plate fixation in 2 cases, circular Ilizarov external fixation in 1 case). The fracture healed in all of the 28 followed patients.

Reconstruction of soft tissue defects was performed in 26 (21.1%) wounded with extensive injuries. In 13 cases it was performed immediately after the debridement and in another 13 patients soft tissue reconstruction was performed later, in the phase of secondary healing (Figures 3-5). The applied reconstructive surgical procedures are shown in Table 2. Hand injuries were the most common location of primary reconstruction, i.e. in 9 cases (7.3%). Thirteen (10.6%) wounded with primary closure of the wound did not have higher incidence of complications in comparison to the wounded where reconstruction was performed during the phase of secondary healing.

Postoperative complications appeared in 22 (17.9%) wounded (Table 3). The analysis of incidence of the complications brought forth the following conclusions:

There was no correlation between incidences of complications in relation to the type of the upper extremity injury.

The higher incidence of complications, in 18 (14.6%) cases, was found in the group of wounded with concomitant injuries in relation to the group of the wounded with isolated upper extremity injury, i.e. 4 (3.3%) of them ($p < 0.05$).

There was no difference in the incidence of complications between the group of the wounded treated during the first 6 hours after injury and the group of the injured treated within the 6 to 12 hours period after injury. These two groups were statistically different regarding the type of injury, but there was no difference in the distribution of high-energy and low-energy injuries.

There was no difference in the incidence of complications between the group of patients with primary soft tissue reconstruction and the group of the wounded where the soft tissue reconstruction was done in the phase of secondary healing.

Amputation was the result of injury in 20 (19.4%) out of 103 (100%) followed patients. Reamputation was performed in 16 (13%) cases because of traumatic amputation of fingers, in 3 (2.4%) cases due to traumatic amputation of the forearm and in 1 (0.8%) case due to traumatic amputation of the upper arm. The III C open fracture was an indication for the forearm amputation in 1 (0.8%) and for the finger amputation in 2 (1.6%) cases. Self-inflicted injuries resulted with 41.6% rate of traumatic amputation ($p < 0.001$) in comparison with injuries sustained from another person.

The average duration of the first hospitalization was 20 (± 19) days, ranging from 1 to 112 days. The mortality rate was 2.4%; 2 wounded died from severe thoracoabdominal injuries and one died after traumatic amputation of both lower extremities complicated with sepsis and multi-organ failure. In the 103 (83.7%) followed patients the average follow up was 14.6 months (ranging from 3 to 31) after the first discharge from UH. The average time of healing was 11.6 months, ranging from 1 to 52 months.

Discussion

The main goal of the treatment of extremity war injuries is to preserve the limb viability and to prevent the appearance of an infection. Early treatment of the wounded close to battlefield has created good preconditions for the treatment in UH. In this series of injuries we found no statistical significance in the incidence of complications between the injured treated during the first 6 hours and patients treated within the 6 to 12 hours period after the injury. The triage of mobile patients with the upper limb injuries to rear hospitals can relieve the surgical team. This should

be different from the treatment of the lower limb war injuries where the poor soft tissue coverage of the lower leg and weaker circulation probably cannot tolerate such a delay.

The debridement is the most important part of early treatment in extensive high-energy war injuries, and its role in prevention of wound infection has been proved [3, 4, 7, 14, 19-22]. One study pointed out that this procedure is frequently performed inadequately [23]. It is also known that the low energy war injuries of soft tissues could be treated conservatively, without debridement, if indications are strictly respected [2, 7, 9, 10]. It should be pointed out that history data about the weapon and mechanism of injury are mainly unknown and rarely accurate, therefore the decision for the management of the wound depends mostly on wound aspect and fracture pattern, with recommendation that the most experienced surgeon must be consulted.

It is generally accepted that primary closure of war injuries increases the likelihood of infection [7, 24], but on the other hand it is very important to perform an early reconstruction of hand injuries to preserve the viability of exposed tissue, reduce the edema and fibrosis, and prevent stiffness [8, 12, 25]. Primary reconstruction of war injuries, after initial aggressive and complete debridement, was performed in 13 patients without the appearance of local infection or other complications. Skin defects on the hand (6 cases) were covered with a groin flap. This flap is easy to use; it can be well adapted to the hand, has good vascularization and substitutes the missing skin and subcutaneous tissue (Figures 3-5). We respect strict indications for primary closure of war wounds with soft tissue defect: debridement done within 12 hours from injury, successful debridement without questionable areas left, isolated injury of upper extremity, no signs of shock or chronic diseases, and an available experienced surgical team.

The external fixation in long bone war fractures could be considered successful because bone healing was achieved in all wounded. The problems and difficulties after external fixation that included malreduction and axis deviation (13.9%) often resulted from unavailability of the image intensifier under war conditions. Good fracture healing was achieved with initial external fixation in 67.9% of the wounded in comparison

with 57.1% of the wounded with successful initial external fixation published by Croatian authors in similar conditions [26]. In this series of wounded, there were no pin tract infections that would demand surgery, although the incidence of pin tract infection in literature ranges from negligible to 78.7% [2, 15, 21, 22]. In all cases local treatment and antibiotic therapy were sufficient to eradicate the local secretion. It is known that instability of construction and positioning of the pin too close to fracture are the main causes of pin tract infection [21]. Therefore, a wide range of incidence from literature is probably the consequence of imprecise definition and different assessment of pin tract infections.

We did not reveal any case of chronic posttraumatic osteomyelitis (OM) what is in contradiction with other Croatian authors who have analyzed the treatment of war extremity injuries. They published the incidence rates of OM 7.6% [26] and 7.75% [15]. These results are not comparable because they did not distinguish the incidence of OM in upper or lower extremities. Better anatomical conditions, good vascularization and bulky soft tissue coverage are surely the important factors in decrease of OM incidence in the upper extremities. Complete eradication of infection was reported in cases of war injuries of the shoulder [27] and elbow war injuries [28]. Furthermore, it has been confirmed that delayed treatment, fracture instability and insufficient debridement of the war wound are agents of wound infections and OM [21, 22]. Our observation is that we could provide a radical debridement and surgical treatment by qualified surgeons within 12 hours from injury, despite the disastrous war conditions.

Low rate of amputation (2.4%) after open grade III fracture suggests that with appropriate surgery and good timing we were able to save the viable limb in most of the patients, although there is a recent report with 9.3% of upper extremity amputation because of vascular injury during Iraqi Freedom Operation [29].

It is important to notice a high percentage of self-inflicted injuries (29.3%), especially in children (87.5%). These injuries resulted in high percentage of amputations (41.6%) and unfavorable results. Out of 17 patients who sustained a traumatic amputation, 15 cases were caused by a self-inflicted injury. Undertrained unprofessional

soldiers handling different arms and availability of explosive weapons to children in war conditions were the main reasons for these preventable accidents.

The limitations of our study include retrospective analysis and wide variety of injuries in different regions of upper extremity that made this group of patients inhomogeneous according to the type of injury.

Conclusions

Preventable self-inflicted injuries were present in 36 (29.3%) cases. These injuries resulted with high traumatic amputation rate of 41.6%.

There is no difference in the incidence of complications between the injured treated during

the first 6 hours and the group of patients treated within 6 to 12 hours period after injury. Our study suggests that we can tolerate the delay in treatment of the isolated upper limb war injury (excluding vascular injury and traumatic amputation) up to 12 hours after injury without higher incidence of complications on the upper extremity. This is an important message in combat situations when mobile surgical teams and war hospitals can be overcrowded with patients.

In selected cases the primary reconstruction of extensive war injuries of the upper extremity could be done. The primary reconstruction could not be the rule due to triage and logistic problems in the reality of war. It should be done only in specialized centres by experienced surgeons.

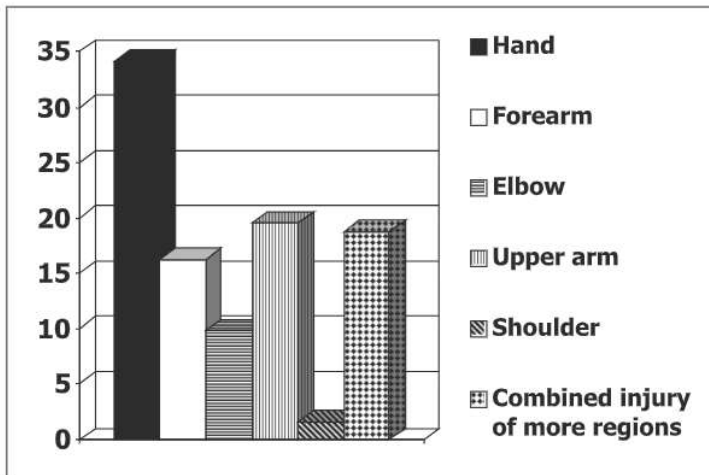


Figure 1.
Distribution of injuries

Figure 2.
Type of injury

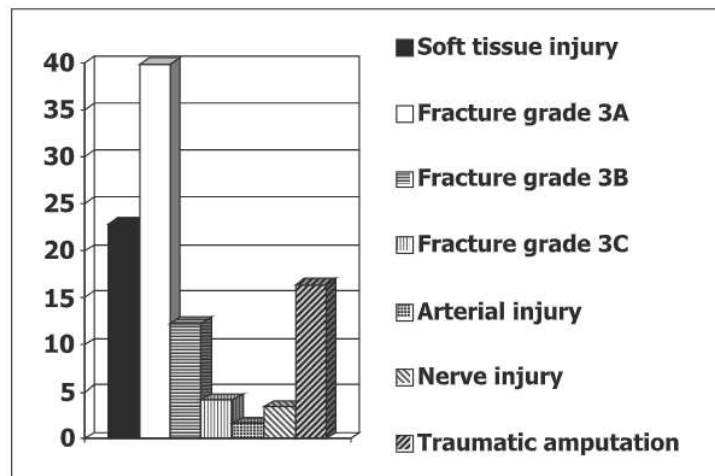


Figure 3. Soft tissue defect after explosive injury of the elbow and lower arm in the phase of secondary healing




Figure 4. Groin flap used for soft tissue reconstruction of lower arm

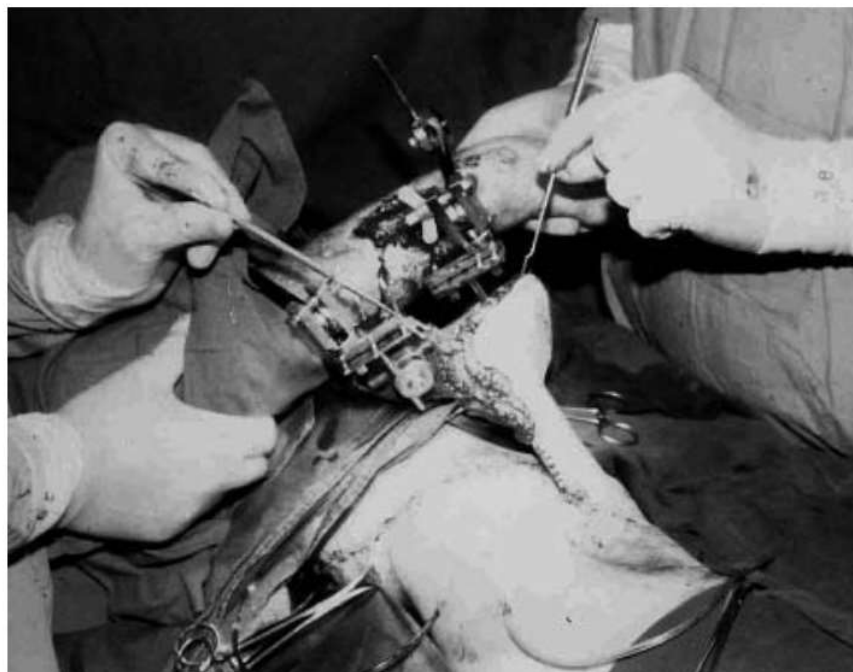


Figure 5. Result after soft tissue reconstruction, elbow arthrodesis and healing of radial fracture (distal part of the ulna is missing, ulnar nerve palsy remains) – the pinch grip

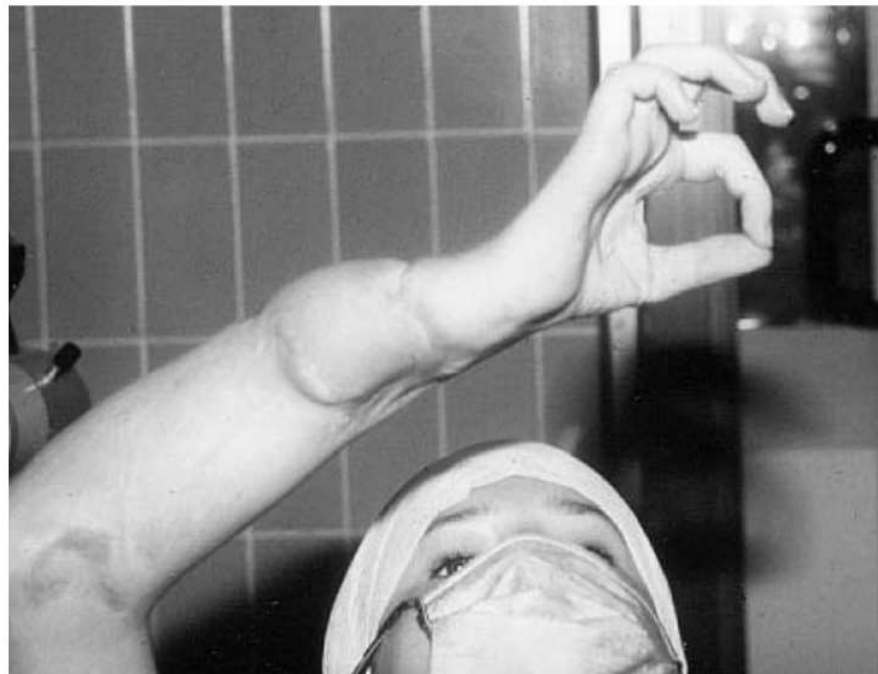

Table 1. Primary therapeutic and surgical procedures in War Hospitals (WH) and University Hospital (UH)

WH	UH	
	No patients (%)	No patients (%)
Urgent surgery due to life-threatening injury	12 (14.5%)	9 (22.5%)
Amputation	0	3 (7.5%)
Reamputation	4 (4.8%)	14 (35%)
Vascular repair	4 (4.8%)	2 (5%)
Débridement	62 (74.7%)	34 (85%)
Plaster immobilization	58 (69.9%)	12 (30%)
External fixation	16 (19.3%)	19 (47.5%)
Osteosynthesis with K wires	0	9 (22.5%)
Plate osteosynthesis	0	1 (2.5%)
Tetanus prophylaxis	83 (100%)	40 (100%)
Antibiotic therapy	83 (100%)	40 (100%)
Soft tissue reconstruction	0	13 (32.5%)
Total	83 (100%)	40 (100%)

Table 2. Surgical procedures used for soft tissue reconstruction

Wound closure	Primary	Secondary
Split thickness graft (STG)	7	4
Groin flap	5	4 1+TF 1+STG
Transposition flap (TF)	1	1
Island flap (Lateral arm)	0	1
Island flap (M. latissimus dorsi)	0	1
Total: 26	13	13

Table 3. Postoperative complications

Type of complication	Patients	
	No	(%)
Wound infection (WI)	7	5.7%
Urinary tract infection (UI)	4	3.3%
Respiratory infection (RI)	1	0.8%
Respiratory failure	2	1.6%
Cardiac arrest	1	0.8%
WI + RI + UI	2	1.6%
WI + RI + Acute renal failure	1	0.8%
UI + Sepsis	1	0.8%
WI + Sepsis	1	0.8%
Postoperative bleeding + RI	1	0.8%
Total	22	17.9%

References

1. U.S. Department of Defense. Emergency war surgery – First U.S. revision of the emergency war surgery – NATO Handbook. U.S. Government Printing Office Washington, D.C., 1975.
2. Lerner A, Fodor L, Soudry M. Is Staged External Fixation a Valuable Strategy for War Injuries to the Limbs? *Clin Orth* 2006;448: 217-224.
3. Manojlovic RD, Vuckovic C, Tabakovic D, Nikola G, Bumbasirevic M. Free Fibula and Corticocancellous Bone grafting for Salvage of War-injured Forearm. *J Orthop Trauma* 2006;20: 495-498.
4. Aldea PA, Shaw WW. The evolution of the surgical management of severe lower extremity trauma. *Clin Plast Surg* 1986;13: 549-569.
5. Champion HR, Bellamy RF, Roberts CP, Leppaniemi A. A Profile of Combat Injury. *J Trauma* 2003;54: S13-S19.
6. Lovric Z, Wertheimer B, Candrljic K, et al. War injuries of major extremity vessels. *J Trauma* 1994;36: 248-251.
7. Covey DC. Blast and Fragment Injuries of the Musculoskeletal System. *J Bone Joint Surg Am* 2002;84-A(7): 1221-1234.
8. Jabaley ME, Peterson HD. Early Treatment of War Wounds of the Hand and Forearm in Vietnam. *Ann Surg* 1973; 167-173.
9. Bowyer GW. Management of small fragment wounds: experience from the Afgan border. *J Trauma* 1966;40: 170-172.
10. Granberry WM. Gunshot wounds of the hand. *Hand* 1973;5: 220-228.
11. Elton RC, Bouzard WC. Gunshot and fragment wounds of metacarpus. *South Med J* 1975;68: 833-843.
12. Swanson TV, Szabo RM, Anderson DD. Open hand fractures: Prognosis and classification. *J Hand Surg* 1991;16A: 101-107.
13. Hardin WD, O'Connell RC, Adinolti MF, Kerstain MD. Traumatic arterial injuries of the upper extremity: Determinants of disability. *Am J Surg* 1985;150: 266-270.
14. Gustilo RB, Merkow RL, Tempelman D. The management of open fractures. *J Bone Joint Surg Am* 1990;72A: 299-304.
15. Huljev D, Rašić Ž, Trajbar T, Košuta D, Nadinić V. External fixation in war trauma management of the extremities - experience from the war in Croatia. *J Trauma* 1994;37: 831-834.
16. Korzinek K. War injuries of the extremities. *Unfallchirurg* 1993;96: 242-247.
17. Duncan RW, Freeland AE, Jabaley ME, Meydrech EF. Open hand fractures: An analysis of the recovery of active motion and of complications. *J Hand Surg* 1993;18A: 387-394.
18. Omer GE Jr. Injuries of nerves to upper extremity. *J Bone Joint Surg Am* 1974;56A: 1615-1624.
19. Gonzalez MH, Hall M, Hall RF Jr. Low-velocity gunshot wounds of the proximal phalanx: treatment by early stable fixation. *J Hand Surg Am* 1998;23: 150-155.
20. Ordog GJ, Balasubramaniam S, Wasserberger J, Kram H, Bishop M, Shoemaker W. Extremity gunshot wounds: Part I. Identification and treatment of patients at high risk of vascular injury. *J Trauma* 1994;36: 358-368.
21. Rautio J, Paavolainen P. Delayed treatment of complicated fractures in war wounded. *Injury* 1987;18: 238-240.
22. Tikka S, Bostman O, Marttinen E, Makitie I. A retrospective analysis of 36 civilian gunshot fractures. *J Trauma* 1996;40: S212-S216.
23. Coupland RM. Technical aspects of war wound excision. *Br J Surg* 1989;76: 663-7.
24. Covey DC, Lurate RB, Hatton CT. Field Hospital Treatment of Blast Wounds of the Musculoskeletal System during the Yugoslav Civil War. *J Orthop Trauma* 2000;14(4): 278-286.
25. Luce EA, Griffen WO. Shotgun injuries of the upper extremity. *J Trauma* 1978;18: 487-492.
26. Pukljak D. External fixation-minimal osteosynthesis: indications, role and place in war surgery. *J Trauma* 1997;43: 275-282.
27. Davila S, Mikulić D, Davila NJ, Popović L, Zupančić B. Treatment of war injuries of the shoulder with external fixators. *Mil Med* 2005;170(5): 414-7.
28. Lerner A, Stahl S, Stein H. Hybrid External Fixation in High-Energy Elbow Fractures: A Modular System with A Promising Future. *J Trauma* 2000;49: 1017-1022.
29. Clouse WD, Rasmussen TE, Perstein J, et al. Upper extremity vascular injury: a current in-theatre wartime report from Operation Iraqi Freedom. *Ann Vasc Surg* 2006;20(4): 429-34.