

Otvorena ili artroskopska stabilizacija ramena - indikacije i probir bolesnika

Mihelić, Radovan; Prpić, Tomislav; Jotanović, Zdravko

Source / Izvornik: **Medicina Fluminensis : Medicina Fluminensis, 2015, 51, 187 - 190**

Journal article, Published version

Rad u časopisu, Objavljena verzija rada (izdavačev PDF)

Permanent link / Trajna poveznica: <https://um.nsk.hr/um:nbn:hr:184:142128>

Rights / Prava: [In copyright](#)/[Zaštićeno autorskim pravom.](#)

Download date / Datum preuzimanja: **2024-09-27**



Repository / Repozitorij:

[Repository of the University of Rijeka, Faculty of
Medicine - FMRI Repository](#)



Open or arthroscopic shoulder stabilization – indications and patient selection

Otvorena ili artroskopska stabilizacija ramena – indikacije i probir bolesnika

Radovan Mihelić*, Tomislav Prpić, Zdravko Jotanović

TO THE EDITOR

Arthroscopic shoulder stabilization is a widely accepted method. Very often, an arthroscopic treatment is preferred by patients and surgeons because it is minimally invasive, spares the subscapularis muscle, and because it enables better identification and treatment of associated pathological conditions, and decreases morbidity. Furthermore, recent studies have demonstrated that the results of arthroscopic treatment of recurrent traumatic anterior instability are comparable with those achieved historically with open procedures¹⁻³.

However, arthroscopy is not always effective and there are cases which require open surgical techniques. There is a variety of reports regarding recurrence rates after arthroscopic Bankart repair, depending on arthroscopic skill, but also on the severity of the instability⁴. Therefore, the patient selection plays an important role on the success rate. After the first traumatic dislocation, a closed reduction has to be done, and the shoulder is put in the sling for two weeks. This rule is indicated for the general population, but if we treat top athletes, sometimes an immediate arthroscopy is indicated. After the period of rehabilitation, some shoulders will remain unstable, and the dislocation can occur during swimming, jumping or even during sleeping. The redislocation rate in the general population is around 50 %⁵. In younger patients or those with hyperlaxity, the percentage is higher, even up to 80 % or 92 %⁶⁻⁹. In Germany, in 73 % of hospitals surgery will be indicated for active younger patients under 30^{10,11}.

In case of recurrent instability, surgical therapy must be considered. For young patients with 2-6 redislocations after traumatic dislocation, arthroscopic treatment is indicated. The lesion of the anterior labrum is called the Bankart lesion and has several forms. There are several arthroscopic techniques, which include placement of titanium or resorbable implants into the anterior glenoid rim, and labrum repair is performed (Figure 1).

In decision making regarding the selection of the surgical technique, we try to perform an anatomical repair, either open or arthroscopic. Therefore, the glenoid labrum repair together with capsular shift is generally accepted as the "gold standard". In patient selection, the first step is a careful clinical

Clinic for Orthopaedic Surgery Lovran,
Faculty of Medicine University of Rijeka,
Rijeka, Croatia

Received: 16.09.2014

Accepted: 7.01.2015

*Corresponding author:

Radovan Mihelic, MD, PhD
Clinic for Orthopaedic Surgery Lovran,
Faculty of Medicine University of Rijeka,
Šetalište Maršala Tita 1, 51 415 Lovran,
Croatia
e-mail: radovan.mihelic@gmail.com

<http://hrcak.srce.hr/medicina>

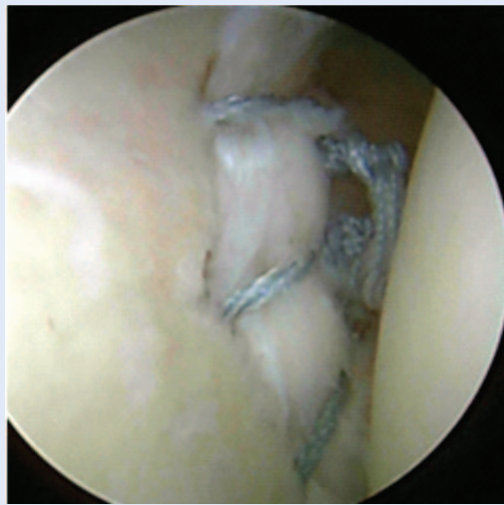

Figure 1. Arthroscopic image of the labrum repair

exam. The range of motion in the instable shoulder should be compared to the contralateral side. Instability tests will give us more information on the grade of instability. After clinical evaluation, a variety of imaging procedures can be used to determine the shoulder pathology. Among them, standard and special X-rays are basic. Sometimes we include ultrasonography or MRI to establish the soft tissue status. (Figures 2 and 3). The results of arthroscopic Bankart repair are generally very good^{2,5,7}. The redislocation rate is reported to be between 6 % and 25 %, depending on the author's experience. A meta-analysis of comparing arthroscopic and open repair showed similar recurrence rates (6 % in arthroscopic and 6.7 % in open repair)¹². In the second part of the study, after a longer follow-up, the reoperation rate was even bigger in the open group (9.2 %) than in the arthroscopic group (2.2 %). This report indicates that arthroscopic stabilization is a reliable method. Indications for arthroscopic Bankart repair are: 3-5 redislocations, well-defined anterior labrum and absence of bony defect on the humeral head or glenoid rim¹³.

In cases where poor capsule quality is proven during arthroscopy, we have to consider that arthroscopic repair might not be sufficient. Balg and Boileau have published an *Instability severity index score*, which can be a useful guideline in the treatment strategy^{14,15} (Table 1). Competitive and contact sport will certainly increase the risk

of re-injury and treatment failure. Hubbel has reported 17 % of redislocations and 60 % of instability in patients with contact sport after arthroscopic Bankart repair¹⁶. Compared to the arthroscopic group, patients with open capsuloraphy had no redislocations, but 47 % had some loss of external rotation. Other authors also report higher failure rates in arthroscopic stabilization^{1,2}. Hyperlaxity is also a problem: if we prove the hyperabduction test to be over 120°, the glenohumeral ligaments reattachment should be done accompanied with capsule plication, otherwise the shoulder will remain unstable. Bilateral instability, a positive sulcus sign proving some extent of multidirectional instability, and poor capsule quality at surgery seem to be the predicting factors for failure^{15,16}. The age of the patient plays also an important role. Patients under 24 years of age have much more risk of failure¹⁷. This could be explained by hyperplastic tissues in adults or poor compliance.

Arthroscopic revision after arthroscopic Bankart repair has a recurrence rate of 6 % to 27 %¹⁸⁻²⁰. As in the revision cases the shoulder capsule is thin and weak, perhaps it is better to do an open repair with abundant capsular shift. A slight tensioning of the subscapularis muscle can be helpful: it will not limit the external rotation, but will produce a tighter anterior wall.

As a result of higher number of dislocations, bony lesions occur. The defect on the posterior side of the humeral head is called Hill-Sachs lesion (Figure 2). The corresponding lesion is created on the anterior glenoid rim (Figure 3). These defects in-

Table 1. Instability severity index score (according to Balg and Boileau)

| | Instability severity index score |
|--------------------|----------------------------------|
| Patient < 20 | 2 |
| Competitive sport | 2 |
| Contact sport | 1 |
| Ant/inf laxity | 1 |
| RTG Hill sacs | 2 |
| RTG glenoid defect | 2 |
| Total | 10 |

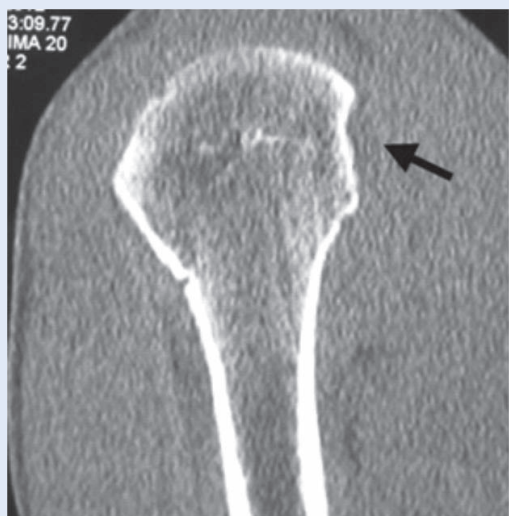

Figure 2. MRI showing the defect on the humeral head (Hill Sachs lesion)

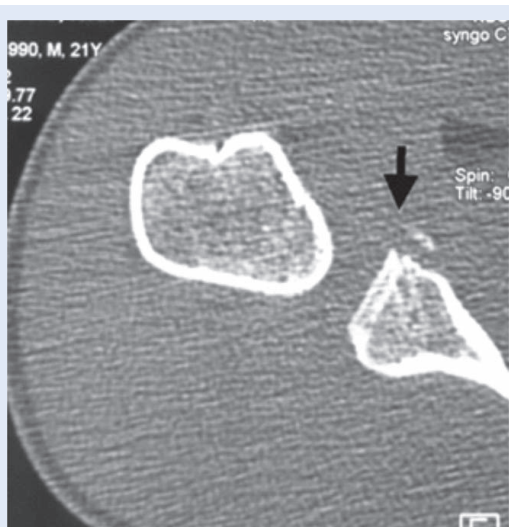


Figure 3. MRI showing the same patient with the defect of the anterior border of the glenoid with fractured fragment.

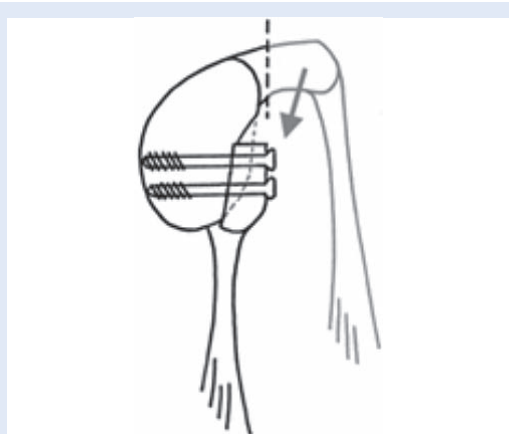


Figure 4. The Latarjet procedure (schematic)

crease the instability and must be addressed in the treatment. There are several surgical techniques, such as bone grafting to fill the defect, capsule fixation into the defect (the “remplissage technique”) and others. A very popular bone block procedure for unstable shoulders is the Latarjet procedure: a resected coracoid is transferred to the anterior inferior rim of the glenoid without detaching the conjoined tendon (Figure 4). The subscapularis muscle is divided horizontally to allow the coracoid to be put on the glenoid. This method has double effect: the bone block will fill up the bone defect and the tendons will have “the sling effect”. Suturing the subscapularis will additionally tension the anterior shoulder wall. This stabilization is indicated when the bone defect on the glenoid is wider than 5 mm or the Hill-Sachs lesion extends to $\frac{1}{4}$ of the humeral head. It is a valid procedure for throwing or contact sports.

The results of our series of following 108 patients operated between 2005 and 2008 show that, after four years of follow-up, we had 28 % of patients with 2-5 redislocations and 72 % with five or more redislocations. There were 80 % male and 20 % female patients. Out of these patients, 83 % had undergone arthroscopic and 17 % open repair. Open surgery consisted of arthroscopic examination and if the criteria for arthroscopic repair were not ideal, an open Bankart repair was done, followed by capsular shift and slight subscapularis tendon tensioning. In the arthroscopic group we had 4 % of redislocations, and in the open group the failure rate was 1 %.

Arthroscopy is a very popular and safe method in shoulder stabilization. If we want to keep the success rate over 90 %, patient selection must be done. In highly unstable shoulders with poor capsular tissue quality or additional bony lesion, one of the open techniques is indicated.

Conflicts of interest statement: The authors report no conflicts of interest.

REFERENCES

1. Cole BJ, Warner JJ. Arthroscopic versus open Bankart repair for traumatic anterior shoulder instability. *Clin Sports Med* 2000;19:19-48.
2. Kim SH, Ha KI, Cho YB, Ryu BO, Oh IA. Arthroscopic anterior stabilization of the shoulder: two to six-year follow-up. *J Bone Joint Surg Am* 2003;85:1511-8.

3. Kim SH, Ha KI, Kim SH. Bankart repair in traumatic anterior shoulder instability: open versus arthroscopic technique. *Arthroscopy* 2002;18:755-63.
4. Wasserstein D, Dwyer T, Veillette C, Gandhi R, Chahal J, Mahomed N et al. Predictors of Dislocation and Revision After Shoulder Stabilization in Ontario, Canada, From 2003 to 2008. *Am J Sports Med* 2013;41:2034-40.
5. Lobenhofer P. Current treatment concepts in first-time dislocation of the shoulder joint. *Zentralbl Chir* 2001;126:192-8.
6. Mazzocca AD, Brown FM Jr, Carreira DS, Hayden J, Romeo AA. Arthroscopic anterior shoulder stabilization of collision and contact athletes. *Am J Sports Med* 2005;33:52-60.
7. Postacchini F, Gumina S, Cinotti G. Anterior shoulder dislocation in adolescents. *J Shoulder Elbow Surg* 2000;9:470-4.
8. Privitera DM, Bisson LJ, Marzo JM. Minimum 10-year follow-up of arthroscopic intra-articular Bankart repair using bioabsorbable tacks. *Am J Sports Med* 2012;40:100-7.
9. Wheeler JH, Ryan JB, Arciero RA, Molinari RN. Arthroscopic versus nonoperative treatment of acute shoulder dislocations in young athletes. *Arthroscopy* 1989;5:213-7.
10. Habermeyer P, Jung D, Ebert T. Treatment strategy in first traumatic anterior dislocation of the shoulder. Plea for a multi-stage concept of preventive initial management. *Unfallchirurg* 1998;101:328-41; discussion 327.
11. Tingart M, Bathis H, Bouillon B, Tiling T. Therapy of traumatic anterior shoulder dislocation: current status of therapy in Germany. Are there scientifically verified therapy concepts?. *Chirurg* 2001;72:677-83.
12. Petrera M, Patella V, Patella S, Theodoropoulos J. Theodoropoulos. A meta-analysis of open versus arthroscopic Bankart repair using suture anchors. *Knee Surg Sports Traumatol Arthrosc* 2010;18:1742-7.
13. Millett PJ, Clavert P, Warner JP. Open Operative Treatment for Anterior Shoulder Instability: When and Why? *J Bone Joint Surg Am* 2005;87:419-32.
14. Balg F, Boileau P. The instability severity index score. A simple pre-operative score to select patients for arthroscopic or open shoulder stabilization. *J Bone Joint Surg Br* 2007;89:1470-7.
15. Boileau P, Villalba M, Héry J-Y, Balg F, Neyton L. Risk Factors for Recurrence of Shoulder Instability After Arthroscopic Bankart Repair. *J Bone Joint Surg Am* 2006;88:1755-63.
16. Hubbel JD, Ahmad S, Bezenhoff LS, Fond J, Pettrone FA. Comparison of Shoulder Stabilization Using Arthroscopic Transglenoid Sutures Versus Open Capsulolabral Repairs. A 5-Year Minimum Follow-up. *Am J Sports Med* 2004;32:650-4.
17. Porcellini G, Campi F, Pegreff F, Castagna A, Paladini P. Predisposing Factors for Recurrent Shoulder Dislocation After Arthroscopic Treatment. *J Bone Joint Surg Am* 2009;91:2537-42.
18. Barnes CJ, Getelman MH, Snyder SJ. Results of arthroscopic revision anterior shoulder reconstruction. *Am J Sports Med* 2009;37:715-9.
19. Krueger D, Kraus N, Pauly S, Chen J, Scheibel M. Subjective and Objective Outcome After Revision Arthroscopic Stabilization for Recurrent Anterior Instability Versus Initial Shoulder Stabilization. *Am J Sp Med* 2011;39:71-7.
20. Neri BR, Tuckman DV, Bravman JT, Yim D, Sahajpal DT, Rokito AS. Arthroscopic revision of Bankart repair. *J Shoulder Elbow Surg* 2007;16:419-24.