

Patient with Lingual Thyroid and Squamous Cell Carcinoma of the Tongue Base - Case Report

Čandrić, Barbara; Pušić, Marin; Kukuljan, Melita; Cvjetković, Niko; Matana, Zrinka; Miletić, Damir

Source / Izvornik: **Collegium antropologicum, 2012, 36 supplement 2, 227 - 229**

Journal article, Published version

Rad u časopisu, Objavljena verzija rada (izdavačev PDF)

Permanent link / Trajna poveznica: <https://um.nsk.hr/um:nbn:hr:184:735362>

Rights / Prava: [Attribution 4.0 International](#)/[Imenovanje 4.0 međunarodna](#)

Download date / Datum preuzimanja: **2024-08-08**



Repository / Repozitorij:

[Repository of the University of Rijeka, Faculty of Medicine - FMRI Repository](#)



Patient with Lingual Thyroid and Squamous Cell Carcinoma of the Tongue Base – Case Report

Barbara Čandrlić¹, Marin Pušić³, Melita Kukuljan¹, Niko Cvjetković², Zrinka Matana¹
and Damir Miletić¹

¹ University of Rijeka, Rijeka University Hospital Center, Department of Radiology, Rijeka, Croatia

² University of Rijeka, Rijeka University Hospital Center, Department of Otorhinolaryngology, Rijeka, Croatia

³ University of Rijeka, School of Medicine, Rijeka, Croatia

ABSTRACT

We demonstrate a rare case of lingual thyroid together with squamous cell carcinoma of the base of tongue. 54-year-old patient presented with left sided lymph node enlargement in regions II, III and IV, without any clinical symptoms. Physical examination revealed semicircular bulge at the base of tongue measuring 30x20 mm and tumorous lesion was suspected. Neck ultrasound showed pathological enlargement of lymph nodes and FNA of lymph node revealed squamous carcinoma cells in the smear. Further investigation included CT and MRI of the neck depicted ectopic thyroid tissue in base of tongue and enlarged and necrotic lymph nodes in regions II and III. Primary carcinoma could not be depicted. Biopsy of the lingual mass was performed and histology confirmed ectopic thyroid tissue. Physical examination of the oral cavity was repeated and suspicious area on the left side of the tongue base near ectopic thyroidal tissue was identified. Histology after biopsy confirmed squamous cell carcinoma with superficial growth. This case emphasizes the important role that collaboration of radiologist and otorhinolaryngologist has in correctly diagnosing oropharyngeal pathology. Also, we underline the importance of careful oropharyngeal region screening in case of unknown pathologic lymphadenopathy, when the possibility of oropharyngeal cancer has to be considered.

Key words: *ectopic lingual thyroid, squamous cell carcinoma, tongue carcinoma, necrotic lymph nodes*

Introduction

Of all ectopic thyroids 90% are found to be lingual¹. It is a rare congenital anomaly appearing with prevalence of 1:100000². Patients may present with an asymptomatic posterior reddish tongue base mass, signs of dysphonia, throat fullness, dysphagia or rarely with hypothyroidism^{3,4}. Squamous cell carcinoma is the most common cancer of the base of tongue. Patients frequently present with advanced disease because of the occult nature of associated symptoms.

Case Report

Our 54-year-old patient presented with left sided lymph node enlargement in regions II, III and IV without any other clinical signs. Physical examination of the oral cavity revealed semicircular bulge at the base of tongue

measuring 30x20 mm and tumorous lesion was suspected. Neck ultrasound and FNA of pathologically enlarged lymph node in region II and III was performed. Squamous carcinoma cells were identified in the smear of lymph node. Further investigation included CT and MRI of the neck, which depicted sharply, bordered formation measuring 30x23x20 mm in tongue base and enlarged, necrotic lymph nodes in regions II and III. (Figure 1–5) There was no thyroid gland in cervical neck, in expected position. CT and MRI characteristics of lingual mass displays intense homogenous enhancement resembled ectopic thyroid tissue. Diagnosis of lingual thyroid was supposed. Blood test results showed that patient was euthyrotic. There were no other suspected pathology in scanned neck region. Primary carcinoma could not be depicted at that time, by imaging. Biopsy of the lingual mass was performed and histology confirmed ectopic thy-

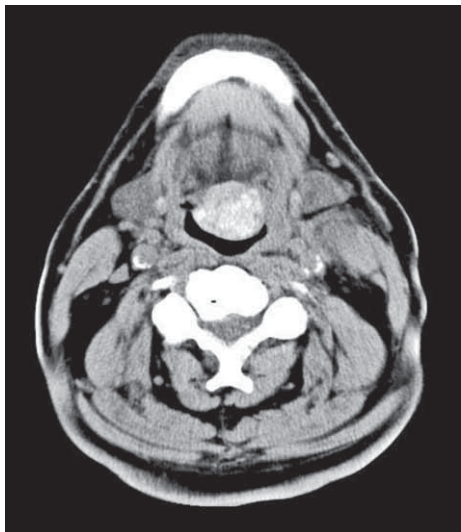


Fig. 1. Unenhanced axial scan through the base of tongue shows centrally placed lingual thyroid, at the expected location of foramen cecum. Within sharply delineated and hyperdense lesion numerous small calcifications are visible. Bulging of the lesion into pharynx is evident.

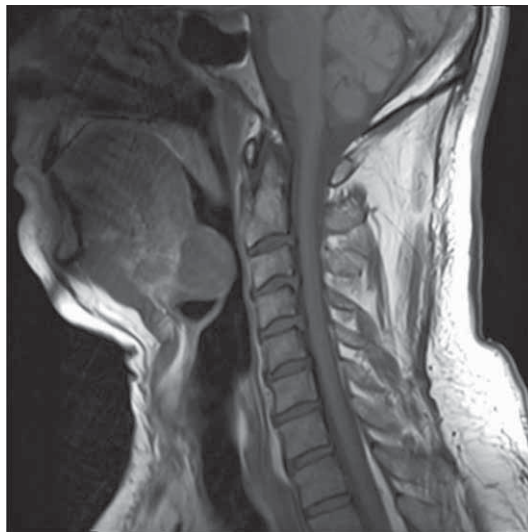


Fig. 3. On the left side, in region II a necrotic lymph node is visible. This sagittal T1 WI MRI scan shows sharply delineated lesion at the base of tongue, at the expected location of foramen cecum. The signal of this lesion is isointensive with surrounding musculature.

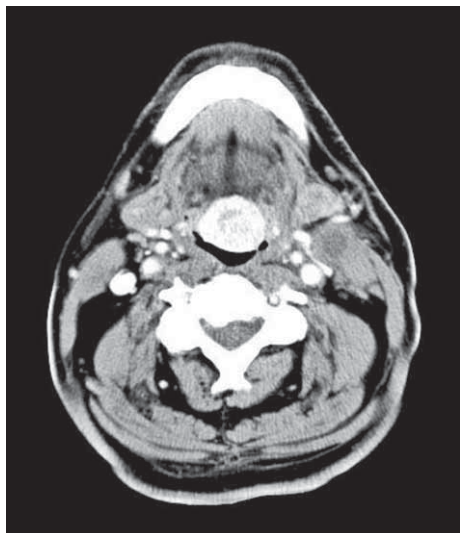


Fig. 2. Contrast enhanced axial scan shows intensive enhancement of the lingual thyroid.

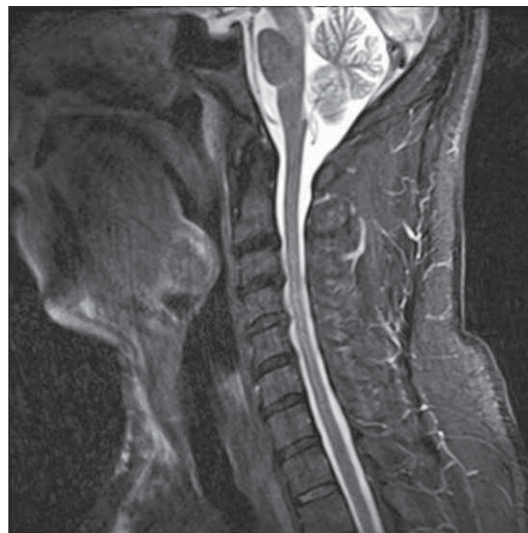

Fig. 4. This sagittal T2 STIR MRI scan shows sharply delineated lesion at the base of tongue with higher signal intensity compared to surrounding musculature.

roid tissue. During controlled physical examination, suspicious area measuring 10x10 mm on the left side of the tongue base, near ectopic thyroid, was identified. Histology after biopsy confirmed squamous cell carcinoma with superficial growth. Radical neck dissection, chemotherapy and radiation were performed.

Discussion

Lingual thyroid results from failure of the thyroid gland to descend from the foramen cecum to the lower

neck⁵. Even with normal appearing thyroid gland, residual thyroid tissue may appear anywhere along the thyroglossal tract¹. Approximately two thirds of the patients with lingual thyroid lack thyroid tissue in neck, like our patient². In 75% lingual thyroid is the only functioning thyroid tissue. The standard treatment of ectopic thyroid varies. Surgical treatment is preferred when there are symptoms like dysphagia or dyspnea.

The diagnosis of lingual thyroid is usually made clinically and radionuclide scanning is used to confirm the diagnosis. Because of pathologic lymph nodes, in our case,

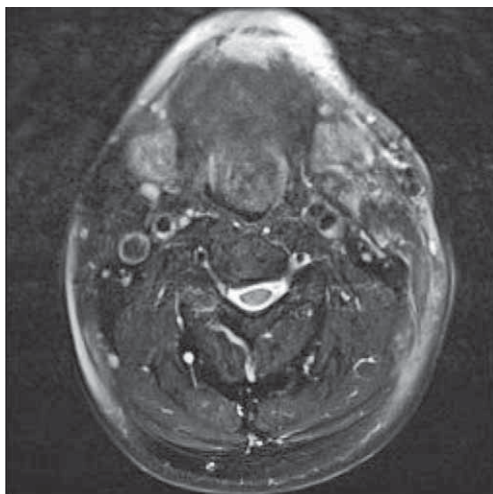


Fig. 5. This axial T2 MRI scan shows sharply delineated high signal lesion, placed medially at the base of tongue.

first diagnostic methods were Ct and MR targeting primary cancer.

REFERENCES

1. WILLIAMS JD, SCLAFANI AP, SLUPCHINSKIJ O, DOUGE C, Ann Otol Rhinol Laryngol, 105 (1996) 312. — 2. CHARLES ND, Thyroid and whole-body imaging. In the thyroid, 5th ed (Lippincot, Philadelphia, 1986). — 3. NEINAS FW, GORMAN CA, DEVINE KD, WOOLNER LB,

Ann Intern Med, 79 (1973) 205. — 4. KUMAR V, NAGENDHAR Y, PRAKASH B, CHATTOPADHYAY A, YEPPAKOMA D, Indian J Pediatr, 71 (12) (2004) e62. — 5. DOUGLAS PS, BAKER AW, Br J Oral Maxillofacial Surg, 32 (1999) 123.

Therefore, we emphasize the importance of cooperation between radiologist and otolaryngologist, particularly in the oropharyngeal region where the surface pathological lesions can occur. While they do not infiltrate the deeper structures, with radiological methods it may be difficult to see them.

Lingual thyroid was correctly diagnosed using radiology imaging techniques but primary carcinoma, regarding the small size and superficial growth of the lesion, could not be depicted. Vicinity of ectopic thyroid gland is also likely to complicate an accurate diagnosis.

B. Čandrlić

University of Rijeka, Rijeka University Hospital Center, Department of Radiology, Krešimirova 42, 51000 Rijeka, Croatia
e-mail: barbaracandrlic@yahoo.com

BOLESNIK SA JEZIČNOM ŠTITNJAJČOM I PLANOCELULARNIM KARCINOMOM BAZE JEZIKA – PRIKAZ SLUČAJA

SAŽETAK

Prikazali smo rijedak slučaj jezične štitnjače udružene sa planocelularnim karcinomom baze jezika. Bolesnik u dobi od 54 godine se prezentirao sa ljevostranim čvorovima na vratu u regiji II, III i IV, bez drugih simptoma. Citološkom punkcijom čvora su dobivene maligne pločate stanice. Fizikalnim pregledom je uočena polukružna tvorba baze jezika suspektna na tumor. Daljnje pretrage su uključivale CT i MR vrata te su pokazale ektopično tkivo štitnjače u bazi jezika i povećane nekrotične čvorove u regijama II i III. Nije prikazan promarni karcinom. Biopsijom baze jezika je potvrđena ektopična štitnjača. Ponovljen je klinički pregled usne šupljine, te je detektirano suspektno područje na lijevoj strani jezika blizu ektopične štitnjače. Ponovljena biopsija je potvrdila planocelularni karcinom. Ovaj slučaj naglašava potrebu suradnje radiologa i otorinolaringologa potrebnu za točnu dijagnostiku orofaringealne regije. Također napominjemo važnost egzaktnog pregleda orofarinksa kod nepoznate limfadenopatije, gdje treba razmotriti mogućnost primarnog tumora orofarinksa.