

Ammonia Intoxication on Workplace - Case Report and a Review of Literature

Lalić, Hrvoje; Djindjić-Pavičić, Milanka; Kukuljan, Melita

Source / Izvornik: **Collegium antropologicum, 2009, 33, 945 - 949**

Journal article, Published version

Rad u časopisu, Objavljena verzija rada (izdavačev PDF)

Permanent link / Trajna poveznica: <https://um.nsk.hr/um:nbn:hr:184:120746>

Rights / Prava: [Attribution 4.0 International](#)/[Imenovanje 4.0 međunarodna](#)

Download date / Datum preuzimanja: **2024-08-31**



Repository / Repozitorij:

[Repository of the University of Rijeka, Faculty of Medicine - FMRI Repository](#)



Ammonia Intoxication on Workplace – Case Report and a Review of Literature

Hrvoje Lalić¹, Milanka Djindjić-Pavičić² and Melita Kukuljan³

¹ Department of Occupational Medicine, School of Medicine, University of Rijeka, Rijeka, Croatia

² Department of Radiology, Polyclinic »Sunce« Rijeka, Rijeka, Croatia

³ Department of Radiology, University Hospital Center »Rijeka«, School of Medicine, University of Rijeka, Rijeka, Croatia

ABSTRACT

In December 2003 in Rijeka, Croatia, a work accident happened when in the meat industry »Vir« a forklift damaged the ammonia pipe. Two butchers were acutely poisoned. The objective is to warn of the danger of ammonia and of the need to improve preventive programs of occupational medicine. The method of comparing the two injured workers, i.e. their spirometric values, was used. The results showed progressive diminishing of patients' respiratory abilities, in the patient with lungs transplanted VC 32%, FVC 33%, FEV1 16% and FEF75%=6% in 2006, the year when he died. In the patient that survived, the values in 2008 were VC 43.5%, FVC 27.2%, FEV1% 56.7% and FEF75%=6%. The patients' CT showed diffused fibrosing and bronchiectasiae. Obliterating bronchiolitis developed in both patients. The second patient is the lung transplantation candidate. The first patient developed post transplantation cytomegalovirus pneumonia so he fought CMV antigenemia and infection till the end.

Key words: occupational medicine, intoxication, work accident

Introduction

There are three possibilities of ammonia intoxication. The first, the one in the war is behind us since the Chechen war¹. Also, there has not been any mention of ammonia used by terrorists. The other possibility lies in the human organism itself, when there is defect in the urea cycle with the consequence of developing hyperammonemia². We are interested in the civilian use of ammonia that is for occupational medicine the use in the working process of that gas from the group of irritants gases. That colourless gas of pungent smell is used mainly as agricultural fertilizer and industrial refrigerant³. Inadequate handling of the gas may cause explosion and lethal consequences. The resulting injuries are mainly to the respiratory tract, eyes, skin damage and burns as well as traumatic injuries⁴. The most endangered is the respiratory tract due to ammonia inhalation. The consequences are cutaneous burns, pulmonary oedema, pulmonary infection, bronchiectasiae and fibrosis⁵. Respiratory difficulties have been described in children living near factories producing artificial fertilizers as they use ammonia⁶. The largest number of acci-

dents takes place in stationary plants, while in transportation there have been few accidents most probably because of high precautions^{7,8}. In case of an accident well-trained rescue teams of paramedics and firemen have to be ready to enter the contaminated area, give help, evacuate and sanitize the area⁹. The injured have to be stripped off their clothes immediately to avoid further poisonous fumes and irrigation by water has to be ensured¹⁰.

The purpose of the paper is to show the course of action after the accident in the meat industry »Vir« in Rijeka, Croatia, when a forklift caught the pipe running on the floor of a workshop and caused a sudden burst of a large quantity of ammonia. Two butchers happened to be near the pipe, one in the immediate vicinity and the other some meters away, so both were directly exposed to ammonia. It all happened in a moment, they lost consciousness one after another and were taken urgently by a rescue team to the emergency department of the Clinical Hospital Centre in Rijeka.

Examinees and Methods

In the accident that occurred on December 2003 two butchers employed by the meat industry »Vir« in Rijeka, Croatia, were injured.

The First Patient

It was a young butcher, aged 20, of excellent health and fitness before the accident. He was taken to Intensive Care Unit of Clinical Hospital Centre Rijeka as an acutely injured person with signs of ARDS (acute respiratory distress). As he was unable to breathe percutaneous tracheotomy was performed and he was connected to the respiratory apparatus. He had received second and third degree burns all over the body. The bronchoscopy showed numerous fibrins sediments and pus deposits. Intensively treated the patient was taken off the respirator and transferred to ICU in Rijeka in February 2004. The lung CT was performed and it showed progression of bulbous and fibrotic changes on both lungs. Staphylococcus aureus and pseudomonas aeruginosa were isolated from his swab, he was running temperature and in March 2004 he was transferred to Pulmology of Clinical Hospital Centre. He was given bronchodilators and oxygen therapy. His condition did not improve and he was taken to Jordanovac Hospital in Zagreb that is Croatian referential centre for lung diseases.

The patient who was moderately cachectic, 70% of ideal body mass, because of low O₂ values and high CO₂ values was given mechanical respiratory support. MSCT diagnostics showed diffuse necroses, multiple cysts 4–8 cm in diameter, extensive fibrosis, condensation of lower right lobe. The ventilation scanner showed 19% of the sustained ventilation of the right lung and 81% of the left lung. Perfusion of the right lung was 36% and of the left one 64%.

On the basis of international cooperation the patient was transferred to University Clinic in Padova, Thoracic surgery department, where transplantation of both lungs was performed on April 29, 2004. The patient took the operation well, the lungs took over the respiratory function spontaneously, but unfortunately he developed cytomegalovirus pneumonia. He was discharged from the Padova hospital and recommended to take large quantities of medicaments: Ciklosporin (Sandimun Neoral) 125+150 mg, Omeprazol (Ulzol) 20 mg, Nistatin, Valaciclovir (Zelitrex) 500+500 mg, Sinersul forte 1+1, Fursemid 25 mg, Prednison 15 mg, Fluconazol (Diflucan) 100 mg, Imuran (Azatioprin) 125 mg, Amlodipin 5mg, Atorvastatin (Sortis) 10 mg, Azitromicin (Sumamed) 500 mg every second day, Bisoprolol (Concor) 1x1 daily.

The patient was discharged to home care and looked after by his general practitioner in Opatija near Rijeka, where he used to live. In December 2004 his temperature was up to 38.3°C and he was tachycardian, but with Rocefin and Amicacin his condition improved. The blood sample on CMV, ppCMV showed two cells per slide. Auscultator bronchitis murmurs were found above the

lungs by his GPs. The GP added Eritromicin to the therapy and the patient complained of breathlessness, tiredness and tachycardia.

At the beginning of 2005 he had the control in Padova. The lung RTG was negative to spots, but there was positive antigenemia on CMV. Valaciclovir therapy was stopped and he was given Gancyclovir intravenously 2X daily. He had been fitted with Groshong catheter earlier. In May 2005 at home pseudomonas aeruginosa was isolated on pharyngeal tampon.

He got temperature again approximately 38 degrees C, reacting to Paracetamol and antibiotics.

In Padova in June 2005 VC and FEV1 was 100% of theoretical, FEF25–75% was 93% of theoretical.

The control was ordered in 5–6 months.

In July 2005 enterobacter aerogenes was isolated from his sputum. He reacted to Amoxiclav.

In August there was a considerable decrease in otherwise steadily controlled cyclosporinemia, the GP increased Sandimun Neoral for 25 mg, around Groshong catheter a red area and purulent discharge appeared. Blood leukocytes increased to 17.800. Augmentin 1 gr was added 2X1 tablet.

In November 2005 he got temperature 39°C and was given Targocid (Teikoplamin) 400 mg.

He was taken to Padova. Thoracic biopsies showed bronchiolitis obliterans and polymorph inflammatory changes. Spirometry showed a significant decrease of respiratory functions.

He was discharged home where he developed hematuria caused by right kidney stone.

In January 2006 the performed spirometry indicated the high degree of restrictive and obstructive ventilation disturbances. Instead of Sandimun Neoral, Prograf (Tacrolimus) 3mg 2X1 tablet daily was introduced.

The hospitalisation in Padova in May 2006 showed a considerable reduction of respiratory status so he was prescribed oxygen for permanent use at home.

In July 2006 he was admitted to the Jordanovac Hospital in Zagreb and received the therapy:

Cell Cept 2X1 gr, Decortin 15 mg, Prograf 3+3 mg, Sinersul f. 2X1, Sumamed 250 mg, Diflucan 100 mg, Nistatin sol. 3X daily, Controloc 40 mg, Concor 5 mg, Sortis 1X daily, Zelitrex 2X500 mg, Seretide 2X500 mg, Spiriva 1 inhalation daily.

The last hospitalisation in Padova after the sojourn in Jordanovac confirmed acute ventilation disturbances and required a long-lasting application of oxygen. The patient died soon as the consequence of one of subsequent infections of the considerably weakened lungs.

The Second Patient

The second patient was also a butcher, at the time of the accident he was 53, in good health, when young he had pneumonia with no consequences. Like the first pa-

tient he was treated of ARDS in the units of intensive care of CHC Rijeka and also in Jordanovac.

Progression of the consequences of ammonia inhalation in the patient develops more slowly. Nevertheless, numerous cylindrical and varicose bronchiectasiae have developed so bronchiolitis obliterans was diagnosed. The patient has restrictive and obstructive ventilation disturbances of high degree.

His therapy consists of Seretide 2X500 mg caps, Spiriva 1 inhalation daily, Iruzid ½ tablet daily, Medrol 1 tablet every second day and Imuran 2X50 mg. Fursemid is taken when needed, 2–3 times a week 1 tablet. Unable to work at all, he was breathless even when resting. He is becoming the lung transplantation candidate.

Methods

The simple method of comparing respiratory values of the two presented patients was used.

Results

The results of spirometric values from 2006 of both patients, and those from 2008 of the patient that survived show restrictive and obstructive ventilation disturbances of high degree (Table 1), (Figure 1).

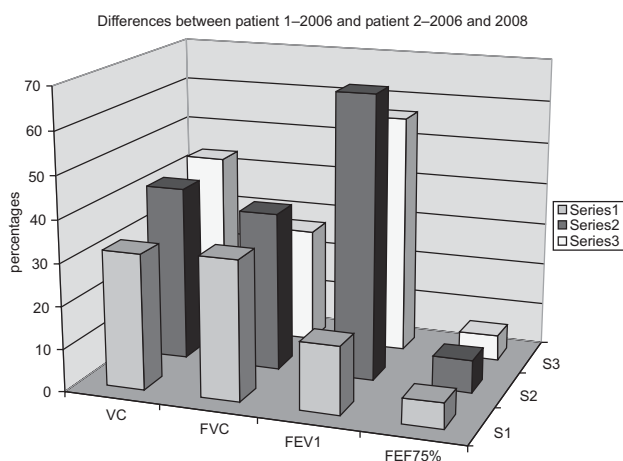


Fig. 1. S1 – patient's 1 spirometric values in percentages in 2006, S2 – patient's 2 spirometric values in percentages in 2006, S3 – patient's 2 spirometric values in percentages in 2008.

TABLE 1
PATIENT'S SPIROMETRIC VALUES FROM 2006, AND SURVIVED PATIENT'S SPIROMETRIC VALUES FROM 2006 AND 2008, IN PERCENTAGES

Patient No	Sex	Age	Year of examination	VC%	FVC%	FEV1%	FEF75%
1	M	20	2006	32	33	16	6
2	M	53	2006	41.4	37.4	66.8	7.6
2	M	53	2008	43.5	27.2	56.7	6

VC, Vital capacity, FVC, Forced vital capacity, FEV1, Forced expiratory volume in first second, FEF 75%, Forced expiratory flow at 75% forced vital capacity.

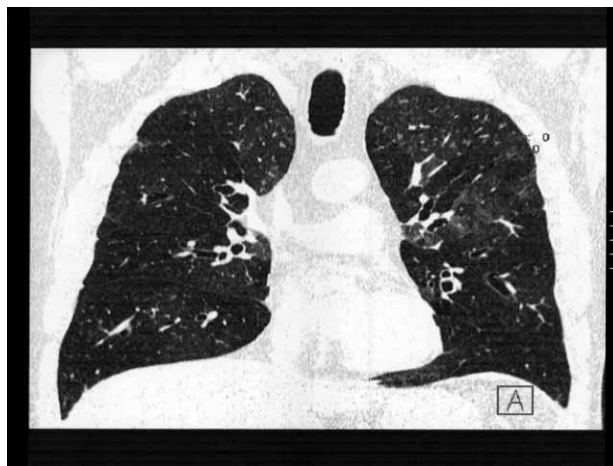


Fig. 2. Patient's 1 – numeral bronchial widening in both lungs.

Bronchiectasiae of the deceased patient are noticeable on both lungs (Figure 2).

Discussion

The first patient's X-ray after the operation in Padova in Italy showed an excellent condition. Unfortunately, like every transplanted patient, he underwent immuno therapy and the immuno-compromised body had low resistance to infections that seldom affect healthy persons. Although cytomegalovirus pneumonia was suppressed it left a mild CMV antigenemia in the patient's body that had to be fought for the rest of his life. The only solution for the young, earlier healthy man was the lung transplantation, which he expected as the beginning of a new, normal life. Sudden inhalation in acute ammonia intoxication leads to progressive weakening of respiratory functions¹¹. Lung fibrosis, accompanying respiratory disturbances which were progressively increasing, were also intensified by general toxic effects of burns all over the patient's body, which also stimulated development of complications¹². The patient was submitted to a number of bronchoscopic tests, which are nowadays indispensable in direct observing of the condition in bronchial tree and bronchioles¹³. MSCT techniques showed atelectatic changes, cylindrical and varicose bronchiectasiae. Spirometric monitoring showed a progressive fall in respira-

tory functions. Because of all mentioned, the described lung transplantation was performed.

The family doctor who cared for the young patient from Opatija, Littoral-Mountainous County, bore a great burden of out-of-hospital treatment. Many of the expensive immunosuppressive and special antibiotics prescribed in Italy may be obtained only in medical institutions. Therefore the mentioned GP had to apply to Croatian Institute for Health Insurance to approve certain medications for the use at the patient's home. Some of the medications are not on the List approved by the Republic of Croatia so an adequate substitute was required. Furthermore, each change in the health condition, rise in temperature, changes in the level of cyclosporinemia required of the physician the utmost care, including contacting the surgeon in Padova by phone or in writing. The patient had frequent high tachycardia, which can accompany acute ammonia intoxication, different from the symptoms of chronic intoxication accompanied by bradycardia and other symptoms^{14,15}. For that reason the patient was consultatively treated by a cardiologist, with a mild cardiologic therapy. He was given corticosteroids, though some studies state that corticosteroid inhalations have no effect on lungs damaged by ammonia inhalation and have no impact on changing gases^{16,17}. Some experimental studies say that the inhaled small concentrations of ammonia do not cause obstruction of upper respiratory tract¹⁸. In the described case it is irrelevant as the patient was intoxicated by high concentrations of ammonia in a very short period, which is covered by the defini-

tion of acute intoxication. The experiments have shown that hyperammonemia weakens neutrophil phagocytes causing them swelling¹⁹. A significant increase of leukocytes and neutrophils appears in peripheral blood²⁰. The presented transplanted patient had repeatedly high white count, which went up to 17.000. He was prone to frequent infections, agents being isolated from his catheter swab or sputum.

Unfortunately, three years after the accident and two years after the transplantation the young patient who developed obliterating bronchiolitis on the transplanted lungs died.

The second patient has been living with now developed restrictive and obstructive ventilation disturbances of high degree and development of obliterating bronchiolitis in his lungs. He is the lung transplantation candidate. This paper wanted to warn of the danger from ammonia, of the consequences it may have for healthy, able-bodied people. Not only for them, but their families, physicians with their incredible devotion shown in treatment of such serious cases, for Croatian Institute for Health Insurance that covers huge expenses, for surgeons in Italy and the whole community.

Therefore, needless to say, it is most important to continue prevention, to avoid such situations, to train and adequately equip rescue teams as well as occupational medicine professionals to enable them to recognize, assess and coordinate such »toxic« disasters.

REFERENCES

1. MARAKOVSKY I, MARKEL G, DUSHNITSKY T, EISENKRAFT A, *Isr Med Assoc J*, 10 (2008) 537. — 2. SUMMAR ML, BARR F, DAWLING S, SMITH W, LEE B, SINGH RH, RHEAD WJ, SNIDERMAN KING L, CHRISTMAN BW, *Crit care Clin*, 21 (2005) 1. — 3. ANONYMOUS, *MMVR Morb Mortal Wkly Rep*, 54 (2005) 359. — 4. BERKOWITZ Z, ORR ME, KAYE WE, HAUGH GS, *J Occup Environ Med*, 44 (2002) 714. — 5. WOTO-GAYE G, MENDEZ V, BOYE IA, NDIAYE PD, *Dakar Med*, 44 (1999) 199. — 6. GOMZI M, SARIC M, *Int Arch Occup Environ Health*, 70 (1997) 314. — 7. WELLES WL, WILBURN RE, ERLICH JK, FLORIDIA CM, *J Hazard Mater*, 115 (2004) 39. — 8. WEISSKOPF MG, DREW JM, HANRAHAN LP, ANDERSON HA, HAUGH GS, *J Occup Environ Med*, 45 (2003) 197. — 9. EDLICH RF, FARINHOLT HM, WINTERS KL, BRITT LD, LONG WB, WERNER CL, GUBLER KD, *J Long Term Eff Med Implants*, 15 (2005) 303. — 10. AMSHEL CE, FEALK MH, PHILLIPS BJ, CARUSO DM, *Burns*, 26 (2000) 493. — 11. LEDUC D, GRIS P, LHEREUX P, GEVENOIS PA, DE VUYST P, YEARNULT JC, *Thorax*, 47

(1992) 755. — 12. WHITE C, PARK MS, RENZ EM, KIM SH, RITENOUR AE, WOLF SE, CANCIO LC, *J Burn Care Res*, 28 (2007) 922. — 13. KERSTEIN MD, SCHAFFZIN DM, HUGHES WB, HENSELL DO, *Mil Med*, 166 (2001) 913. — 14. GEORGE A, BANG RL, LARI AR, GANG RK, KANJOOR JR, *Burns*, 26 (2000) 409. — 15. BRAUTBAR N, WU MP, RICHTER ED, *Arch Environ Health*, 58 (2003) 592. — 16. SJOBLOM E, HOJER J, KULLING PE, STAUFFER K, SUNESON A, LUDWIGS U, *J Toxicol Clin Toxicol*, 37 (1999) 59. — 17. HOJER J, LUDWIGS U, *J Toxicol Clin Toxicol*, 38 (2000) 81. — 18. SIGURDARSON ST, O'SHAUGHNESSY PT, WATT JA, KLINE JN, *Am J Ind Med*, 46 (2004) 345. — 19. SHAWCROSS DL, WRIGHT GA, STADLBAUER V, HODGES SJ, DAVIES NA, JONES C, PITSILLIDES AA, JALAN R, *Hepatology*, 48 (2008) 1202. — SUNDBLAD BM, LARSSON BM, ACEVEDO F, ERNSTGARD L, JOHANSON G, LARSSON K, PALMBERG L, *Scand J Work Environ Health*, 30 (2004) 313.

H. Lalić

Department of Occupational Medicine, School of Medicine, University of Rijeka, Brentinijeva 5, 51000 Rijeka
e-mail: hlalic@inet.hr

OTROVANJE AMONIJAKOM NA RADNOM MJESTU – PRIKAZ SLUČAJA I PREGLED LITERATURE

SAŽETAK

U prosincu 2003. godine u Rijeci, u Hrvatskoj, dogodila se nesreća na radu kada je u mesnoj industriji »Vir« viljuškar udario u cijev kojom je prolazio plin amonijak. Tom prilikom akutno su otrovana dva mesara. Cilj je ukazati na opasnost koja vrebala i u današnje vrijeme od plina amonijaka ukoliko dođe do akcidenta, te na potrebu jačanja preventivnih programa od strane medicine rada. U radu korištena je metoda usporedbe dvojice ozlijeđenih radnika, odnosno njihovih spirometrijskih vrijednosti. Rezultati su pokazali progresivno smanjivanje respiracijskih sposobnosti pacijenata, kod transplantiranog pacijenta sa transplantirana oba plućna krila VC 32%, FVC 33%, FEV1 16%, FEF75%=6%, 2006. godine, koji je te godine i preminuo. Kod preživjelog pacijenta 2008. godine vrijednosti su VC 43,5%, FEV1 27,2%, FEF75%=6%, 2008. godine, koji je te godine i preminuo. CT snimke pacijenata ukazuju na difuzne fibrozirajuće promjene i bronhiektazije, te razvoj obliterirajućeg bronhiolitisa, na transplantiranim plućima, odnosno na vlastitim plućima pacijenta koji nije transplantiran. Drugi pacijent je kandidat za transplantaciju pluća. Prvi pacijent je dobio citomegalovirusnu pneumoniju po transplantaciji, te se borio protiv CMV antigenemije i infekcija do smrti. Usprkos uznapredovaloj i vrhunskoj operativnoj tehnici, preventivne mjere koje mora sprovoditi medicina rada u sprečavanju ovakvih nezgoda i razvijanja plana akcije za vrijeme akcidenata i danas ostaju na prvom mjestu.