

# Dermatomycosis in Cutaneous Tumors is a Predictor for Non-malignancy: A Cross-sectional Study

---

Čabrijan, Leo; Lipozenčić, Jasna; Cvečić, Ana; Goldust, Mohamad

Source / Izvornik: **Acta Dermatovenerologica Croatica, 2019, 27, 231 - 234**

Journal article, Published version

Rad u časopisu, Objavljena verzija rada (izdavačev PDF)

Permanent link / Trajna poveznica: <https://um.nsk.hr/um:nbn:hr:184:953750>

Rights / Prava: [In copyright](#)/[Zaštićeno autorskim pravom.](#)

Download date / Datum preuzimanja: **2024-12-18**



Repository / Repozitorij:

[Repository of the University of Rijeka, Faculty of Medicine - FMRI Repository](#)



# Dermatomycosis in Cutaneous Tumors is a Predictor for Non-malignancy: A Cross-sectional Study

Leo Čabrijan<sup>1</sup>, Jasna Lipozenčić<sup>2</sup>, Ana Cvečić<sup>3</sup>, Mohammad Goldust<sup>4</sup>

<sup>1</sup>Department of Dermatology, Clinical Hospital Centre, Rijeka, Croatia; <sup>2</sup>Croatian Academy of Medical Sciences, Zagreb, Croatia; <sup>3</sup>Department of Dermatology, Universal Hospital Pula, Croatia; <sup>4</sup>Department of Dermatology, Mazandaran University of Medical Sciences, Sari, Iran

## Corresponding author:

Leo Čabrijan, MD, PhD  
Department of Dermatology and Venereology  
Clinical Hospital Centre Rijeka  
Krešimirova 42  
51000 Rijeka  
Croatia  
[leo.cabrijan@ri.t-com.hr](mailto:leo.cabrijan@ri.t-com.hr)

Received: July 23, 2019

Accepted: November 15, 2019

**ABSTRACT** The aim of this study was to evaluate the presence of spores and/or hyphae in benign cutaneous tumors (CT) and compare their presence in malignant cutaneous tumors. In this cross-sectional study we evaluated 328 CTs positive for spores and/or hyphae. The results show that the greatest number of involved CTs which contained spores and/or hyphae were found in compound nevi 181 (55.18%) and seborrheic warts 61 (18.60%). No spores and/or hyphae were observed in the melanoma samples, and a very low prevalence was found in squamous cell carcinomas (SCCs) (2; 0.61%) and basal cell carcinoma (BCC) (1; 0.30%). The presence of spores and/or hyphae could be a good indicator for non-malignancy, allowing differential diagnosis between benign CTs and SCCs or BCCs as well as between melanoma and nevi.

**KEY WORDS:** spores, hyphae, cutaneous tumors

## INTRODUCTION

In clinical practice, it is not usual to see any signs of dermatomycosis in cutaneous tumors (CTs).

In histopathological examination, little attention is usually given to spores and/or hyphae in the stratum corneum of CTs, and this is the reason why they are rarely found in histopathological descriptions. Another reason is the difficulty in distinguishing spores and erythrocytes under histopathological examination.

The skin does not show signs of dermatomycosis on examination. Under light microscopy stained with hematoxylin and eosin, spores and/or hyphae that can be seen in stratum corneum of nevi (compound and lentiginous), as well as in seborrheic warts, fibropapillomas, keratoacanthomas, dermatofibromas, and actinic keratoses. They are rare in carcinoma *in situ* (Ca *in situ*), SCCs, and BCCs, and have not been observed in any melanoma in our study.

The aim of this study was to compare the presence of spores and/or hyphae in benign and malignant skin tumors.

## PATIENTS AND METHODS

In this cross-sectional study, we collected samples positive for spores and/or hyphae from the pathological laboratory at the Department of Dermato-venereology, Rijeka University Hospital Center, Rijeka, Croatia over a two-years period. These samples were previously histopathologically confirmed as benign or malignant tumors. We collected histopathology samples of fibropapillomas, seborrheic warts, actinic keratoses, compound nevi, dysplastic nevi, intradermal nevi, epidermal nevi, keratoacanthomas, pigmented actinic keratosis, Bowen disease (Ca *in situ*), BCC, SCCs, solar lentigo, and dermatofibromas.

For histopathology, we simply used a hematoxylin and eosin stain and PAS stain to confirm the presence of hyphae or spores in all collected samples.

We did not perform mycological examination in our patients with CTs since there were no clinical manifestations or signs of dermatomycosis or pityriasis versicolor.

## RESULTS

In cases of benign and malignant CTs we observed clear hyphae and/or spores in the stratum corneum upon pathohistological examination.

Spores and/or hyphae were observed in the 328 histopathologically positive samples as follows: compound nevi 181 (55.18%), seborrheic warts 61 (18.60%), actinic keratoses 24 (7.32%), fibropapillomas 23 (7.01%), Ca *in situ* 14 (4.27%), dysplastic nevi 11 (3.35%), keratoacanthomas 3 (0.91%), intradermal nevi 3 (0.91%), SCCs 2 (0.61%), epidermal nevi 2 (0.61%), pigmented actinic keratosis 1 (0.30%), BCC 1 (0.30%), dermatofibroma 1 (0.30%), and solar lentigo 1 (0.30%) (Table 1).

We evaluated 22 melanomas in our histopathological reports, with none showing any spores and/or hyphae. Out of 37 SCCs (one Mb. Bowen) we found two positive samples with spores in the two-year period.

## DISCUSSION

The present study indicates that malignant tumors have some kind of self-immunity against dermatomycosis. This indirectly allowed us to conclude that there is no melanoma present when hyphae or

spores are detected in stratum corneum in the melanocytic lesion.

There are few studies which describe CTs containing hyphae or spores (1-4). We wanted to explore these findings further and decided to conduct our own study on various types of CTs (benign and malignant) positive for spores and/or hyphae, and compare them with one another. This sample comparison could clarify in which types of CTs spores and/or hyphae are more often present.

Only one previous study evaluated the connection between melanoma and dermatomycosis; a case of acral melanoma and onychomycosis found together (5). Onychomycosis is not rare and therefore the possibility of previous coexistence or presence at the same time may also explain that finding.

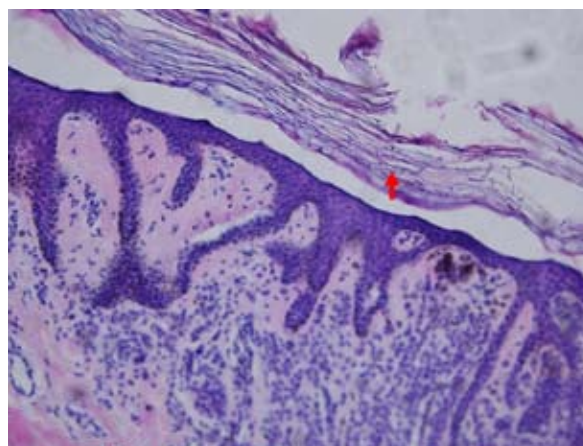
Tseng *et al.* reported similar findings with diagnosis of tinea nigra plantaris or differentiation from plantar melanoma (6) as well as differentiation from junctional nevi in the same region (7).

Dermoscopy can also help in distinguishing tinea nigra from malignant melanoma as well as junctional nevi (8,9).

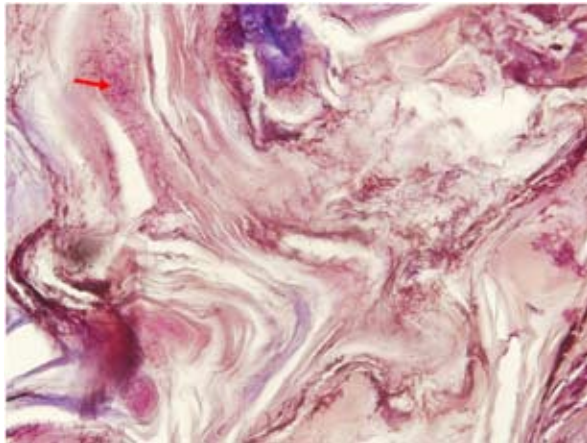
*Pityrosporum (P.) ovale* is found in keratotic lesions of the seborrheic areas and in seborrheic keratoses, actinic keratoses, viral warts, and nevocellular nevi (1). It is thought that *P. ovale* could be important in pathogenesis of seborrheic keratosis and responsible for their development (1). In that study, the prevalence of *P. ovale* was not statistically higher in seborrheic keratoses, in contrast with other keratotic lesions that were observed (1). This theory is hard to prove, since we have found hyphae/and or spores in other CTs as well in some Ca *in situ* and dermal nevi. It is not conclusive that *P. ovale* is responsible for development of all the above CTs.

**Table 1.** Number and percentages of CTs positive (and negative) for spores and/or hyphae

Tumor	Number of tumors	Percentage
Compound nevi	181	55.18%
Seborrheic warts	61	18.60%
Actinic keratoses	24	7.32%
Fibropapillomas	23	7.01%
Ca <i>in situ</i>	14	4.27%
Dysplastic nevi	11	3.35%
Keratoacanthomas	3	0.91%
Intradermal nevi	3	0.91%
SCC	2	0.61%
Epidermal nevi	2	0.61%
BCC	1	0.30%
Pigmented actinic keratosis	1	0.30%
Dermatofibroma	1	0.30%
Solar lentigo	1	0.30%
<b>TOTAL</b>	<b>328</b>	



**Figure 1.** Spores and hyphae (red arrow) in the stratum corneum of a compound nevus; PAS stain  $\times 100$ .



**Figure 2.** Spores and hyphae (red arrow) in the stratum corneum of seborrheic keratosis; PAS stain  $\times 200$ .

One previous study compared the presence of *P. ovale* in seborrheic keratoses versus melanocytic tumors (papillomatous nevi) (2). Their results revealed that 62% of papillomatous nevi were positive with *P. ovale* in comparison with 45% seborrheic keratoses being positive with *P. ovale* (2).

We observed spores in compound nevi (55.18%) as shown in Figure 1 (red arrow) and in seborrheic warts (18.60%) as shown in Figure 2 and Figure 3 (red arrow). Interestingly, we also observed a relatively high percentage of spores in actinic keratoses (7.32%) and Ca *in situ* (4.27%), which showed that semi-malignant lesions could also contain spores. We found a low percentage of spores in malignant tumors, 2 in SCCs (0.61%) and 1 in BCCs (0.30%)

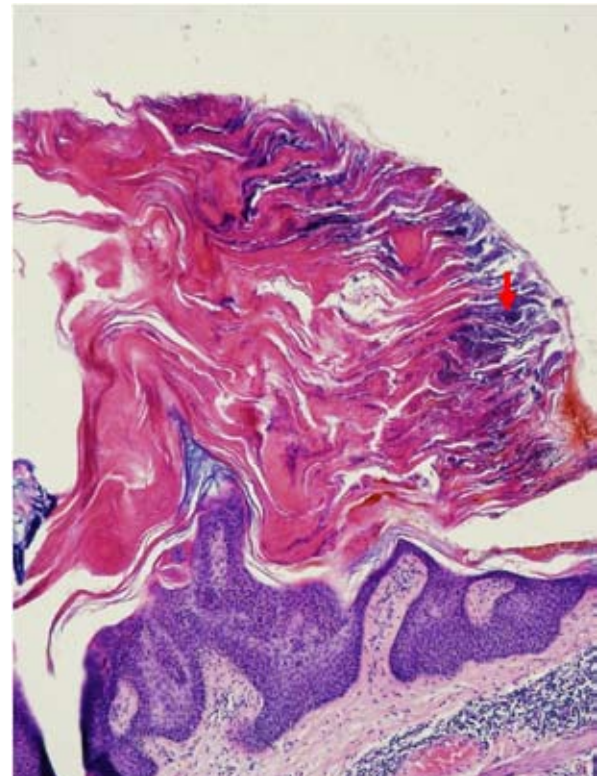
In the study by Borestein *et al.*, *P. ovale* was present in the majority of seborrheic keratoses in comparison with verruca vulgaris and BCCs (3).

Brazdil *et al.* demonstrated that 43% of seborrheic keratoses-warts were positive for spores and were associated with prominent hyperkeratosis and papillomatosis (4).

These results are similar to ours, since we found spores and/or hyphae mostly in seborrheic warts and compound nevi.

Therefore, it is not rare to see spores and/or hyphae in benign CTs under dermatoscopic examination, but their presence without clinical signs of dermatomycosis may lead to some implications on the behavior of these tumors.

According to our results, there is strong evidence for the predominance of spores and/or hyphae in benign CTs. Therefore, melanoma and other malignant skin tumors may not be good host for spores and/or hyphae or these tumors have their own immunity against them.



**Figure 3.** Spores and hyphae (red arrow) in the stratum corneum of seborrheic keratosis; hematoxylin and eosin stain  $\times 100$ .

We found spores only rarely: in 24 actinic keratoses (7.32%), 14 (4.27%) in Ca *in situ* (Bowen disease) and 3 (0.91%) in keratoacanthomas, in comparison with other studies that found *P. ovale* in seborrheic keratoses, actinic keratoses, nevi, and viral warts (5).

One of the reasons why we found greater presence of spores and/or hyphae in CTs may also be because people believe CTs should not be touched or even washed. No evidence of spores was found on other parts of the skin. The clinical manifestations of dermatomycosis or pityriasis versicolor were also negative.

## CONCLUSION

In our subject study, spores and/or hyphae were not present in melanoma and were rarely in BCC and SCC.

We therefore conclude that it is not rare to find dermatomycosis in CTs, and if spores and/or hyphae are found in the CTs it can be presumed that they are not malignant tumors. Our findings may also facilitate the diagnosis and differentiation between benign and malignant CTs in some doubtful cases, especially for melanoma.

### References:

1. Bourlond A, Votion V, Armijo F, Minne G. *Pityrosporum ovale* in keratotic lesions of seborrheic areas. *Dermatol Venereol*. 1984;111:1081-5.
2. Mittag H, Rupec M. *Pityrosporum ovale/orbiculare* in papilomatous nevus cell nevi. *Dermatologica*. 1991;183:191-6.
3. Borenstein M, Mirzabeigi M, Vincek V. *Pityrosporum ovale* and seborrheic keratosis: An association. *Dermatol Online J*. 2005;11:3.
4. Brazdil J, Buček J, Feit J. Occurrence of *Pityrosporum ovale/orbiculare* in seborrheic keratosis and melanocytic nevus. *Scripta Medica Brno*. 2000;73:273-82.
5. Blum A. Onychomycosis with onychodystrophy or acrolentiginous melanoma with onychomycosis and onychodystrophy? *Hautarzt*. 2012;63:341-3.
6. Tseng SS, Whittier S, Miller SR, Zalar GL. Bilateral tinea nigra plantaris and tinea nigra plantaris mimicking melanoma. *Cutis*. 1999;64:265-8.
7. Hall J, Perry VE. Tinea nigra palmaris: differentiation from malignant melanoma or junctional nevi. *Cutis*. 1998;62:45-6.
8. Xavier MH, Ribeiro LH, Duarte H, Saraça G, Souza AC. Dermatoscopy in the diagnosis of tinea nigra. *Dermatol Online J*. 2008;14:15.
9. Paschoal FM, de Barros JA, de Barros DP, de Barros JC, Filho CD. Study of the dermatoscopic pattern of tinea nigra: report of 6 cases. *Skinmed*. 2010;8:319-21.