

Intermitentne klaudikacije uzrokovane velikim intramuskularnim lipomom natkoljenice

Grebić, Damir; Tomašić, Ana-Marija; Pirjavec, Aleksandra

Source / Izvornik: **Medicina Fluminensis : Medicina Fluminensis, 2016, 52, 238 - 240**

Journal article, Published version

Rad u časopisu, Objavljena verzija rada (izdavačev PDF)

Permanent link / Trajna poveznica: <https://um.nsk.hr/um:nbn:hr:184:080466>

Rights / Prava: [In copyright](#)/[Zaštićeno autorskim pravom.](#)

Download date / Datum preuzimanja: **2025-02-20**



Repository / Repozitorij:

[Repository of the University of Rijeka, Faculty of Medicine - FMRI Repository](#)



Intermittent claudication caused by a large intramuscular lipoma of the thigh

Intermitentne klaudikacije uzrokovane velikim intramuskularnim lipomom natkoljenice

Damir Grebić^{1*}, Ana-Marija Tomašić², Aleksandra Pirjavec³

¹Department of General and Oncological Surgery, Clinical Hospital Center Rijeka, Rijeka

²Clinical Hospital Center Rijeka, Rijeka

³Department of Plastic and Reconstructive Surgery, Clinical Hospital Center Rijeka, Rijeka

Abstract. Aim: To present a case of a very rare large intramuscular lipoma of the thigh with compression on blood vessels of the lower extremity. **Case report:** A 72-year-old man felt a formation on the medial side of his right thigh. From his medical history, it was found out that within the last four months he suffered from intermittent claudication. The patient did not present risk factors for atherosclerotic disease. Laboratory test results were normal. During the physical examination, a non-fixed tumour was found consuming almost the entire medial side of the thigh. An ultrasound examination indicated a soft tissue tumour, dimensions 27×20 cm. A Doppler ultrasound showed reduced flow in the popliteal artery and its branches, while the flow through the femoral artery was normal. A biopsy was performed which confirmed a mesenchymal tumour. Surgery was performed next and the tumour was extirpated from the adductor canal. During the operation it was confirmed that by its size and mass, the tumour compromised adjacent blood vessels. Pathohistological diagnosis confirmed an intramuscular lipoma. Postoperatively, the patient had no pain in the leg while walking. A follow-up Doppler ultrasound showed regular flow through the popliteal artery and its branches. **Conclusion:** This case report presented a patient with a rare, huge atypical intramuscular lipoma as a potential cause for intermittent claudication.

Key words: Doppler; intermittent claudication; lipoma; thigh

Sažetak. Cilj: Cilj je ovog rada prikazati rijedak slučaj velikog intramuskularnog lipoma natkoljenice s kompresijom velikih krvnih žila donjeg ekstremiteta. **Prikaz slučaja:** 72-godišnji muškarac palpao je čvrstu formaciju na medijalnoj strani desnog bedra. Iz anamneze se doznaje da je u posljednja četiri mjeseca patio od intermitentnih klaudikacija u desnoj potkoljenici. Pacijent nije imao faktore rizika za aterosklerotsku bolest perifernih arterija nogu. Učinjeni su laboratorijski nalazi koji su bili unutar referentnih vrijednosti. Fizikalnim pregledom otkrivena je tumorska formacija, pomična u odnosu na okolno tkivo, koja je zauzimala gotovo cijelu medijalnu stranu bedra. Ultrazvučni pregled ukazao je na tumor mekog tkiva dimenzija 27 × 20 cm. Doplerov ultrazvuk pokazao je smanjen protok u arterijama potkoljenice i njihovim granama, dok je protok kroz femoralnu arteriju bio uredan. Pacijent je potom podvrgnut citološkoj punkciji tumorske tvorbe te je time potvrđen tumor mezenhimalnog podrijetla. Nakon učinjene dijagnostike pacijent je podvrgnut operativnom zahvatu odstranjenja tumorske tvorbe. Intraoperativno se utvrdilo da tumor svojom veličinom i položajem komprimira krvne žile natkoljenice. Tumor se u cijelosti ekscirpirao iz aduktornog kanala. Patohistološkom dijagnostikom potvrđen je intramuskularni lipom. Postoperativni tijek protekao je uredno i rana je uredno cijelila. Pacijent više nije imao bolove u nozi u vidu intermitentnih klaudikacija. Kontrolni dopler ultrazvuk pokazao je uredan protok krvi kroz poplitealnu arteriju i njene ogranke. **Zaključak:** Prikazali smo rijedak slučaj pacijenta s velikim intramuskularnim lipomom te potencijalno mogućim uzrokom intermitentnih klaudikacija.

Ključne riječi: bedro; dopler; intermitentne klaudikacije; lipom

***Corresponding author:**

Damir Grebić, MD, PhD
Department of General and Oncological Surgery
Clinical Hospital Center Rijeka
Krešimirova 42, 51000 Rijeka
e-mail: damir.grebic@medri.uniri.hr

<http://hrcak.srce.hr/medicina>

INTRODUCTION

Lipomas are slow-growing benign tumours of adipose tissue with an incidence of about 10% of all diagnosed benign tumours¹. Their appearance is most common in subcutaneous adipose tissue of the head, neck, and back, while those in the extremities are infrequent. Intramuscular lipomas are extremely rare², but when they occur are most commonly located in the extremities. This type of tumour has a tendency for recurrence, therefore, total excision is the best and most effective method of treatment³. A vital step in diagnosis is to distinguish a lipoma from a well-differentiated liposarcoma⁴. An ultrasound-guided biopsy is a helpful and inexpensive diagnostic technique and it is usually sufficient to confirm the diagnosis¹.

This case report presents a patient with a rare, huge atypical intramuscular lipoma as a potential cause for intermittent claudication.

CASE REPORT

A 72-year-old man felt a formation on the medial side of his right thigh. From his medical history, it was found out that within the last four months the patient had pain while walking in the shin and walking was not possible for extended periods of time without pain. The pain was classified as intermittent claudication. The patient did not present risk factors that would indicate peripheral atherosclerotic occlusive disease of the arteries that could lead to these symptoms. Laboratory tests including serum levels of cholesterol and triglycerides were within reference ranges. The patient did not suffer from hypertension, diabetes mellitus, or heart disease, and the patient was a non-smoker.

During the physical examination, a non-fixed tumour was discovered covering almost the entire medial side of the thigh. An ultrasound examination indicated a soft tissue tumour, dimensions 27×20 cm. Additionally, a Doppler ultrasound showed reduced blood flow in the popliteal artery and its branches, the anterior and posterior tibial artery, while the flow through the femoral artery in the groin was normal. An ultrasound-guided biopsy was performed. Cytology con-

firmed a mesenchymal tumour with atypical cells. Surgery was performed next in which the tumour was extirpated from the adductor canal (Figure 1). During the operation it was confirmed that by its size and mass, the tumour compromised adjacent blood vessels. The dimensions of the tumour, according to pathological findings, were 27×20×9 cm (Figure 2). The pathohistological diagnosis confirmed an intramuscular lipoma with atypical cells.

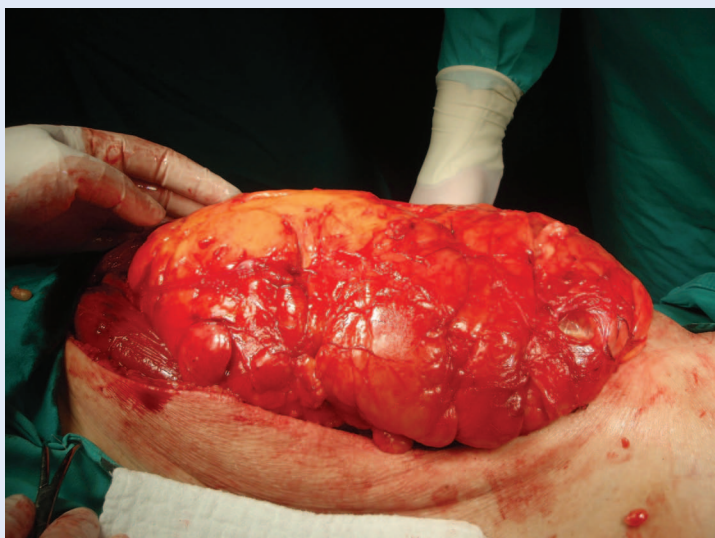

Figure 1. Huge lipoma of the thigh. Intraoperative photography.

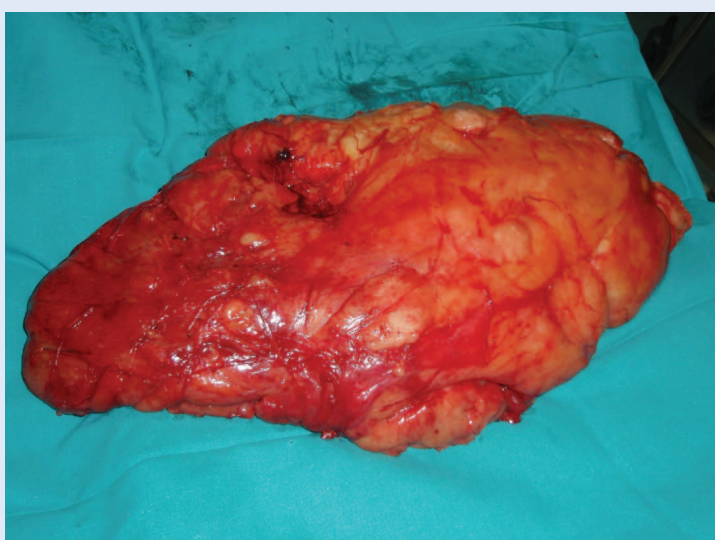


Figure 2. Extirpated lipoma of the thigh. A gigantic tumorous mass is seen which was situated in the adductor canal and pressed on the adjacent structures, namely blood vessels. The dimensions of the tumour are 27×20×9 cm.

There were no postoperative complications. The wound healed by primary intention (*per primam*). The patient was discharged on the fourth and the sutures were extracted on the tenth postoperative day. A follow-up Doppler ultrasound showed normal blood flow through the popliteal artery and its distal branches. Likewise, the patient no longer felt pain in the form of intermittent claudication while walking.

This report presents a rare patient with a huge intramuscular lipoma in the adductor canal of the right thigh, causing compression of large blood vessels, which clinically manifested as intermittent claudication. Reduced arterial blood flow caused by the “mass” effect of the tumour was diagnosed using Doppler ultrasound. Pathohistological analysis confirmed an atypical lipoma.

DISCUSSION

Intramuscular lipomas are rare benign tumours whose clinical presentation may mimic liposarcoma. Lipomas tend to infiltrate local tissue, as is the case with malignant variants. Therefore, without a confirmed pathohistological diagnosis, an intramuscular lipoma must be treated as its malignant variant^{2,3}, especially if cytological findings show atypical cells as was found in this case. Therefore, extirpation of the tumour and a pathohistological exam must be performed to confirm or exclude malignancy. Considering the fact that our patient did not present risk factors for atherosclerosis, it was concluded that the tumour, by its size, compressed circulation while walking causing intermittent claudication. During the operation, the large tumorous mass was visualised consuming the adductor canal of the thigh near vascular structures, pressing against them. To prove the tumour compromised blood vessels and reduced blood flow, preoperative and

postoperative Doppler ultrasounds were performed and compared. The preoperative Doppler ultrasound showed reduced flow without signs of atherosclerotic plaques, the postoperative Doppler ultrasound showed the popliteal artery and all of its branches had regular blood flow. Anamnesis also confirmed these findings. Postoperatively, the patient's circulation rapidly improved and pain was no longer present in the leg while walking. To our knowledge, there has only been one reported case to date where a lipoma compromised circulation⁵.

CONCLUSION

With the appearance of intermittent claudication, especially in elderly patients, it is important to exclude peripheral atherosclerotic disease considering it is the most common cause of intermittent claudication. In our patient, peripheral arterial disease, despite being common, was not the cause of these symptoms. Based on all the facts, it was concluded that the lipoma, based on its location, size, and mass, compromised circulation in the thigh, causing the described symptoms which were resolved after surgery.

Conflicts of interest statement: The authors report no conflicts of interest.

REFERENCES

1. Vandeweyer E, Scagnol I. Axillary giant lipoma: a case report. *Acta Chir Belg* 2005;105:656-7.
2. Per Bjerregaard, Hagen K, Daugaard S, Kofoed H. Intramuscular lipoma of the lower limb. Long-term follow-up after local resection. *J Bone Joint Surg* 1989;71:812-5.
3. Su CH, Hung JK, Chang IL. Surgical treatment of intramuscular, infiltrating lipoma. *Int Surg* 2011;96:56-9.
4. Rydholm A, Berg NO. Size, site and clinical incidence of the lipoma. Factors in the differential diagnosis of lipoma and sarcoma. *Acta Orthop Scand* 1983;54:929-34.
5. Garrido-Gomez J, Vizoso-Perez ML, Linares-Palomino JP, Arrabal-Polo MA, Cardenas-Grande E. Intermittent claudication caused by a gigant atypical lipoma of the thigh. *J Vasc Surg* 2012;56:808-11.