

Significance of Mini Radial Endoscope Ultrasound (MREUS) in Diagnosis and Therapy of Colorectal Neoplasia

Ivaniš, Nikola; Grubešić, Aron; Šoša, Ivan; Ivaniš, Viktor; Šuke, Ramadan; Kovačević, Miljenko

Source / Izvornik: *Collegium antropologicum*, 2012, 36, 873 - 877

Journal article, Published version

Rad u časopisu, Objavljena verzija rada (izdavačev PDF)

Permanent link / Trajna poveznica: <https://urn.nsk.hr/urn:nbn:hr:184:824394>

Rights / Prava: [In copyright](#) / [Zaštićeno autorskim pravom](#).

Download date / Datum preuzimanja: **2024-07-13**



Repository / Repozitorij:

[Repository of the University of Rijeka, Faculty of Medicine - FMRI Repository](#)



Significance of Mini Radial Endoscope Ultrasound (MREUS) in Diagnosis and Therapy of Colorectal Neoplasia

Nikola Ivaniš¹, Aron Grubešić², Ivan Šoša³, Viktor Ivaniš⁴, Ramadan Šuke¹ and Miljenko Kovačević⁵

¹ »Ivaniš« Polyclinic, Rijeka, Croatia

² Rijeka Institution for Emergency Medicine, Rijeka, Croatia

³ University of Rijeka, School of Medicine, Department of Forensic Medicine and Criminalistics, Rijeka, Croatia

⁴ Thalassotherapia Hospital, Clinic for Cardiovascular Disease Treatment, Prevention and Rehabilitation, Opatija, Croatia

⁵ University of Rijeka, Rijeka University Hospital Center, Department of Surgery, Rijeka, Croatia

ABSTRACT

In the pursuit to advance diagnostic procedures with colon carcinoma patients, we included the 15 MHz mini radial endoscopic ultrasound (MREUS) in our work up algorithm, following PH verification. When compared to surgical and final pathohistological (PH) findings, MREUS shows that it can differentiate colon layers in great detail and therefore we can determine the degree of carcinoma dissemination (T1, T2, T3, T4) as well as to make a correct therapeutic choice. MREUS (12–15–20 MHz) is a highly reliable colon layer structural analysis method. As we have shown in our study, the accuracy of T stage colon carcinoma visualization in correlation to equivalent PH studies varies from 90–100% which makes MREUS the best as well as the most reliable method in determining preoperative T stage colon carcinoma.

Key words: MREUS, colon layers, pathologistological studies

Introduction

Tumors of the colon are a heterogeneous group of neoplasm that are, as most others, classified into benign and malign. Benign tumors, in the form of polyps, are the most common tumors found in general. During their early forming they are tubular, villous or tubo-vilous, and it is only in the following ten year that they usually transform into malignant form¹. The extent of the malignancy can be determined by a pathoistological examination where various degrees of atypical citoarchitecture are commonly found. All benign collon tumors are verified endoscopically and through a pathoistological examination. The advancement of endoscopy as a technique made structural analysis and visualization as well as mini-probe radial ultrasound (MRS 12–15–20 MHz) possible. MRS is excellent at visualization of different layers of colon, in-between which most tumors are found. This is of great significance to patient outcome, especially if the tumor can be safely extracted through endoscopic electro-diathermic polypectomy (EEP)². Adenocarcinoma is the most common malignant tumor of the colon. It is,

almost always, formed through malignant alteration of a benign polyp – adenoma. Colorectal carcinoma's (CRC) incidence is in second place among the most common malignant colon tumors³. After a diagnosis of CRC had been established, determining the degree of distribution is of critical importance when considering an appropriate treatment option. Other rare malignancies of the colon include leyomiosarcoma, fibrosarcoma, lymphoma, neurosarcoma, angiosarcoma, malignant schwannoma as well as carcinoids⁴. Treatment method of choice is usually imposed by disease distribution. We stress the inviolability of using endoscopic ultrasound as a method in early disease discovery. Our aim is to discover as many T1(m) pathohistological stage carcinomas through the use of this method. Also a T1(m) and T1(sm) submucose carcinoma can still be removed by endoscopy (endoscopic electro-diathermic polypectomy – EEP, endoscopic mucose resection – MR or endoscopic submucose dissection – KR)⁵.

Stages of colorectal carcinoma distribution are: T1m – Ca reaches mucose layer, T1sm – Ca reaches submucose layer, T2 – Ca reaches muscularis propria layer, T3 – Ca reaches subserose and serose layers, T4 – Ca reaches fat tissue and colon surrounding structures⁶ (Figure 1).

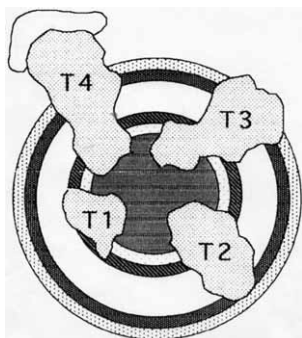


Fig 1. Visualization of colorectal carcinoma dissemination (MREUS stage T1, T2, T3, T4).

Patients and Methods

We present 35 patients (19 male and 16 female), examined in a 2 year mini-study (January 2009–January 2011), with an endoscopy finding of neoplasia and colon carcinoma verified through a pathohistological (PH) exam. All patients were processed in Polyclinic »Ivaniš« in Rijeka. Patients reported to the clinic due to non-specific symptoms, such as abdominal pain, change in stool frequency/form (diarrhea/constipation) and stool blood occurrence in the form of haematochezia or black and tarry stool – »melena«. Only a small number of patients had presented with abdominal pain (N=2) or false urge cramping (N=1).

All patients were subjected to a detailed clinical examination that included proctoscopy and colonoscopy, determining carcinoembryonic antigen values as well as thorax, bowel and abdomen computerized tomography. Endoscopy ultrasound was performed preoperatively with the use of the following equipment: MRS PL-2317B probe Pentax EC3840K colonoscope with Fujinon radial module and Hitachi EUB 8500 ultrasound support.

Mini radial probe visualizes 5 layers: mucose (hiperecho), lamina muscularis mucosae (hipoecho), submucose (hiperecho), lamina muscularis propria (hipoecho), subserose/serose (hiperecho)⁷ (Figure 2).




Fig 2. Visualization of 5 colon layers shown by MREUS.

In order to be accepted into the study patients had to be under 76 years of age and had to show no localization of lesions 11cm oral to muco-cutaneous border. All patients that had a proven dissemination of disease to local or distant nodes were removed from the study and were not taken into consideration for endoscopic treatment.

Statistical analysis

Statistical significance was set at $p=0.05$. The statistical analysis was done by SAS statistical software (rel. 8.02; SAS Institute, Cary, NC).

Ethical considerations and conflict of interest

Authors declare that they have no competing interests As well, this study was in accordance with the ethi-

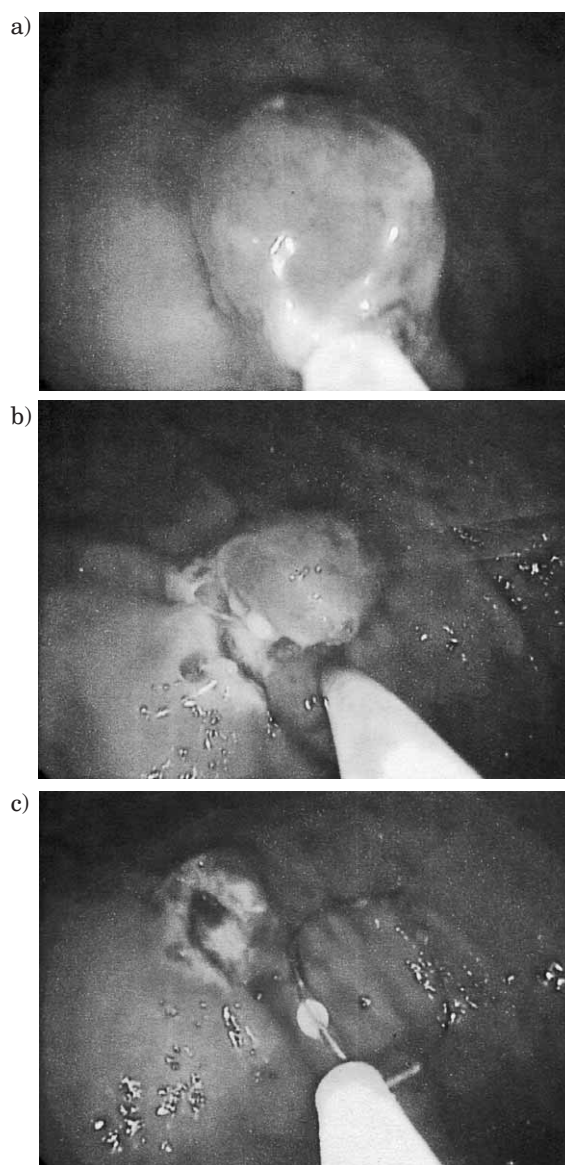


Fig 3. Visualization of endoscopic mucosal resection procedure (EMR). A: small carcinoma enveloped with an endoscopic instrument; B: extraction of the small carcinoma; C: extraction point.

cal standards of the responsible committee on human experimentation (institutional and national) and with the Helsinki Declaration of 1975, as revised in 2008.

Endoscopic therapeutic procedures were conducted for liable patients as shown in Figure 3a–c.

Following the therapeutic procedure, surgical findings as well as final pathohistological exam were once again reviewed and stage of dissemination was defined and results show in tables. Comparing MREUS T stage with the surgical finding and final PH exam gives us an objective picture of the value of preoperative MREUS colon carcinoma exam and the credibility behind MREUS T stage carcinoma determination.

Results

Basic demographics, MREUS findings and T stage carcinoma dissemination for all 35 patients are shown in Table 1. Endoscopy exam determined T1N0 pathohistological stage equivalent macroscopical lesions in seven patients. Six patients were determined to be within the endoscopy treatment criteria and one was, due to inaccessibility, treated surgically. Remaining 28 non-T1N0 patients were treated surgically as preoperative examination determined that they do not fulfill endoscopic treatment criteria. (Table 1, 2 and 3, Figure 4.)

TABLE 1
MREUS T AND N STAGES IN THE ANALYSED GROUP OF 35 CRC PATIENTS

T stage	Number	N-stage
T1	7	7N ₀
T2	13	7N ₀ i 6N ₁
T3	10	2N ₀ i 8 N ₁
T4	5	5N ₁

TABLE 2
RESULTS FOR REMOVED CRC IN PATIENTS WITH MREUS T1 STAGE

TN stadij	BROJ	Terapijski postupak	Završni PH stadij
T1N ₀	7	6EMR i 1CR	7T1

TABLE 3
RESULTS FOR SURGICALLY TREATED PATIENTS WITH ADVANCED CRC (MREUS STAGE T2, T3 AND T4)

TN stadij	Kirurški (završni) PH stadij
7 T2N ₀	5 T2N ₀ and 2T2N ₁
6 T2N ₁	5T2N ₁ and 1T3N ₁
2 T3N ₀	1T3N ₀ and 1T3N ₁
8 T3N ₁	7T3N ₁ and 1T4N ₁
5 T4N ₁	5T4N ₁



Fig 4. MREUS – Stages T1, T2, i T3 of Colorectal carcinoma.

Discussion

Colon cancer usually develops out of so called premalignant lesions (polyps, adenomas) which are benign forms, that usually take up to 15 years to be transformed into a malignancy. In fact, this long term process gives us enough time for early discovery and extraction of these non-symptomatic premalignant lesions which will otherwise probably lead to cancer. A polyp is a benign growth that is formed out of the mucosal colon layer and arches into the colon lumen creating a macroscopically visible mass in the process. A polyp can be found anywhere between esophagus and anus. Colon polyps represent a particular problem, they manifest sporadically or as a part of intestinal polyposis syndrome.

Early colon carcinoma discovery is the aim of modern gastroenterological diagnostics. Techniques' needed to discover and PH verify carcinomas as well as to determine dissemination stage exist today and are available to most physicians. 5-year survival of early T1 stage colon carcinoma is more than 90%, which is both promising and stimulating in the effort to discover early colon carcinomas⁸. Also, Croatian national program of prevention and early detection of colorectal cancer is committed to the same goal.

MREUS had determined T1 stage in 7 out of 35 examined patients. Surgical and PH findings concluded T1 stage in all seven patients, which shows great correlation though barring in mind a small patient group. T1 stage results (as well as T2, T3 and T4) show a significant contribution of MREUS as a choice for endoscopic therapy in early stage colon carcinoma patients which suggests the need to implement MREUS in colorectal patient diagnostic algorithm.

Understaging is a phrase commonly found in papers describing MREUS. A certain understaging reflects in MREUS N stage determination (lymph nodes) which was not the subject of this study⁹. In our analysis MREUS has also shown a high specificity for patients with T2, T3 and T4 stages, but in a small amount of patients we determined a lower MREUS stage when compared to final PH assessment. Out of 28 developed carcinoma patients operated on we found two that had higher grade T stage (one MREUS T2 was actually PH T3 and one MREUS T3 was actually PH T4)¹⁰.

Specificity of T stage MREUS results vary in different papers but show great promise as they correlate from 90 to 96 % to PH stage findings¹¹. The distribution of differ-

ent age groups does not show a statistical significance although vertical shifting inside the age groups indicates an advantage that the use of MREUS represents when considering early colon carcinoma discovery.

Endoscopy (Sigmoidoscopy – lower colon examination and colonoscopy – entire colon examination) is usually performed when patients present with problems or symptoms that indicate colon disease.

When local staging is indicated (approximation of the level of colon layer and lymph node invasion), endoscopic ultrasound is more useful than a CT scan.

Recognizing the depth of the invasion and the state of lymph nodes is necessary to effectively plan therapy. Patients have various treatment options at their disposal, some are standard (in current use) but new ideas and approaches are being tested in clinical research¹². Today, T1 stage carcinomas are mostly treated endoscopically but in cases of inaccessibility need to be surgically removed.

Conclusions

In polyclinic »Ivaniš«, we are using a new technique in early colon carcinoma discovery which represents a highly reliable method for colon layer structure analysis. Mini radial ultrasound (MREUS) equipped with a mini radial probe of 12–15–20 MHz has proven to be a great asset, expanding everyday diagnosis and treatment options.

As we have shown in our study, the accuracy of T stage colon carcinoma visualization in correlation to equivalent PH studies varies from 90–100% which makes MREUS the best as well as the most reliable method in determining preoperative T stage colon carcinoma.

REFERENCES

1. KUJUNDŽIĆ M, BANIĆ M, BOUN T, MEDIX, 82 (2009) 35. — 2. HURLSTONE DP, BROWN S, CROSS SS, SHORTHOUSE AJ, SANDERS DS, *Endoscopy*, 37 (2005) 710, DOI: 10.1055/s-2005-870142. — 3. American Joint Committee on Cancer, *AJCC Cancer Staging Manual*, 6th edition Springer (2002). — 4. Hrvatski zavod za javno zdravstvo, *Incidencija raka u Hrvatskoj. Bilten br. 30* (2005). — 5. MURATA Y, OGUMA H, KITAMURA Y, IDE H, SUZUKI S, TAKASAKI T, *Nihon Geka Gakkai Zasshi*, 9 (1998) 564. — 6. LIMBERG B, Springer – Verlag, (1998) 93. — 7. FRANK N, HOLZAPFEL P, WENK A, *Endoskopie Heute*, 3 (1994) 238–244. — 8. STERGIU N, HAJI-KERMANI N, SCHNEIDER C, MENKE

D, KÖCKERLING F, WEHRMANN T, *Int J Colorectal Dis*, 18 (2003) 450, DOI: 10.1007/s00384-003-0506-Z. — 9. KALAITZAKIS E, SADIK R, DOIG L, MEENAN J, *Dis Esophagus*, 22 (2009) 409, DOI: 10.1111/j.1442-2050.2008.00900.X. — 10. DE ANGELIS CG, *Endoscopy*, 37 (2005) 281. — 11. HURLSTONE DP, CROSS SS, SANDERS DS, *Clin Gastroenterol*, 39 (2005) 596, DOI:10.1097/01.mcg.0000170740.82004.39. — 12. HAN JP, HONG SJ, MOON JH, LEE GH, BYUN JM, KIM HJ, CHOI HJ, KO BM, LEE MS, *Gastrointest Endosc*, 74 (2011) 1230, DOI:10.1016/j.gie.2011.07.044.

A. Grubešić

Branka Blečića BB, 51000 Rijeka, Croatia
e-mail: agrubestic@gmail.com

ZNAČAJ MINI RADIJALNOG ENDOSKOPSKOG ULTRAZVUKA (MREUZ) U DIJAGNOSTICI I TERAPIJI KOLOREKTALNIH NEOPLAZIJA

S A Ž E T A K

Težeći stalnom unapređenju dijagnostičkog postupka pri obradi bolesnika sa karcinomom debelog crijeva, kao i stalnoj racionalizaciji algoritma pretraga uključen je mini radijalni endoskopski ultrazvuk (MREUZ) od 15 MHz u postupak obrade, a nakon PH verificiranja karcinoma. Rezultati MREUZ-a uspoređeni sa kirurškim i završnim PH nalazom pokazuju da mini endosonografski možemo izvrsno determinirati slojeve stijenke kolona i tako odrediti stupanj raširenosti karcinoma (T1, T2, T3, T4) te napraviti pravilan izbor terapije. Mini radijalni endoskopski ultrazvuk (12–15–20 MHz) je visoko pouzdana metoda za analizu strukture stijenke debelog crijeva. Točnost prikaza T stadija karcinoma debelog crijeva iznose između 90 i 100% (u ispitanoj seriji 100%) te je mini radijalni endoskopski ultrazvuk danas najbolja i najpouzdanija metoda određivanja prijeternog T stadija karcinoma debelog crijeva.