

Transitory bone marrow oedema of the hip in pregnant patient with antiphospholipid syndrome: A case report

Šimac, Daniel Victor; Veljković Vujaklija, Danijela; Mirić, Filip; Novak, Srđan

Source / Izvornik: **The Egyptian Rheumatologist**, 2021, 43, 209 - 212

Journal article, Published version

Rad u časopisu, Objavljena verzija rada (izdavačev PDF)

<https://doi.org/10.1016/j.ejr.2021.02.001>

Permanent link / Trajna poveznica: <https://um.nsk.hr/um:nbn:hr:184:835708>

Rights / Prava: [Attribution-NonCommercial-NoDerivatives 4.0 International/Imenovanje-Nekomercijalno-Bez prerada 4.0 međunarodna](#)

Download date / Datum preuzimanja: **2024-11-25**



Repository / Repozitorij:

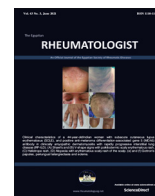
[Repository of the University of Rijeka, Faculty of Medicine - FMRI Repository](#)





Contents lists available at ScienceDirect

The Egyptian Rheumatologist

journal homepage: www.elsevier.com/locate/ejr

Case reports

Transitory bone marrow oedema of the hip in pregnant patient with antiphospholipid syndrome: A case report

Daniel Victor Šimac^{a,*}, Danijela Veljković Vujaklija^b, Filip Mirić^a, Srđan Novak^a^a Department of Rheumatology and Clinical Immunology, Clinical Hospital Center Rijeka, Croatia^b Department of Radiology, Clinical Hospital Center Rijeka, Croatia

ARTICLE INFO

Article history:

Received 3 February 2021

Accepted 3 February 2021

Available online 9 March 2021

Keywords:

Transient bone marrow oedema of the hip
 Bone marrow oedema syndrome
 Antiphospholipid syndrome
 Pregnancy

ABSTRACT

Background: Transient bone marrow oedema (BMO) of the hip presents with pain, is diagnosed by magnetic resonance imaging (MRI), and usually resolves within 6 months. Risk factors include pregnancy. Avascular necrosis of bone and an association with BMO are among the less common presentations of antiphospholipid syndrome (APS).

Aim of the work: To present a young Croatian female APS patient who developed transient BMO during pregnancy which spontaneously resolved postpartum.

Case report: After developing left leg deep vein thrombosis and positive lupus anticoagulant at 22 years old, the patient was diagnosed with primary APS. Antinuclear antibody was borderline, but classification criteria for SLE were not fulfilled. She had an early missed abortion during her first pregnancy while receiving low-weight molecular heparin (LWMH) (enoxaparin 40 mg), and her second pregnancy was to term with LWMH, aspirin, and hydroxychloroquine 200 mg daily. During the third trimester of this pregnancy, she developed excruciating bilateral hip pain to the point she could barely walk. Based on an MRI scan, the patient was diagnosed with bilateral BMO of the femoral head. The condition improved and resolved within four months with conservative treatment postpartum, as confirmed by followup MRI.

Conclusion: Considering that pregnancy and APS are risk factors for BMO, both played a role in the development of BMO and the severity of presentation. This case report presents a differential diagnosis of hip pain in pregnant patients, especially with APS. Although APS is commonly associated with AVN, it may also be associated with transient BMO.

© 2021 Egyptian Society of Rheumatic Diseases. Publishing services provided by Elsevier B.V. This is an open access article under the CC BY-NC-ND license (<http://creativecommons.org/licenses/by-nc-nd/4.0/>).

1. Introduction

Bone marrow oedema (BMO) or BMO syndrome of the hip or femoral head is a term used in radiology to describe a non-specific lesion pattern seen by magnetic resonance imaging (MRI) “characterised by altered marrow signal intensity within the femoral head suggestive of medullary infiltration by interstitial edema”. It can be primary, known as transient BMO, or secondary to osteoarthritis, trauma, stress fracture, or osteonecrosis [1]. Transient BMO is idiopathic, painful, uni- or bilateral, considered benign, slightly more common in men, and self-limiting, usually resolving within 6 months [2]. It is this combination of joint pain

and distinctive MRI changes that characterises primary or transient BMO syndrome [3].

According to Van de Berg et al., four criteria must be fulfilled on T1-weighted images for BMO syndrome of the hip: femoral head must be involved, the lesion has no definite margins, and its signal is homogenous, while signal intensity is reduced on T1-weighted SE images. Signal intensity is intermediate to high on T2-weighted images and short tau inversion recovery (STIR) images [1]. Such bone marrow lesions (BMLs) are localised oedema within subchondral bone, often as a result of subchondral insufficiency stress, or microfractures, early chondromalacia changes, and/or avascular necrosis (AVN) [4].

Additional changes in the articular cartilage, subchondral bone plate and marrow, such as deformity or fracture, and a crescent-shaped low signal intensity in the subchondral area, are indicative of irreversible changes associated with osteonecrosis or possibly stress fractures. Some subchondral MRI findings, such as lines or spots, can be misinterpreted as initial or possible AVN, making

Peer review under responsibility of Egyptian Society of Rheumatic Diseases.

* Corresponding author at: Department of Rheumatology and Clinical Immunology, Clinical Hospital Center Rijeka, Tome Strižića 3, 51000 Rijeka, Croatia.

E-mail address: danielsimac@hotmail.com (D.V. Šimac).

<https://doi.org/10.1016/j.ejr.2021.02.001>

1110-1164/© 2021 Egyptian Society of Rheumatic Diseases. Publishing services provided by Elsevier B.V.

This is an open access article under the CC BY-NC-ND license (<http://creativecommons.org/licenses/by-nc-nd/4.0/>).

the diagnosis of transient BMO challenging [5]. In unclear cases, follow-up MRI at 3 months is justified [1]. Transient BMO and early AVN are clinically and radiologically similar, and the distinction between the two is difficult. It is important to keep this in mind as transient BMO is benign and self-limiting, while AVN can progress making surgical reconstruction necessary [2].

Risk factors include pregnancy, usually seen in the last trimester of pregnancy due to mechanical overload and metabolic changes, as the most common, as well as alcohol, glucocorticoid use, smoking, and hypothyroidism [2]. Generally, transient BMO is associated with various diseases, this finding is usually non-specific, still, in some cases, considering BMO existence or pattern, the differential diagnoses can be narrowed, or a specific diagnosis can be made. This is why understanding pathophysiology is crucial for clinicians and radiologists alike to avoid diagnostic pitfalls [6]. However, pathophysiology is unclear, triggers such as trauma, infection, ischemia, drugs, and others are believed to cause oedema as a result of increased bone turnover, microfracture, and venous hypertension [2]. This makes combining such imaging patterns with history, clinical findings, and laboratory results vital for accurate diagnosis [6]. Transient BMO does not usually result in hip fracture, AVN or bone marrow necrosis (BMN). Treatment is conservative and includes rest, minimising weight-bearing activities and analgesics; some studies have shown bisphosphonate, calcitonin, and teriparatide to be effective, while support is weak for core decompression [2–4].

Antiphospholipid syndrome (APS) is a condition characterised by arterial and/or venous thromboses, recurrent miscarriage, along with positive antiphospholipid antibodies (aPL): lupus anticoagulant (LAC), anticardiolipin (aCL) or anti- β_2 glycoprotein-I (a β_2 GPI) antibodies [7,8]. It can be primary or secondary, usually to systemic lupus erythematosus (SLE) or other autoimmune diseases, infection, medication, or malignancy [7]. In pregnancy, placental insufficiency as a result of inflammation due to coagulation by-products as well as thrombi formation lead to miscarriage or preeclampsia [7,8]. Between 20 and 30% of the placenta can be affected in APS [9]. Treatment includes thromboprophylaxis with vitamin K antagonists, although aspirin may be sufficient in some cases [7]. Immunosuppression, with glucocorticoids or hydroxychloroquine (HCQ), is namely reserved for secondary APS [7]. Low molecular weight heparin (LMWH) or unfractionated heparin (UF) are used in pregnancy as oral anticoagulants are teratogenic. Aspirin has been shown to be beneficial in pregnancy, with a success rate of 70–80% [7,8].

Less common presentations include premature birth and preeclampsia [10]. The incidence of AVN in primary APS has been reported at 0.9–20%, [11]. Transient BMO was described in a case control study by Tektonidou *et al.* who reported finding BMO on MRI without necrosis in 13% (4/30) of primary APS patients and as far as we know, seems to be the only one to effectively show an association between APS, and AVN and transient BMO [12].

To add to this growing literature, a case of a young Croatian female APS patient who developed transient BMO during pregnancy which spontaneously resolved postpartum is presented. The study was approved by the ethics committee of Clinical Hospital Center Rijeka, and was carried out in accordance with the principles of the Declaration of Helsinki. Informed consent was obtained from the patient.

2. Case report

At 22 years old, the patient developed left leg deep vein thrombosis (DVT) and was put on warfarin. She took it on a regular basis and was regularly followed by a vascular surgeon. Later she was referred to a rheumatologist due to positive thrombophilia workup with positive LAC, highest noted value at 1.93 units, and the diagnosis of primary APS was made. Over the years she was followed and did not develop any recurrent thrombosis, while LAC remained positive. Later, antinuclear antibody (ANA) was borderline at titre 1:100, and aCL (IgM 35.9 U/mL and IgG 5.6 U/mL) and a β_2 GPI (IgM > 200 RU/mL, IgG 7.57 RU/mL) became elevated. Mild thrombocytopenia was also noted. The classification criteria for SLE were not fulfilled.

At the age of 33, the patient began to plan for pregnancy, and the same year became pregnant. As planned, she was switched from warfarin to LMWH (enoxaparin 40 mg or 4000 IU). Unfortunately, at 8 weeks, she had a missed abortion. During the next follow-up, she was started on HCQ 200 mg daily. The following year she became pregnant again, continued HCQ 200 mg, started aspirin 100 mg daily, and received enoxaparin 40 mg. The first two trimesters were uneventful, except for minor gestational diabetes. At 34 weeks, she first complained of hip pain which spread to the inguinal regions and back. A couple of weeks later the patient was hospitalised due to progression of pain and difficulty walking requiring crutches. A healthy male infant was delivered by a Cesarean section. Included in the further pain workup a rheumatologist was consulted and hip MRI was recommended for possible AVN. The radiologist described low signal areas on T1-weighted images and high signal areas on fat suppression or

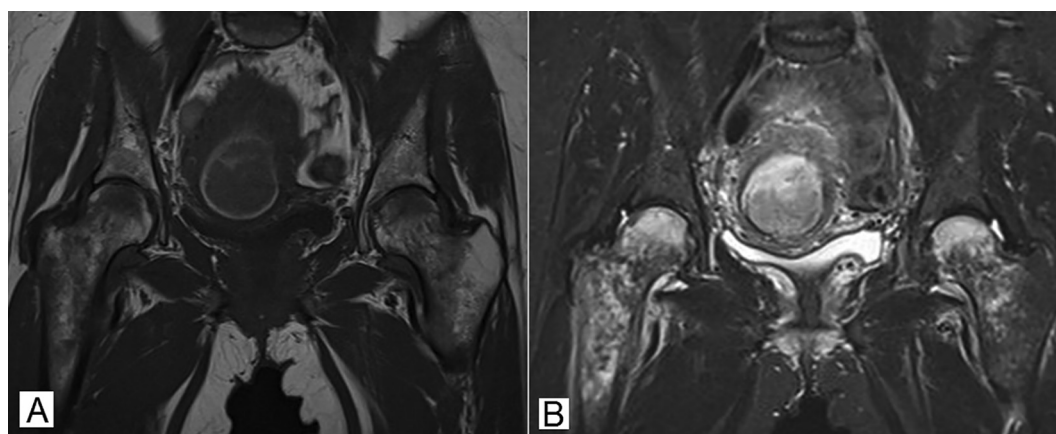


Fig. 1. Magnetic resonance imaging (MRI) of pelvis, baseline scan. Findings in line with bone marrow oedema (BMO). A. Coronal T1-weighted image, areas of low signal intensity involving the head, neck, and intertrochanteric regions of both femurs are seen, more pronounced on the right; B. Short tau inversion recovery (STIR) image, areas of high signal intensity corresponding to the areas of low signal intensity as shown in A.

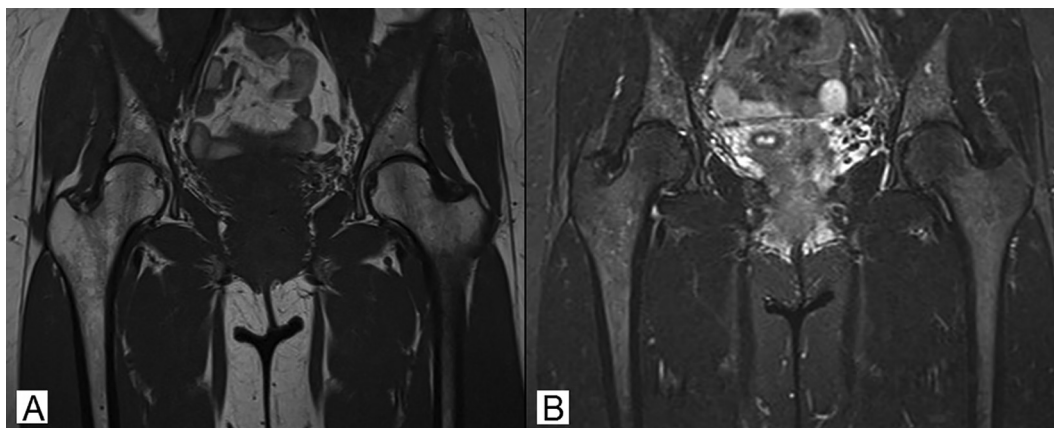


Fig. 2. Magnetic resonance imaging (MRI) of pelvis, follow-up at four months. A. Coronal T1-weighted image; B. Short tau inversion recovery (STIR) image, complete regression of earlier changes.

STIR images in the head, neck and intertrochanteric regions of the femurs, more pronounced on the right, and mild inhomogenous signal increase post contrast (Fig. 1). Mild oedema of adjacent soft tissue and minor joint effusion were noted. Signs of bone infarction or AVN were not found, and the radiologist suggested transient BMO. Upon discharge, the patient noted improvement. HCQ was continued, later reduced to 200 mg every other day. Oral anticoagulant prophylaxis was reintroduced, apixaban 5 mg twice daily instead of warfarin. Followup MRI was done four months later showing complete regression of BMO thus confirming the diagnosis (Fig. 2). As a point of interest, histopathology of the placenta reported subacute and chronic lobe infarctions, fibrous changes, and calcifications.

It is noteworthy that the patient has iatrogenic hypothyroidism (right lobectomy was performed for a cold nodule 7 years ago) and lymphocytic thyroiditis (confirmed by histopathology) on replacement therapy with levothyroxine, regularly followed by a nuclear medicine specialist. No other significant comorbidities or earlier history is noted.

3. Discussion

There is only one study [12] that presented an association between APS and BMO. However, many others link APS to AVN or BMN [13–16]. Looking at the patient, the question remains, was the bilateral BMO of the hip and her associated symptoms a result of primary APS, pregnancy, or a combination? On one hand, it is established that pregnancy is a risk factor for developing transient BMO [2]. Indeed, Tektonidou et al. [12] excluded pregnant patients from their study, likely due to this link. Considering the fact that the patient developed BMO during the third trimester of pregnancy which spontaneously resolved postpartum, it could be argued the transient BMO in the patient was simply a complication of pregnancy, and not APS. On the other hand, APS is not completely understood, and along with its usual DVT and embolism or recurrent foetal loss manifestations, can have several rarer manifestations, including transient BMO and AVN, as suggested in various reports [12–16]. With ischemia as a possible trigger for BMO [2], and thromboses at the core of most APS manifestations [7], the connection between the two is not difficult to make. With the patient having primary APS and developing transient BMO, it could be argued that the two are related. Of course, we do not have insight into whether the patient developed a form of asymptomatic transient BMO earlier, nor did the patient see late pregnancy earlier, which could have led to symptomatic transient BMO, and as such we cannot apply this information to the current case. It

is important to note, as the MRI did not show additional signs indicative of AVN, transient BMO was considered the most likely diagnosis. The patient's condition improved, which also fits the diagnosis, but as it can be difficult to distinguish transient BMO and AVN, follow-up MRI was performed which showed complete regression, confirming the diagnosis.

Looking at the report for the histopathology analysis of the placenta of the patient, subacute and chronic lobe infarctions along with fibrous changes and placental insufficiency were described [17]. As insight into the percentage of placenta affected in the patient is lacking, it cannot be concluded if the changes fall within normal pregnancy or APS. The placenta was affected likely as a result of APS and this could be extrapolated to provide another argument for transient BMO as a result of APS in this patient.

Taking all of this into consideration, a definite answer to the initial question on the cause of transient BMO in the patient (APS or pregnancy), cannot be made. Both scenarios are possible, but considering that both APS and pregnancy are known risk factors for transient BMO, it could be concluded that both, increasing the overall risk, and possibly complementing one another, lead to the development of transient BMO. This assumption would explain the severity of the hip pain in the patient.

In conclusion, this is an isolated case report, which admittedly can only suggest an association between APS, pregnancy, and transient BMO. Further studies testing the presence of BMO in pregnant APS patients in comparison to healthy pregnant patients could provide more of a definite answer. This report sheds light on this unique, albeit rare, association. It is recommended that a pregnant APS patient presenting with bilateral hip pain should have further workup done for BMO or AVN considering the presence of two risk factors. While transient BMO is usually self-limiting, AVN is not, and may require further treatment.

Funding

This research did not receive any specific grant from funding agencies in the public, commercial, or not-for-profit sectors.

Declaration of Competing Interest

The authors declare that they have no known competing financial interests or personal relationships that could have appeared to influence the work reported in this paper.

References

- [1] Vande Berg BC, Lecouvet FE, Koutaissoff S, Simoni P, Malghem J. Bone marrow edema of the femoral head and transient osteoporosis of the hip. *Eur J Radiol* 2008;67(1):68–77.
- [2] Asadi-pooya K, Graves L, Greene LW. Transient osteoporosis of the hip: Review of the literature. *Osteoporos Int* 2017;28(6):1805–16.
- [3] Flores-Robles BJ, Sanz-Sanz J, Sanabria-Sanchinel AA, Huntley-Pascual D, Andréu Sánchez JL, Campos Esteban J, et al. Zoledronic acid treatment in primary bone marrow edema Syndrome. *J Pain Palliat Care Pharmacother*. 2017;31(1):52–6.
- [4] Kapil N, Samuel LT, Kamath AF. Management of bone marrow lesions of the hip with subchondral calcium phosphate injection: Surgical technique and tips. *Arthrosc Tech* 2020;9(7):e863–75.
- [5] Geith T, Stellwag A-C, Muller PE, Reiser M, Baur-Melnyk A. Is bone marrow edema syndrome a precursor of hip or knee osteonecrosis? Results of 49 patients and review of the literature. *Diagn Interv Radiol*. 2020;26(4):355–62.
- [6] Klontzas ME, Zibis AH, Vassalou EE, Karantanas AH. MRI of the hip: current concepts on bone marrow oedema. *Hip Int* 2017;27(4):329–35.
- [7] Negrini S, Pappalardo F, Murdaca G, Indiveri F, Puppo F. The antiphospholipid syndrome: From pathophysiology to treatment. *Clin Exp Med*. 2017;17(3):257–67.
- [8] Schrieber K, Hunt BJ. Managing antiphospholipid syndrome in pregnancy. *Thromb Res* 2019;181(Suppl 1):S41–6.
- [9] Berceanu S, Patrascu A, Berceanu C, Tica AA, Badulescu A, Braila MB, et al. Morphopathological changes induced by the obstetrical antiphospholipid antibody syndrome in fetal adnexa and uterus. *Rom J Morphol Embryol* 2008;49(1):47–52.
- [10] Asherson RA, Cervera R. Unusual manifestations of the antiphospholipid syndrome. *Clin Rev Allergy Immunol* 2003;25(1):61–78.
- [11] Noureldine MHA, Khamashta MA, Merashli M, Sabbouh T, Hughes GRV, Uthman I. Musculoskeletal manifestations of the antiphospholipid syndrome. *Lupus* 2016;25(5):451–62.
- [12] Tektonidou MG, Malagari K, Vlachoyiannopoulos PG, Kelekis DA, Moutsopoulos HM. Asymptomatic avascular necrosis in patients with primary antiphospholipid syndrome in the absence of corticosteroid use: A prospective study by magnetic resonance imaging. *Arthritis Rheum* 2003;48(3):732–6.
- [13] Hisada R, Kato M, Ohnishi N, Sugawara E, Fujieda Y, Oku K, et al. Antiphospholipid score is a novel risk factor for idiopathic osteonecrosis of the femoral head in patients with systemic lupus erythematosus. *Rheumatology (Oxford)* 2019;58(4):645–9.
- [14] Cecchi I, Pérez Sánchez L, Sciascia S, Roccatello D. Multifocal avascular osteonecrosis despite appropriate anticoagulation therapy in a patient with systemic lupus erythematosus and antiphospholipid syndrome. *BMJ Case Rep*, 2018; 2018:bcr2018225532.
- [15] Legrève S, Brands G. Multifocal osteonecrosis revealing an antiphospholipid syndrome: case report. *Rev Med Liege*. 2017;72(5):232–6.
- [16] Crome CR, Rajagopalan S, Kuhan G, Fluck N. Antiphospholipid syndrome presenting with acute digital ischaemia, avascular necrosis of the femoral head and superior mesenteric artery thrombus. *BMJ Case Rep*, 2012; 2012:bcr2012006731.
- [17] Lee EE, Jun JK, Lee EB. Management of women with antiphospholipid antibodies or antiphospholipid syndrome during pregnancy. *J Korean Med Sci*. 2021;36(4):e24.