

# Simultaneous Arterial and Venous Thromboembolic Incidents in a Patient with Liver Cirrhosis

---

Milić, Sandra; Rajević, Damir; Mikolašević, Ivana; Štimac, Davor

Source / Izvornik: **Journal of Liver and Clinical Research, 2014, 1**

**Journal article, Published version**

**Rad u časopisu, Objavljena verzija rada (izdavačev PDF)**

Permanent link / Trajna poveznica: <https://um.nsk.hr/um:nbn:hr:184:393736>

Rights / Prava: [Attribution-NonCommercial 4.0 International](#)/[Imenovanje-Nekomercijalno 4.0 međunarodna](#)

Download date / Datum preuzimanja: **2024-07-26**



Repository / Repozitorij:

[Repository of the University of Rijeka, Faculty of Medicine - FMRI Repository](#)



## Case Report

# Simultaneous Arterial and Venous Thromboembolic Incidents in a Patient with Liver Cirrhosis

Milic Sandra<sup>1</sup>, Raljevic Damir<sup>2\*</sup>, Mikolasevic Ivana<sup>1</sup> and Stimac Davor<sup>1</sup>

<sup>1</sup>Department of Gastroenterology, University Hospital Rijeka, Croatia

<sup>2</sup>Division of Cardiology, Hospital for Medical Rehabilitation of the Hearth and Lung Diseases and Rheumatism, Croatia

**\*Corresponding author**

Raljevic Damir, Division of Cardiology, Hospital for Medical Rehabilitation of the Hearth and Lung Diseases and Rheumatism "Thalassotherapija" Opatija, M.Tita 188/1, 51410 Opatija, Croatia, Tel: 385915970296, Fax: 38551202724, E-mail: damir.raljevic@gmail.com

Submitted: 29 September 2014

Accepted: 24 October 2014

Published: 30 October 2014

**Copyright**

© 2014 Raljevic et al.

**OPEN ACCESS****Keywords**

- Coagulation
- Cirrhosis
- Stroke
- Thrombosis
- Infarction

**Abstract**

**Introduction:** There is a widespread opinion that patients with liver cirrhosis are protected from thromboembolic incidents, largely because of the increased risk of bleeding and altered conventional coagulation tests. However, an increasing number of publications confirm the opposite. We present a case report of liver cirrhosis patients with multiple thromboembolic incidents.

**Case report:** A 50-year-old patient with previously known liver cirrhosis of alcoholic etiology presented with weakness of the left body side, right-sided homonymous hemianopsia, and abdominal pain. The patient was diagnosed with ischemic lesions of the left occipital lobe, multiple spleen infarctions, and thrombosis of the portal, lineal, and mesenteric veins.

**Discussion:** Disrupted balance of the synthesis of anti- and procoagulant factors in patients with liver cirrhosis underlies the increased incidence of thromboembolic incidents in these patients compared with the general population. Despite the reduced number of platelets, elevated von Willebrand factor levels often compensate for this imbalance. Genetic polymorphisms in Factor II, Factor V, and methyltetrahydrofolate reductase (involved in homocysteine metabolism) are associated with patients with liver cirrhosis who develop thromboembolic incidents.

**Conclusion:** This case provides yet more insight in the elevated incidence of thromboembolic incidents in patients with liver cirrhosis compared with the general population. Despite the popular view that these patients are protected from these incidents, they are not uncommon and should be considered during patient treatment.

**INTRODUCTION**

There is a widespread opinion among medical professionals and the scientific community that patients suffering from liver cirrhosis are protected from thromboembolic incidents. This opinion is based on the observation that patients with liver cirrhosis are more likely to hemorrhage due to decreased platelet counts and disrupted conventional coagulation parameters such as prothrombin time [1]. However, a growing number of publications report that the risk of thromboembolic incidents is increased in these patients compared with the general population [2-7]. This increased risk is independent of standard tests of coagulation. Here we present a case report of a patient with liver cirrhosis who, in spite of impaired values on standard

coagulation tests, suffered multiple thromboembolic incidents.

**CASE PRESENTATION**

A 50-year-old patient with previously diagnosed liver cirrhosis grade B according to Pugh's modification of the Child classification was hospitalized at the Department of Hepatology, Clinic of Internal Medicine, and University Hospital in Rijeka, Croatia because of pain in the abdomen, left-sided hemiparesis, and right-sided homonymous hemianopsia. The symptoms were acute in nature and began on the day of hospitalization. Laboratory tests indicated decreased platelet levels, an accelerated erythrocyte sedimentation rate, decreased serum albumin levels, and elevated C-reactive protein levels; the tests also revealed impaired values on conventional coagulation tests

(Table 1). An urgent brain computed tomography scan was performed, followed by magnetic resonance imaging of the brain (Figure 1) that verified ischemic cerebrovascular stroke of the left occipital lobe. Vascular ultrasound of the abdomen reflected elevated pressure in the portal circulation. Multi-slice computed tomography (MSCT) angiography revealed thrombosis of the portal and mesenteric veins and multiple spleen infarctions (Figure 2). A week before the incident, the patient had been hospitalized to implement the first stage of processing for liver transplantation. The above-mentioned disorders were not reported, suggesting an acute condition.

Given the presence of a simultaneous arterial and venous thrombotic incident, a transthoracic and transesophageal ultrasound of the heart was performed and did not provide evidence of a right-left shunt. Color Doppler of the carotid and vertebral arteries showed no interference with blood flow. Laboratory tests registered decreased levels of protein C and antithrombin III; normal alleles of Factor II and Factor V were detected, but the patient was heterozygous for the 1298C MTHFR677T mutation in methylenetetrahydrofolate reductase (MTHFR), an enzyme involved in homocysteine metabolism (Table 2). Cytology and laboratory analysis of ascites established spontaneous bacterial peritonitis. At the time of hospitalization we were unable to assess PTT because of a temporary technical laboratory malfunction, although this is a routinely performed test. Unfortunately, it is impossible in our facility to assess the level antiphospholipid and anticardiolipid antibodies, which would help to assess more precisely the whole coagulation status.

The patient was treated with standard therapy to reduce

portal pressure, antibiotics, and parenteral anticoagulant therapy. During the initial days of hospitalization, the patient was treated with low molecular weight heparin with continued warfarin administration. The patient subsequently became asymptomatic, with complete regression of the left-sided hemiparesis and partial regression of the right-sided hemianopsia. After six months of anticoagulant therapy, a control MSCT of the abdomen showed absolute regression of the portal and mesenteric vein thromboses (Figure 3). The patient is currently on the list for liver transplantation.

## DISCUSSION

This case reports provides a counter-example to the widespread belief among medical practitioners in general that patients with liver cirrhosis are protected from thromboembolic incidents. This opinion is based on the observation that patients with liver cirrhosis are more likely to hemorrhage due to decreased platelet counts and disrupted conventional coagulation parameters such as prothrombin time [1]. Recent studies have indicated that the decreased platelet number is compensated by an increased level of the von Willebrand factor, which renders insignificant the difference in platelet aggregation between the general population and patients with liver disease [8]. Other studies, particularly epidemiological, report an increased incidence of thromboembolic incidents in patients with liver disease relative to the general population [4,5], possibly due to decreased levels of synthesis of procoagulant and anticoagulant factors such as protein C, protein S, or tissue plasminogen activator. If the synthesis of anticoagulant factors decreases relative to the synthesis of procoagulant factors, the risk of thromboembolic incidents increases [9]. This increased

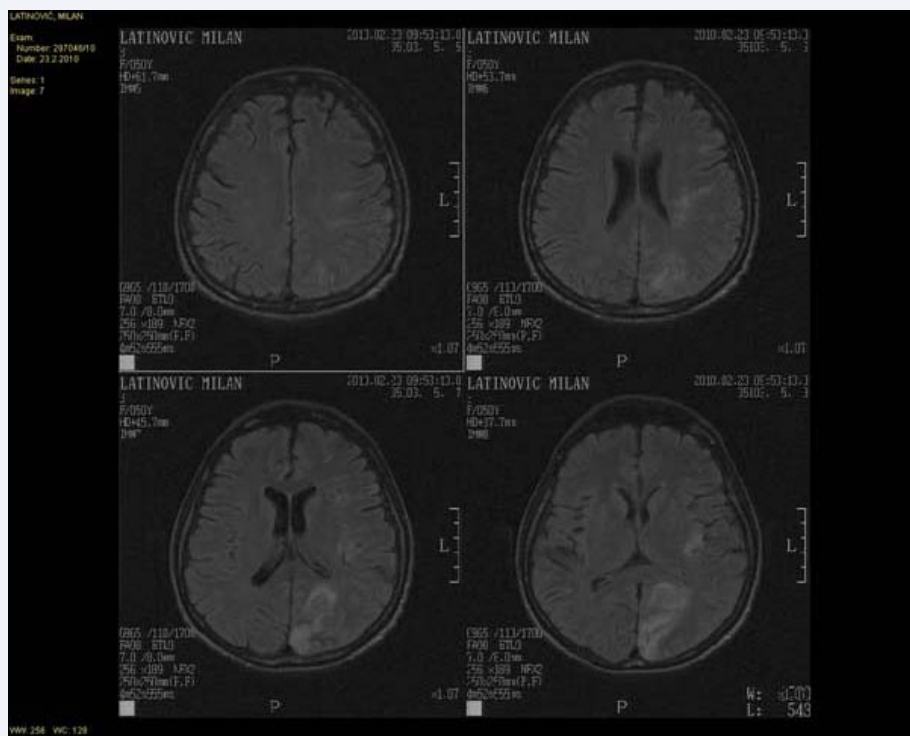
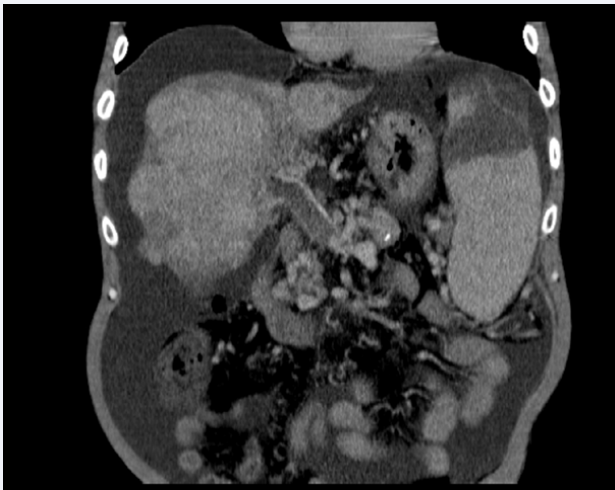
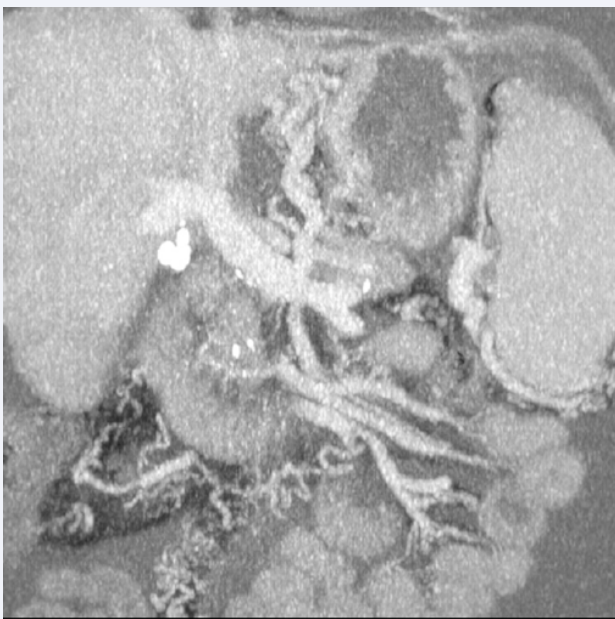
Figure 1 Magnetic resonance image of the brain, including an ischemic lesion of the right occipital lobe.



**Figure 2** Abdominal multi-slice computed tomography indicating portal vein thrombosis, mesenteric vein thrombosis, and multiple spleen infarctions.



**Figure 3** Control MSCT of the abdomen – complete regression of the portal and mesenteric vein thrombosis.

risk is not related to abnormal coagulation tests, which are not adequate to assess the risk of future thromboembolic incidents [3]; therefore, new routine tests for the assessment of this risk should be introduced. Serum albumin levels and partial thromboplastin time (PTT) values are independently associated with an increased risk of thromboembolic incident [3]. In our patient, the levels of albumin and protein C were decreased (Table 1); unfortunately, at the time of hospitalization because of a temporary laboratory technical malfunction we were unable to assess PTT, although it is a routinely performed test. Since the patient evidently suffered an incident that was simultaneously arterial and venous, we suspected a systemic coagulation disorder.

The incidence of portal vein thrombosis is highest in cases of liver cirrhosis, and 69.5% of patients with liver cirrhosis and portal vein thrombosis also have hereditary hypercoagulability syndrome [10,11]. We assayed for genetic factors such as disruption of the genes for Factor II and Factor V Leiden, but our patient carried normal alleles (Table 2). Elevated serum homocysteine levels, which are associated with reduced MTHFR activity due to genetic polymorphism, are also associated with increased risk of thromboembolic incident. The MTHFR677T polymorphism leads to a 30% reduction in MTHFR activity, with homozygotes exhibiting a 60% decrease in activity [12,13]. Our patient is heterozygous for MTHFR677T and MTHFR1298C (Table 2) and this gene polymorphism that leads to reduced MTHFR activity may be responsible for the thromboembolic incident. Unfortunately, in our hospital it is possible to assess the

**Table 1:** Initial laboratory findings.

Laboratory test	Result	Reference values
Leukocytes (x10 <sup>9</sup> /L)	10.7	3.4 - 9.7
Hemoglobin (g/L)	116	138 - 175
Hematocrit	0.339	0.415 - 0.530
Platelets (x10 <sup>9</sup> /L)	64	158 - 424
Serum urea (mmol/L)	5.5	2.8 - 8.3
Serum creatinine (μmol/L)	73	79 - 125
Aspartate aminotransferase (U/L)	65	11 - 38
Alanine aminotransferase (U/L)	75	12 - 48
Gammaglutaryl transferase (U/L)	75	11 - 55
Alkaline phosphatase(U/L)	100	60 - 142
Total bilirubin (μmol/L)	50	3 - 20
Direct bilirubin (μmol/L)	16	0 - 5
Serum amylase (U/L)	43	23 - 91
Serum lipase (U/L)	60	13 - 60
CRP (mg/L)	132.9	0 - 5
Serum albumin (g/L)	32.9	40.6 - 51.4
PT	0.58	≥ 0.70
INR	1.16	1.0
D-dimer (mg/L)	6.45	< 0.50

**Table 2:** Laboratory coagulation tests.

Test	Result	Interpretation
Factor V Leiden G1691A	Normal allele	Normal genotype
Prothrombin (II) G20210A	Normal allele	Normal genotype
MTHFR C677T	Mutated and normal alleles	Heterozygous
MTHFR A1298C	Mutated and normal alleles	Heterozygous
Antithrombin	70% activity	Reduced activity
Protein C	65% activity	Reduced activity
Protein S	78% activity	Normal activity
Lupus anticoagulant	44 seconds	Normal

MTHFR- Methylene tetrahydrofolate reductase.

homocysteine concentration. The same is with antiphospholipid anticardiolipid antibody. Knowing the level of these antibodies would help to assess the coagulation status more precisely.

Despite abnormal conventional coagulation tests, anticoagulant therapy is a logical strategy for treating patients with liver cirrhosis and portal vein thrombosis. Long-term anticoagulant therapy is not recommended for all patients with liver cirrhosis, although it is recommended for patients exhibiting signs of intestinal ischemia and in candidates for liver transplantation [14,15]. Now days the benefit of long-term anticoagulant therapy in treatment and prevention of thromboembolic incidents in patients with liver cirrhosis is insufficiently explored and additional data are required.

## CONCLUSION

Our patient case study is in agreement with a growing number of scientific publications reporting an increased incidence of hypercoagulability in patients with liver cirrhosis compared with the general population. The synthesis of anti- and procoagulant factors is reduced in patients with liver cirrhosis, and reduced synthesis of anticoagulant factors underlies the increased incidence of thromboembolic incidents in these patients. Based on our experience, and counter to the general opinion, we recommend the consideration of thromboembolic incidents when treating patients with liver cirrhosis.

## ACKNOWLEDGEMENTS

Milic S, Raljevic D, Mikolasevic I and Stimac D. contributed equally to this work; Milic S, Raljevic D, Mikolasevic I and Stimac D. designed and performed the work and wrote the paper

## REFERENCES

1. Tripodi A, Mannucci PM. Abnormalities of hemostasis in chronic liver disease: reappraisal of their clinical significance and need for clinical and laboratory research. *J Hepatol.* 2007; 46: 727-733.
2. Tripodi A, Anstee QM, Søgaard KK, Primignani M, Valla DC. Hypercoagulability in cirrhosis: causes and consequences. *J Thromb Haemost.* 2011; 9: 1713-1723.
3. Gulley D, Teal E, Suvannasankha A, Chalasani N, Liangpunsakul S. Deep vein thrombosis and pulmonary embolism in cirrhosis patients. *Dig Dis Sci.* 2008; 53: 3012-3017.
4. Ali M, Ananthakrishnan AN, McGinley EL, Saeian K. Deep vein thrombosis and pulmonary embolism in hospitalized patients with cirrhosis: a nationwide analysis. *Dig Dis Sci.* 2011; 56: 2152-2159.
5. Søgaard KK, Horváth-Puhó E, Grønbaek H, Jepsen P, Vilstrup H, Sørensen HT, Risk of venous thromboembolism in patients with liver disease: a nationwide population-based case-control study. *Am J Gastroenterol.* 2009; 104: 96-101.
6. Lesmana CR, Inggriani S, Cahyadinata L, Lesmana LA. Deep vein thrombosis in patients with advanced liver cirrhosis: a rare condition? *Hepatol Int.* 2010; 4: 433-438.
7. Northup PG, McMahon MM, Ruhl AP, Altschuler SE, Volk-Bednarz A, Caldwell SH, et al. Coagulopathy does not fully protect hospitalized cirrhosis patients from peripheral venous thromboembolism. *Am J Gastroenterol.* 2006; 101: 1524-1528.
8. Lisman T, Bongers TN, Adelmeijer J, Janssen HL, de Maat MP, de Groot PG, et al. Elevated levels of von Willebrand Factor in cirrhosis support platelet adhesion despite reduced functional capacity. *Hepatology.* 2006; 44: 53-61.
9. Tripodi A, Primignani M, Chantarangkul V, Dell'Era A, Clerici M, Franchis R, et al. An imbalance of pro- vs anti-coagulation factors in plasma from patients with cirrhosis. *Gastroenterology.* 2009; 137: 2105-2111.
10. Amitrano L, Brancaccio V, Guardascione MA, Margaglione M, Iannaccone L, D'Andrea G, et al. Inherited coagulation disorders in cirrhotic patients with portal vein thrombosis. *Hepatology.* 2000; 31: 345-348.
11. Valla DC. Thrombosis and anticoagulation in liver disease. *Hepatology.* 2008; 47: 1384-1393.
12. Miyaki K. Genetic polymorphisms in homocysteine metabolism and response to folate intake: a comprehensive strategy to elucidate useful genetic information. *J Epidemiol.* 2010; 20: 266-270.
13. Biagini MR, Tozzi A, Marcucci R, Paniccia R, Fedi S, Milani S, et al. Hyperhomocysteinemia and hypercoagulability in primary biliary cirrhosis. *World J Gastroenterol.* 2006; 12: 1607-1612.
14. Senzolo M, Sartori MT, Lisman T. Should we give thromboprophylaxis to patients with liver cirrhosis and coagulopathy? *HPB (Oxford).* 2009; 11: 459-464.
15. Ponziani FR, Zocco MA, Campanale C, Rinninella E, Tortora A, Di Maurizio L, et al. Portal vein thrombosis: insight into physiopathology, diagnosis, and treatment. *World J Gastroenterol.* 2010; 16: 143-155.

### Cite this article

Milic S, Raljevic D, Mikolasevic M, Stimac D (2014) Simultaneous Arterial and Venous Thromboembolic Incidents in a Patient with Liver Cirrhosis. *J Liver Clin Res* 1(1): 1003.