

# 6th Congress of Emergency Medicine : Abstract book

---

## Other document types / Ostale vrste dokumenata

Publication year / Godina izdavanja: **2022**

Permanent link / Trajna poveznica: <https://urn.nsk.hr/urn:nbn:hr:184:763342>

Rights / Prava: [In copyright](#) / [Zaštićeno autorskim pravom.](#)

Download date / Datum preuzimanja: **2024-07-14**

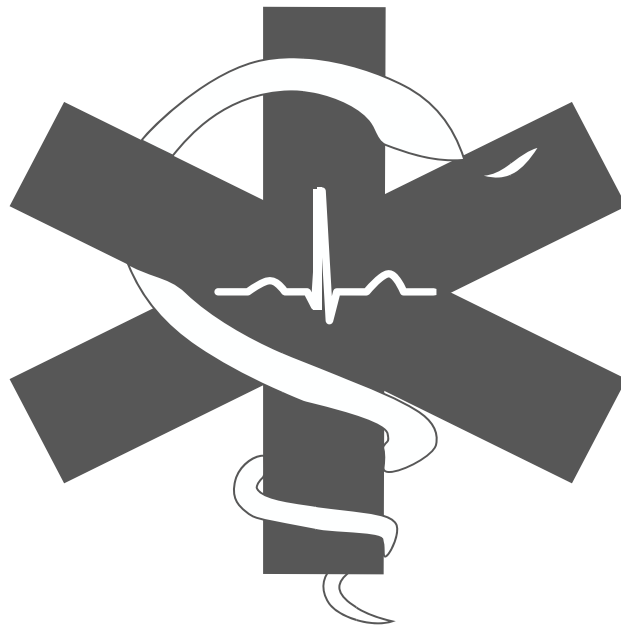

Repository / Repozitorij:

[Repository of the University of Rijeka, Faculty of Medicine - FMRI Repository](#)



# **6<sup>th</sup> Congress of Emergency Medicine**



**March 25<sup>th</sup> -27<sup>th</sup>, 2022  
Rijeka, Croatia**

---

# Impressum

**Published and organized by**  
FOSS MEDRI

**Co-organized by**  
University of Rijeka, Faculty of Medicine  
Clinical Hospital Center Rijeka  
Institute for Emergency Medicine of the Primorje – Gorski kotar County

**For publisher**  
Marija  
Prekodravac

**Editors**  
Lara Tomašić  
Mario Barukčić

**Editor in-chief**  
Edvard Bedoić

**Language editors**  
Lara Tomašić  
Mario Barukčić

**Graphic design**  
Ivona Pek

**Print**  
Čarobni tim, Osijek

**Copies**  
55

*Printing of this Abstract book was made possible by the financial support of the University of Rijeka Student Union. The translations, opinions, findings, conclusions and recommendations presented in this Abstract Book do not necessarily reflect those of the Editing Board or the Sponsors and are exclusively the responsibility of the Authors.*

**ISBN:**

**UDK:**

*CIP entry is available at the University Library of Rijeka in their Computer Catalog under number*

---

# Committees

## Organizing Committee

Antonio Kauzlarić

David Senjić

Rea Korpar

Laura Radoš

Sandra Knežević

Lucija Kučina

Dora Primorac

Iva Saraja

Maša Kopusar

Lucija Gajski

Eva Levatić

Petra Mrković

Antun Mršić

Mario Rumora

Tiyya Selimović

Magda Gajski

Lara Tomašić

Edvard Bedoić

Mario Barukčić

Josipa Kajjić

Marija Prekodravac

## Scientific Committee

Sara Belčić, MD

Domagoj Mičetić, MD

Ana Pavletić, MD

Marta Crnčić, MD

Nikolina Golem, MD

Frano Marinelli, MD

Ana Terezija Jerbić Radetić, MD

---

## Welcome note

Dear colleagues and friends,

On behalf of the Organizing Committee, it is my great honor to wish You a warm welcome to the 6th Congress of Emergency Medicine.

This Congress is organized by students for students and all those who wish to perfect lifesaving skills. It is a project arranged by the student association FOSS MEDRI in partnership with the Faculty of Medicine University of Rijeka, Clinical Hospital Center Rijeka and the Emergency medicine institute of the Primorje-Gorski kotar County. It consists of lectures, presentations of students' research papers and practical workshops.

From the beginning our main focus was on raising awareness for the importance of emergency medicine. This year, for the first time, the Congress has a theme, trauma. We decided to put a spotlight on this big part of emergency medicine that is somewhat overlooked in our curriculum. Our biggest motivation is to help students and young doctors gain additional knowledge and practice in emergency medicine for which, unfortunately, there is no time during their studies. Through the years, we have kept our mission alive by hosting some of our leading experts in the field of medicine, who selflessly shared their expertise and experience.

This past year we had the privilege of organising this Congress in its full capacity after 3 years. This is a passion project that wouldn't be possible without a group of dedicated medical students that planned it to the smallest detail. I would like to thank this amazing team for every written e-mail, social media post, creative idea, long hours and never-ending enthusiasm that made this years Congress a reality

Sincerely,




Marija Prekodravac  
President of Organizing committee

---

---

# PLENARY LECTURE

---



---

## **Polytrauma management**

Višnja Neseck Adam<sup>1,2,3</sup>

<sup>1</sup>*Head of University Department of Anesthesiology, Resuscitation and Intensive Care*

<sup>2</sup>*Head of Emergency Medicine Department*

<sup>3</sup>*President of the Croatian Society of Emergency Medicine*

---

**Lecture summary:** Polytrauma is a simultaneous traumatic injury that affects two or more body system or organs, one of which may be potentially life-threatening in severity. It is the leading cause of mortality in the under-40 population and morbidity with severe sequelae.

Clinical management of severely injured patients is challenging in all phases of treatment during the clinical course and the optimization of their care is today a major focus of clinical research. In order to achieve the best possible outcomes, the management of trauma patients requires a highly systematic approach and multidisciplinary evaluation. The initial management includes securing the airway and breathing, hemorrhage control, resuscitation, and stabilization the vital function. Despite improvements in trauma care, uncontrolled bleeding contributes to 30% to 40% of trauma-related deaths and is the most common preventable causes of mortality. In the acute phase of hemorrhage, priority is to stop the bleeding, start with balanced approach to fluid replacement and the use of vasopressors and blood transfusion to prevent or correct acute coagulopathy of trauma.

Although, the optimal resuscitative strategy in trauma patients is still controversial, in this lecture we will present a review of current knowledge in the field of trauma with emphasizes on fluid and blood resuscitation.



---

# LECTURES

---



---

## **Distinguish the important from the irrelevant - the first steps in ER patients approach.**

Ivana Žitinić<sup>1,2</sup>

<sup>1</sup> *Emergency Medicine Department, Clinical Hospital Center Rijeka, Croatia*

<sup>2</sup> *Anesthesiology, Reanimatology, Intensive Care and Emergency Medicine Department, School of Medicine, Rijeka, Croatia*

---

**Summary:** The approach to the patient in ER differs from the approach to the patient in the outpatient setting. In the ER we have limited time, limited resources, and a seemingly “infinite” number of patients awaiting examination and treatment. The first contact with the medical staff at ER is the triage technician or nurse, who, depending on the primary problem, duration, and vital parameters, triages the patient into one of five categories. ER medical history is focused and complain directed. The primary goal is to rule out potentially life-threatening conditions. The secondary goal is to make a differential diagnosis. There is no universal approach, but there are specific questions for certain groups of problems that helps us to narrow the differential diagnosis as much as possible. The most common errors in the treatment of patients in ER are insufficiently detailed examination and speed due to crowds, as a result of which it is often forgotten to reevaluate the patient. The approach to each patient in ER should be as if he / she is potentially critically ill until proven otherwise, with priority given to sicker patients, ie patients of higher triage category.

Key words: differential diagnosis, emergency, triage

---

## **Water and sodium in ICU patients**

Alan Šustić<sup>1,2</sup>

<sup>1</sup>*Department of Anesthesiology, Intensive Care, Emergency and Intensive Care*

<sup>2</sup>*Faculty of Medicine, University of Rijeka*


---

**Lecture summary:** In this review lecture, the author presents the fundamental relationships of water and sodium metabolism in critically ill patients. In the first third of the lecture, he looks at the physiological relationships between water and sodium and lays the foundations for their understanding. The second third of the lecture points to the water balance in critically ill patients in the context of the patient's condition and outcome. Finally, in the third part of the lecture, the author talks about the problems of hyper- and hyponatremia in intensive care and ways to treat them.

---

# WORKSHOPS

---



---

## **Workshop of Clinical Scenarios**

Tamara Petrić<sup>1</sup>, Maja Materljan<sup>2</sup>, Ema Šlabek<sup>3</sup>

*<sup>1</sup>Emergency medicine specialist, Center for Emergency Medicine  
Clinical Hospital Center Rijeka*

*<sup>2</sup>Emergency medicine specialist, Center for Emergency Medicine, Clinical  
Hospital Center Rijeka*

*<sup>3</sup>Center for Emergency Medicine, Clinical Hospital Center Rijeka*

---

**Workshop summary:** Trauma is the leading cause of mortality globally. Worldwide, road traffic injuries are the leading cause of death among young patients. As first-line providers, our primary responsibility is to initiate resuscitation and stabilization of traumatised patients in the acute phase. Throughout this workshop we will try to explain the importance of ABCDE approach, the role of bed side ultrasound and the utility of equipment specialized for traumatised patients.

Clinical cases that will be shown in this workshop will present our clinical experience and are designed to answer all of your questions. They are going to cover a series of trauma cases of varying complexity.

The concept of the clinical cases will be case-report form like and are following the patients from their admission to the department of the Emergency medicine, following the procedures that were made, following the treatment that was chosen, and the follow-up of the patients as well. So, keep your mind open, concentrate on the differential diagnosis and be prepared to choose the right treatment in the given situation.

---

## **Focused sonography in traumatized patients in emergency medicine – FAST and e-FAST protocols, practical appliance**

Medjit Smilji<sup>1</sup>, Tatjana Mileta<sup>1,2</sup>, Ivana Žitinić<sup>1,2</sup>

<sup>1</sup>*Emergency Medicine Department, Clinical Hospital Center Rijeka, Croatia*

<sup>2</sup>*Anaesthesiology, Reanimatology, Intensive Care and Emergency Medicine Department, School of Medicine, Rijeka, Croatia*

---

**Workshop summary:** Ultrasound is a radiological, digital and non-invasive technique based on the reflection of ultrasound waves. Ultrasound has become an indispensable diagnostic tool in emergency medicine. It is a fast, painless, safe, comfortable, mobile and reliable examination technique that enables fast and accurate diagnosis in a large number of patients and helps to plan further diagnostic procedures. Focused assessment with sonography for trauma (FAST) has become an indispensable part of the treatment of patients with abdominal and / or thoracic trauma. FAST protocol includes targeted ultrasound examination of the abdomen at four points (subxiphoid, hepatorenal, splenorenal and suprapubic) with the aim of detecting the presence of free fluid in the abdomen and pericardium. An extended version of the FAST protocol is e-FAST, which additionally includes a four-point examination of the chest (anterior and lateral pleural space of the right and left chest) to detect the presence of free fluid in the chest (hemothorax) and / or pneumothorax. FAST and e-FAST protocols are now used in emergency medicine as an initial diagnostic method in the assessment of patients with abdominal and / or thoracic trauma. These protocols have significantly shortened the work-up time of traumatized patients, especially those requiring urgent surgical treatment. Although designed to speed up the care of traumatized patients, FAST and e-FAST protocols are also used as point-of-care ultrasound (POCUS) components to identify free fluid of other etiologies in the daily treatment of non-traumatic emergency patients (e.g., ruptured abdominal aortic aneurysm, ectopic pregnancy, ascites, pleural effusions of cardiac or inflammatory etiology).

---

## **The wound management workshop**

Marinka Otočan<sup>1</sup>, Petra Šverko Zinaić<sup>2</sup>, Mirjana Maras<sup>3</sup>, Luciana Jakšić<sup>4</sup>

<sup>1</sup>*Center for Emergency Medicine, Clinical Hospital Center Rijeka, Department of Anaesthesiology, Reanimatology Intensive Care and Emergency Medicine, Faculty of medicine, University of Rijeka*

<sup>2</sup>*Center for Emergency Medicine, Clinical Hospital Center Rijeka, Department of Anaesthesiology, Reanimatology Intensive Care and Emergency Medicine, Faculty of medicine, University of Rijeka*

<sup>3</sup>*Center for Emergency Medicine, Institute of Emergency medicine of Istra*

<sup>4</sup>*Center for Emergency Medicine, Clinical Hospital Center Rijeka*

---

**Workshop summary:** One of the most common problem in emergency department is dealing with wounds including lacerations, bites and punctures.

Attention to each step of wound care leads to the best possible outcome. These steps are: hemostasis, anaesthesia, wound irrigation, removal of devitalized and contaminated tissue, tissue preservation, closure tension, sutures, dressing and follow up.

The major goals of wound care are to eliminate complications, restore function and reduce scarring, and the most common complication of wound care is infection.

The main aim of this workshop it to determine sewing skills and wound treatment to medical students.

This wound management workshop aims to expand students knowledge and skills required in assessment and management of wounds.

---

## Vacuum mattress immobilization

Darko Stošić<sup>1</sup>

*<sup>1</sup>Institute of Emergency Medicine of the Primorje – Gorski kotar County, Rijeka, Croatia*

---

**Workshop summary:** A vacuum mattress is used to immobilize the whole body. It is more comfortable than any other immobilizer, so it is also suitable for longer transports. Casualties with suspected pelvic or both femur injuries are ideal for a vacuum mattress, as are those with polytrauma. Scoop stretchers are used to move the victim to the vacuum mattress. Also, the elderly should be placed in a vacuum mattress. The disadvantage is that it cannot be used for extraction due to the sensitivity of the material. When the casualty is moved to a vacuum mattress using a scoop stretcher, it should be removed. After that, the standard fixation with a belt starts, first the body and then the head. In order to obtain the desired effect, it is necessary to extract the air contained in it with the help of a hand pump. Inside the mattress are polystyrene balls that come together by drawing air and create a solidified mass. In this way, the mattress as an immobilizing device is adapted to the anatomy or injury of the victim. No matter how hard you try to get air out of it, it will never be completely hard. Therefore, it is recommended that the patient be carried on the sides otherwise unwanted vacuum mattress bending may occur.



---

## Spinal motion restriction with the long backboard

Darko Stošić<sup>1</sup>

*<sup>1</sup>Institute of Emergency Medicine of the Primorje – Gorski kotar County, Rijeka, Croatia*

---

**Workshop summary:** The long backboard for immobilization and extraction is an aid with which we immobilize the whole body. It is made of plastic, reinforced inside to prevent cracking and a load capacity of 150 to 270 kilograms, depending on the manufacturer. The long backboard is also suitable for extracting from stagnant and running water because it floats on the surface of the water. The casualty is placed onto the backboard by log rolling or if there is a suspicion of injury to the pelvis or both femur and a foreign body in the torso by moving it with a scoop stretcher. With log rolling the spine moves as a single entity with the head and pelvis. The long backboard is not recommended for the elderly due to frequent spinal deformities, as well as transport longer than 30 - 40 minutes due to discomfort. For fixing on a long backboard, 4 straps and head stabilizers with fixing straps are required. Head stabilizers can be plastic or soft sponge mass. They have an opening on each one where the victim's ear is positioned for easier communication but also to monitor bleeding from the ear or leakage cerebrospinal fluid from the ear. The victim's body is fixed first, then his head. Fixation starts from the chest to the feet, so that the first strap is placed as high as possible so that the strap comes at the level of the armpits, the second is placed over the pelvis, the third above the knee and with the fourth strap we do the so-called "eight" where we immobilize the ankle area for better stabilization. If a pelvic injury is suspected, then the second and third strap is fixed diagonally across the pelvis. If there is a suspicion of a femur injury, then the third strap is placed below the knee. After fixing the body, the head is fixed with head stabilizers and fixation straps, one over the forehead and the other over the collar under the chin.

---

## Trauma assessment

Darko Stošić<sup>1</sup>

*<sup>1</sup>Institute of Emergency Medicine of the Primorje – Gorski kotar County, Rijeka, Croatia*

---

**Workshop summary:** All persons who have experienced trauma should be assessed and cared systematically using a systematic trauma examination to identify casualties with potentially life-threatening injuries. The trauma assessment begins with scene size-up which includes taking standard precautions, evaluating hazards on the scene, determining the number of patients and the need for additional resources, as well as the mechanism of injury. Mechanism of injury can be generalized or localized. Generalized mechanism of injury includes collision of motor vehicles, fall from a height, etc. Localized mechanism specifically causes injury limited to the area such as stab wounds to the abdomen, amputation of feet, etc. Generalized mechanism of injury requires rapid examination of trauma, while localized in most cases sufficient targeted examination limited to affected anatomical regions or systems. The assessment of the scene is followed by an initial assessment. During the initial assessment ABC, the head and neck are manually stabilized and the state of consciousness is determined, A- airways, B- breathing (respiration), and C- circulation are assessed. Problems are solved as they are encountered, i.e. no assessment of respiration and circulation is made until airway is ensured. Detention at the scene for critical casualties should not be longer than 10 minutes. A quick trauma examination allows the HMS team leader to detect injuries that require prompt care. It is necessary to examine every segment of the body (head, neck, chest, abdomen, pelvis, legs, arms and back) by inspection, palpation, auscultation and percussion (if necessary).

A SAMPLE history should be taken during a rapid trauma examination. After the initial assessment and a quick examination of the trauma, a decision is made on the immobilizer and transport of the injured person.

---

# ORAL PRESENTATIONS

---



---

## **Acute coronary syndrome in family medicine practice - case report**

Filip Doder<sup>1</sup>, Jakov Božiković<sup>2</sup>

<sup>1</sup>Health center of Krapinsko Zagorska county, Krapina, Croatia

<sup>2</sup>Medical faculty, University of Rijeka, Rijeka, Croatia

**Corresponding author:** Filip Doder, dodorf97@gmail.com

---

**Introduction:** Acute coronary syndrome (ACS) is defined as a wide spectrum of conditions associated with sudden reduced blood flow through coronary arteries. Based on the electrocardiogram (ECG) it may divide into groups: ACS with persistent ST segment elevation and ACS without persistent ST elevation which according to the troponin levels may be either non ST segment elevation myocardial infarction (NSTEMI) or unstable angina pectoris. Clinically patients present with symptoms as chest pain and symptoms of acute heart failure. In this case report we present a 82 year old female who presented to the family medicine physician (FMP) with ACS like symptoms, its approach and role in disposal of ACS algorithm in Croatia.

**Case report:** A 82 year old female presented to her FMP complaining on chest pain and dyspnea. She localized the pain in the center of the sternum with radiation to her upper back. Upon arrival she was tachydyspnoic using auxiliary respiratory muscles with saturation of 87%. Her skin was cold, mildly diaphoretic, with palpable, arrhythmic radial pulse. Blood pressure was non measurable and heart action was arrhythmic with quieter heart sounds without a heart murmur. Electrocardiogram showed atrial fibrillation with rapid ventricular response and ST depression of 1 mm in leads V2-V6. Capillary refill time was three seconds. The venous cannula and the catheter were administered. She was alert, her glucose levels were 12.3 mmol/l. Extremities were slightly edematous, cold with palpable pulsations. According to these findings the working diagnosis of ACS was made and patient was transferred hospital.

**Conclusion:** According to the literature about 20-40% of people reports to their FMPs with chest pain during lifetime. Of these only 3.6% are later diagnosed with ACS. With these findings we see that although ACS is not that common, FMPs should be aware of it and act properly.

**Keywords:** Acute coronary syndrome, Chest pain, Family medicine

---

## **Case report: Aortic dissection presenting primarily as acute neurological disorder**

Danijel Lugonjić<sup>1</sup>, Iva Kovačević<sup>1</sup>, Nataša Mavrinac<sup>2</sup>

<sup>1</sup>*University of Rijeka, Faculty of Medicine, Rijeka, Croatia*

<sup>2</sup>*Emergency Medicine Department, Clinical Hospital Center Rijeka, Rijeka, Croatia*

**Corresponding author:** Danijel Lugonjić, danac.lugonjic@gmail.com

---

**Introduction:** Acute aortic dissection is a life-threatening condition characterized by a separation of the layers of the aortic wall due to an intimal layer tear. This tear results in formation of a second, false lumen of the aorta, which causes the original lumen to be occluded or dissection can propagate anterograde or retrograde and cause branch obstruction and initiate acute tamponade, aortic regurgitation or aortic rupture. Aortic dissection is mostly caused by chronic uncontrolled hypertension.

**Case report:** 59-year-old male presented to the Emergency room (ER) with acute onset of impaired consciousness and right-sided weakness. His wife heard him fall and found him unconscious on the floor. Soon he regained consciousness but then lost it again. In the ER the patient was agitated and aggressive, complained of strong occipital headache and right hip pain. The patient was hemodynamically stable and had a normal breathing sound. However, he had a right-sided facial drop and right-sided weakness. Due to suspicion of cerebral infarction, a Computed tomography (CT) scan was performed. Soon after, the patient started complaining of chest, neck and right hip pain. His blood pressure was immeasurably low and had no palpable pulse over his right femoral and left radial arteries. Multi-slice computer tomography (MSCT) aortography revealed Stanford A aortic dissection that required immediate surgical intervention.

**Conclusion:** Aortic dissection is a life-threatening emergency which can present with a broad spectrum of symptoms. It is essential to include aortic dissection in differential diagnosis, especially in cases of acute chest, back and abdominal pain or circulatory symptoms. For proper treatment, it is necessary to be up to date with current guidelines on diagnosis and management of aortic dissection.

**Keywords:** Aneurysm, Dissecting, Hypertension, Neurological manifestations

---

## **Bowel Perforation After Chicken Bone Ingestion Resulting in a Prolonged Hospital Stay – Case Report**

Lucija Jambrošić<sup>1</sup>, Lucija Brkić<sup>1,2</sup>, Diana Kovač<sup>1</sup>, Trpimir Morić<sup>2</sup>

<sup>1</sup>*School of Medicine, University of Zagreb, Zagreb, Croatia*

<sup>2</sup>*Department of Surgery, University Hospital Center Zagreb, Zagreb, Croatia*

**Corresponding author:** Lucija Jambrošić, ljambrosic@student.mef.hr

---

**Introduction:** Gastrointestinal perforation is a common cause of acute abdomen that needs an immediate surgical intervention. Foreign body ingestion is a common occurrence, but most of it passes through the digestive tract uneventfully. Less than 1% of ingested foreign bodies cause perforation, usually at the most angulated portion of the bowel. We report a case of a chicken bone ingestion resulting in small intestine and sigmoid colon perforation.

**Case report:** An 89-year-old woman was admitted to the Emergency Department for lower stomach pain with a three-day old necrotic wound. Vital signs were normal, and the abdomen was soft and painful on palpation. Chest and abdominal X-ray did not show any abnormalities. A contrast computed tomography (CT) was performed, and a large intraabdominal abscess was found. CT scan showed multiple gaseous-fluid collections and a linear hyperdense object lateral to the sigmoid colon, suggestive of a foreign body. The abdominal surgery team performed a lower midline laparotomy extended above the umbilicus, revealing a chicken bone 75 centimeters (cm) from the Bauchini valve. As the bone perforated the parts of gastrointestinal tract, Hartmann's procedure and resection of small intestine with latero-lateral anastomosis were done. Subsequently, suprapubic incision and drainage of a massive subcutaneous abscess was performed. Postoperatively, wound dressing under general anesthesia was done 18 times. The patient was discharged 4 months after the initial surgery.

**Conclusion:** Most of the ingested foreign objects that pass through the gastrointestinal tract will be eliminated without causing any complications, although some of the cases will require interventions or even surgery, depending on the characteristics of the foreign object.

**Keywords:** Adenocarcinoma, Foreign body, Intestinal perforation, Laparotomy

---

## Management of postintubation tracheal stenosis after prolonged mechanical ventilation due to Covid-19 infection: a case report

Filip Doder<sup>1</sup>, Sonja Badovinac<sup>2</sup>

<sup>1</sup>Health center of Krapinsko zagorska county, Krapina, Croatia

<sup>2</sup>University hospital Zagreb, Departament for Lung diseases, Zagreb, Croatia

**Corresponding author:** Filip Doder, [doderf97@gmail.com](mailto:doderf97@gmail.com)

---

**Introduction:** The most severe manifestation of Covid-19 infection is acute respiratory distress syndrome (ARDS) which in approximately 9-15% of cases requires invasive mechanical ventilation(MV), for some for a longer period of time. Although intubation is still the golden standard for severe respiratory failure management it may bring different complications. One of complications is post-intubation tracheal stenosis(PITS). We present a case of a 69 year old patient who was transferred to the Department for Lung Diseases of University hospital center Zagreb in urgent protocol due to PITS.

**Case report:** A 69 year old female was admitted to regional hospital center due to inspiratory stridor and dyspnea that lasted for two weeks. Four months ago she was hospitalized in the Covid-19 intensive care unit(ICU) because of ARDS for two weeks where she was invasively mechanically ventilated for unknown period of time. Computed tomography of the neck and thorax revealed circulatory stenosis of the proximal trachea <6mm in diameter that was confirmed with flexible bronchoscopy. According to those findings urgent transport to our clinic was arranged. Upon the arrival she was respiratory insufficient and tachydyspnoic with SpO<sub>2</sub> of 75%. Auscultation showed inspiratory stridor. Urgent flexible bronchoscopy revealed tracheal stenosis but currently with diameter of 3mm,5 cm below vocal cords. That indicated urgent bronchoscopic intervention in general anesthesia. Patient was intubated with rigid bronchoscope, electroresection of stenosis, balloon dilatation and dilatation using rigid bronchoscopes was performed and resulted with complete tracheal recanalization. After the procedure patient was transferred to the ICU where she received all supportive therapy.

**Conclusion:** Symptoms such as dyspnea and stridor in patients that have been MV due to Covid-19 should cast a doubt on PITS. Awareness of potential late complications of MV and recognition of symptoms using adequate diagnostic tools leads to positive outcomes as it was with in the presented case.

**Keywords:** Bronchoscopy, Covid-19, Tracheal stenosis

---

## **Massive hemoptysis in patient on direct-acting oral anticoagulant: a case report**

Jakov Božiković<sup>1</sup>, Filip Doder<sup>2</sup>, Vuk Prica<sup>3</sup>

<sup>1</sup>*Medical faculty of Rijeka, Rijeka, Croatia*

<sup>2</sup>*Health center of Krapinsko Zagorska county*

<sup>3</sup>*Clinical hospital center Rijeka, Rijeka, Croatia*

**Corresponding author:** Jakov Božiković, e-mail:  
jakov.bozikovic1996@gmail.com

---

**Introduction:** Massive hemoptysis is the copious expectoration of blood that originates from the lower respiratory tract and belongs to the emergencies in pulmonology. The aim is to present a patient with massive hemoptysis caused by direct oral anticoagulant (DOAC) as a rare cause.

**Case report:** An 82-year-old male was admitted to the emergency department due to copious expectoration of blood that occurred on the day of arrival. During physical examination the patient was tachypnoic with auscultatory audible bilateral snoring, more intense over the right lung. Chest radiography showed reduction of air in the right lung with spotty lung opacifications and the right hemidiaphragm obscured that aroused suspicion of pleural effusion. Pulmonary angiography ruled out pulmonary thromboembolism. Tranexamic acid and a mixture of clotting factors were administrated to reduce bleeding. Then transnasal flexible bronchoscopy was performed, which was hampered by the abundance of blood in the larynx and trachea. After clearing the bronchial tree, bleeding from the middle lobe was visualized. Tamponade was performed, which led to a significant reduction in bleeding, but did not stop it completely. Computed tomography of the chest showed consolidation of the middle lobe of the right lung suspected of malignant mass. During the next bronchoscopy the sample of tissue was taken for pathohistological analysis. Pleural effusion was also confirmed and evacuated by ultrasound guidance and the sample was sent for cytological analysis. Both findings ruled out a malignant process. After diagnostic processes and treatment, it was found that expectoration of the blood is a consequence of therapy with DOAC.

**Conclusion:** Although DOACs are a rare cause of massive hemoptysis, they should definitely be included in the differential diagnosis because such a condition is both a diagnostic and therapeutic challenge in patient care.

**Keywords:** Anticoagulant, Bronchoscopy, Hemoptysis



---

## **Lactating woman with primary adrenal insufficiency – case report**

Matej Lovrić<sup>1</sup>, Franciska Lovrić<sup>1</sup>, Petra Kovačević<sup>1</sup>, Branko Šego<sup>2</sup>, Kamelija Horvatović<sup>3</sup>, Ante Mandić<sup>1,4</sup>

<sup>1</sup>*School of Medicine, University of Mostar, Mostar, Bosnia and Herzegovina*

<sup>2</sup>*Faculty of Medicine, University of Osijek, Osijek, Croatia*

<sup>3</sup>*Faculty of Science, University of Zagreb, Zagreb, Croatia*

<sup>4</sup>*University Clinical Hospital Mostar, Mostar, Bosnia and Herzegovina*

**Corresponding author:** Matej Lovrić, matej.lovric007@gmail.com

---

**Introduction:** Primary adrenal insufficiency (PAI) or Addison's disease is a rare, usually progressive hypofunction of the adrenal cortex. It is characterized by hypotension, general weakness, electrolyte imbalance and hyperpigmentation. PAI may cause adrenal crisis with cardiovascular collapse. Etiology is associated with autoimmune diseases, infectious diseases, infiltration of metastatic tumors, and drugs that inhibit cortisol biosynthesis. The diagnosis is based on the clinical presentation, low cortisol concentration and elevated ACTH.

**Case report:** A 38-year-old lactating woman was referred to the Department of internal medicine due to fatigue and weight loss. Two months prior to admission, patient had a premature birth. After that, patient began to feel worse, had a loss of appetite, and fever with elevated inflammatory biomarkers. Antimicrobial therapy was administered by infectious disease specialist. However, patient still felt unwell, lost about 10 kg of body weight, and had muscle weakness. Lower blood pressure values were measured and hypoglycemia was reported. Otherwise, during pregnancy, patient noticed that her skin was diffusely hyperpigmented, without previous sunbathing. At admission, the patient was hypotensive and tachycardic with mild hyponatremia. Cortisol concentration was extremely low and ACTH was elevated. After administration of parenteral hydrocortisone therapy, there was a significant improvement in the patient's condition.

**Conclusion:** The clinical presentation of adrenal insufficiency is variable and diagnosis is often delayed, so it is very important to raise awareness of this rare disease.

**Keywords:** Adrenal insufficiency; Adrenocorticotrophic Hormone; Lactation.

---

## Diabetic ketoacidosis and acute heart failure in patient with comorbidities-case report

Nejira Imamović<sup>1</sup>, Azra Dervišbegović<sup>1</sup>, Bilal Oglečevac<sup>2</sup>

<sup>1</sup>Faculty of Medicine, University of Sarajevo, Sarajevo, Bosnia and Herzegovina

<sup>2</sup>General Hospital «prim. dr. Abdulah Nakaš», Sarajevo, Bosnia and Herzegovina

**Corresponding author:** Azra Dervišbegović, azradervisbegovic16@gmail.com

---

**Introduction:** Diabetic ketoacidosis is an acute complication of diabetes characterized by hyperglycemia (leading to osmotic diuresis with significant loss of fluids and electrolytes), hyperketonemia and metabolic acidosis. It causes nausea, vomiting, and abdominal pain and can progress to cerebral edema, coma and death. Acute heart failure is defined as rapid onset of new or worsening of pre-existing signs and symptoms of heart failure – breathlessness, edemas, fatigue and many more.

**Case report:** A 84-year-old female patient presents to the Emergency Room (ER) as dyspneic, pale, adynamic, with pretibial edema and peripheral oxygen saturation (SpO<sub>2</sub>) of 66%. She presented to the ER 16 days earlier, with blood glucose levels of 23.6mmol/L, ketonuria and a C-reactive protein of 68. In the meantime, she broke her pubic bone. CXR (Chest x-ray) showed a large left pleural effusion and hypostatic pneumonia, as well as a heart-thorax ratio greater than 1:3, blood tests showed again high blood glucose, a rise in non specific inflammatory markers, severe anemia with hematocrit of 0.25, acidosis and ketonuria. She was taken as an inpatient in the intensive care unit (ICU), intubated at the site, since oxygen support alone was not enough. Later, she became mechanical-ventilation-dependent and hemodynamically unstable, underwent many diagnostic procedures and therapeutic protocols due to her concomitant comorbidities; which also included chronic pulmonary emphysema, recurrent cerebrovascular accidents, deafness and adjustment disorders. After receiving all required supportive and antibiotic therapy for multi resistant microbes, she was released home after 83 days.

**Conclusion:** Diabetic ketoacidosis can arise as a result in dysregulation of blood glucose levels in shortage of intrinsic insulin or receptors' decreased sensitivity, but as well as from other metabolic, inflammatory and/or infectious causes and it should be treated as an emergency, especially in a complex patients, as it can result in a positive outcome.

**Keywords:** Case report, Diabetes mellitus, Heart failure, Ketoacidosis

---

## **Case report of the 83-year-old patient with acute myocardial infarction accompanied by ventricular tachycardia with pulse**

Lucija Kučina<sup>1</sup>, Senka Kajčić<sup>2</sup>

<sup>1</sup>*Faculty of Medicine, University of Rijeka, Rijeka, Croatia*

<sup>2</sup>*Emergency medicine institute of the Primorje-Gorski Kotar County, Rijeka, Croatia*

**Corresponding author:** Lucija Kučina, [Ikucijak18@gmail.com](mailto:Ikucijak18@gmail.com)

---

**Introduction:** Acute coronary syndrome is a condition that arises as a result of an acute obstruction of the coronary arteries, resulting in ischemia of the heart muscle. Ventricular tachycardia is a type of an arrhythmia that appears in the ventricular portions of the heart and is characterized as three or more consecutive heartbeats with a frequency of 120 beats per minute or higher.

**Case report:** In this case report, a 83-year-old patient will be treated for acute ventricular tachycardia with pulse caused by an ST-elevation myocardial infarction, which resulted in cardiac arrest. The patient was successfully resuscitated.

**Conclusion:** Team 1 Outpatient Ambulance initially cared for the patient. The ABCDE approach procedures were used, the SAMPLE anamnesis was performed, and the patient was treated according to the ALS protocol outlined in the European Resuscitation Council's guidelines.

**Key words:** Acute coronary syndrome, Ventricular tachycardia, ST-elevation myocardial infarction

---

## **Unsafe Handling of Fireworks as a Cause of Face and Eye Trauma – Case Report**

Bruno Gross<sup>1</sup>, Nikolina Morić<sup>2</sup>, Jakov Končurat<sup>3</sup>, Tina Herljević<sup>1</sup>, Silva Šiftar<sup>1</sup>,  
Emil Klarić<sup>1</sup>

<sup>1</sup>*Emergency Medicine Institute Zagreb County, Velika Gorica, Croatia*

<sup>2</sup>*Faculty of Medicine, Rijeka, Croatia*

<sup>3</sup>*Emergency Medicine Institute Zadar County, Posedarje, Croatia*

**Corresponding author:** Bruno Gross, bruno\_gross@ymail.com

---

**Introduction:** Firework injuries are a relatively uncommon, but frequently devastating cause of trauma that requires ambulance intervention and admittance to the emergency room (ER). The type of damage can vary, but usually it is a combination of blunt trauma, explosive trauma and combustion damage. Virtually every case requires a multidisciplinary approach due to the wide array of affected tissues. Almost all cases of firework injuries can be avoided, but unfortunately, citizen education, government measures and law enforcement are seemingly unable to address this issue. We present a case of face trauma due to firework mishandling.

**Case report:** A 20-year-old patient was transported to the emergency room (ER) following an injury caused by fireworks. The accident happened in front of his home on New Year's Eve. He suffered a blow to the head from the projectile which then flew away, burning both eyes and part of his face. The patient had lacerations and major swelling of the face and lips, both eyes were full of debris. During transport, his face was cleaned, eyes rinsed with saline, which revealed significant damage. Following debridement and antibiotic treatment, he reported having no eyesight problems.

**Conclusion:** We presented a firework-associated trauma case which was at first assumed to have caused major eye damage. However, following treatment, there appears to be no lasting damage. This case highlights the unreliability of macroscopic visual assessment of injuries by medical professionals and the importance of objective and specialised workup.

**Key words:** Lacerations, Eye injury, Trauma

---

## **Case report: Gunshot wound of the Thorax with an excellent outcome**

**Nika Ribarić<sup>1</sup>**, Marina Baran<sup>2</sup>, Klara Kuzman, Daniel Rajačić<sup>3</sup>

<sup>1</sup>*School of Medicine, University of Zagreb, Zagreb, Croatia*

<sup>2</sup>*Department of Surgery, University Hospital Centre Zagreb, Zagreb, Croatia*

<sup>3</sup>*Department of Surgery, University Hospital Centre Zagreb, Zagreb, Croatia*

**Correspondent author:** Nika Ribarić, nikaribaric2011@gmail.com

---

**Introduction:** Gunshot wounds of the thorax require urgent surgical care. Common resulting injuries are pneumothorax and haemothorax, injuries of the aorta, and the tracheobronchial tree. This case report presents a patient who managed to elude all of these fatal injuries.

**Case report:** The patient was admitted to the emergency room (ER) for a gunshot wound to the thorax. While cleaning a small caliber pistol, the patient accidentally shot himself. The patient was conscious and hemodynamically stable. The entry wound was located at the right pectoral muscle, at the fourth intercostal space with an angulation to the right shoulder. Gunpowder residue and local burns were noted. An emergent computed tomography (CT) angiography was done to assess vascular, cardiac, and pulmonary injuries. There were no signs of pneumothorax, injuries of the lung and no visible contrast extravasation. There were no fractures of the thoracic skeleton. The bullet was located subcutaneously, close to the scapular bone. After ruling out life-threatening injuries, the bullet was extracted through an individual incision under local anesthesia. Wound dressing and primary wound closure were performed. The patient was discharged from the hospital the next day, with antibiotic therapy, analgesics and strict instructions to rest.

**Conclusion:**

While gunshots to the thorax are closely correlated with high mortality and immediate emergency surgery. Extent of injuries depends, among others, on the caliber size, distance from firearm, and angle. Observation is mandatory in these patients due to the risk of delayed pneumothorax and occult vascular injuries.

**Keywords:** Accidents, Gunshot wounds, Penetration, Thoracic Injuries

---

## **Hypovolemic shock as a complication of ulcerative colitis**

Lucija Karaman<sup>1</sup>, Leonardo Hršak<sup>1</sup>, Kristina Baraba-Dekanić<sup>2</sup>

<sup>1</sup>*University of Rijeka, Faculty of Medicine, Rijeka, Croatia*

<sup>2</sup>*Clinical Hospital Center Rijeka, Rijeka, Croatia*

**Corresponding author:** Lucija Karaman, lucija.karaman15@gmail.com

---

**Introduction:** Ulcerative colitis is a chronic inflammatory bowel disease in which abnormal reactions of the immune system cause inflammation and ulcers on the inner lining of a large intestine. Ulcerative colitis can begin gradually and become worse over time. Hypovolemic shock is considered present when severe hypovolemia results in organ dysfunction as the result of inadequate tissue perfusion due to loss of blood or extracellular fluid.

**Case report:** 17-year-old patient was hospitalized due to hypovolemic shock induced by ulcerative colitis which was diagnosed 2 weeks ago. In patient's medical history it was noted that, two days before hospitalization, patient had high a fever and multiple bloody stool. On the day of hospitalization, he didn't have a fever, but he started to throw up and had 15 stools. During clinical examination, patient was tachycardic, tachypneic, with low blood pressure and prolonged time of recapillarization. He was of poor general condition, with pale grey skin-tone and dry mucous membranes. Clinical examination and initial diagnostic tests indicated that the patient was in the state of hypovolemic shock and developed acute kidney injury. During the hospitalization, the patient was initially given intravenous rehydration therapy. His initial response was good, but his condition deteriorated during the first night, after which he was transferred to the intensive care unit. Following morning, after it was concluded that the patient didn't have toxic megacolon and infection, he was given intravenous corticosteroids which rapidly improved his condition. After his condition stabilized, patient was transferred to the department of gastroenterology where he remained until he was released home.

**Conclusion:** Hypovolemic shock can occur as a complication of ulcerative colitis. Hypovolemic shock can be induced very rapidly and patients may, on the first glance, look as their condition is improving but we should always cure the primary disease because it can influence the general condition and the severity of the complications as this case showcases.

**Keywords:** Inflammatory bowel disease, Hypovolemic shock, Ulcerative colitis

---

## **Torsades de pointes associated with acute ST-elevation myocardial infarction: a case report**

**Iva Kovačević<sup>1</sup>, Danijel Lugonjić<sup>1</sup>, Marinka Otočan<sup>2</sup>**

<sup>1</sup>*University of Rijeka, Faculty of Medicine, Rijeka, Croatia*

<sup>2</sup>*Emergency Medicine Department, Clinical Hospital Center Rijeka, Rijeka, Croatia*

**Corresponding author:** Iva Kovačević, iva.kovacevic22@gmail.com

---

**Introduction:** Torsades de pointes (TdP) is a form of polymorphic ventricular tachycardia (VT) that occurs in the setting of QT interval prolongation, acquired or congenital. TdP is typically characterized by a heart rate between 160 and 250 beats per minute, an antecedent prolonged QT interval, irregular RR intervals, and oscillatory changes in the amplitude of the QRS complexes around the isoelectric line every 5 to 20 beats. TdP typically terminates spontaneously but most patients experience multiple episodes which can recur in rapid succession and potentially degenerate to VF and sudden cardiac death.

**Case report:** A 41-year-old male presented to the emergency department (ER) with chest pain that occurred at rest. In the ER, VF and TdP occurred and direct current (DC) cardioversion was performed in 8 repeats with intermittent return of spontaneous circulation. The patient received a total of 4g magnesium sulfate and 300mg amiodarone. The patients had an acute ST-elevation myocardial infarction of the anteroseptal wall. Emergency coronary angiography was performed followed by primary percutaneous coronary intervention with stent placement in the anterior descending branch of the left coronary artery. The patient became rhythmically and hemodynamically stable without support. Optimal performance was achieved. Slightly reduced systolic function of the left ventricle was verified by echocardiography. During the day and at discharge, the patient was in good general condition, cardially compensated, normotensive, without abdominal pain, Glasgow Coma Scale (GCS) score of 15.

**Conclusion:** Torsades de pointes is a life-threatening arrhythmia, which occurs in the settings of acquired or congenital QT interval prolongation. For proper treatment, it is essential to be up to date with current management guidelines as well as preventing its onset by targeting modifiable risk factors.

**Keywords:** Cardiac arrhythmias, Myocardial infarction, Sudden cardiac death, Tachycardia, Torsades de Pointes

---

## **Nonconvulsive status epilepticus in comatose patient - case report**

Dea Sabo<sup>1</sup>, Jelena Šarić Jurić<sup>2</sup>; Stjepan Jurić<sup>1,2</sup>

<sup>1</sup>*Faculty of Medicine, Josip Juraj Strossmayer University of Osijek, Osijek, Croatia*

<sup>2</sup>*Department of Neurology, University Hospital Center Osijek, Osijek, Croatia*

**Corresponding author:** Dea Sabo, dea.sabo7@gmail.com

---

**Introduction:** Nonconvulsive status epilepticus (NCSE) is a status defined by continuous or repetitive seizures without convulsions that last from 5 to 10 minutes without recovery of consciousness between the seizures. In comatose patients, NCSE is defined as a status with more than 30 minutes of ictal electroencephalography (EEG) in an hour of recording. It's a status that in a short time can cause long-term consequences, such as neuronal death and neuronal damage. We present a case of a comatose patient with nonconvulsive status epilepticus.

**Case report:** An eighty-four-year-old woman is brought to the emergency department after a sudden loss of consciousness with a Glasgow Coma Scale (GCS) of 3. The previous history did not show any neurological issues. Neurologically, there are no signs of neck stiffness, pupils are narrow and react slowly to light, there is no spontaneous nystagmus or facial paresis. All extremities fall symmetrically to the base from the antigravitational position. The Babinski reflex is positive on both sides. The blood test shows a high C-reactive protein level and a high D-dimer level. The cerebrospinal fluid test shows a low protein level. The brain computed tomography (CT) and CT angiography are normal. EEG shows generalized periodic discharges. The brain MRI shows supratentorial cortical hyperintensities in the brain, which corresponds to encephalitis. The treatment included anticonvulsants levetiracetam and lacosamide, as well as antibiotic treatment with acyclovir.

**Conclusion:** Since brain damage occurs swiftly as a result of status epilepticus, it is important to start treatment promptly. Even though an EEG is essential in order to diagnose NCSE, there is no pathognomonic EEG model for this disorder. In non-comatose patients, treatment must begin if NCSE is suspect (based on the clinical condition), without waiting for the EEG results. In comatose patients, EEG is the only diagnostic method, which causes delays in treatment and more serious consequences for the patient.

**Keywords:** Coma, Epilepsy, Seizures



---

## Subarachnoid haemorrhage and mesencephalic ischemia diagnosed via lumbar puncture-case report

Alen Šarić<sup>1</sup>, Ivana Žitinić(mentor)<sup>2</sup>

<sup>1</sup>*Faculty of Medicine, University of Rijeka, Rijeka, Croatia*

<sup>2</sup>*Clinical Hospital Center Rijeka, Department of Emergency Medicine, Rijeka, Croatia*

**Corresponding author:** Alen Šarić, asaric2@student.uniri.hr

---

**Introduction:** Subarachnoid haemorrhage (SAH) is defined by presence of blood between arachnoid layer and deepest meningeal layer-pia mater. It is mostly caused by ruptured aneurism and diagnosed with CT-scan in 95% of cases. The rare cases that have negative CT-scan are diagnosed by lumbar puncture (LP) which will show large number of erythrocytes in cerebrospinal fluid (CSF) with increased quantity of proteins.

**Case report:** Case that is presented showed typical clinical presentation of SAH that include severe headache, signs of meningism (in this case neck stiffness and nausea) and impaired consciousness. This case is important because it is one of rare cases with negative CT-scan without contrast and negative CT angiography, but lumbar puncture confirmed diagnosis of SAH. In addition, this patient had ischemic lesion in mesencephalon, which was proved on MRI scan, but without any specific symptoms of ischemia in that part of the brain. The patient spent 7 days in hospital care that include antithrombotic therapy, gastroprotection, lipid-lowering agents and antihypertensive therapy. At the discharge patient made full recovery without any permanent neurological deficit. Also, cardiological assessment was recommended to find a cause of thrombotic ischemia and follow-up visits at the neurologist.

**Conclusion:** Head CT has very high specificity and sensitivity in detecting SAH, but negative CT-scan should not distract us from right diagnosis if we have strong clinical findings that guide us towards the diagnosis of SAH. In case of negative CT-scan, LP is necessary instrument to confirm or exclude diagnosis of SAH and we should not be feared of using that method.

**Keywords:** Brain ischemia, Cerebrospinal fluid, Spinal puncture, Subarachnoid haemorrhage

---

## General weakness as a manifestation of hyperkalemia and hyponatremia in a patient with chronic kidney disease and polypharmacy

Josipa Živko<sup>1</sup>, Đidi Delalić<sup>2</sup>, Ingrid Prkačin<sup>1,2</sup>

<sup>1</sup>*Clinical hospital Merkur, Zagreb, Republic of Croatia*

<sup>2</sup>*University of Zagreb School of Medicine, Zagreb, Republic of Croatia*

**Corresponding author:** Josipa Živko, josipa.zivko96@gmail.com

---

**Introduction:** Electrolyte abnormalities are frequent pathology in the emergency departments, with emergency medicine physicians being well trained to recognize and treat the various presentations of those abnormalities. Still, treatment is only a part of the puzzle, with most electrolyte abnormalities having an underlying cause which, if left unaddressed, often leads to recurring abnormalities and potentially fatal outcomes.

**Case report:** This case report describes a 66-year old female patient with a history of chronic kidney disease presenting to the emergency ward with general weakness and bradycardia. The physical exam did not display any significant pathology. Laboratory test results showed a combined electrolyte disorder, with both hyponatremia and hyperkalemia present. The electrolyte disorder was properly managed, following the standard management algorithms for hyponatremia and hyperkalemia. During the patient's stay in the emergency department, it has been found out by inspecting the patient's medical documentation that there was a disparity between the information obtained during the history taking process and the documentation itself - the patient had been taking eplerenone twice a day instead of twice a week. This overdose had an additional contribution to existing factors leading to electrolyte abnormalities, including chronic kidney disease and polypharmacy.

**Conclusion:** Emergency room visits like the one described in this case can be easily prevented by taking the time to explain the patient's therapy to them and helping them understand how much of which medication to take and when. Monitoring the patient's compliance by way of regular visits to the family physician is also desirable. The question we can ask ourselves is if a properly treated acutisation or complication of an improperly managed chronic condition is a success for emergency medicine or a failure of the healthcare system as a whole in preventing the undesirable event in the first place.

**Keywords:** Bradycardia, Hyperkalemia, Hyponatremia

---

## Management of supraventricular tachycardia in pre-hospital emergency care - Case report

Tina Herljević<sup>1</sup>, Nikolina Morić<sup>2</sup>, Emil Klarić<sup>1</sup>, Jakov Končurat<sup>3</sup>, Silva Šiftar<sup>1</sup>, Bruno Gross<sup>1</sup>

<sup>1</sup>*Emergency Medicine Institute Zagreb County, Velika Gorica, Croatia*

<sup>2</sup>*Faculty of Medicine, Rijeka, Croatia*

<sup>3</sup>*Emergency Medicine Institute Zadar County, Posedarje, Croatia*

**Corresponding author:** Tina Herljević, tinaherljevic@hotmail.com

---

**Introduction:** Paroxysmal supraventricular tachycardia (PSVT) is a type of cardiac arrhythmia that occurs when a short circuit rhythm develops in the atria. That results in a regular but rapid heartbeat that starts abruptly and can stop either spontaneously, using certain maneuvers or using medication.

**Case report:** 56-year old male patient presented with palpitations and feeling of pressure in the chest area. The symptoms had rapid onset and lasted for about 3 hours. His blood pressure was 130/80 mm Hg, SpO<sub>2</sub> 94%, pulse rate 194 bpm. He didn't report having any chronic illnesses but he has been treated for PSVT on few occasions. Electrocardiogram (ECG) showed regular tachycardia, heart rate 190 bpm, with narrow QRS complexes. After confirming the diagnosis we unsuccessfully tried to slow the episode of PSVT using vagal maneuvers and carotid sinus massage. After that we put two intravenous cannulas in both cubital veins. We put saline on the right venous route. We administered 6 mg of adenosine in a fast intravenous injection followed by 20 ml of saline on the left venous route. Heart rate slowed down to 180 bpm but we didn't manage conversion. After a few minutes we repeated the adenosine injection, this time doubling the dose (12 mg) which caused conversion to normal sinus rhythm. Patient experienced mild dizziness and nausea after which he reported the regression of initial symptoms. His blood pressure was 115/80 mmHg, SpO<sub>2</sub> 97%, heart rate 94 bpm. He was observed for about 40 minutes after the conversion after which he was discharged with the recommendation of a regular cardiologist check-up.

**Conclusion:** In this case we presented a typical example of PSVT episode which was treated in pre-hospital emergency medical care. In this case patient already had a diagnosis and was already converted a few times using the same protocol. We could afford to observe him for some time after the conversion to make sure he didn't have any symptoms so in this case hospitalization was not required.

**Keywords:** Adenosine, Arrhythmia, Vagal nerve stimulations, Supraventricular tachycardia

---

# POSTER PRESENTATIONS

---



---

## **Case report: Pulmonary embolism**

Nika Jurić<sup>1</sup>, Elena Hegna<sup>2</sup>, Helena Smokrović<sup>3</sup>

*<sup>1</sup>University of Rijeka, Faculty of Medicine, Rijeka, Croatia*

*<sup>2</sup>University of Rijeka, Faculty of Medicine, Rijeka, Croatia*

*<sup>3</sup>Department of Pulmonology, Clinic of Internal Medicine, Clinical Hospital Center Rijeka, Rijeka, Croatia*

Corresponding author: Nika Jurić, nikajuric66@hotmail.com

---

**Introduction:** Pulmonary embolism is an emergency condition caused by obstruction of a pulmonary artery or one of its branches. In most cases, it is caused by blood clots that travel to the lungs from deep veins in the legs. This condition is marked by labored breathing, chest pain, fainting, rapid heart rate, cyanosis, shock and sometimes death.

**Case report:** A 62-year old woman presented to the emergency room (ER) with dyspnea, weakness and chest pressure. She was tachycardic and hypoxemic with elevated blood C-reactive protein (CRP), glucose and leukocytosis. Also, NT-proBNP levels were higher than normal. The patient was hospitalized 2 years ago for aseptic cerebral venous thrombosis, intracerebral and subarachnoid hemorrhage. She stopped taking anticoagulant therapy. During the auscultation, decreased respiratory sound was noticed in the right base. An X-ray detected consolidations of unclear etiology. Patient was referred with computed tomography (CT) pulmonary angiography which discovered multiple pulmonary infarctions and signs of pulmonary hypertension. This was followed by an emergency echocardiography which showed pulmonary trunk dilatation and floating thromb in the right pulmonary artery. Also, venous ultrasound revealed deep popliteal venous thrombosis of the left leg. Due to previous intracranial hemorrhage, fibrinolytic therapy was contraindicated. The patient was treated with enoxaparin and antibiotics.

**Conclusion:** Pulmonary embolism is a life-threatening emergency which requires immediate hospitalization and proper treatment. Since dyspnea may be the leading symptom, it's important not to overlook this condition, especially with patients with a positive history of embolism.

**Keywords:** Pulmonary embolism, Pulmonary hypertension, Venous thrombosis

---

## Case report: Peptic Ulcer Perforation

Dora Jurić<sup>1</sup>, Klara Vranešević<sup>2</sup>, Dorian Kršul<sup>3</sup>

*<sup>1</sup>University of Rijeka, Faculty of Medicine, Rijeka, Croatia*

*<sup>2</sup>University of Rijeka, Faculty of Medicine, Rijeka, Croatia*

*<sup>3</sup>Department of Abdominal Surgery, Clinical hospital Center Rijeka, Rijeka, Croatia*

**Corresponding author:** Dora Jurić, dora.juric.dj@gmail.com

---

**Introduction:** Peptic ulcer is a lesion of the mucous surface of the digestive tract, typically in the stomach or duodenum, caused by the digestive action of pepsin and stomach acid. The common forms of peptic ulcers are associated with *Helicobacter pylori* and consumption of nonsteroidal anti-inflammatory drugs (NSAIDs). Peptic ulcer perforation is a serious complication of peptic ulcer in which penetration through the wall of the gastrointestinal tract is allowing the leakage of luminal contents into the peritoneal cavity.

**Case report:** An 80-year old female patient presented to the emergency room (ER) with an acute onset of abruptly formed epigastric pain that woke her up at 1 AM. Pain was dull, persistent and severe, 10/10 on VAS scale (visual analog scale). Patient denies nausea, vomiting or loss of consciousness. Owing to shoulder pain, the patient was taking NSAIDs for the last month. Bowel movement is normal in terms of frequency, color and consistency. She was afebrile with normal blood pressure, sinus rhythm and lower oxygen level (92%). Abdomen was painful in the epigastric area, without any palpable masses. Laboratory findings showed elevated C-reactive protein (CRP) (40 mg/L), leukocytosis ( $29 \times 10^9/L$ ), glucose, urea and creatinine. Patient was referred to an abdominal computed tomography scan (CT) where focal thickening of the antral gastric wall was detected. A collection of air anterior to the liver indicates pneumoperitoneum. Emergency exploratory laparotomy, perforation suturing and omental patch repair with lavage and drainage of peritoneal cavity was performed. Patient was admitted and treated with antibiotic, analgesic and gastroprotective medication and had uneventful recovery.

**Conclusion:** Gastrointestinal perforation with leakage into peritoneal cavity is a surgical emergency and may be life threatening. The majority is from spontaneous perforation due to peptic ulcer disease. Surgical techniques are varied, but laparotomy and omental patch repair remains the gold standard. Laparoscopic surgery may be considered when expertise is available.

**Keywords:** Anti-inflammatory agents, Emergency, Non-Steroidal, Peptic ulcer perforation

---

## Case report – Polytrauma with cardiopulmonary arrest

Maša Kopušar<sup>1</sup>, Klara Poldan Skorup<sup>2</sup>

<sup>1</sup>*Faculty of Medicine, University of Rijeka, Croatia*

<sup>2</sup>*Department of Emergency Medicine, Clinical Hospital Centre Rijeka, Rijeka, Croatia*

**Contact:** Maša Kopušar, Kopusar.masa10@gmail.com

---

**Introduction:** Polytrauma is one of the most complicated injuries of the human body. It is defined as cases with an Abbreviated Injury Scale  $\geq 3$  for two or more different body regions and one or more additional variables from five physiologic parameters (hypotension, Glasgow Coma Scale (GCS)  $\leq 8$ , acidosis, coagulopathy and age  $\geq 70$ ).

**Case report:** A 56 year old male was taken by the ambulance to the Emergency Department (ED). Vital parameters measured in the ambulance vehicle were: blood pressure (BP) 140/80, heart rate 85 bpm, SpO<sub>2</sub> 60% and blood sugar 10.5 mmol / L. During the physical examination in the ED, the patient was unconscious, GCS was 6, the pupils were narrow, symmetrical, non-reactive to light and open injuries of the scalp were found on the temporo-occipital region. Deformity of the left hemithorax, palpable crepitation and weakened breathing were noted during examination. He was breathing independently with rhythmic heart action and absent peripheral pulse. The abdomen was hard and tense. Limbs were without visible injuries and the skin was pale and cold.

FAST ultrasound was urgently initiated to confirm the existence of left hemopneumothorax and the presence of free fluid in the abdomen. When vital parameters were remeasured, BP was as immeasurable as SpO<sub>2</sub>, pulse peripherally impalpable.

The patient was orotracheally intubated and placed on mechanical ventilation, the thoracic drain of the left hemithorax was placed and blood was obtained. The patient was administered parenteral hydration with balanced crystalloid, 2 doses of erythrocytes and 1 gram tranexamic acid.

Soon after, cardiopulmonary arrest with the initial rhythm of pulseless electrical followed. Cardiopulmonary resuscitation measures were initiated, but despite the implemented measures death was declared.

**Conclusion:** Despite the advances in medicine, polytrauma remains a major challenge for the health professionals themselves and the health care system. Although diagnostic medicine and guidelines have significantly improved over the years, some injuries are simply too severe and result in negative outcomes.

---

**Keywords:** Cardiopulmonary arrest, Hemopneumothorax, Multiple trauma, Tranexamic acid

---

## Post-traumatic duodenal hematoma – case report

Maja Kos<sup>1</sup>, Marta Lauda<sup>1</sup>, Harry Nikolić<sup>1,2</sup>

<sup>1</sup>Faculty of Medicine, University of Rijeka, Rijeka, Croatia

<sup>2</sup>Pediatric Surgery Clinic, University Hospital Centre Rijeka, Rijeka, Croatia

**Corresponding author:** Maja Kos, maja.kos3@gmail.com

---

**Introduction:** Post-traumatic duodenal hematoma is a condition caused by the blunt, compressive trauma to the abdomen. Although isolated duodenal injury is very rare, untreated it can lead to sepsis, intra-abdominal abscesses, and very high morbidity rate. This paper aims to emphasize the importance of prompt diagnostic evaluation and management of abdominal injuries, which are the utmost challenge in surgery.

**Case report:** A 16-year-old boy presented to the emergency room complaining of epigastric pain and vomiting after getting hit by a ball at a basketball game. On arrival his vital parameters were normal with exception of hyperventilation, pale skin, and painful abdominal region. Initial check-up of laboratory parameters showed mild increase of glucose, urea, and conjugated bilirubin along with increased alpha amylases and inflammatory parameters. Patient was diagnosed with acute pancreatitis and transferred to the Paediatric Surgery Department for further observation and conservative treatment. Ultrasound showed possible lesion and was supplemented by computed tomography (CT) showing signs of retroperitoneal hematoma together with intra-abdominal haemorrhagic content. Due to severe pain the boy was prescribed analgesic and antibiotic therapy as prevention to possible sepsis. Magnetic resonance (MR) and small bowel follow-through were conducted, as result of mild increase in liver and pancreas enzymes, that showed narrowing of descending duodenal flexure. During further treatment several gastroenterological examinations and nutritional observations were performed additionally with laboratory check-ups and control ultrasounds. Patient was gradually transferred to a liquid parenteral supplementation diet. Given the good general condition, in addition to normal vital and inflammatory parameters along with liver and pancreas enzymes, the boy was discharged by the end of the third week of treatment.

**Conclusion:** Laboratory parameters and ultrasound are not enough for clinical decision making. It is vital to take quality history, particularly when trauma is suspected. Moreover, it is crucial to broaden medical assessment and include as many selective examinations, especially in the paediatric population which is prone to trauma that is not always easy to diagnose.

**Key words:** Duodenum, Hematoma, Pancreatitis, Trauma



---

## A Rare Case of Left Anterior Descending Artery Stent Overlap Rupture and Repeat Coronary Angiography with Multivessel Coronary Artery Disease

Luka Košak<sup>1</sup>, Davorka Lulić<sup>2</sup>, Vjekoslav Tomulić<sup>3</sup>

<sup>1</sup>*Faculty of medicine, University of Rijeka, Rijeka, Croatia*

<sup>2</sup>*Clinic for Cardiovascular Diseases, Clinical Hospital Centar Rijeka, Rijeka, Croatia*

<sup>3</sup>*Clinic for Cardiovascular Diseases, Clinical Hospital Centar Rijeka, Rijeka, Croatia*

**Corresponding Author:** Luka Košak, luka.kosak4@gmail.com

---

**Introduction:** Coronary perforation is a life-threatening complication of percutaneous interventions. Angiographic evidence of perforation has been reported in 0.1% to 3.0% of the lesions treated with various intervention techniques. When the typical conservative method (ie, extended balloon inflation and reversal of anticoagulation) fails, covered stents have emerged as a therapy option<sup>1</sup>. Repeat coronary angiography should be reserved for those with objective evidence of spontaneous or provokable ischemia<sup>2</sup>.

**Case report:** A 54-year-old female presented with a history of chest pain radiating to interscapular region and left arm followed by nausea. The patient feels prolonged chest pressure during physical activity. She suffered from arterial hypertension, with bad medication adherence. Electrocardiogram (ECG) performed in emergency department (ED) shows anteroseptal ST-elevation myocardial infarction (STEMI) which is indication for primary percutaneous coronary intervention (PCI). Emergent coronary angiography showed atherosclerotic lesions in left and right coronary arteries with acute occlusion of left anterior descending artery (LAD) and preocclusive stenoses of first and second diagonal branches. The PCI has been complicated by perforation of the LAD at the point of overlap of two stents placed in the proximal and middle segment. The complication has been successfully controlled with inflation of balloon catheter and repaired with graft stent implantation. A year later, the patient experienced similar symptoms and was diagnosed with unstable angina. The patient's medical history indicated that a repeat coronary angiography was required, which revealed left main coronary artery (LMCA) stenosis, LAD in stent restenosis (ISR), poststent LAD and ostial stenosis of left coronary circumflex (LCx) artery. ISR in LAD was treated with application of drug coated balloons (DCB). Two drug eluting stents (DES) deployed in "mini crush" method, followed by "kissing" post dilatation and proximal optimization technique (POT) were used for left main stenosis.

**Conclusion:** The most effective technique to treat coronary artery rupture is stent graft implantation. Secondary prevention of acute coronary syndrome decreases the risk of restenosis and subsequent problems, firstly through lifestyle habits and medication adherence.

**Keywords:** Case report, Myocardial infarction, Rupture, Coronary artery disease

---

## Central retinal artery occlusion as emergency condition – case report

Petra Kovačević<sup>1</sup>, Matej Lovrić<sup>1</sup>, Nika Samardžić<sup>1</sup>, Ana Didović Pavičić<sup>2</sup>

<sup>1</sup>University of Mostar School of Medicine, Mostar, BiH

<sup>2</sup>General Hospital Zadar, Zadar, Croatia

Corresponding author: Petra Kovačević, petra.kovacevic110@gmail.com

---

**Introduction:** Central retinal artery occlusion (CRAO) refers to blockage of the retinal artery carrying oxygen to the nerve cells in the retina at the back of the eye. Most of the cases present with sudden painless loss of vision. CRAO occurs due to blockage of the retinal artery, often by an embolus or thrombus. The presentation of CRAO is associated with a variety of medical conditions. CRAO is usually diagnosed by an examination of the eye fundus in mydriasis that shows a “cherry-red spot,” where the centre of the macula appears red, with the surrounding retina pale due to the lack of blood flow. There is no clinically proven treatment for CRAO. Several therapies may be used including anterior chamber paracentesis and ocular massage to lower the intraocular pressure. For any treatment to be potentially effective it must be deployed within 4 to 6 hours after onset of symptoms.

**Case presentation:** A 68-year old woman was admitted to the department of emergency medicine due to sudden painless visual loss in the left eye. On examination visual acuity of light – perception was noted in the left eye with a left relative afferent pupillary defect. Fundoscopic examination revealed retinal ischemic whitening constriction of the arteriole and venule with segmentation and typical “cherry-red spot” suggesting CRAO.

**Conclusion:** The CRAO is an emergency condition that requires a multidisciplinary approach. A patient with a CRAO has a markedly decreased survival rate, the main cause of death being heart-related problems. Risk factors control can contribute to prevention.

**Keywords:** CRAO, Ophthalmology, Painless loss of vision

---

## **Case report: Acute aortic dissection – from head to toe**

Matilda Pudić<sup>1</sup>; Antonija Raguž, MD<sup>2</sup>

<sup>1</sup>*School of Medicine, University of Zagreb, Zagreb, Croatia*

<sup>2</sup>*General Hospital “Dr. Josip Benčević”, Slavonski Brod, Croatia*

**Correspondent author:** Matilda Pudić, matilda.pudic@gmail.com

---

**Introduction:** Acute aortic dissection is a rare but often fatal condition. The most common clinical manifestation is the acute onset of severe chest or back pain, followed by variable organ ischemia and it is a state of inevitable life threat.

**Case report:** A 53-year old male patient, heavy smoker, with a history of hypertension, presented to the emergency department due to sudden epigastric pain, malaise and tingling sensations in both legs and arms respectively. Half an hour later, after arriving at the hospital, residual paresthesia and difficulties in movement of the right leg were noted. Physical examination revealed bradycardia, blood pressure 130/80 mmHg, heart and lung auscultation without significance. Both legs were considerably colder, and the puls was impalpable on the right leg. ECG showed no abnormalities. Due to the suspected stroke, the patient was initially referred to the neurologist. Computed tomography (CT) angiography revealed aortic dissection (Stanford type A, DeBakey type I) with an intimal flap and a false lumen extending within ascending aorta and aortic arch, including the brachiocephalic trunk, to the abdominal aorta. Another intimal flap was located on the aortic bifurcation with a double lumen extending throughout the right common iliac artery. Echocardiogram revealed mild aortic regurgitation. Patient was urgently transferred to the UHC Osijek, Department of Cardiac Surgery for further treatment.

**Conclusion:** Aortic dissection, the Great Masquerader, could easily be misdiagnosed due to the symptoms which mimic other more frequent conditions. Complete and rapid diagnostic and prompt management are crucial for positive outcome, even in the cases of comprehensive dissection.

**Keywords:** Aortic dissection, CT angiography, Paresthesia

---

## Possible malignant transformation of lesions in a patient with Brooke-Spiegler syndrome - case report

Klara Vranešević<sup>1</sup>, Nika Juric<sup>1</sup>, Bruno Popić<sup>2</sup>

<sup>1</sup> *University of Rijeka, Faculty of Medicine, Rijeka, Croatia*

<sup>2</sup> *Department of Maxillofacial and Oral Surgery, Osijek University Hospital Center, Osijek, Croatia*

**Corresponding author:** Klara Vranešević, klara.vranesevic@student.uniri.hr

---

**Introduction:** Brooke-Spiegler syndrome is a rare autosomal dominant condition associated with various nodular adnexal tumors localised on the face, scalp and neck. It predominantly affects women and typically manifests in early adulthood. Malignant transformation of lesions occurs in 5%-10% of all cases and is usually associated with enlargement, ulceration and bleeding.

**Case report:** A 43-year-old woman presented to the ER with severe bleeding from extensive and mutilating ulcero-infiltrative lesions on the parieto-occipital region and left temporal section of the head. Lesions destroyed 2/3 of the left auricle, filling the entire external auditory canal while also infiltrating the left parotid gland and sternocleidomastoid muscle. Peripheral paresis of the left facial nerve was visible on the skin of the face as well as multiple papular hemispherical changes on the upper lip and paranasal area. The patient stated that other members of their family had experienced equivalent skin changes. When asked how long the lesions had been present, the patient indicated that they had appeared approximately one year prior but had enlarged over time. To stop the bleeding, blood vessels were cauterised and the wound was dressed with hydrogen peroxide and Surgicel, following which the patient was hospitalised for further processing. MRI of the brain showed proliferative ex ulcerated tumor process of parieto-occipital epicranium, parasagittal parietal bone infiltration as well as dura and sagittal sinus infiltration. Histopathology report determined a combination of basal-cell and squamous-cell carcinoma, after which the patient underwent several rounds of immunotherapy.

**Conclusion:** Although cutaneous tumors are generally considered to be easily recognisable because of their visibility, neglected advanced skin neoplasms remain present, even today. Due to positive family history and a specific clinical presentation, this case is believed to be a malignant transformation of lesions within Brooke-Spiegler syndrome.

**Keywords:** Basal cell cancer; Facial paresis; Squamous cell cancer

---

## **COVID-19 in Children: A Case Report of Multisystem Inflammatory Syndrome (MIS-C)**

Roberto Diminić<sup>1</sup>, Andrija Dukić<sup>1</sup>, Kristina Lah-Tomulić<sup>2</sup>

<sup>1</sup>*University of Rijeka, Faculty of medicine, Rijeka, Croatia*

<sup>2</sup>*Clinical Hospital Center Rijeka, Department of Pediatrics, Rijeka, Croatia*

**Corresponding author:** Roberto Diminić, roberto.diminic@gmail.com

---

**Introduction:** In children, COVID-19 is usually a mild disease. However, in rare cases, children can be severely affected. This severe condition is called multisystem inflammatory syndrome in children (MIS-C; or pediatric multisystem inflammatory syndrome PMIS). The course of the disease can be quite severe, with many children requiring intensive care interventions.

**Case report:** In this case report a 16 year old male patient comes to the hospital with clinical signs of acute abdomen; pain in the lower right quadrant and high fever, suggestive of appendicitis. Although ultrasound findings were compatible with appendicitis, a CT scan did not show signs of acute appendicitis. Instead, it showed signs of mesenteric lymphadenitis. His clinical findings (abdominal pain, headache, high fever) and history of COVID-19 infection, one month prior, were compatible with MIS-C. This was later confirmed by laboratory findings. Since acute appendicitis was excluded, this patient no longer needed surgery, which could have only worsen his condition. The patient developed shock and acute kidney injury during his stay in the hospital. He required intensive care, monitoring and was given both specific and supportive therapy with a positive response.

**Conclusion:** This was an example of severe form of MIS-C, which required intensive care. As seen in this case, appendicitis can mimic MIS-C, so nowadays it is really important to think about MIS-C in differential diagnosis. Long-term follow-up data is limited, but the prognosis of MIS-C looks positive as most children have a full clinical recovery.

**Keywords:** Appendicitis, COVID-19, Critical care, Shock

---

## Case report: Simultaneous bilateral pneumothorax

Elena Hegna<sup>1</sup>, Dora Jurić<sup>1</sup>, Vuk Prica<sup>1,2</sup>

<sup>1</sup>University of Rijeka, Faculty of Medicine, Rijeka, Croatia

<sup>2</sup>Department of Pulmonology, Clinic of Internal Medicine, Clinical Hospital Center Rijeka, Croatia

**Corresponding author:** Elena Hegna, elena.hegna@gmail.com

---

**Introduction:** A pneumothorax is a collection of air outside the lung but within the pleural cavity. It occurs when air accumulates between the parietal and visceral pleura inside the chest where it can apply pressure on the lung and make it collapse. Simultaneous bilateral spontaneous pneumothorax is a rare condition occurring in up to 1.9% of cases of spontaneous pneumothorax. Risk factors include male sex, smoking, height and underlying lung conditions.

**Case report:** We present a case of 35-year-old male with sarcoma who presented to the ER with sudden bilateral chest pain and dyspnea. X- ray demonstrated bilateral pneumothorax with both lungs completely collapsed, alongside multiple pulmonary metastases from sarcoma. Chest tubes were inserted bilaterally and connected to Heimlich valve after which patient felt relief. Patient was admitted to Department of Pulmonology. Right side recovered completely and a chest tube was removed whereas the left side became worse and progressed into hydro-pneumothorax, which is why the active suction was placed. Both lungs expanded and patient was discharged with left side chest tube against medical advice 13 days after admission. Few hours after release patient comes back to the ER with progression of the symptoms. X- ray confirmed progression of right-side pneumothorax with partial collapse of the lung. Another chest tube was placed in his right hemithorax and patient was again discharged against medical advice with bilateral chest tubes. Patient was regularly controlled by a pulmonologist and was again admitted a month after and sadly died of the underlying condition.

**Conclusion:** Bilateral pneumothorax is a rare condition that can be associated with pulmonary metastases from sarcoma. Pneumothorax related to pulmonary metastases tends to be refractory to conventional therapy and needs surgical intervention to prevent recurrences. Oncologists need to be aware of this unusual metastasis during the follow-up of advanced sarcoma.

**Keywords:** Chest tubes, Neoplasm metastasis, Pneumothorax, Sarcoma

---

## **Hypokalemia in patient with ST elevations as a cause of cardiac arrest – Case Report**

Emil Klarić<sup>1</sup>, Nikolina Morić<sup>2</sup>, Jakov Končurat<sup>3</sup>, Tina Herljević<sup>1</sup>, Silva Šiftar<sup>1</sup>, Bruno Gross<sup>1</sup>

<sup>1</sup>*Emergency Medicine Institute Zagreb County, Velika Gorica, Croatia*

<sup>2</sup>*Faculty of Medicine, Rijeka, Croatia*

<sup>3</sup>*Emergency Medicine Institute Zadar County, Posedarje, Croatia*

**Corresponding author:** Emil Klarić, [klaric1995@gmail.com](mailto:klaric1995@gmail.com)

---

**Introduction:** Cardiopulmonary arrest (cardiac arrest, CA) is defined as the complete cessation of effective circulation and ventilation. Causes of CA, among others, can be myocardial infarction and hypokalemia. ST-segment elevation myocardial infarction (STEMI) is characterized by ST elevation finding on electrocardiogram (ECG), confirmed by coronography. Hypokalemia is defined as a level of serum potassium below 3,5 mmol/L, with specific ECG presentation including ST depression and U wave formation. We present an unusual case of electrolyte disbalance as a cause of CA.

**Case report:** A 75-year-old patient was transported to the emergency room following CA. At the scene the patient had suffered a loss of consciousness, respiration and pulse. The emergency team began providing basic life support (BLS) and after transporting the patient inside an ambulance advanced life support (ALS). Initially recorded rhythm was pulseless electrical activity (PEA), following 2 rhythms were ventricular fibrillations (VF), after that pulseless ventricular tachycardia (VT) followed by PEA on 4 occasions before the return of spontaneous circulation (ROSC). The patient was brought to the emergency room unconscious with palpable radial and central pulse and spontaneous respiration. In the emergency room on 2 occasions pulseless VT was recorded following synchronized cardioversion and return of sinus rhythm. On ECG ST elevation in avR and inferior leads was recorded. Due to the patient's prior ischaemic cardiomyopathy and ECG findings, emergent coronography was ordered. Coronography showed no acute thrombosis hence the cause of CA was diagnosed as electrolyte disbalance due to hypokalemia (K 2.3-2.9 mmol/L).

**Conclusion:** In this case, we presented an unusual case of electrolyte disbalance, with ST elevations and prior ischaemic cardiomyopathy suggesting STEMI as a cause of CA. Despite previous assumptions, the conclusion on the primary cause of CA was electrolyte disbalance. This case highlights the importance of carrying out thorough diagnostics, which can help diagnose the cause of CA.

**Keywords:** Heart arrest, Hypokalemia, STEMI

---

## **Flail chest after motorcycle accident – a case report**

Leo Matijašević<sup>1</sup>, Drago Marijanović<sup>2</sup>, Tomislav Žigman<sup>3</sup>

<sup>1</sup>*School of Medicine University of Zagreb, Zagreb, Croatia*

<sup>2</sup>*Department of Traumatology, University Hospital Centre Zagreb, Zagreb, Croatia*

**Corresponding author:** Leo Matijašević, leo.matijasevic@gmail.com

---

**Introduction:** Flail chest is a most life-threatening complication of blunt chest trauma defined as a fracture of three or more consecutive ribs broken in at least two places. It results in paradoxical movement of a segment of the chest wall during spontaneous breathing. It is noted during the physical exam and therefore considered a clinical diagnosis. Flail chest occurs in about 7% of chest trauma. The mortality ranges from 10% to 20%, often due to other accompanying injuries rather than the flail chest alone. Flail chest usually occurs among other injuries and is an excruciating condition.

**Case report:** A 34-year-old male sustained a motorcycle crash and was brought to the emergency clinic. He was admitted complaining about pain in the right hand and dyspnea. The patient was conscious (GCS 15) and hemodynamically stable. Blood gas analysis at presentation showed regular respiratory function. Physical examination showed crackles and an absence of breathing sound above the left hemithorax, paradoxical movement of the chest wall segment, a deformity of the right forearm, and an open wound of the right third finger. Computed tomography showed fractures from the second to ninth rib on the left side, fractures of the left transverse processes from the first to seventh thoracic vertebrae, extensive pneumothorax on the left, a contralateral shift in the structures of the mediastinum and a left hemothorax. Right arm X-ray showed Monteggia's fracture, fracture of the head of the radius, and an extensor tendon lesion of the third finger. The fractured hand was surgically taken care of, while the flail chest was treated conservatively. The patient's postoperative course was uneventful.

**Conclusion:** Traffic accidents usually cause polytrauma, and blunt chest trauma can result in flail chest. Conservative treatment is the treatment of choice for flail chest with stable respiratory function and tolerable pain.

**Keywords:** Accidents, Traffic, Flail chest, Hemothorax, Multiple trauma



---

## Ischaemic stroke – case report

Dora Padjen<sup>1</sup>, Paolo Salamon<sup>2</sup>, Mateo Borovac<sup>3</sup>

<sup>1</sup>*University of Rijeka, Faculty of Medicine, Rijeka, Croatia*

<sup>2</sup>*University of Rijeka, Faculty of Medicine, Rijeka, Croatia*

<sup>3</sup>*Department of Neurology, Clinical Hospital Centre Sestre milosrdnice, Zagreb, Croatia*

**Corresponding author:** Paolo Salamon, paolo.salamon12345@gmail.com

---

**Introduction:** Ischaemic stroke is a medical emergency resulting from an inadequate supply of blood and oxygen to the brain due to a blockage of an artery, often by a blood clot.

**Case report:** The patient, a 47 year old male, was admitted to the Neurointensive care unit after experiencing nausea, vertigo and fever, combined with speech impediment. The symptoms have been present for 15 days before the admission, and significantly intensified a day before he was brought to the Neurointensive care unit by the emergency services. The patients' wife stated that he had been drinking the day prior to the admission, followed by worsening of the symptoms. Although the differential diagnosis included alcohol abuse, the patients' symptoms rapidly magnified leading to a stuporous state (GCS 6) which required an emergency brain MRI and CTA. The imaging showed occlusion and stenosis of the left vertebral artery, as well as recent ischaemic lesions. After an urgent mechanical thrombectomy was performed, the patients' state slightly improves. Although the procedure seemed to have a satisfactory outcome, the patient remains somnolent and significantly visually impaired (homonymous hemianopsia). The patient was shortly afterwards transferred to the COVID-unit after his PCR test came back positive.

**Conclusion:** Typical symptoms of a cerebrovascular insult, such as face and arm paralysis, headache, trouble speaking, and lack of bladder control are not difficult to recognize. However, it is important not to ignore other acute neurological symptoms, because if not detected they can quickly progress to a fatal outcome.

**Key words:** Ischaemic stroke, Stupor; Thrombectomy

---

## Diabetic ketoacidosis in a 13 year old girl – case report

Tea Škoda<sup>1</sup>, Petar Žauhar<sup>1</sup>, Iva Vrsaljko<sup>2</sup>

<sup>1</sup>University of Rijeka, Faculty of Medicine, Rijeka, Croatia

<sup>2</sup>Department of Pediatrics, Clinical Hospital Centre Rijeka, Rijeka, Croatia

**Corresponding author:** Tea Škoda, tea.skoda@hotmail.com

---

**Introduction:** Diabetic ketoacidosis is the most common acute hyperglycaemic emergency in people with diabetes mellitus. It typically occurs in the setting of hyperglycaemia and insulin deficiency, which causes unopposed lipolysis and oxidation of free fatty acids, thereby resulting in ketone body production and metabolic acidosis. Symptoms of hyperglycaemia are polyuria, polydipsia, and sometimes more severe such as unintentional weight loss, vomiting, weakness, and mentation changes. Dehydration and metabolic abnormalities can lead to lethargy, fatigue and may even cause respiratory failure, coma, and death.

**Case report:** A 13-year old Caucasian girl is brought by a helicopter to paediatric emergency department Kantrida, Rijeka presenting with disturbed mental state, weakness and fatigue, dry mouth, coated tongue, acetone-scented breath, dehydration, abdominal pain, cold extremities and dry skin. She vomited once the night before. She has been experiencing abdominal pain, headaches, muscle spasms in legs, weakness and fatigue in the last month. Her mother noticed significant and unintentional weight loss in the last month which is more intense in the last 7 days. Glucose levels measured at home were 16 mmol/L. Weight, from her physical exam, 51kg, blood pressure 115/80, SpO<sub>2</sub> 98%, pulse 90/min, breathing frequency 25/min, glucose in blood 14 mmol/L, pH 7,12, bicarbonates 4,2. She received 500 mL of Ringer's lactate solution during transport and a continuous insulin infusion (0.05 units/kg/h) when she was admitted to intensive care unit. In the following days, patient's symptoms regressed, she was educated about diabetic diet plan, had a consultation with endocrinologist about continuous insulin therapy and she made full recovery.

**Conclusion:** Diabetic ketoacidosis is a serious complication of diabetes that can present with variety of symptoms. It is a serious condition because it can lead to metabolic abnormalities that can result in respiratory failure, coma and even death.

**Keywords:** Diabetic ketoacidosis, Diabetes mellitus, Hyperglycaemia, Insulin

---

## Importance and usage of Point of care ultrasound

Megi Paus<sup>1</sup>, Ana Tancabel Mačinković<sup>2</sup>

<sup>1</sup>University of Rijeka, Faculty of Medicine, Rijeka, Croatia

<sup>2</sup>Clinical Hospital Centre Rijeka, Rijeka, Croatia

**Corresponding author:** Megi Paus, megi.paus1@gmail.com

---

**Summary:** Medical ultrasound includes diagnostic techniques using ultrasound to create images of internal body structures. Because it provides images in real-time, is portable, relatively cheap and does not use harmful radiation it makes a perfect diagnostic tool for any doctor. Point-of-care ultrasound (POCUS) refers to the practice of medical professionals using ultrasound to diagnose problems wherever a patient is being treated, whether that's in a modern hospital, an ambulance, or a remote village. In remote regions with limited access to medical facilities, ultrasound is useful in providing rapid and non-invasive diagnosis on site.

Critical care ultrasonography (CCUS) refers to the use of ultrasonography in patients who are critically ill, this also includes POCUS and organ ultrasonography (eg, thoracic ultrasonography-TUS). Some of the protocols that had been described and who can help with critically ill patients are RUSH (Rapid ultrasound in shock), FAST (Focused assessment with sonography for trauma), FATE (Focus Assessed Transthoracic Echo) and BLUE (Bedside Lung Ultrasound in an Emergency). Ultrasound is not a replacement for the more sensitive imaging (eg. MSCT) but serves as an initial screening tool for patients with life-threatening injuries. If you perform a FAST exam in the field and make a diagnosis before arriving to the hospital you've directly shortened the time of emergency department (ED) management and increased the survival rate. Unfortunately, in Croatia, young doctors and nurses working in the field are usually not well trained in sonography. In Emergency medicine time is crucial and should not be taken for granted. Being educated and knowing how to follow these protocols maximizes the quality of treatment and leads to more a positive outcome. Knowing that, investing in education and including POCUS in everyday practice, more lives can be saved and a higher quality of diagnosis can be performed by physicians.

**Key words:** Emergency medicine, Critical illness, Ultrasound

---

## **Cardiac arrest during transport in Emergency medical services - a case report**

Silva Šiftar<sup>1</sup>, Nikolina Morić<sup>2</sup>, Emil Klarić<sup>1</sup>, Tina Herljević<sup>1</sup>, Bruno Gross<sup>1</sup>, Jakov Končurat<sup>3</sup>

<sup>1</sup>*Emergency Medicine Institute Zagreb County, Velika Gorica, Croatia*

<sup>2</sup>*University of Rijeka, Faculty of Medicine, Rijeka, Croatia*

<sup>3</sup>*Emergency Medicine Institute Zadar County, Posedarje, Croatia*

**Corresponding author:** Silva Šiftar, [siftar.silva@gmail.com](mailto:siftar.silva@gmail.com)

---

**Introduction:** Cardiac arrest (CA) is an abrupt loss of heart function. The most common cause are malignant arrhythmias. ECG shows either ventricular fibrillation (VF), ventricular tachycardia (VT) without pulse, pulseless electrical activity (PEA) or asystole. It is important to correctly determine the rhythm because of different protocols of providing advanced life support (ALS). VF and VT without pulse are shockable rhythms, and PEA and asystole are not.

**Case report:** A 76-year old male presented with difficulty breathing. His oxygen saturation was 80%, temperature was 38.6°C and blood glucose level was 22.2. Other vitals were within the normal range. Chest auscultation showed no abnormal heart or lung sounds. This was a patient with known arterial hypertension and diabetes. Due to his current condition, we decided to transport him to the nearest hospital emergency center. ECG showed a sinus rhythm (SR) with a rate of 71. He was administered oxygen and intravenous fluids. Five minutes into transport the ECG showed an alteration of SR and VT with pulse, which was when we prepared amiodarone to be administered. Suddenly, he lost consciousness, stopped breathing and ECG showed a VT with no pulse. He was defibrillated with 150J followed by chest compressions - within two minutes of the arrest VT was converted to SR and he regained spontaneous breathing and circulation. In the emergency room he had a cardiac arrest 2 more times with 4 other episodes of VT. A cardioverter-defibrillator was implanted and he was released from the hospital in a stable condition.

**Conclusion:** This was a case of hyperglycemia and hypoxia that took a surprising turn and became a case of heart failure in a patient with no familiar heart condition. This was a result of an underlying paroxysmal VT. This case showed the importance of quick assessment, correct diagnosis and appropriate treatment.

**Keywords:** Cardiac arrest, Hyperglycemia, Ventricular tachycardia

---

## Pacing for life - Case report

Sandra Knežević<sup>1</sup>, Anamaria Zuljani<sup>1</sup>, Ivana Žitinić<sup>2</sup>

<sup>1</sup>University of Rijeka, Faculty of Medicine, Rijeka, Croatia

<sup>2</sup>Clinical Hospital Centre Rijeka, Rijeka, Croatia

**Corresponding author:** Sandra Knežević, knezevic.sandra71@gmail.com

---

**Introduction:** Syncope is a clinical syndrome in which transient loss of consciousness is caused by a period of inadequate cerebral nutrient flow, most often the result of an abrupt drop of systemic blood pressure. Typically, the inadequate cerebral nutrient flow is of relatively brief duration (8 to 10 seconds).

**Case report:** 87-year-old patient was hospitalised due to vertigo and vomiting. The patient was complaining of shortness of breath in the last 3 days as well as losing consciousness a few times but without falling. Otherwise, she is a cardiac patient who had a pacemaker implanted in 2018 due to a high grade AV block. The X-ray visualised a well-placed pacemaker with a continuous electrode. During observation the patient became bradycardic (20/min) and unconscious for about 10 seconds. Following three precordial thumps, the patient's heart started beating again with the rhythm of the pacemaker. After regaining consciousness, the patient felt shortness of breath for a couple of minutes and then she stabilised. This fall in frequency (20/min) with loss of consciousness happened three more times. It was noticed that it would happen in the moment the patient would raise her arms. The cardiologist was urgently called, and the patient had an external pacemaker placed that took over the pace (50/min). After, the patient was taken to the Cardiology department where she had a temporary pacemaker placed.

**Conclusion:** Clinical symptoms of pacemaker malfunction are variable and include syncope, dizziness, palpitations, and slow or fast heart rate. Pacemaker malfunction is a rare entity varying to 2 percent of clinical cases but must be taken into consideration having a patient presented with syncope to the Emergency department.

**Key words:** Bradycardia, Pacemaker, Syncope

---

## Can sudden hearing loss be adverse reaction of Covid-19 vaccination? – case report

Nikolina Morić<sup>1</sup>, Emil Klarić<sup>2</sup>, Jakov Končurat<sup>3</sup>, Maja Mrak(mentor)<sup>4</sup>, Filip Guzić(mentor)<sup>4</sup>

<sup>1</sup>*Faculty of Medicine, University of Rijeka, Rijeka, Croatia*

<sup>2</sup>*Emergency Medicine Institute Zagreb County, Zagreb, Croatia*

<sup>3</sup>*Department of Emergency Medicine Zadar County, Zadar, Croatia*

<sup>4</sup>*Health Centre Primorsko-goranska County, Rijeka, Croatia*

**Corresponding author:** Nikolina Morić, nikolina.moric@student.uniri.hr

---

**Introduction:** Sudden sensorineural hearing loss (SSNHL) is characterized by an acute sensorineural hearing loss  $\geq 30$  dB over three consecutive frequencies that occur within 72 hours. Although SSNHL can result from a viral infection, vasculitis, autoimmune disease and tumor, the majority of cases are idiopathic. In this case report, we wanted to present a patient who presented with SSNHL after the third dose of the Pfizer-BioNTech COVID-19 vaccine.

**Case report:** An 82-year-old patient was admitted to the Ear, nose and throat Department of the Clinical hospital center Rijeka due to sudden hearing loss in the right ear. The symptoms started two days after receiving the third dose of the Pfizer-BioNTech vaccine. The otoscopic, rhinoscopic, and oropharyngoscopic findings were normal. The audiogram showed bilateral sensory impairment, a threshold right between 45 and 75 dB and left between 85 and 110 dB. Tinnitus was identified on the left at 6 kHz with an intensity of 90 dB. The speech audiometry showed a listening threshold of 55 dB to the right and 90 dB to the left. On the right ear, 100% intelligibility at 90 dB was achieved and only 20% at 100 dB on the left ear. Emergency corticosteroid intratympanic therapy was indicated and the patient underwent a myringotomy on the right ear. The patient was treated with intratympanic injections of 125mg of methylprednisolone for five days. At the follow-up examination, the audiogram showed a bilateral perceptual hearing impairment threshold right between 50 and 75 dB, left between 85 and 110 dB. Due to incomplete recovery and residual symptoms of hearing loss in the right ear, hyperbaric oxygen therapy (HBOT) was recommended.

**Conclusion:** In this case, we wanted to present a rarely reported side effect of a booster vaccination. The etiology of SSNHL after vaccination is still unknown. In some reported cases, fast diagnosis and therapy improved the outcome of these patients.

**Keywords:** BNT162 vaccine, COVID-19, Hearing loss, Sudden, Injection, Intratympanic

---

## **Urgent tracheotomy after thyroid gland surgery**

**Bernard Nović<sup>1</sup>, Tena Štefanac<sup>1</sup>, Iva Šimić<sup>1</sup>, Filip Tudor<sup>2</sup>, Blažen Marijić<sup>2</sup>**

*<sup>1</sup>Faculty of Medicine, University of Rijeka, Rijeka, Croatia*

*<sup>2</sup>Department of Otorhinolaryngology, Head and Neck Surgery, Rijeka University Hospital Center, Rijeka, Croatia*

**Corresponding author:** Bernard Nović, [beronovic@gmail.com](mailto:beronovic@gmail.com)

---

**Summary:** Tracheotomy is a surgical procedure that involves establishing a tracheostomy on the front of the neck and inserting a tube into the trachea. The clinical indications for tracheotomy are various and a significant spot is occupied by the bilateral paresis and paralysis of the vocal cords. Muscle which abducts the vocal cord is innervated by the recurrent laryngeal nerve, a branch of the vagus nerve. If bilateral damage occurs, the vocal cords are positioned in a paramedian or median position, preventing air from reaching the lower respiratory tract, necessitating a tracheotomy. Thyroid surgical procedures, particularly total thyroidectomy, are a common cause of bilateral recurrent laryngeal nerve injury. A retrospective study was conducted in which were included all the surgical procedures of the thyroid gland at the Department of Otorhinolaryngology, Head and Neck Surgery from 17th November 2014 to 13th July 2020. Thyroid surgery was performed on a total of 270 patients, with 131 of them undergoing total thyroidectomy. Bilateral paresis of the recurrent laryngeal nerve was found in 7 (5,3%) patients who underwent total thyroidectomy. Five patients were given corticosteroids, and the condition of their vocal cords quickly improved. Tracheotomy was performed on two patients (1,5%) and both patients' vocal cords recovered. The first patient recovered in one month and decannulation was performed two months after the surgery. Four months following surgery, the second patient regained vocal cord function, and decannulation was performed two months later.

Despite the fact that the recurrent laryngeal nerves are preserved and displayed during thyroid gland procedures, the surgeon must be aware that temporary and even permanent paresis of the vocal cords may occur. As the vocal cords are in a paramedian position, ventilation is obstructed and an emergency tracheotomy is needed.

**Keywords:** Recurrent laryngeal nerve, Tracheotomy, Vocal cord paralysis

---

**Supraventricular tachycardia as the first manifestation of Wolff-Parkinson-White Syndrome – case report**  
Andrea Racetin<sup>1</sup>, Frane Paleka<sup>2</sup>

<sup>1</sup>*School of Medicine, University of Zagreb, Zagreb, Croatia*

<sup>2</sup>*Department of Emergency Medicine of Krapina-Zagorje County, Krapina, Croatia*

**Correspondent author:** Andrea Racetin, andrearacetin1996@gmail.com

---

**Introduction:** Wolff-Parkinson-White Syndrome (WPW-SY) is a congenital heart condition defined by an extra signaling pathway between atria and ventricles. Most accessory pathways have different electrophysiological properties from normal atrioventricular conduction systems. As a result of that, they conduct impulses faster and in both directions. This abnormal conduction can cause Re-entry arrhythmias with a narrow QRS complex, but the greatest concern for people with WPW is the possibility of having atrial fibrillation with rapid ventricular response leading to ventricular fibrillation. WPW-SY is also related to sudden cardiac death.

**Case report:** A 39-year old woman, with a disease history of arterial hypertension and Charcot-Marie-Tooth disease presented with dyspnea, anxiety, dizziness and severe heart palpitations. The physical examination showed RR= 110/70, RF=20, c/p=220 and SpO<sub>2</sub>=77% in room air. Electrocardiogram (ECG) revealed narrow QRS complex tachycardia. The patient was treated in the emergency department by stimulating the vagus with carotid massage and i.v adenosine but without success. She was transported to the hospital where treatment was continued with i.v. adenosine. After converting to sinus rhythm, 12-lead ECG was performed and it revealed classic ECG morphology of WPW-SY, shortened PR interval and delta wave. This was her first manifestation of WPW-SY.

**Conclusion:** Despite the fact that narrow QRS complex tachycardia is rarely life-threatening, we must keep in mind that it can be the first representation of WPW-SY. Diagnosing this disorder can be challenging, especially when patients present with tachyarrhythmias and the pathognomonic delta wave becomes invisible. Radiofrequency catheter ablation is the treatment of choice in WPW-SY patients with several tachycardia episodes.

**Keywords:** Adenosine, Tachycardia, Wolff-Parkinson-White syndrome



---

## **Pulmonary embolism in patients with COVID-19**

Marija Sabol<sup>1</sup>, Ana Tancabel Mačinković<sup>2</sup>

<sup>1</sup>*Faculty of Medicine, University of Rijeka, Rijeka, Croatia*

<sup>2</sup>*Clinical Hospital Center Rijeka, Department of Emergency Medicine, Rijeka, Croatia*

**Corresponding author:** Marija Sabol, marija.sabol@student.uniri.hr

---

**Summary:** This review aims to show the correlation of COVID-19 and pulmonary embolism (PE) and the latest experiences with therapies, as presented in recent professional literature.

Patients with COVID-19 are at an increased risk of developing PE, which may occur in up to one-third of critically ill COVID-19 patients requiring intensive care unit (ICU) admission. Thromboprophylaxis should therefore be started in COVID-19 patients admitted to the hospital, and intermediate therapeutic doses of anticoagulants can be considered in patients requiring ICU admission or those with multiple risk factors for venous thromboembolism (VTE). Extending thromboprophylaxis after hospital discharge or in the prehospital phase during self-isolation at home should be done according to a meticulous risk/benefit assessment, balancing the reduction of the risk of VTE with the increase of the risk of bleeding events. Therapeutic anticoagulation is the foundation in the management of patients with PE. The selection of an appropriate agent and correct dosage requires consideration of underlying comorbidities and organ dysfunctions. The initial approach to patients with suspected PE should focus upon stabilizing the patient while clinical evaluation and definitive diagnostic testing is ongoing. Supplemental oxygen should be administered to target oxygen saturation  $\geq 90$  percent. Severe hypoxemia, hemodynamic collapse, or respiratory failure should prompt consideration of mechanical ventilation. For those who require hemodynamic support, we suggest cautious infusions of intravenous fluid (500 to 1000 mL of normal saline) rather than larger volumes (Grade 2C). Vasopressor therapy should be initiated if perfusion fails to respond to IVF.

The review indicates a high prevalence of pulmonary embolism in patients with COVID-19 at the time of hospital admission. For this reason, we support CT pulmonary angiogram exams on hospital admission in COVID-19 patients requiring supplemental oxygen, having high D-dimer concentrations or a long history of COVID-19 symptoms, if not contraindicated.

**Keywords:** COVID-19, Pulmonary embolism, SARS-CoV-2

---

## Transposition of the great arteries in a newborn – case report

Sara Smeraldo<sup>1</sup>, Zane Demiri<sup>2</sup>, Neven Čače<sup>3</sup>

<sup>1</sup> University of Rijeka, Faculty of Medicine, Rijeka, Croatia

<sup>2</sup> University of Rijeka, Faculty of Medicine, Rijeka, Croatia

<sup>3</sup> Department of Pediatrics, Clinical Hospital Centre Rijeka, Rijeka, Croatia

**Corresponding author:** Sara Smeraldo, sara.smeraldo@gmail.com

---

**Introduction:** Transposition of the great arteries is a ventriculoarterial discordant lesion in which the aorta arises from the right ventricle and the pulmonary artery from the left ventricle. This is a cyanotic congenital heart disease as a result of two separate, parallel circulations. Clinical presentation usually occurs on the first day of life with progressive cyanosis. In some cases the disease is detected later due to the presence of ventricular septal defect (VSD), atrial septal defect (ASD), distal airway pressure (DAP) which allow mixing of blood. The aim of this report is to present a case of unrecognized congenital heart disease with development of acute cardiogenic shock.

**Case report:** A 28-days old male newborn was admitted to the Intensive care unit (ICU) after his regular appointment at the pediatric cardiologist due to VSD. He was found to be in critical condition with a recapillarization time of 4 seconds. The patient was tachypneic with a blood oxygen level of just 50%, with yellow to grayish skin, tachycardia (180/min) and a 3/6 systolic murmur. It was concluded (deduced) that the patient was in severe shock. On echocardiography transposition of the great arteries (TGA) with VSD, and restrictive ASD was found. Rashkind procedure was performed in order to dilate the ASD. The patient was stable shortly afterwards with blood oxygen level around 75%. Two or three days later arterial switch operation with closure of VSD and ASD was performed with very good results.

**Conclusion:** Congenital heart diseases can be overlooked and not recognised immediately which may lead to serious and life threatening conditions. It is important to implement screening for critical congenital heart diseases to avoid these unwanted mistakes.

**Keywords:** Cyanosis, Heart defects, Congenital, Shock

---

## Use Of Tocilizumab In The Treatment Of Acute Respiratory Failure Caused By Covid-19: A Case Series

Mila Stazić<sup>1</sup>, Marta Marčinković<sup>1</sup>, Damir Vučinić<sup>2,4</sup>, Aron Grubešić<sup>1,3,4</sup>

<sup>1</sup>*Faculty of Medicine, University of Rijeka, Rijeka, Croatia*

<sup>2</sup>*Clinic for Radiotherapy and Oncology, Clinical Hospital Centre of Rijeka, Rijeka, Croatia*

<sup>3</sup>*Department of Hematology, Clinical Hospital Centre of Rijeka, Rijeka, Croatia*

<sup>4</sup>*Multidisciplinary ward for treatment of COVID-19 patients, Clinical Hospital Centre of Rijeka, Rijeka, Croatia*

**Corresponding author:** Mila Stazić, email: stazic.mila@gmail.com

---

**Aim:** We describe a three-case series of Coronavirus disease 2019 (COVID-19) patients hospitalized in Clinical Hospital Center Rijeka due to acute respiratory failure caused by coronavirus pneumonia, with a focus on cytokine storm and the potential therapeutic role of tocilizumab.

**Case description:** Three male patients aged between 48 and 61 years were followed for 20 days after tocilizumab therapy. All patients had confirmed SARS-CoV2 infection based on real-time polymerase chain reaction analysis of nasal swab sample, radiological findings consistent with COVID-19 pneumonia, and laboratory evidence of systemic inflammation with C-reactive protein (CRP) being greater than 100 mg/L. Despite initiated supplemental oxygen therapy, corticosteroid therapy, and thromboprophylaxis, 24 hours after admission, respiratory parameters worsened, leading to acute respiratory distress syndrome (ARDS). Interleukin-6 (IL-6) concentration was found to be 272.1 ng/L (patient 1), 119.2 ng/L (patient 2) and 119.5 ng/L (patient 3) after which all patients received tocilizumab (8 mg/kg i.v. 800 mg). At the time of tocilizumab administration, all patients had been treated with continuous positive airway pressure (CPAP) administered via non-invasive mechanical ventilation due to type 1 respiratory failure. After 72-96 h there was a significant reduction in ventilation and oxygen requirements for all patients accompanied by a reduction of laboratory inflammatory markers. The average duration of hospitalization was nine days.

**Conclusion:** IL-6 had been identified by various authors as one of the crucial factors in cytokine storm cascade which is thought to be behind COVID-19 ARDS. Tocilizumab selectively and competitively binds to soluble expressing IL-6 receptor subsequently blocking that signaling pathway. Significant clinical improvement was noted in all three patients treated with tocilizumab. Further studies are needed to establish exact protocols for the application of IL-6 inhibitors in the COVID-19 setting.

**Keywords:** COVID-19, Inflammation, Respiratory Distress Syndrome, Tocilizumab

---

## Perforated appendiceal actinomycosis – a case report

Ines Trkulja<sup>1</sup>, Lucija Brkić<sup>2</sup>, Branko Bogdanić<sup>2</sup>

<sup>1</sup>*School of Medicine University of Zagreb, Zagreb, Republic of Croatia*

<sup>2</sup>*Department of Surgery, Clinical Hospital Centre Zagreb, Zagreb, Republic of Croatia*

**Corresponding author:** Ines Trkulja, ines.trkulja@gmail.com

---

**Introduction:** Actinomycosis (AMC) is a rare infectious disease caused by Actinomyces bacteria due to the mucosal barrier disruption. It commonly presents as cervicofacial, pulmonary, or, rarely, gastrointestinal infection. AMC can affect the gastrointestinal system after major abdominal or pelvic surgeries, trauma incidents, immunosuppression, or gastrointestinal tract lesions. The ileocecal region is the most frequent site for gastrointestinal AMC. However, the most significant problem is that it mimics other diseases and that the preoperative diagnosis is made in fewer than 10% of the cases.

**Case report:** A 24-year-old female was firstly treated after complaining about lower abdominal pain and fever in the last few days. She denied nausea and vomiting. Multislice computed tomography (MSCT) did not find any indications for surgery. C-reactive protein (CRP) was 115 mg/L. She was again admitted to the Emergency room (ER) due to high fever (axillary 39,6) and diffuse abdominal pain. The increased rigidity of lower hemiabdomen found on the physical examination and increased CRP of 157 mg/L led to the diagnosis of acute abdomen. Laparoscopy showed perforated, thickened, gangrenous appendix vermiformis and purulent content in all four abdominal quadrants. The patient was firstly administered with ciprofloxacin (2x400 mg) and metronidazole (3x500 mg), and later on with meropenem (3x1 g) and vancomycin (2x1 g) during postoperative care. The antibiotic regimen was changed to ceftriaxone (1x2 g) and metronidazole (3x500 mg) after pathology described typical histological signs of AMC – yellow sulfur granules that refer to PAS-positive colonies of Actinomyces. The patient was also tested negative for HIV. She became afebrile and recovered fully.

**Conclusion:** Although appendiceal actinomycosis is an uncommon finding, it should be considered due to its treatment specificity. Pathohistological examination is essential when the patient does not respond to standard postoperative prophylactic antibiotic treatment.

**Keywords:** Abdomen, Acute, Actinomycosis, Laparoscopy

---

## Treatment of hemorrhagic shock due to arterial bleeding in the area of tracheostomy cannula - Case report

Hana Vičević<sup>1</sup>, Anamaria Zuljani<sup>1</sup>, Jan Maroević<sup>2</sup>

<sup>1</sup>University of Rijeka, Faculty of Medicine, Rijeka, Croatia

<sup>2</sup>Department of Anesthesiology, Intensive Care Medicine and Pain Treatment, Clinical Hospital Center Rijeka, Rijeka, Croatia

**Corresponding author:** Hana Vičević, vicevic.hana@gmail.com

---

**Introduction:** Hemorrhagic shock is a state of acute hemorrhage or excessive fluid loss resulting in hypovolemia. This condition results in anaerobic metabolism, acidosis, and deleterious alterations to cell function, due to reduced tissue perfusion and therefore inadequate delivery of oxygenated blood.

**Case report:** 68-year-old patient was initially accepted to the Emergency department (ED) as cerebrovascular insult. She underwent a Computed tomography (CT) where diffuse subarachnoid and right intracerebral brain hemorrhage (ICH) was found and was then hospitalized on the Neurology department. The patient went from full consciousness to somnolence and a control CT showed the hematoma progressing. Decompressive craniectomy was done after which she was kept at the Intensive care unit (ICU) of the Anesthesiology department. There she underwent a percutaneous dilatational tracheostomy (PDT) and, after her state stabilizing, was transferred to the ICU of the Neurology department. In the next two weeks her state improved, and she regained consciousness. Her tracheostomy cannula was changed several times, due to hygienic reasons. After one change the patient started heavily bleeding through the cannula. Following a checkup from the otorhinolaryngologist and anesthesiologist she was sent to an emergency operation during which she keeps heavily bleeding and goes into hemorrhagic shock and cardiopulmonary arrest. After a successful reanimation and hemostasis by the cardiothoracic surgeon the patient is held at the ICU of the Anesthesiology department where she is hemodynamically stable. Through the next few days her vital functions are worsening, signs of multiorgan failure are noticed and the patient passes away.

**Conclusion:** This case is an example of good teamwork as Return of spontaneous circulation (ROSC) was managed in a hypovolemic patient by cooperation of volume optimisation by the anesthesiology team and surgical hemostasis by the surgical team. It shows how treatment of reversible causes of death (4H and 4T), if done adequately and on time, can lead to ROSC.

**Keywords:** Hematoma, Hemorrhagic shock, Resuscitation, Tracheostomy

---

## **Acute pancreatitis in a 13-year-old boy – case report**

Zanë Demiri<sup>1</sup>, Sara Smeraldo <sup>2</sup>, Kristina Baraba Dekanić<sup>3</sup>

<sup>1</sup> *University of Rijeka, Faculty of Medicine, Rijeka, Croatia*

<sup>2</sup> *University of Rijeka, Faculty of Medicine, Rijeka, Croatia*

<sup>3</sup> *Department of Pediatrics, Clinical Hospital Centre Rijeka, Rijeka, Croatia*

**Corresponding author:** Zanë Demiri, zanademiri12@gmail.com

---

**Introduction:** Acute pancreatitis is an inflammatory process which occurs over a short period of time. The main causes of pancreatitis are gallstones, alcohol and hypertriglyceridemia. Clinical presentation ranges from mild to a severe disease with high morbidity and mortality. Acute pancreatitis in children is a relatively rare occurrence and it mainly presents with abdominal pain. The aim of this report is to present a case of acute pancreatitis in a child in order to avoid a delay in diagnosis and treatment.

**Case report:** A 13-year old Caucasian boy was admitted to the ER following four days of severe epigastric pain which intensified postprandially. The patient was afebrile and denied nausea, vomiting and diarrhea. Further examination showed a BMI of 37.5. Admission laboratory tests showed elevated results of serum amylase(1421 U/L), lipase(2062 U/L), AST(213 U/L), ALT(203 U/L), and GGT(427 U/L). Inflammatory changes were visualized during abdominal ultrasound. The patient was subsequently hospitalized and diagnosed with acute pancreatitis and gallstones. He was then scheduled for a laparoscopic cholecystectomy. Following symptomatic treatment, the young patient was fully recovered.

**Conclusion:** Acute pancreatitis can have life-threatening complications. It is very important to not overlook this diagnosis even in children, where it usually presents with common GIT symptoms such as abdominal pain, nausea or vomiting.

**Keywords:** Abdominal pain, Amylases, Pancreatitis

---

## **Brachial Artery Entrapment: A Case Report**

**Andrija Dukić<sup>1</sup>, Roberto Diminić<sup>1</sup>, Ana Bosak Veršić<sup>2</sup>**

<sup>1</sup>*University of Rijeka, Faculty of Medicine, Rijeka, Croatia*

<sup>2</sup>*Clinical Hospital Center Rijeka, Department of Pediatric Surgery, Rijeka, Croatia*

**Corresponding author:** Andrija Dukić, andrijaduk@gmail.com

---

**Introduction:** Brachial artery entrapment is a rare vascular condition in which the brachial artery is compressed by perivascular tissue, resulting in reduced blood flow to the forearm. Reduced blood flow and compression can result in serious damage to both the artery and the forearm.

**Case report:** We present a case of a 5-year-old boy who came to the hospital after a fall that resulted in a displaced supracondylar fracture of his left arm. Peripheral capillary refill time on his left forearm was normal, but radial artery pulsations were not palpable. After repositioning and fixating the bone fragments, radial artery pulsations were still absent. A CT angiography scan was performed and showed a lack of blood flow through the brachial artery below the level of the fracture. After consulting the vascular surgeon, a second surgery was performed. Firstly, the compressed terminal segment of the brachial artery was visualized. After mobilizing and decompressing the artery, radial pulsations were palpable. Normal blood flow was confirmed with an intraoperative Doppler ultrasound. After the surgery, the arm was immobilized using a plaster splint. The patient was discharged from the hospital 10 days after the surgery. 6 days after the discharge from the hospital, the splint was removed and the patient was hospitalized for physical therapy during the next 13 days, which resulted in a full recovery of function.

**Conclusion:** Brachial artery entrapment is a rare cause of forearm ischemia following a fracture. However, it can result in a serious long-lasting functional deficit. Therefore, radial artery pulsations should always be assessed following a fracture of the arm.

**Keywords:** Arterial occlusive diseases, Humeral fractures, Vascular surgical procedures

---

## Acute appendicitis in children

Mario Koporčić<sup>1</sup>, Andrija Karačić<sup>2</sup>

<sup>1</sup>*School of Medicine, University of Zagreb, Zagreb, Croatia*

<sup>2</sup>*Department of Surgery, University Hospital Sveti Duh, Zagreb, Croatia*

**Correspondent author:** Mario Koporčić, mario.koporcic@gmail.com

---

**Introduction.** Acute appendicitis (AA) is the most common surgical emergency in children. While the differential diagnosis of abdominal pain is one of the most complicated in medicine itself, the diagnosis in children is further complicated by age-related specifics. The aim of this paper is to point out frequency, clinical manifestations and possibilities of diagnosing AA in children.

**Review.** The incidence of AA is 100-151/100000 people per year, with the highest incidence in the age group of 10-19. Clinical manifestations in older children are similar to those in adults – indeterminate abdominal pain, anorexia, pain in the lower right abdomen, nausea, vomiting, fever, abdominal rigidity and increased pain caused by characteristic physical examination procedures. It is much more complicated to diagnose AA in young children. Signs and symptoms are mostly atypical and unreliable, the differential diagnosis is very broad and an adequate medical history is almost impossible to take. These reasons often lead to late diagnosis, resulting in perforation. The average incidence of perforation in children is up to 30% and increases as the child is younger (up to 90% in infants). The diagnosis of AA is based on medical history, physical exam, laboratory findings and radiological procedures. Laboratory findings suggesting AA are leukocytosis, neutophilia with left shift and elevated CRP levels. Of the radiological procedures, ultrasound and CT are used, each having its own advantages and disadvantages. Treatment is mostly surgical, with other options being discussed lately.

**Conclusion.** The goal is to accurately diagnose AA and avoid the severe consequences of the disease and unnecessary diagnostic or therapeutic interventions. For that, a fast and precise diagnostic method should be developed. Today, however, medical history and physical examination are still the basis for diagnosing AA, which requires certain skills and experience of the physician.

**Keywords:** Abdominal pain, Appendicitis, Children



---

## **Barotrauma Resulting From Non-Invasive Ventilation For Acute Respiratory Distress Syndrome Caused By Covid-19 Infection: A Case Series**

Marta Marčinković<sup>1</sup>, Mila Stazić<sup>1</sup>, Damir Vučinić<sup>2,4</sup>, Aron Grubešić<sup>1,3,4</sup>

<sup>1</sup> Faculty of Medicine, University of Rijeka, Rijeka, Croatia

<sup>2</sup> Clinic for Radiotherapy and Oncology, Clinical Hospital Centre of Rijeka, Rijeka, Croatia

<sup>3</sup> Department of Hematology, Clinical Hospital Centre of Rijeka, Rijeka, Croatia

<sup>4</sup> Multidisciplinary ward for treatment of COVID-19 patients, Clinical Hospital Centre of Rijeka, Rijeka, Croatia

**Corresponding author:** Marta Marčinković, email: marta.marcinkovic@gmail.com

---

**Introduction:** To report a case series of three patients with barotrauma that were treated with positive air pressure non-invasive ventilation due to Coronavirus disease - 2019 (COVID-19) infection related acute respiratory distress syndrome (ARDS).

**Case description:** All patients were hospitalized in the COVID-19 multidisciplinary department due to COVID-19 infection related ARDS. The average patient age was 67 years, two were male and one female. On admission, patients were treated with supplemental oxygen therapy, corticosteroid therapy, thromboprophylaxis and gastroprotection according to current guidelines. Admission chest radiographs were reviewed and all three patients had bilateral pneumonia without any signs of emphysema, atelectasi or bullae. The course of hospitalization was complicated by development of ARDS which required continuous positive airway pressure (CPAP) delivered via non-invasive mechanical ventilation. All patients developed clinical deterioration after having an initial satisfactory response. Chest X-ray was done and showed that two out of three patients had pneumomediastinum likely related to CPAP barotrauma and were consequently switched to lower positive pressure delivered via high-flow cannula (HFNC). Third patient was diagnosed with right-sided pneumothorax and was subsequently treated with a chest drain. In further course of treatment, condition of two pneumomediastinum patients improved. Patient with pneumothorax was transferred to an intensive care unit and treated with invasive mechanical ventilation, after which respiratory parameters gradually improved and was in further course discharged.

**Conclusion:** COVID-19 infection related ARDS is associated with a higher incidence of barotrauma which is likely related CPAP delivered via non-invasive ventilation and as such presents unique challenges clinicians. Further studies are required to develop safer positive air pressure protocols as well as to adequately reduce treatment complications.

**Keywords:** COVID-19, Pulmonary barotrauma, Pneumothorax, Pneumomediastinum, Adult respiratory distress syndrome

---

## Where is the capsule? Video capsule retention in capsule endoscopy

Drago Marijanović<sup>1</sup>, Ines Trkulja<sup>1</sup>, Lucija Brkić<sup>1,2</sup>, Trpimir Morić<sup>2</sup>, Klara Kuzman<sup>1</sup>, Petar Matošević<sup>1,2</sup>

<sup>1</sup>*School of Medicine University of Zagreb, Zagreb, Republic of Croatia*

<sup>2</sup>*Department of Abdominal Surgery, University Hospital Center Zagreb, Zagreb, Republic of Croatia*

**Corresponding author:** Drago Marijanović, dragomarijanovic0@gmail.com

---

**Introduction:** Capsule endoscopy provides a direct, non-invasive inspection of the small intestine along its entire length. It has become the gold standard for diagnosing many different illnesses in that region. This type of endoscopy is regarded as a safe procedure. However, capsule retention is the most severe complication since it may result in bowel obstruction and surgical intervention.

**Case Report:** An 81-year old female was admitted to the ER because of melena and anemia. Physical examination revealed signs of skin pallor and tachycardia. Hemoglobin was 84 g/L and required blood transfusions. Computed tomography, esophagogastroduodenoscopy, and colonoscopy showed no signs of active bleeding. Video capsule endoscopy was indicated after hemodynamic stabilization. Multiple jejunal and ileal angiodysplastic lesions were present with no signs of active bleeding. The patient was discharged and asked to return the capsule. Two months later, the patient was hospitalized because of capsule retention. Retrieval of a retained video capsule via colonoscopy was unsuccessful. Abdominal X-ray confirmed retention, and the patient was admitted to the surgical department for capsule extraction. Explorative laparotomy showed three significant stenosed segments of the small intestine (55, 70, and 75 cm from the ileocecal valve, respectively). The retained capsule was proximal to the stenosis. Stenosed segments were resected, the capsule was extracted, and a latero-lateral (LL) anastomosis was performed. Signs of anastomotic leakage were found during the postoperative period, demanding reoperation. The anastomosis was resected, and a double-barrel ileostomy was formed.

**Conclusion:** This case shows that even a low-risk, non-invasive procedure can lead to an invasive intervention and multiple surgeries. However, in this case, capsule retention helped diagnose the stenosis that would not be found otherwise. Therefore, video capsule endoscopy is a valuable procedure that brings a great help in the visualization of the complete intestine.

**Keywords:** Capsule endoscopy, Intestinal obstruction, Melena

---

## **Acute Stress Reaction As A Trigger To Cardiovascular Event In Patient With No History Of Coronary Heart Disease – a Case Report**

Jakov Končurat<sup>1</sup>, Emil Klarić<sup>2</sup>, Maja Mrak<sup>3</sup>, Nikolina Morić<sup>4</sup>, Tina Hreljević<sup>2</sup>, Silva Šiftar<sup>2</sup>, Bruno Gross<sup>2</sup>

<sup>1</sup>*Emergency Medicine Institute Zadar County, Posedarje, Croatia*

<sup>2</sup>*Emergency Medicine Institute Zagreb County, Velika Gorica, Croatia*

<sup>3</sup>*Health Center of Primorsko-goranska County, Rijeka, Croatia*

<sup>4</sup>*Faculty of Medicine, Rijeka, Croatia*

**Corresponding author:** Jakov Končurat, jakov.koncurat95@gmail.com

---

**Introduction:** Acute stress disorder (ASD) is an intense, dysfunctional reaction that occurs shortly after an overwhelmingly traumatic event. ASD explains acute stress reaction (ASR) lasting no more than four weeks. ASR can lead to tachycardia, high blood pressure, and increased serum levels of cortisol. It can disrupt cholesterol-filled plaques, cause a catecholamine surge and increase the risk of myocardial infarction. In this case, we will present an ASR as a trigger to a cardiovascular event.

**Case report:** We report a case of a 63-year-old male patient who sought medical care due to chest pain lasting for 10 hours. The onset of pain started two days after the tragic loss of a family member. The patient did not have previous conditions apart from controlled hypertension. Upon the arrival of the emergency team, the patient was conscious and hemodynamically stable. While the vital signs showed no alterations, an electrocardiogram (ECG) presented significant ST-elevation in inferior leads (II, III, aVF) and mirrored ST-depression in V1, V2. During the transport to the ambulance, the patient suffered a myocardial infarction and lost consciousness, respiration, and pulse. The emergency team started advanced life support (ALS). ECG monitor showed ventricular fibrillation (VF), and shock was administered. The patient quickly regained consciousness and pulse and remained stable until his admission to the hospital. During the patient's hospitalization, multiple VFs were recorded with consequential defibrillations. Coronarography showed 100% occluded right coronary artery (RCA), which indicated emergency percutaneous coronary intervention and implantation of three coronary stents. The patient recovered without complications and was discharged eight days after admission.

**Conclusion:** In this case, we wanted to emphasize the connection between an acute reaction to stress and an increased risk of a cardiovascular event. These findings call for enhanced awareness, monitoring and early intervention in patients who experienced a tragic event.

**Keywords:** Acute stress disorder, Heart disease, Risk factors, Myocardial infarction

---

## **ALS and the importance of early primary percutaneous coronary intervention – case report**

Ivan Radaković<sup>1</sup>; Bogdan Radaković<sup>2</sup>

<sup>1</sup> *University of Rijeka, Faculty of Medicine, Rijeka, Croatia*

<sup>2</sup> *Private cardiology clinic Radaković, Poreč, Croatia*

**Corresponding author:** Ivan Radaković, iradakovic1@gmail.com

---

**Introduction:** Advanced Life Support (ALS) is a set of life saving protocols and skills that extend beyond Basic Life Support (BLS). It includes various algorithms that help increase survival rates for patients with sudden cardiac arrest. Primary percutaneous coronary intervention (PCI) is a procedure used to treat the narrowed coronary arteries of the heart. It is indicated if the time from diagnosis to PCI is less than 120 minutes.

**Case report:** A 55-year old male pulled over on a highway because of dizziness. He was found unconscious in his car by an ambulance that happened to be passing by. They found the patient to be in cardiac arrest with VF and CPR was performed immediately. The patient was successfully resuscitated and taken to the ER in KBC Sušak. There the patient had another cardiac arrest where he was successfully resuscitated once again. The patient was then diagnosed with acute coronary syndrome and sent to primary PCI where stents were implanted in the right coronary artery (RCA). Before being released from the hospital the patient received a VVI pacemaker. 6 months after these events the patient is living a healthy and active life.

**Conclusion:** A fast response time to cardiac arrest, both in terms of resuscitation and PCI, leads to good outcomes in patients.

**Keywords:** Cardiac arrest, Cardiopulmonary resuscitation, Percutaneous coronary intervention

---

## **Massive hematochezia stopped by a hemostatic suture - Case report**

Anamaria Zuljani<sup>1</sup>, Hana Vičević<sup>1</sup>, Sandra Knežević<sup>1</sup>, Boris Brozović<sup>2</sup>

<sup>1</sup>*University of Rijeka, Faculty of Medicine, Rijeka, Croatia*

<sup>2</sup>*Clinical Hospital Center Rijeka, Rijeka, Croatia*

**Corresponding author:** Anamaria Zuljani, [anamaria.zuljani@gmail.com](mailto:anamaria.zuljani@gmail.com)

---

**Introduction:** Hematochezia is the passage of fresh blood through the anus, usually in or with stools. It is a bleeding normally coming from the colon, but it can also be a profuse bleeding located in the upper gastrointestinal tract (eg. peptic ulcer). Colonoscopy is a dual diagnostic/therapeutic procedure that allows rapid localization of the source of bleeding and hemostatic interventions.

**Case report:** A 73-year-old patient was transferred to the Gastroenterology department from the post-Covid19 department due to profuse hematochezia. In the post-Covid19 department the patient was stable but when transferred she needed hemodynamic support. She was indicated for a colonoscopy where a large coagulum was found 20 to 25 cm into the sigmoid colon after which the mucosa was clean, with only a few smaller coagulums. The exact location of bleeding was not found despite significant rinsing. Before having surgery, the patient received 2 red cell concentrates and 3 fresh frozen plasmas. The patient had transanal endoscopic surgery where the coagulums were removed and then, 3 cm from the anorectal border, the bleeding site was found. It was determined to be profuse venous bleeding and a hemostatic suture was placed. During the surgery the patient received another 5 red blood cell concentrates and 2 thrombocyte pools. After that the control rectoscopy, that was done until 25 cm, showed no other signs of bleeding. The patient was then transferred to the Intensive care unit of the Gastroenterology department where there was no longer a need for further blood transfusions and the patient was hemodynamically stable. She had no further hematochezias before release.

**Conclusion:** Hematochezia usually presents as minor arterial bleeding that is important because it may come from a rectal or colonic neoplasm. In this case the bleeding was massive, and it came from a venous source.

**Key words:** Colonoscopy, Hematochezia, Sutures, Transanal endoscopic surgery

---

## Status epilepticus refractory to therapy - Case report

Anamaria Zuljani<sup>1</sup>, Sandra Knežević<sup>1</sup>, Hana Vičević<sup>1</sup>, Ivana Žitinić<sup>2</sup>

<sup>1</sup>University of Rijeka, Faculty of Medicine, Rijeka, Croatia

<sup>2</sup>Clinical Hospital Center Rijeka, Rijeka, Croatia

**Corresponding author:** Anamaria Zuljani, anamaria.zuljani@gmail.com

---

**Introduction:** Status epilepticus is a seizure with 5 minutes, or more, of continuous clinical and/or electrographic seizure activity, or recurrent seizure activity, without recovery between seizures. Refractory status epilepticus refers to continuing seizures (convulsive or non-convulsive) despite appropriate antiepileptic drugs

**Case report:** A 75-year-old patient has been brought with the Emergency vehicle because of impaired consciousness and right-sided hemiparesis. In the vehicle he had a seizure and was sedated. The seizures continued throughout his stay at the Emergency department (ED), and they were found to be epileptic grand mal seizures. Because of pyuria the patient was thought to be in urosepsis. He was also previously diagnosed with chronic obstructive pulmonary disease, for which he received home oxygen therapy. While in the ED the patient went into status epilepticus. He received antiepileptic drugs which were not helping. After rapid sequence intubation (RSI), while giving etomidat, the status ended. During the cranial CT, he went into cardiopulmonary arrest and was cardiopulmonary reanimated and defibrillated several times. After the patient regained a steady pulse, the CT showed no pathological lesions. The patient was then transferred to the Intensive care unit of the Anaesthesiology department where every attempt to remove the patient from analgesedation resulted in a grand mal epileptic seizure, which indicated a hypoxic brain injury. In the ICU he went into acute right-sided heart failure. Despite the attempts to stabilize the patient's circulation and respiration, he passed away.

**Conclusion:** Status epilepticus is usually treated with intravenous antiepileptic drugs but in this case the patient didn't respond to this treatment. The status was only stopped after endotracheal intubation performed by the RSI protocol. The probable cause of our patient's secondary status epilepticus were his multiple comorbidities, including global respiratory insufficiency, suspected urosepsis, which cause general hypoxia. This shows us how important it is to think of all the possible etiologies of this state.

**Key words:** Endotracheal intubation, Epileptic seizure, Status epilepticus

---

## Acute pyelonephritis with renal abscesses diagnosis and management - case report

Petar Žauhar<sup>1</sup>; Tea Škoda<sup>1</sup>; Dean Markić<sup>2</sup>

<sup>1</sup>University of Rijeka, Faculty of Medicine, Rijeka, Croatia

<sup>1,2</sup>Department of Urology, Clinical Hospital Centre Rijeka, Rijeka, Croatia

**Corresponding author:** Petar Žauhar, petar.zauhar@gmail.com

---

**Introduction:** Abscess are a rare complication of acute pyelonephritis. In abscesses of smaller diameter (<3cm) primary conservative antibiotic treatment is used, while in large abscesses (>5cm) drainage is indicated. Opinion on the treatment of medium size abscesses is divided, both drainage and conservative treatment are options. Drainage can be performed both percutaneously for smaller and surgically for bigger abscesses.

**Case report:** A 28-year-old woman presented to the Emergency department of Clinical Hospital Centre Rijeka with constant, non-radiating, shooting pain in the lower right quadrant of her abdomen and fever up to 40°C that started three days ago. Patient denies nausea, emesis and other gastrointestinal concerns. Lower abdomen was painful upon deep palpation, with Rovsing's, Bloomberg's and Grassman's signs negative. Patient was examined by an abdominal surgeon and a gynaecologist who excluded both digestive and reproductive pathology. Laboratory results showed her leukocyte count at  $10.2 \times 10^9/L$ , neutrophil count  $7.00 \times 10^9/L$ , monocyte count  $1.10 \times 10^9/L$  and basophile count  $0.10 \times 10^9/L$ , while she had 116.7mg/L CRP value. Urinalysis has described a cloudy urine sample with trace amounts of leukocyte esterase, positive nitrites and haemoglobin, with 2 to 4 erythrocytes, many leucocytes and epithelial cells per field of vision. While chest x-ray was unremarkable, a CT of the abdomen showed right-sided pyelonephritis with two abscesses up to 16mm of diameter and dilatated renal pelvis. Following CT findings, there were no indications for surgical or percutaneous interventions. The patient was admitted to the Clinic for infectious diseases. The next day microbiological results found 100,000+ CFU/mL of *Escherichia Coli* resistant only to ampicillin and sulfamethoxazole-trimethoprim. The therapy started with intravenous co-amoxiclav after which regression of the abscesses and resolution of pyelonephritis was noticed. Three weeks later the patient was completely cured.

**Conclusion:** Renal abscesses are rare complications of pyelonephritis. Conservative antibiotic treatment of small to medium-size abscesses is an adequate treatment for most patients.

**Keywords:** Abdominal pain, Abscess, Infection, Kidney diseases, Pyelonephritis, X-ray computed tomography scanner

---

---



---

## Sponsors and partners

---

We want to thank the following institutions and sponsors for their generosity and support during 6<sup>th</sup> Congress of Emergency Medicine.



---

## Notes

---

---

---

---

---

---

---

---

---

---

---

---

---

---

---

---



---

---