

Focused High Risk - Population Screening for Carotid Stenosis and Retinal Microangiopathia after Radiotherapy for Laryngeal Carcinoma

Strenja-Linić, Ines; Vojniković, Božo; Čaljkušić-Mance, Tea

Source / Izvornik: **Collegium antropologicum, 2010, 34 supplement 2, 49 - 52**

Journal article, Published version

Rad u časopisu, Objavljena verzija rada (izdavačev PDF)

Permanent link / Trajna poveznica: <https://urn.nsk.hr/urn:nbn:hr:184:393030>

Rights / Prava: [In copyright](#)/[Zaštićeno autorskim pravom.](#)

Download date / Datum preuzimanja: **2025-01-01**



Repository / Repozitorij:

[Repository of the University of Rijeka, Faculty of Medicine - FMRI Repository](#)



Focused High Risk – Population Screening for Carotid Stenosis and Retinal Microangiopathia after Radiotherapy for Laryngeal Carcinoma

Ines Strenja-Linić¹, Božo Vojniković², Tea Čaljkušić-Mance³, Robert Tićac⁴, David Bonifačić¹ and Damir Kovačević³

¹ Department of Neurology Rijeka University Hospital, Rijeka, Croatia

² Daily Eye Clinic »Dr. Božo Vojniković«, Rijeka, Croatia

³ Department of Ophthalmology, Rijeka University Hospital, Rijeka, Croatia

⁴ Department of Otorhinolaryngology, Rijeka University Hospital, Rijeka, Croatia

ABSTRACT

Carotid artery stenosis (CAS) is one of the major complications of external irradiation (radiotherapy, RT) for laryngeal carcinoma. Considering amaurosis fugax is often one of the first signs of significant CAS our focus was to determine whether patients with post-irradiation CAS also develop ocular microangiopathy as a result of insufficient ophthalmic circulation. In our study Carotid Duplex ultrasound scans revealed that 33.33% of patients had significant radiation-induced CAS. The majority (over 85.71%) of radiation-induced CAS had more than one atherosclerotic plaque including any degree of stenosis in the RT group, and had significantly more than that of the control group. Microangiopathic changes were documented only with the patients that have had an increased cerebrovascular risk (diabetes mellitus and arterial hypertension).

Key words: carotid artery stenosis, retinal microangiopathia, laryngeal carcinoma, radiotherapy

Introduction

Stroke is the third leading cause of death in the world, and also the leading cause of serious long-term disability, causing functional limitation in elderly population^{1,2}. The clinical burden of stroke and transient ischemic attack now exceeds that of coronary heart disease^{1,3,4,7-10}.

Atherosclerosis accounts for up to one-third of all strokes¹¹⁻¹⁵. Approximately 50% of strokes occur in the distribution of the carotid arteries and patterns of progression of carotid stenosis is unpredictable, diseases may progress quickly or slowly, or remain stable for many years^{4-7,13}. Carotid artery stenosis (CAS) can reduce the risk of ipsilateral ischemic stroke in patients with 70–99% symptomatic carotid stenosis, and in some patients with 50–69% stenosis, if the stenosis is removed quickly^{5,8-11,15}. Carotid stenosis greater than or equal to 50% has been identified in 7% of men and 5% of women older than 65 years^{4,14}. The annual stroke risk in patients with carotid stenosis is most dependent on presence of

symptoms as well as stenosis severity, but is also influenced by the presence of silent cerebral infarction, contralateral diseases, atherosclerotic risk factors, morphology of plaque and etc^{1-4,11,12}. Stroke risk is the highest immediately after the ischemic event.

Carotid artery stenosis (CAS) is one of the major complications of external irradiation (radiotherapy, RT) for laryngeal and neck carcinoma¹⁶⁻¹⁷. Prevalence of carotid arterial disease in patients with previous cervical radiation therapy is high enough to justify routine screening for carotid artery stenosis. The prevalence of critical CA stenosis in patients who have received radiation therapy for head and neck cancer has been reported to be as high as 22%¹⁷. Irradiation may accelerate the development of atherosclerosis, and this vascular injury involves all layers of the vessel wall, with characteristic endothelial cell proliferation, media scarring, loss of smooth muscle and adventitial fibrosis.

The ophthalmic artery is the first major branch of the supraclinoid portion of the internal carotid artery (ICA). Hemodynamically significant CAS can lead to diverse ocular complications, including transient monocular blindness, known as amaurosis fugax, retinal artery occlusion and the ocular ischemic syndrome (OIS)²⁰. Anterior segment fluorescein angiography (FAG) can be performed to evaluate hypoxic ocular conditions in the radiation-induced CAS. FAG characteristically reflects to the status of chronic hypoperfusion of the chorioid and retina.

Considering amaurosis fugax is often one of the first signs of significant CAS our focus was to determine whether patients with post-irradiation CAS also develop ocular microangiopathy as a result of insufficient ophthalmic circulation¹⁶.

Material and Methods

The extracranial carotid arteries of 42 (33 male and 9 female; mean age of 53.6 years) post-irradiation patients with laryngeal carcinoma (International Classification-TNM: T3,T4) were examined with Color Doppler Ultrasound by a vascular neurologist in a Neurosonology Laboratory, at the Department of Neurology, Rijeka University Hospital. We applied Ultrasound screening protocol for radiation-induced carotid stenosis originated in our Neurological Laboratory (Figure 1).

Also, for all of the patients fluorescein angiography (FAG) was performed by an ophthalmologist at the Department of Ophthalmology, Rijeka University Hospital. All of the patients were divided into two groups: post-irradiation patients with and without CAS. Patients without CAS also represented the control group. The distribution of the CAS and the degree of stenosis were documented.

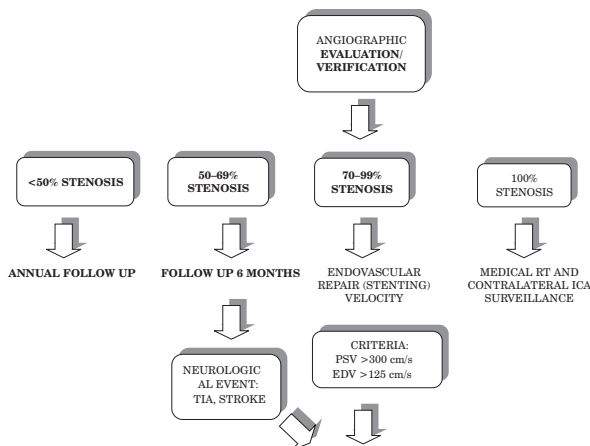
All of the patients with laryngeal carcinoma had been undertaken to total laryngectomy with/without radical neck dissection. The mean duration after radiotherapy in

the RT group was 5.2 years and the mean dosage of irradiation was 6000 cGy in the neck area.

Incidences of risk factors for arterial stenosis such as treated hypertension, smoking, treated diabetes and hypercholesterolemia in these two groups were also monitored. The data was analyzed by the Fisher exact test.

Results

The average age of patients in the study group with radiation-induced CAS was 53.6 years, and that of the control group without CAS 66.8 years. The median follow up since RXT was 5.2 years. Duplex ultrasound scans revealed that 14 (33.33%) of patients had significant radiation-induced CAS. Five patients (11.9%) had unilateral carotid occlusion (Figure 2) and four patients (9.52%) have had stroke after radiation therapy. The majority (over 85.71%) of radiation-induced CAS had more than one atherosclerotic plaque including any degree of stenosis in the RT group, and had significantly more than that of the control group (Figure 3). Male patients are significantly more prevalent in CAS group than female ($p >$



CAS-carotid stent-assisted angioplasty, PSV-peak systolic velocity, ICA-internal carotid artery, TIA- transient ischemic attack, RT-radiotherapy.

Fig. 1. Ultrasound screening protocol and patient management for radiation-induced carotid stenosis.

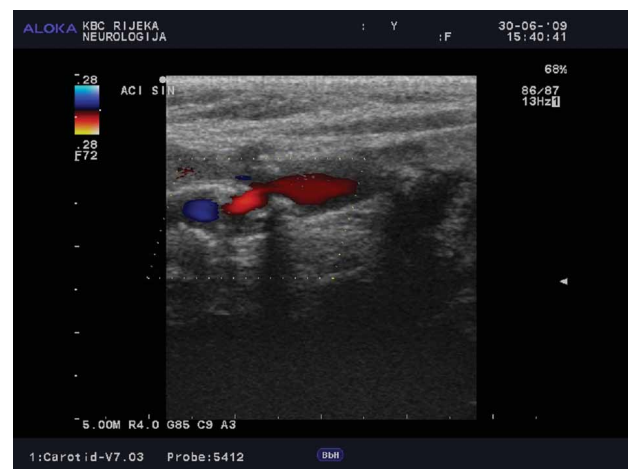

Fig. 3. Radiation-induced carotid stenosis.

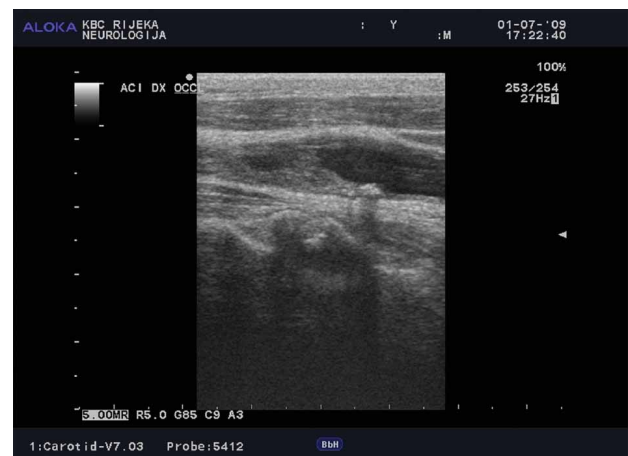

Fig. 2. Radiation-induced occlusion of internal carotid artery.

TABLE 1
PATIENT CHARACTERISTICS AND COMORBIDITIES

Variable (n=42)	Significant stenosis	No significant stenosis	p value
Number of patients	14	28	–
Mean age (years)	53.6	66.8	–
Sex			
Male	14	19	0.0154
Female	0	9	
Cumulative radiation dosage (cGy)	6,000	6,000	–
Mean follow up since XRT	5.2 yrs	5.2 yrs	–
Combination surgery with XRT	14	28	–
Stroke	4	5	0.220
Current tobacco use	10	22	0.231
Coronary artery disease	4	7	0.277
Prior stent or surgical bypass graft mellitus	3	6	0.307
Hypertension	10	19	0.271
Diabetes mellitus	5	5	0.134
Hyperlipidemia	5	8	0.244
Chronic renal failure (creatinine >2)	1	2	0.461
Atrial fibrillation	1	3	0.410

0.0154) (Table 1). Microangiopathic changes (performed FAG) were documented only with the patients that have had an increased cerebrovascular risk (diabetes mellitus and arterial hypertension) and in both group of our patients: with and without CAS. In this patients FAG showed delayed chorioidal filling, delayed retinal arterial filling and slow arteriovenous transit time.

Discussion and Conclusion

The prevalence of carotid arterial disease in patients with prior cervical radiation therapy is clinically significant and warrants aggressive screening as part of routine pre-radiation and post-radiation care. Proposed mechanism is a combination of direct vessel wall damage, with intimal proliferation, necrosis of media and also accelerated atherosclerosis and indirect effects as a result of radiation-induced obliteration of the adventitial vasa vasorum^{18,19,21}. Our results support this thesis, because

the majority of radiation-induced CAS has more than one atherosclerotic plaque.

This study has also shown that radiation could cause significant carotid stenosis, but not ocular microangiopathy.

Changes in the domain of ocular microcirculation had only been documented with the patients with the usual cerebrovascular risk factors (diabetes mellitus and arterial hypertension). Yearly ultrasound examinations for RT patients are therefore necessary for screening and early detection of carotid stenosis and to increase the possibility of intervention for this late radiation-induced complication¹⁷.

Carotid artery disease that occurs as a result of radiation therapy or radical neck dissection is considered a clear indication for endovascular therapy and CA angioplasty and stent placement has become an ultimate treatment strategy for this particularly challenging group of individuals¹⁶.

REFERENCES

- ROTHWELL PM, COULL AJ, SILVER LE, Lancet, 366 (2005) 1773. — 2. WARDLAW JM, STEVENSON MD, CHAPPELL F, ROTHWELL PM, GILLARD J, YOUNG G, THOMAS SM, RODITI G, GOUGH MJ, Stroke, 40 (2009) 3511. — 3. ROTHWELL PM, ELIASZIW M, GUTNIKOV SA, Lancet, 361 (2003) 107. — 4. ROTHWELL PM, MEHTA Z, HOWARD SC, GUTNIKOV SA, WARLOW CP, Lancet, 365 (2005) 256. — 5. NORTH AMERICAN SYMPTOMATIC CAROTID ENDARTERECTOMY TRIAL COLLABORATORS, N Engl J Med, 325 (1991) 445. — 6. BARNETT HJ, GUNTON RW, ELIASZIW M, FLEMING L, SHARPE B, GATES P, MELDRUM H, JAMA, 283 (2000) 1429. — 7. ROTHWELL PM, SLATTERY J, WARLOW CP, Stroke, 27 (1996) 260. — 8. BULAT C, ALFIREVIĆ I, KORDA ZA, PROTRKA N, NOVOSKI M, PREDRIJEVAČ M, Coll Antropol, 32 (2008) 209. — 9. DE SYO D, BJÖRN D, FRANJIĆ, LOVRIČEVIĆ I, VUKELIĆ M, PALENKIĆ H, Coll Antropol, 29 (2005) 627. — 10. BOŠNJAK PAŠIĆ M, VARGEK SOLTER V, ŠERIĆ V, URMOVIĆ M, VIDRIH B, LISAK M, DEMARIN V, Coll Antropol, 29 (2005) 623. — 11. VIDJAK V, HEBRANG A, BRKLJAČIĆ B, BRAJŠA M, KARLO N, ANTE B, Coll Antropol, 31 (2007) 723. — 12. VIDJAK V, HEBRANG A, BRKLJAČIĆ B, BRAJŠA M, NOVAČIĆ K, BARADA A, Coll Antropol, 31 (2007) 775. — 13. ŽUNTAR IN, VRKIĆ N, TOPIĆ E, KUJUNDŽIĆ N, DEMARIN V, VUKOVIĆ V, Coll Antropol, 30 (2006) 871. — 14. REINER-TEDESCHI E, REINER Ž, IVEKOVIĆ R, NOVAK-LAUŠ K, PINTARIĆ I, Coll Antropol, 26 (2002) 615. — 15. ROBERT DE, DONOVAN MT, HOPKINS NL, Neurosurg Focus, 18 (2005) 8. — 16. MORITZ MW, HIGGINS RF, JACOBS JR, Arch Surg, 125 (1990) 1181. — 17. DUBEC JJ, MUNK PL, TSANG V, LEE MJ, JANZEN DL, BUCKLEY J, Br J Radiol, 71 (1998) 872. — 18. CARMODY BJ, ARORA S, AVENA R, J Vasc Surg, 30 (1999) 1045. — 19. TAKAYUKI B, KYOKO I, RITSUKO T, TSUTOMU K, MOTOHIRO K, FUJIO N, Jpn J Ophthalmol, 43 (1999) 546. — 20. FAJARDO LF, Cardiovasc Radiat Med, 1 (1999) 108.

I. Strenja-Linić

*Department of Neurology, Rijeka University Hospital, Cambierieva 17/8, 51000 Rijeka
e-mail: medines4@yahoo.com*

CILJANI PROBIR VISOKORIZIČNE POPULACIJE ZA KAROTIDNU STENOZU I RETINALNU MIKROANGIOPATIJU NAKON RADIOTERAPIJE KARCINOMA LARINKSA

S A Ž E T A K

Stenoza karotidne arterije (KAS) jedna je od glavnih komplikacija radijacijske terapije (radioterapija, RT) laringealnog karcinoma. Uzimajući u obzir da je amaurosis fugax jedan od prvih znakova značajne KAS, naš cilj je bio utvrditi da li pacijenti sa postradijacijskom KAS razvijaju i očnu mikroangiopatiju kao rezultat insuficijencije oftalmičke cirkulacije. U našoj studiji nalazi dobiveni učinjenom ultrazvučnom doppler pretragom karotidnih arterija potvrđuju da 33% pacijenata ima značajnu postiradijacijsku KAS. Većina (preko 85,71%) radijacijom induciranih KAS imali su više od jednog aterosklerotskog plaka uključujući razne stupnjeve stenozu u RT grupi, također značajno više nego u kontrolnoj grupi. Mikroangiopatske promjene oka su dokumentirane samo kod pacijenata koji su imali povećani cerebrovaskularni rizik – šećernu bolest, te arterijsku hipertenziju.