

# Giant Pseudocyst of the Rectus Femoris Muscle - Repetitive Strain Injury in Recreational Soccer Player

---

Cicvarić, Tedi; Lučin, Ksenija; Roth, Šandor; Ivančić, Aldo; Marinović, Marin; Šantić, Veljko

Source / Izvornik: **Collegium antropologicum, 2010, 34 supplement 2, 53 - 55**

Journal article, Published version

Rad u časopisu, Objavljena verzija rada (izdavačev PDF)

Permanent link / Trajna poveznica: <https://um.nsk.hr/um:nbn:hr:184:155032>

Rights / Prava: [In copyright](#)/[Zaštićeno autorskim pravom.](#)

Download date / Datum preuzimanja: **2024-05-22**



Repository / Repozitorij:

[Repository of the University of Rijeka, Faculty of Medicine - FMRI Repository](#)



# Giant Pseudocyst of the Rectus Femoris Muscle – Repetitive Strain Injury in Recreational Soccer Player

Tedi Cicvarić<sup>1</sup>, Ksenija Lučin<sup>2</sup>, Šandor Roth<sup>3</sup>, Aldo Ivančić<sup>1</sup>, Marin Marinović<sup>1</sup> and Veljko Šantić<sup>4</sup>

<sup>1</sup> Clinic for Surgery, University Hospital of Rijeka, Rijeka, Croatia

<sup>2</sup> Department of Pathology, Medical Faculty, University of Rijeka, Rijeka, Croatia

<sup>3</sup> Institute for Children's Orthopaedics, University Hospital of Rijeka, Rijeka, Croatia

<sup>4</sup> Clinic for Orthopedic Surgery, Lovran, Croatia

## ABSTRACT

*We report a case of a traumatic pseudocyst, in a recreational soccer player, after rupture of rectus femoris muscle. 37-year-old male, with history of repetitive painful accidents, was examined because of a double fist-sized mass in the anterior thigh. Ultrasound examination revealed a cystic mass in the rectus femoris muscle. Surgical removal of the mass and proximal remnant of muscle was done. Primary healing and functional recovery was achieved. Histological analysis revealed pseudocyst filled with degenerating clot and surrounded with thick fibrous capsule. The repetitive strain muscle injury, with prolonged period of healing, can occur like pseudocyst.*

**Key Words:** diagnosis, muscle strain, pseudocyst, rectus femoris muscle, surgery, ultrasound

## Introduction

Muscle tumors are rare in young adults. The most common are sarcomas, with the lower extremity, especially the thigh, accounting for the majority of the cases<sup>1–3</sup>. Benign soft tissue tumors are usually located above the superficial fascia, with only 1% arising in the deep soft tissue or muscle<sup>4</sup>. Differential diagnosis includes reactive conditions such as nodular fasciitis, different form of myositis, metastases and pseudotumors as a result of inflammation or trauma<sup>5–13</sup>.

We report a case of a traumatic pseudocyst of muscle rectus femoris. To the best of our knowledge, it has not yet been published in relevant literature. Pseudocysts are only mentioned as a wrapper of the rectus femoris deep tendon in the chronic strain injuries<sup>8</sup>.

## Case Report

A 37-year-old male was examined in out-patient clinic because of mass in the anterior thigh. The patient had a history of the repetitive painful accidents during recreational soccer plays. The first accident occurred 3 years

ago. At the end of the soccer play, while he was striking the ball, he felt the strong pain followed by the audible pop in the anterior thigh, which forced him to leave the game. He treated himself with ice and rest. After two months the mass appeared, but the patient continued to play soccer two to three times a week. During this period, the mass remained of the same size.

The physical examination revealed a double fist-sized, painless mass in the proximal thigh (Figure 1). The mass was hard with smooth surface. It was fixed to the deep tissue layers. Skin and subcutaneous tissue were not indurated. The mass was movable with contraction of quadriceps muscle. The thigh circumference was 13 cm wider in comparison to the opposite thigh. The knee flexion was limited for 15° and patient was slightly limping on his right leg.

An ultrasound examination was performed with a linear 7.5-MHz and 3.5-MHz convex-array transducer (Shimadzu SDU-400, Shimadzu Corporation, Kyoto, Japan). It revealed a big cystic mass, measuring 108×78 mm longitudinally (Figure 2a). The mass was located be-

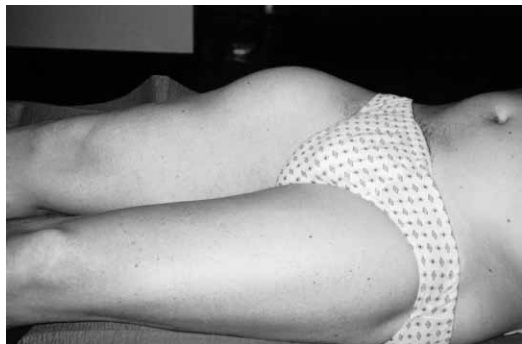

Fig. 1. Double fist-sized, painless mass in the proximal right thigh.

tween vastus muscles and subcutaneous tissue. It had thick hyperechoic clear border from surrounded muscles. Towards the proximal part of the rectus femoris muscle it had irregular border in a zone of 15 to 20 mm (Figure

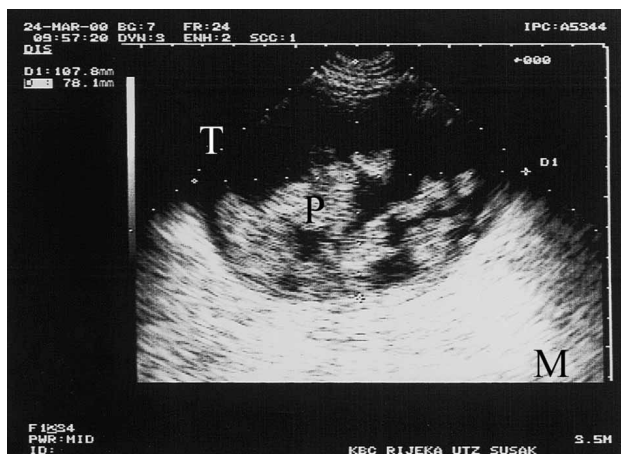


Fig. 2a. Cystic mass (T) 107.8×78.1 mm with papillomatous floating formations (P) surrounded by normal muscle (M).

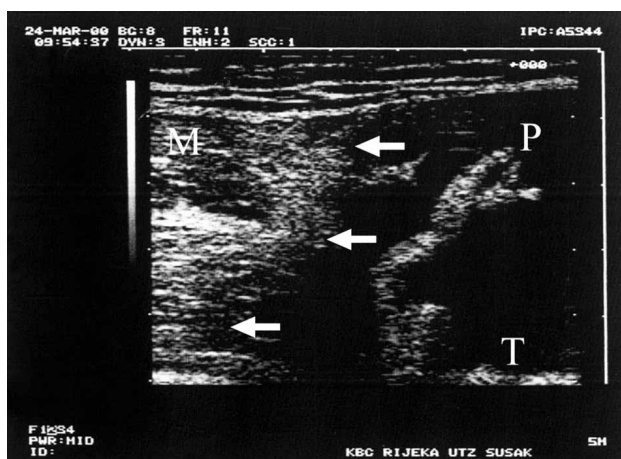


Fig. 2b. The irregular border (arrows) between proximal, normal muscle (M) and the mass (T). (P) - Papillomatous floating formation.

1b). In the cyst the homogenous, hyperechoic irregular floating papillomatous formations were seen (Figure 2a, 2b). The sonographic guided puncture was performed and chocolate-colored liquid was partially evacuated. Cytological analysis revealed fresh and hemolysed erythrocytes with a lot of pigmentophages, crystals and basophilic amorphous substance. The analysis suggested hematoma. The bacteriological culture was sterile. CT scan confirmed the large cyst in the anterior thigh, but the internal substance was homogenous. MRI was not available at that time.

In general anesthesia, the whole tumor with proximal part of the rectus femoris muscle was removed through anterior skin incision. The plan of dissection was subfascial and between the vastus muscles. There was no infiltration of surrounding structures. The wound was drained and closed by layers. Primary healing was achieved. Section throughout the mass showed cystic formation with hard fibrous wall filled with chocolate colored fluid and soft fibrin-like papillomatous formations (Figure 3). Histological analysis revealed cyst formation filled with degenerating clot and surrounded with thick fibrous capsule, formed by hyaline collagenous tissue. Toward cyst lumen, fibrous tissue was infiltrated by mononuclear cells, predominantly foamy or hemosiderin laden macrophages, and lymphocytes. Also, a lot of cholesterol crystals surrounded by multinuclear giant cells were seen, as a sign of old hemorrhage.

Patient recovered his daily activities after 2 to 3 weeks, and become fully active in soccer about 6 months later. Three years later, he does not feel any physical disability and plays soccer two to three times a week. The defect of rectus femoris muscle is still clinically visible, although the mid-thigh circumference of 54 cm is of the same size like opposite thigh.

### Discussion

Although it rarely occurs in young people, a possibility of malignant tumor should be firstly ruled out. Physical examination, duration of symptoms, history of trauma,

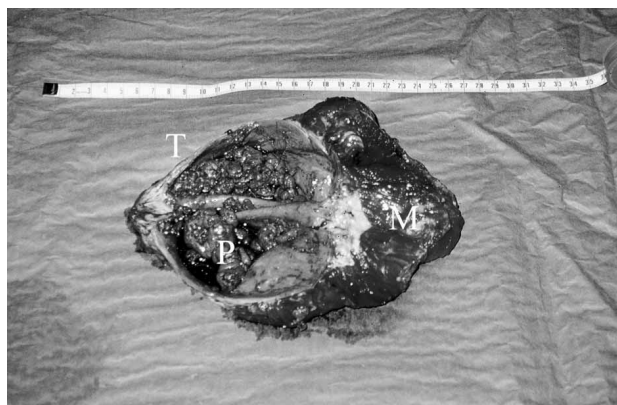


Fig. 3. The mass (T) and papillomatous formations (P) with proximal part of the rectus femoris muscle (M) after surgical removal.

ultrasound findings and cytological analysis indicated a benign nature of the lesion. The histological analysis, which corresponded to old, degenerating and encapsulated hematoma, confirmed a traumatic origin of the lesion.

Surgery was indicated due to esthetic impairment and large size of the mass. Less invasive approach (incision, drainage) was ruled out because we did not suspect the cavity with such thick fibrous capsule to obliterate. Minimally invasive approach is indicated in a case of hematoma after the muscle rupture<sup>9,10</sup>.

After three years of recreative soccer play the patient regain the muscle mass of the thigh and full activity even his rectus femoris was missed. This may be an interesting data for rehabilitation after knee injuries<sup>11</sup>.

The muscle strains are common injuries in sports<sup>12–16</sup>. Strain injury of the rectus femoris muscle is typical for

soccer players<sup>8</sup>. Temple published the article about the pseudo-tumor as a consequence of rectus femoris tear<sup>6</sup>. In seven active patients they found only one with specific trauma event, while the others had an active lifestyle but without clear injury in history. In our patient repetitive injuries were documented in the last few years, with the result of growing hematoma. Due to its large size, the process of healing was slow, resulting in encapsulated cystic mass.

## Conclusion

It is important to anticipate that repetitive muscle strain injuries can occur like large pseudocyst.

## REFERENCES

1. TROJANI M, CONTESSO G, COINDRE JM, ROUESSE J, BUI NB, DE MASCAREL A, GOUSSOT JF, DAVID M, BONICHON F, LAGARDE C, *Int J Cancer*, 33 (1984) 37. — 2. TSUJIMOTO M, AOZASA K, UEDA T, MORIMURA Y, KOMATSUBARA Y, DOI T, *Cancer*, 62 (1988) 994. — 3. NAKANISHI H, ARAKI N, SAWAI Y, KUDAWARA I, MANO M, ISHIGURO S, UEDA T, YOSHIKAWA H, *Skeletal Radiol*, 32 (2003) 701. — 4. MYHRE-JENSEN O, *Acta Orthop Scand*, 52 (1981) 287. — 5. GALLOWAY HR, DAHLSTROM JE, BENNETT GM, *Australas Radiol*, 45 (2001) 347. — 6. TEMPLE HT, KUKLO TR, SWEET DE, GIBBONS CL, MURPHEY MD, *Am J Sports Med*, 26 (1998) 544. — 7. MAGEE T, ROSENTHAL H, *Am J Roentgenol*, 178 (2002) 985. — 8. GARRETT WE, *Am J Sports Med*, 24 (1996) S2. — 9. CICVARIĆ T, ŠUSTIĆ A, MILETIĆ

D, VESELKO M, MOZETIĆ V, ŠPANJOL J, *Arthroscopy* 22 (2006) 912 — 10. CICVARIĆ T, ŠUSTIĆ A, MILETIĆ D, *Acad Emerg Med*, 26 (2006) 359. — 11. UREMOVIĆ M, PASIĆ MB, SERIĆ V, SOLTER VV, BUDIĆ R, BOSNJAK B, CVIJETIĆ-AVDAGIĆ S, SOLTER D, DEMARIN V, *Coll Antropol*, 28 (2004) 227. — 12. NOOAN TJ, GARRETT WE, *J Am Acad Orthop Surg*, 7 (1999) 262. — 13. TOMAZIN K, SKOF B, DOLENEC A, COH M, *Coll Antropol*, 32(3) (2008) 821. — 14. MARKOVIC G, SEKULIC D, MARKOVIC M, *Coll Antropol*, 31(3) (2007) 787. — 15. HAS B, NAGY A, HAS-SCHON E, PAVIC R, KRISTEK J, SPLAVSKI B, *Coll Antropol*, 30(4) (2006) 823. — 16. MIJATOVIĆ D, BULIĆ K, NIKOLIĆ V, *Coll Antropol*, 30(3) (2006) 593.

T. Cicvarić

*Klinika za kirurgiju, Odjel za traumatologiju, KBC Rijeka, Tome Strišića 3, 51000 Rijeka, Croatia*  
e-mail: [tedi\\_cicvaric@yahoo.com](mailto:tedi_cicvaric@yahoo.com)

## DIVOVSKA PSEUDOCISTA RAVNOG BEDRENOG MIŠIĆA – PONAVALJANA OZLJEDA U NOGOMETASA

### SAŽETAK

Prikazan je slučaj traumatske pseudociste nakon rupture ravnog bedrenog mišića u nogometaša. Klinički je evaluiran 37-godišnji muškarac s anamnezom višestrukih udarac i palpabilnom tvorбом u gornjoj trećini prednje strane desnog bedra. Ultrazvukom dokazana je pseudocistična formacija u ravnom bedrenom mišiću. Tvorba kao i ostatni, proksimalni dio ravnog mišića bedra kirurški su odstranjeni. Postignuto je primarno cijeljenje i oporavak. Patohistološki radilo se o pseudocisti s debelom fibroznom kapsulom ispunjenoj dijelom nekrotičnim detritusom. Ponaavljane ozljede mišića s produljenim cijeljenjem mogu rezultirati nastankom pseudociste.