

Histomorphological Analysis of the Osteophytic Appositions in Patients with Lumbar Lateral Recess Syndrome

Bajek, Goran; Bajek, Snježana; Zoričić Cvek, Sanja; Bobinac, Dragica; Splavski, Bruno; Šepić Grahovac, Dubravka

Source / Izvornik: **Collegium antropologicum, 2010, 34 supplement 2, 79 - 84**

Journal article, Published version

Rad u časopisu, Objavljena verzija rada (izdavačev PDF)

Permanent link / Trajna poveznica: <https://urn.nsk.hr/urn:nbn:hr:184:982085>

Rights / Prava: [In copyright](#) / [Zaštićeno autorskim pravom.](#)

Download date / Datum preuzimanja: **2024-06-17**



Repository / Repozitorij:

[Repository of the University of Rijeka, Faculty of Medicine - FMRI Repository](#)



Histomorphological Analysis of the Osteophytic Appositions in Patients with Lumbar Lateral Recess Syndrome

Goran Bajek¹, Snježana Bajek², Sanja Zoričić Cvek², Dragica Bobinac², Bruno Splavski³ and Dubravka Šepić Grahovac⁴

¹ Department of Neurosurgery, Rijeka University Hospital, Rijeka, Croatia

² Department of Anatomy, Rijeka University School of Medicine, Rijeka, Croatia

³ Department of Neurosurgery, Osijek University Hospital, Osijek, Croatia

⁴ Polyclinic »Interneuron«, Rijeka, Croatia

ABSTRACT

Patients with lumbar lateral recess syndrome (LRS) can be successfully cured by removing osseous excrescences that grow on the peripheral edge of articular surface of the facet joint. They cause narrowing of the lateral recess and compress a root of the spinal nerve. Their appearance is related to the instability of respective dynamic vertebral segment. The aim of this study was to analyze the osteophytic composition morphohistochemically and elucidate cellular processes that lead to this new formation appearance. It is necessary to find a possible causative-consequential relation between the osteophyte and instability. The ideal object to explore was the osteophyte in the lateral recess because it had to be removed during operative treatment. The group of 30 patients with clinical feature of LRS was chosen. Each patient had clinically verified LRS with consequential radiculopathy. Bony outgrowths were removed surgically and analyzed by histological and immunohistochemical methods: toluidine blue, Goldner trichrome, TRAP, indirect peroxidase with antibodies against BMP 3 and BMP 7. The outgrowths that caused lateral recess stenosis were composed of fibrous and hyaline cartilage and cancellous bone. The changes in cartilage and bone, and occurrence of intramembranous bone formation in sense of enlargement of trabeculae, leads to the conclusion that marginal osteophytic formations could be an adaptation to changed conditions in the dynamic vertebral segment and an attempt to stabilize this segment by enlargement of articular surface.

Key words: lumbar lateral recess syndrome, osteophyte, instability, intramembranous bone formation

Introduction

The importance of articular processes and their changed articular surfaces became object of interest as a source of lumbar painful syndrome. A modern approach to spinal stenosis and to the syndrome of lateral recess dates from year 1954 when Verbiest described intermittent nature of pain and sensitive and motor symptoms in lower limbs of patients with spinal stenosis. Spinal stenosis and intermittent neurogenic claudication are frequent topics of many neurosurgical, neurological and orthopedic publications¹⁻⁴. Although the causative-consequential relation between a prominent excrescence and compressed root of spinal nerve is known, and therefore

became a base for successful surgical treatment, the etio-pathogenesis of these changes has not been completely clarified after sixty years of research and the experience in curative treatment.

Every increase of mobility of vertebral dynamic segment, within physiological loadings, points to biomechanical instability of spine. That can be a consequence of trauma, illness or condition after surgical treatment. Instability of spine was subject of many studies, and the works of Roy-Camill, Junghans and Louis represent basic researches in biomechanical approach. Changes in stability lead to a combination of various painful symp-

toms well known as low back pain. Disc degeneration with disc space narrowing modifies the normal biomechanics of the mobile segment and affects the facet joints. The consequence is instability leading to re-stabilisation by fibrosis and osteophytic formation. Clinical symptoms in the instability are heterogeneous, depending on the segment level, the degree of affection of neural structures, and also present an important psychological and a social component. Newly formed bony outgrowths on the margins of articular surfaces could, enlarging articular surfaces, stabilize relation between two vertebrae additionally. That could be physiological reaction on instable spine, with a purpose to stabilize vertebral column. Therefore the investigation of histological morphology of the osteophytes with the aim to distinguish processes that result with forming a new bony outgrowth, is important for correct interpretation and possible confirmation of cause-effect relationship between those osteophytes and instability. An ideal object for analysis is just bony outgrowth from margin of articular surface, in region of lateral recess, because it has to be removed during surgical treatment.

Osteophytes are bony outgrowths mostly formed on the margin of articular surfaces of osteoarthritic joints. Although several terms are used for those excrescences such as spurs or bony excrescences, most often are named osteophytes. Some other names also exist for outgrowths that are not related to articular surfaces: spondylophytes for those that appear on vertebral bodies, or entesophytes for those on insertions of ligaments and tendons to the bones. Of all articular osteophytes the most described are those developed in large joints, as a hip and a knee. It is observed that they mostly appear on regions of the joint that are not directly loaded or are exposed to lesser burdening⁵. It is considered that osteophyte develops mostly as a reparative response of damaged articular cartilage. Blood vessels enter into cartilage and the osseous tissue is being formed on its eroded surfaces through process of endochondral ossification. An osteophyte can also arise through process of intramembranous bone formation in which cells of synovial membrane form osseous tissue⁵. However, the osteophyte is mostly formed by both processes of bone forming, endochondral and intramembranous^{6–10}. Relations between degenerative disorders of spine and osteophytes were researched in numerous radiological and morphological studies but only several studies analysed histomorphology of those spinal outgrowths in humans^{8,11,12}. Therefore experiments were made on animal models as attempt to elucidate the mechanism of the vertebral osteophyte formation^{13,14}. During the lifetime fully grown bones change their internal structure due to continuing process of bone remodelling. That process is an adaptation to stresses and strains that prevail upon some bone. Depending on biomechanical condition applied to the bone surface, bone formation or bone resorption proceeds or that surface remains inactive¹⁵. Those processes occur in cancellous, trabecular, as well as in compact, cortical bone.

Bone morphogenetic proteins (BMPs) are signalling proteins that influence on morphogenesis in different systems during the development and growth in embryonal and postnatal life. Some members of BMP family control different morphological processes during bone and cartilage forming. BMP-3 or osteogenin influences on intramembranous formation and on maintaining of extracellular matrix in cartilage¹⁶. BMP-7 or osteogenic protein -1, is important in metabolism of cartilage and bone and induces endochondral bone formation¹⁷. Several growth factors and bone morphogenetic proteins were analysed in osteophytes of hip and knee joints in humans to clarify their role in osteophyte development^{9,18}.

From the clinical aspect it is important to discern patoanatomical basis of lateral syndrome recess in each patient, specially in a young one with monosegmental changes without another signs of spondylarthrotic changes. This is emphasized because of unjustly ingrained attitude that lateral recess syndrome is mainly feature of third age. In order to understand growth of osteophytes from the area of zygapophysial joints, we analysed the material obtained from patient undergoing surgery due to lumbar lateral recess syndrome.

Materials and Methods

The study was performed on osteophytes obtained from 30 patients (12 women) operated on for lateral recessus stenosis (LRS); middle age 51.4 years. The patients did not suffer from chronic disease, endocrine disorder or malignant disease. LRS was on L4/L5 level in 16 patients, on L5/S1 level in 10 patients and in 4 patients on both levels. Patients had no discal hernia, what was proved during diagnostic procedure with CT or NMR, although disc space narrowing was present. The operative approach was planned with intention to preserve ligamental apparatus maximally. Surgical procedure was done under microscope control. In 13 patients interlaminectomy was applied and in 7 patients bilateral interlaminectomy. Interarcual laminectomy was performed in four patients and unilateral approach for bilateral undercutting facetectomy in six patients. Bony outgrowth that narrowed lateral recess was removed and spinal root was released from the compression. The research was approved by local ethics committee and informed written consent was obtained from patients.

Tissue samples were washed in saline and immediately fixed in 4% paraformaldehyde for several hours and embedded in a methyl methacrylate. They were sectioned on rotatory microtome (Leica RM 2155) equipped with tungsten carbide knife. Sections were stained with toluidine blue and Goldner trichrome method. Histochemical detection of tartaric acid resistant phosphatase was used to present osteoclastic activity, while immunohistochemical method of indirect immunoperoxidase was performed with goat polyclonal antibodies BMP-3 and BMP-7 (Santa Cruz, CA, USA).

Results

According to morphology of cells and staining pattern of extracellular matrix, on the surface of analysed tissue samples, a layer of cartilage with characteristics of transitional form from fibrous to hyaline cartilage was noticed. Cancellous bone was placed below that layer. On the peripheral parts of osteophyte, surface, cartilage tissue traversed into connective tissue, while the osseous tissue of osteophyte continued basally into vertebral bone tissue (Figure 1). The majority of the osteophytes were covered with hyaline cartilage whose superficial layer contained elongated chondrocytes parallel with surface of cartilage. The chondrocytes in its deeper layer were round, larger and dispersed. Beneath that area they were arranged in columns or irregularly. In some areas where the superficial cartilage was changed, hypertrophied chondrocytes and chondrocyte clusters were present; such a formation is sign of degenerative changes of hyaline cartilage. The matrix that surrounded those formations displayed stronger metachromasia, while neighbouring parts were uncolored with toluidine blue staining. In some samples the presence of hyaline cartilage in deeper parts of the osteophyte, i.e. on the surfaces that underwent active process of osteogenesis, was noticed (Figure 2). Such a cell and tissue pattern pointed to unevenness in arrangement of tissues observed in the conformation of the osteophyte. However, those samples were

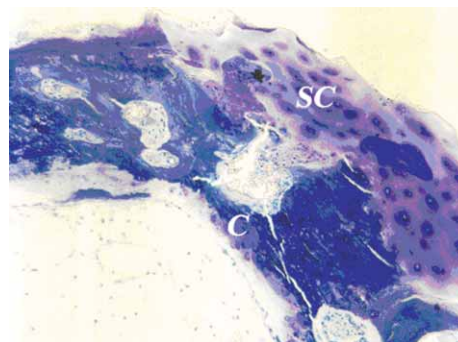


Fig. 2. Hyaline cartilage (C) in the inner part of the osteophyte on the wall of the cancellous bone spaces. Superficially is cartilage of the osteophyte (SC). Toluidine blue, 400X.

noticed very rarely, so, with regard to that, it could not be concluded whether the bone in that area developed by endochondral or intramembranous formation. On the surface of few osteophytes was fibrous but not hyaline cartilage. Such a cartilage had typical cellular morphology and staining of extracellular matrix; cells were elongated or spindly and matrix was abundant and did not show metachromasia in toluidine blue staining. The deeper part of that layer, contiguous to the subchondral bone, exhibited weak metachromasia and higher cellular density.

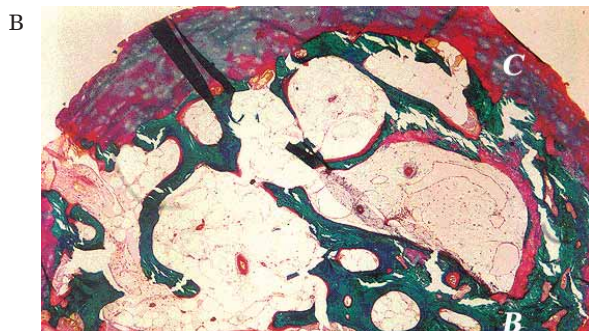
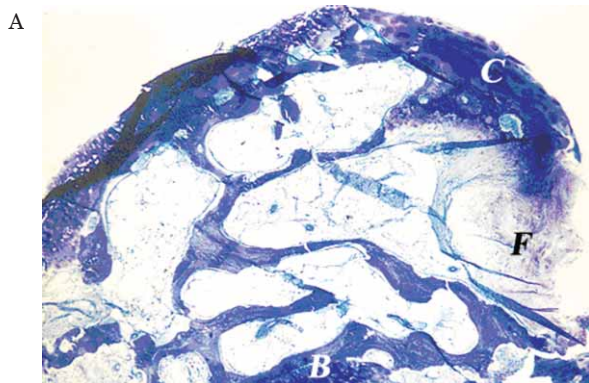


Fig. 1. Hyaline cartilage on the surface of the osteophyte (C) continues peripherally to fibrous tissue (F). Cancellous bone continues basally to vertebral bone tissue (B). a) – Toluidine blue, b) – Goldner trichrom, 40X.

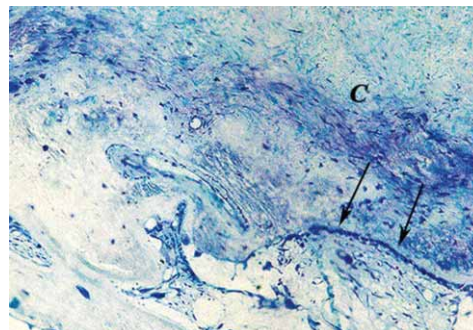


Fig. 3. On the periphery of superficial part of the osteophyte the osteoblasts cover bony trabecula (arrow). Toluidine blue, 40X.

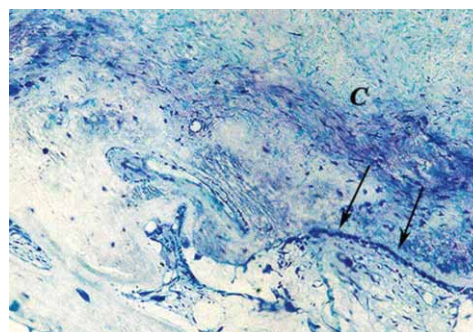


Fig. 4. The chains of osteoblasts (arrows) cover bony trabecula. Fibrous cartilage on the surface of the osteophyte (C). Toluidine blue, 200X.

The surface of periphery of the osteophyte was covered with connective tissue that contained blood vessels. In several specimens in that area, osteoblasts that covered subchondral bone, forming a layer of osteoid, were noticed (Figures 3 and 4). That represented the area of active intramembranous bone formation on the surface of osteophyte. Deeper part of osteophyte was predominantly composed of trabecular osseous tissue with lamellar structure, although immature bone tissue was presented sporadically. The islets of hyaline cartilage were located in the middle parts of some trabeculae (Figure 5). The surfaces of trabeculae were differently covered in some samples; in some osteophytes those were overlaid by quiescent lining cells, while in the others a thicker stratum of osteoid covered by osteoblasts was seen (Figure 6) or young osteocytes embedded in surrounding nonmineralized matrix (Figure 7). The trabeculae became thicker and intertrabecular spaces smaller due to such a process of intramembranous bone formation what led to bone sclerosation. A forming of tunnels whose blind ends were filled up with multinuclear cells was noticed in several samples. Those cells were osteoclasts, what was demonstrated by histochemical detection of tartaric resistant acid phosphatase (Figure 8). However, osteoclasts were observed rarely, because in the majority of the osteophytes (18 patients) bony trabeculae were thickened and intertrabecular spaces were diminished.

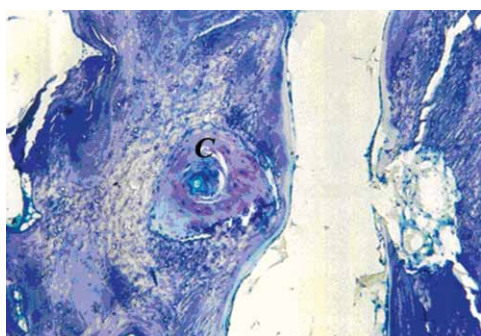


Fig. 5. The islets of hyaline cartilage (C) in subchondral bone. Toluidine blue, 100X.

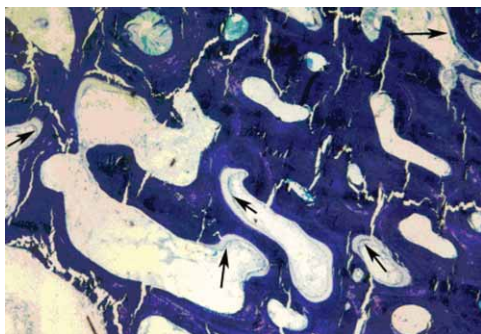


Fig. 6. The intramembranous bone formation in deeper parts of the osteophyte. Osteoblasts deposit osteoid. Toluidine blue, 100X.

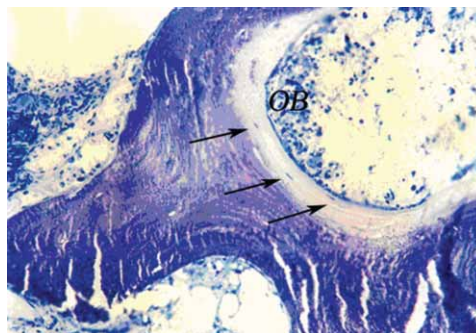


Fig. 7. The osteocytes (arrows) embedded in osteoid of trabecula formed by osteoblasts (OB). Toluidine blue, 400X.

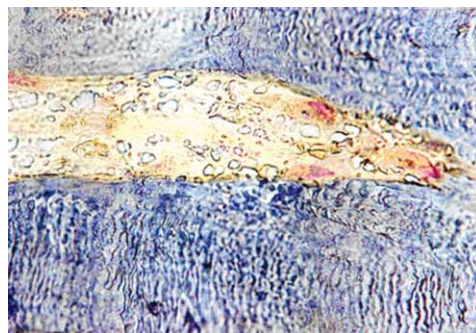


Fig. 8. The activity of osteoclasts demonstrated (red) by method for tartaric resistant acid phosphatase, 400X.

The expression and localisation of two bone morphogenetic proteins with already known function in cartilage and bone metabolism, BMP-3 and BMP-7, were analyzed. The distribution and expression of those morphogens were similar in the majority of samples. The most pronounced expression of BMP-3 and -7 was observed in osteoblasts and newly formed nonmineralized matrix in area of trabecular bone with active intramembraneous bone formation. They were also expressed in cartilage cells, mostly in hypertrophied chondrocytes, while the matrix was negative.

Discussion and Conclusion

It is known from the clinical practice that marked proliferation of the osteophytes may result in limited mobility of a joint because of changed congruence of the articular surfaces. In an advanced stage they can limit the movement and in a certain way immobilise the joint. It is obviously that organism in that way stabilized that segment and reduced the range of motion in order to diminish the pain. In such a process of adaptation the osteophytes of lumbar zygapophyseal joints can be also involved.

The articulations of lumbar part of the spine participate in a transmission of the loading forces that act with different intensity depending on conditions of dynamic vertebral segment and its components. Those loadings are changed during the instability of vertebral segment,

the vectors of the forces get different directions and, regarding a semicylindrical shape of articular surfaces, the loadings can cause different reactions and lesions. In several studies was concluded that longlasting micro-trauma leads to moderate reaction, i.e. to adaptation of the bone, and cosecutive formation of an osteophyte¹⁹. The bony tissue, as well as other body tissues, adapts to new conditions²⁰. The structure of cancellous bone is defined by rate between bone forming and bone resorption. That relation is changed during immobilization and unloading towards increased resorption and diminished bone formation, leading to thinning of trabeculae. Conversely, trabeculae of very burdened bone get thicker because of increased bone formation. Accordingly, mechanical forces of strain, compression and torsion are very important factors that influence processes of bone forming or bone resorption, i.e. bone remodelling.

The osteophyte that grows near the articular facet of vertebral articulation, causes a widening of that facet and becomes loaded itself with the same forces that act on that joint. The consecutive processes in the osteophytes were thickening of the trabeculae and diminishing of cancellous bone spaces, the process that corresponded to sclerosation. That feature was observed in the majority of the osteophytes analysed in this study. The bone resorption in such a condition was weak, therefore the osteoclasts that participated in osteophyte remodelling were presented in a small number. As those osteophytes had no possibility of unhindered growth as non loaded osteophytes, the activity of osteoclasts was weaker. The process that predominated in analysed osteophytes was thickening of trabeculae. That histological feature was common regardless of age or sex of the patients, what is conducive to assumption that the formation of the osteophytes is reaction to instability of spine. This data could point, in accordance with biomechanics of spine and mechanostatic theory, to conclusion that this is the adaptation of spine on increased loading.

The osteophytes from the area of lumbar zygapophyseal articulations are interesting in elucidation of clinical problem related to lateral recess syndrome. Hyaline cartilage or transitional form from a fibrous to a hyaline cartilage was on the surface of most of analyzed

osteophytes. Such a morphological feature points to additional enlargement of surface of articular facet. Those excrescences resembled to mature, mainly quiescent osteophytes whose development was already or nearly finished. Nevertheless, processes of intramembranous bone forming near the surface of osteophyte and in its peripheral parts, as well as in cancellous bone spaces of deeper part of that outgrowth, pointed to certain processes still going on. So, processes of osteogenesis, e.i. osteoid deposition made by chains of osteoblasts in peripheral superficial parts and in intertrabecular spaces, implies a new bone tissue forming that makes already existing formation more solide and compact.

Bone morphogenetic proteins regulate and control the processes of development and growth of cartilage and bone. The presence of BMP-3 and -7 was observed in osteoblasts of analysed osteophytes in this study by immunohistochemical metod. As those proteins are involved in bone forming in normal conditions, it can be concluded that their presence in those osteophytes additionally confirm the existance of such a processes in those excrescences. The expression of those morphogens was significantly stronger and abundant in the osteophytes of osteoarthrotic hip and knee joint as presented by Zoričić et al.⁹. Those proteins were also observed in some hypertrofied chondrocytes of the deeper part of the cartilage in our study. Since in some of such spiecemens there was no morphological evidence of endochondral ossification, the finding of BMP-7 in them could indicate to apoptosis. That could mean that those proteins can be expected in developing and growing cartilages but also in those undergoing degenerative processes²¹.

In conclusion, the analyzed outgrowths that caused lumbar spinal stenosis were already formed osteophytes covered mostly with hyaline cartilage. The elements of intramembranous bone formation in the deeper parts of the osteophytes, on the walls of intertrabecular spaces, were noticed in the majority of the osteophytes. The results of osteophyte analysis compared to clinical picture of the lumbar lateral recess syndrome lead to conclusion that marginal osteophyte formation was probably an attempt of the organism to stabilize instabile segment enlargening articular surface by additional growth.

REFERENCES

- SCHLESINGER PT, *J Bone Joint Surg*, 37 (1955) 115. — 2. KIRKAJD Y, WILLIS WH, PAINE KW, CAUCHOIX J, *Clin Orthop*, 99 (1974) 30. — 3. EPSTEIN JA, EPSTEINBS, ROSENTHAL AD, CARRAS R, LAVINE LS, *J Neurosurg*, 36 (1972) 584. — 4. CIRIC I, MIKHAEL MA, *J Neurosurg*, 53 (1980) 433. — 5. RESNICK D, *Arthrit and Rheumat*, 7 (1983) 908. — 6. AIGNER T, DIETZ U, STO? H, VON DER MARK K, *Lab Invest*, 2 (1995) 236. — 7. DODDS RA, GOWEN M, *J Histotechnol*, 1 (1994) 37. — 8. BENJAMIN M, TOUMI H, SUZUKI D, HAYASHI K, McGONAGLE D, *Ann Rheum Dis*, 68 (2009) 1003. — 9. ZORIČIĆ S, MARIĆ I, BOBINAC D, VUKIČEVIĆ S, *J Anat*, 202 (2003) 269. — 10. VAN DER KRAAN PM, *OsteoArthritis and Cartilage*, 15 (2007) 237. — 11. TANAKA N, TSUCHIYA T, SHIOKAWA A, TASHIRO K, YAMAZAKI T, YOSHIKI S, *Nip Seika Gak Zas*, 60 (1986) 323. — 12. DOKTOROV AA, DENISOV-NIKOLSKII I, *Arkh Patol*, 55 (1993) 61. — 13. YEH TT, WEN ZH, LEE HS, LEE CH, YANG Z, JEAN YH, WU SS, NIMNI ME, HAN B, *Eur Spine J*, 17 (2008) 734. — 14. PENG B, HOU S, SHI Q, JIA L, *Chin J Traumatol*, 15 (2000) 202. — 15. EINHORN TA, *The Bone Organ System: Form and Function*. In: MARCUS R, FELDMAN D, KELSEY J (Eds): *Osteoporosis* (Academic Press Inc, San Diego, 1996). — 16. VUKIČEVIĆ S, LUYTEN FP, REDDI AH, *Proc Nat Acad Sci USA*, 86 (1989) 8793. — 17. ASAHINA I, SAMPATH TK, NISHIMURA I, HAUSCHKA, *J Cell Biol*, 123 (1993) 921. — 18. DODDS RA, MERRY K, LITTLEWOOD A, GOWEN M, *J Histochem Cytochem*, 42 (1994) 733. — 19. VAN DER BERG WB, VAN OSCH G, VAN DER KRAAN P, VAN BEUNINGEN H, *Agents and Actions*, 40 (1993) 215. — 20. RODAN GA: *Coupling of Bone Resorption and Formation during Bone Remodeling*. In: MARCUS R, FELDMAN D, KELSEY J (Eds): *Osteoporosis* (Academic Press Inc, San Diego, 1996). — 21. BOBINAC D, ŠPANJOL J, MARINOVIĆ M, ZORIČIĆ CVEK S, MARIĆ I, CICVARIĆ T, FUČKAR D, MARKIĆ D, VOJNIKOVIĆ B, *Coll Antropol*, 32 (2008) 83.

G. Bajek

*Clinic of Neurosurgery, University Hospital of Rijeka, T. Stržića 3, 51000 Rijeka, Croatia
e-mail: goran.bajek@ri.t-com.hr*

HISTOMORFOLOŠKA ANALIZA OSTEOFITIČNIH APOZICIJA U BOLESNIKA SA SINDROMOM LUMBALNOG LATERALNOG RECESUSA

S A Ž E T A K

Bolesnici sa sindromom lumbalnog lateralnog recesususa (SLR) mogu se uspješno liječiti otklanjanjem koštanih izraslina koje se stvaraju na rubnom dijelu zglobne plohe slabinskog zgloba. Oni sužavaju lateralni recesus i komprimiraju korijen spinalnog živca. Njihova pojava povezuje se s nestabilnošću dotičnog dinamičkog vertebralnog segmenta. Cilj ovoga rada bio je morfohistološki analizirati građu osteofita s namjerom da se razluče stanični procesi koji dovode do novonastale koštane tvorbe. To je od značaja za ispravno tumačenje i eventualnu potvrdu o uzročno-posljedičnoj svezi između osteofita i instabiliteta. Kao idealan objekt ispitivanja ukazuje se upravo osteofit u području lateralnog recesususa, jer se u svrhu liječenja otklanja. Izabrana je skupina od 30 bolesnika s kliničkom slikom SLR. Svaki je bolesnik imao klinički verificirani SLR s posljedičnom radikulopatijom. Koštane izrasline su kirurški otklonjene i analizirane histološkim i imunohistokemijskim metodama: toluidine blue, Goldner trikrom, TRAP, metoda indirektne peroksidaze s protutijelima protiv koštanih morfogenetskih proteina 3 i 7. Izrasline koje su uzrokovale stenozu lateralnog recesususa su građene od vezivne i hijaline hrskavice, te od spongioznog koštanog tkiva. Promjene u hrskavici i kosti te odvijanje procesa intramembranskog stvaranja koštanog tkiva u smislu proširenja koštanih gređica, moglo bi upućivati na zaključak da bi rubna osteofitna tvorba bila prilagodba izmijenjenom stanju u dinamičkom vertebralnom segmentu i pokušaj da se ovaj segment stabilizira povećanjem zglobne plohe.