

# Modified Extensive Anterior Vaginal Wall Repair for Cystocele

---

Valenčić, Maksim; Maričić, Anton; Oguić, Romano; Rahelić, Dražen;  
Sotošek, Stanislav; Gršković, Antun

Source / Izvornik: **Collegium antropologicum, 2010, 34 supplement 2, 191 - 194**

Journal article, Published version

Rad u časopisu, Objavljena verzija rada (izdavačev PDF)

Permanent link / Trajna poveznica: <https://um.nsk.hr/um:nbn:hr:184:539835>

Rights / Prava: [In copyright](#)/[Zaštićeno autorskim pravom.](#)

Download date / Datum preuzimanja: **2024-12-24**



Repository / Repozitorij:

[Repository of the University of Rijeka, Faculty of  
Medicine - FMRI Repository](#)



# Modified Extensive Anterior Vaginal Wall Repair for Cystocele

Maksim Valenčić, Anton Maričić, Romano Oguić, Dražen Rahelić, Stanislav Sotošek and Antun Gršković

Department of Urology, University Hospital of Rijeka, Rijeka, Croatia

## ABSTRACT

*We describe a new transvaginal technique for cystocele repair. We prospectively evaluated patients with moderate and high-grade cystocele who underwent repair with the new transvaginal repair between 2000 and June 2009. Preoperative evaluation included history and physical examination using the Pelvic Organ Prolapse Quantification, urine culture, residual urine measurement, urodynamic studies and cystoscopy. We performed the repair in 76 patients with a mean age of 65.24 years (range, 36 to 84 years), with anatomical cure in 72 (95%) patients. Four (5%) patients had recurrent cystocele, 3 (4%) patients claimed residual sensory urgency and 4 (5%) stress urinary incontinence (SUI) after the operation. The operation is safe, simple, and provides good anatomic results with minimal complications.*

**Key words:** cystocele, anterior colporrhaphy, urodynamic studies

## Introduction

Estimating the true incidence of pelvic floor disorders is difficult, because many women accept uterovaginal prolapse as an inevitable consequence of childbirth and ageing<sup>1</sup>. It is obvious that the incidence of genital prolapse increases with age. Symmonds *et al.* Reported in their study that 60% of patients with vaginal vault prolapse were over 60 years of age<sup>2</sup>. Over a half of women aged >75 years may think that their symptoms are normal for elderly people<sup>3</sup>. In the USA over 200,000 surgeries are performed yearly for the treatment of POP. The majority of these procedures are performed on the older woman<sup>5</sup>. The estimated demand for care of pelvic floor disorders has been projected to increase by 45% over the next 30 years. Pelvic floor surgery is considered an intermediate risk procedure with perioperative mortality rates from 0.0% to 4.1% and complication rates from 15.5% to 33.0%<sup>5</sup>. Surgical techniques to address anterior defects are the anterior colporrhaphy and paravaginal repair. Repair of the anterior vaginal wall is associated with the highest long-term failure rates of all the vaginal wall defect repairs, reaching over 60%. In this article we

describe an own, modified extensive anterior vaginal wall repair in women with cystocele.

## Patients and Methods

We retrospectively analyzed the records of 76 patients who between 2000 and 2009 underwent an operation for cystocele. We have been performing an own, modified, extensive anterior vaginal wall repair. The average age of the patients was 65.24 years (range: 36 to 84 years, median: 60.0 years). Preoperative evaluation included clinical history, physical examination using the Pelvic Organ Prolapse Quantification, urine culture, residual urine measurement, urodynamic studies and cystoscopy. Evaluation has been performed with the patient in the dorsal lithotomy position and all quantifications have been obtained under a strong Valsalva maneuver causing maximal prolapse of the vaginal tissue. Stage II cystocele has been diagnosed in 12, stage III in 31 and stage IV in 33 patients (Table 1).

**TABLE 1**  
DISTRIBUTION OF CYSTOCELE RELATIVE TO THE AGE AND STAGE

Age	30–39	40–49	50–59	60–69	70–79	>80
Stage 1	0	0	0	0	0	0
Stage 2	1	0	3	1	7	0
Stage 3	0	5	13	6	6	1
Stage 4	0	1	3	7	20	2
Total	1 (1%)	6 (8%)	19 (25%)	14 (18%)	33 (44%)	3 (4%)

All patients underwent a modified extensive anterior vaginal wall repair. The operation is performed in the dorsal lithotomy position with candy-cane stirrups. A weighted vaginal speculum is placed, and labial retraction sutures of 2–0 silk are used for maximal exposure. A 16-Fr Foley catheter is placed per urethra. A ring retractor with four hooks is placed to expose the introitus. The anterior vaginal wall is grasped and everted through the introitus. The limbs of the T-formed incision are located on the anterior vaginal wall just outside of the reflection of the lateral walls of the vagina. The horizontal part of the T-formed incision is located directly under the bladder neck, wherefrom a single incision is carried to the level of the vaginal apex in the midline (Figure 1). The cut edges of the vaginal wall in the midline are grasped with Allis clamps. Lateral and anterior dissection is carried out first. The entire bladder base with attached fascia should be dissected free of the vaginal wall. Posteriorly, the dissection is carried to the level of the vaginal apex in the region of the cardinal ligaments. A 1–0 polypropylene suture is placed in the helical pattern that catches the urethropelvic ligament, pubocervical ligaments and cardinal ligament with the vaginal wall through the edge of endopelvic fascia at both sides. The sutures are tied at both ends (Figure 2).

Repair starts with the reapproximation of the area of the cardinal ligaments, in the midline with a 1–0 braided synthetic nonabsorbable suture, catching the polypropylene suture. Attention is now turned to the urethropelvic

ligament, lateral to the bladder neck on either side. A horizontal stitch of 1–0 braided synthetic nonabsorbable suture is used to plicate this fascia toward the midline, catching the polypropylene suture also. The cystocele is reduced manually and the remaining perivesical fascia is then plicated from the level of the bladder neck to the cardinal ligaments with interrupted horizontal sutures of 1–0 braided synthetic nonabsorbable sutures (Figure 3). The sutures repairing the central defect are now tied.

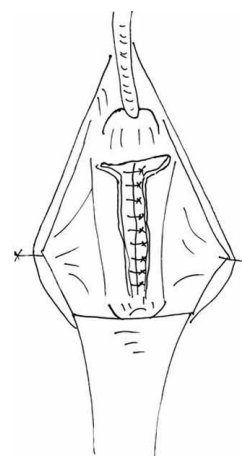


Fig. 2. Polypropylene suture of the pubocervical fascia and vaginal wall

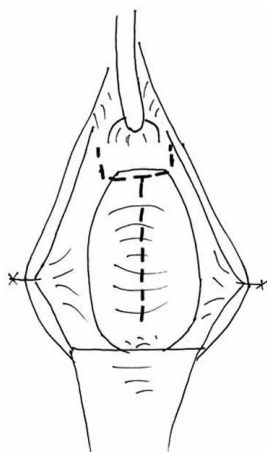


Fig. 1. Incision of the vaginal wall.

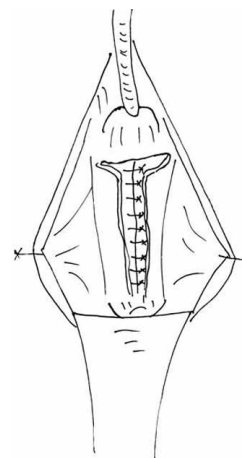


Fig. 3. Plication of the pubocervical fascia

**TABLE 2**  
RESULTS OF MODIFIED EXTENSIVE ANTERIOR VAGINAL WALL  
REPAIR FOR CYSTOCOELE

Anatomical cure	72 (95%)
Recurrent cystocele	4 (5%)
Sensory urgency	3 (4%)
SUI	4 (5%)

The ends of the polypropylene suture are cut as short as possible to avoid a later perforation of the vaginal wall. The limbs of the T-formed incision are closed with interrupted 2–0 absorbable sutures. The excess vaginal wall is trimmed, and the vaginal wall is reapproximated with interrupted 2–0 absorbable suture. The vagina is packed with antibiotic-impregnated gauze. The vaginal pack is removed in 24 hours. Three days after surgery Foley catheter is removed. When the residual urine is less than 50 cc the patient is discharged from the hospital. The patient may resume all regular activities immediately postoperatively, except heavy lifting, running, and sexual intercourse for four weeks.

## Results

The mean operative time was 55 min (range 45 to 80 min). No intraoperative or immediate postoperative complications have been observed. The average follow-up was 60.14 months (range 3–120 months, median 61.5 months), with 72 (95%) anatomical cures. In our series we had 4 (5%) patients with recurrent cystocele, 2 of them with initial stage 3 and one with stage 4. In 2 pa-

tients the cause of the recurrence was the postoperative perforation of the vaginal wall through a long end of the polypropylene suture left, with consequent vegetations, what made a suture extraction necessary. The other 2 patients had a dehiscence of the polypropylene sutures. Three (4%) patients claimed residual sensory urgency and 4 (5%) stress urinary incontinence (SUI) after the operation.

## Discussion and Conclusion

Older women are at high risk for developing conditions of the pelvic floor that require intervention. Consideration of conservative treatment modalities is recommended, however, surgery should not be avoided based on age alone<sup>4</sup>. The use of numerous materials and techniques has been described to reinforce or replace inadequate anterior vaginal tissue. There are few randomized prospective studies available that have proved significant benefit with the use of reinforcement material over anterior colporrhaphy alone. Several studies reported excellent results and low erosion rates with transvaginal implantation of polypropylene mesh for the correction of anterior vaginal wall, with 75–94% anatomic cure, but 2.1–24% mesh erosion also<sup>8–12</sup>. We have been performing anterior colporrhaphy using nonabsorbable sutures for the plication of the pubocervical fascia. This suture represents a nucleus for the development of a strong fibrous bridge between the bladder neck and vaginal apex as a support of the anterior vaginal wall and bladder. The operation is safe, simple, and provides good anatomic results with minimal complications.

## REFERENCES

- BIDMEAD J, CARDOZO LD, BJU International, 82 (1998) 18. —
- SYMMONDS RE, WILLIAMS TJ, LEE RA, ET AL, Am J Obstet Gynecol, 140 (1981) 852. —
- GJORUP T, HENDRIKSEN C, LUND E, ET AL, J Chron Dis, 40 (1987) 1095. —
- GERTEN KA, RICHTER HE, Clin Obstet Gynecol, 50 (2007) 826. —
- HAMILTON BOYLES S, WEBER AM, MEYN L, Am J Obstet Gynecol, 188 (2003) 108. —
- LUBER KM, BOERO S, CHOE JY, Am J Obstet Gynecol 184 (2001) 1496. —
- ABRAMS P, Incontinence (Health Publications Ltd, Paris, 2005). —
- HOENIL J, JAE WK, NOH HP, ET AL, J Obstet Gynecol Res 33 (2007) 700. —
- AMRUTE KV, EISENBERG ER, RASTINEHAD AR, ET AL, Neurourol Urodyn, 26 (2007) 53. —
- GAURUDER-BURMESTER A, KOUTOUZIDOU P, ROHNE J, ET AL, Int Urogynecol J, 18 (2007) 1059. —
- ORESKOVIC S, KALAFATIC D, GRSIC HL, GOJEVIC A, GREGOV M, BABIC I, Coll Antropol, 33(1) (2009) 201. —
- VALENCIC M, SPANJOL J, MARICIC A, MARKIC D, FICKAR D, BOBINAC M, Coll Antropol, 32(Suppl 2) (2008) 207.

*M. Valencic*

*Department of Urology, University Hospital of Rijeka, T. Strizica 3, 51000 Rijeka, Croatia  
e-mail: maksim.valencic@ri.t-com.hr*

## **MODIFICIRANA PROŠIRENA PREDNJA VAGINALNA PLASTIKA U LIJEČNJU CISTOCELE**

### **S A Ž E T A K**

U ovoj studiji opisujemo novu tehniku za transvaginalni popravak cistocele. Prospektivno smo pratili bolesnice s cistocecom umjerog i visokog stupnja, koje su bile podvrgnute novoj metodi transvaginalnog popravka između 2000 godine i lipnja 2009. Prijeoperacijska evaluacija uključuje anamnezu i fizikalni pregled koristeći pregled u spekulima zatim urinokulturu, mjerenje ostatnog urina, urodinamiku i cistoskopiju. Izvršili smo popravak u 76 bolesnika srednje dobi od 65.24 godine (raspon od 36 do 84 godine). Popravak je bio uspješan u 72 (95%) bolesnice. U četiri (5%) bolesnice iamli smo povratak cistocele, 3 (4%) bolesnice imale su i dalje urgenciju, a 4 (5%) stres inkontinenciju (SUI) nakon operacije. Operacija je sigurna, jednostavna, a daje anatomske dobre rezultate s minimalnim komplikacijama.