

Neuroimaging Techniques in Modern Forensic Psychiatry

Radeljak, Sanja; Žarković Palijan, Tija; Kovačević, Dražen; Marinović, Dunja; Dadić-Hero, Elizabeta

Source / Izvornik: **Collegium antropologicum, 2010, 34 supplement 2, 287 - 290**

Journal article, Published version

Rad u časopisu, Objavljena verzija rada (izdavačev PDF)

Permanent link / Trajna poveznica: <https://um.nsk.hr/um:nbn:hr:184:585970>

Rights / Prava: [In copyright](#)/[Zaštićeno autorskim pravom.](#)

Download date / Datum preuzimanja: **2025-02-10**



Repository / Repozitorij:

[Repository of the University of Rijeka, Faculty of Medicine - FMRI Repository](#)



Neuroimaging Techniques in Modern Forensic Psychiatry

Sanja Radeljak¹, Tija Žarković-Palijan¹, Dražen Kovačević¹, Dunja Marinović² and Elizabeta Dadić Hero³

¹ Department of Forensic Psychiatry, Neuropsychiatric Hospital »Dr. Ivan Barbot«, Popovača, Croatia

² Juvenile Correctional Institution, Rijeka, Croatia

³ Community Primary Health Centre of Primorsko-goranska County, Department of Family medicine, Medical faculty, University of Rijeka, Rijeka, Croatia

ABSTRACT

Applied neuroscientific knowledge such as brain neuroimaging has widespread application in the medical diagnostic and treatment areas. Neuroscientific progress such as cognitive neuroscience has strong implications in specific medical fields such as forensic psychiatry. Significant progress in forensic psychiatry has affected the practice of law, in which an understanding of the complex relationship among mind, brain, and behavior is becoming necessary. Forensic psychiatry is concerned with the relationship between psychiatric abnormalities and legal violations and crimes. Due to the lack of available biological criteria, assessment, evaluation and therapy in forensic psychiatry have so far been restricted to psychosocial and mental criteria of offender personality. Recent advances in nuclear radiology such as brain imaging techniques (fMRI, DT-MRI, PET, SPECT) allow a closer approach to the neural correlates of personality, moral judgments and decision-making. Introduction of neurobiological criteria (based on advanced neuroimaging techniques) in the field of forensic psychiatry and establishing the rules to what extent such biological criteria will be more reliable choice in evaluating mentally ill offenders would be of fundamental value in the modern forensic psychiatry. Psychosocial and subjective criteria in forensic evaluation will be more accomplished by biopsychosocial and objective criteria. Advances in the neuroimaging techniques bring specificity to the problems underlying the application of neuroscience to criminal law.

Key words: neuroimaging techniques, brain imaging, forensic psychiatry, criminal law

Neuroimaging Studies in Violent Offenders

Recent studies have revealed that human brain areas specifically associated with violent behavior are located in the prefrontal cortex, medial temporal regions and limbic regions^{1,2}. Key regions commonly found to be impaired in population of violent homicide offenders include prefrontal cortex, temporal gyrus, amygdala-hippocampal complex, and anterior cingulate cortex. Moreover, a close link between structural brain abnormalities and impulsive violent behavior in homicidal patient has been found, supporting the neuroscientific hypothesis that impulsive homicide offenders lack the prefrontal »inhibitory« machinery³. A new technique such as diffusion tensor magnetic resonance imaging (DT-MRI), allowed the researchers to look at the white matter tract linking the two key brain areas; grey and white brain matter and

their interconnections⁴ (Figures 1 and 2). Functional neuroimaging studies in motor planning, awareness of actions, organization, social reasoning, and theory of mind have recently targeted a small group of brain networks thought to be instrumental in offender's decision making. Using the PET technique, Adrian Raine and colleagues have been studying homicide offenders and found that 41 homicide offenders have significantly decreased level of brain functioning in the prefrontal cortex than mentally healthy persons, indicating that functional brain deficit is closely related to violence. Generally speaking, the results from numerous and extensive Raine's studies showed that frontal lobe dysfunction was presented in all homicide offenders as abnormal lower activity of the frontal brain area with absence of

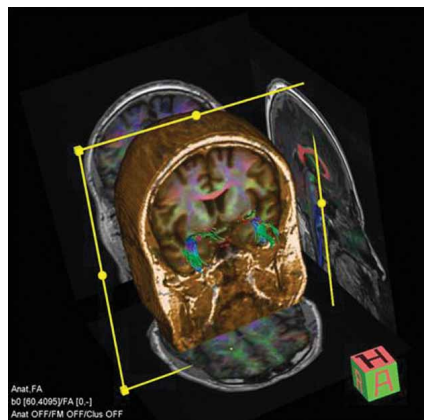


Fig. 1. Figure shows diffusion tensor magnetic resonance imaging (DT-MRI) tractography of uncinate fasciculus in forensic patient in order to study connections between amygdale and orbitofrontal cortex (Figure obtained from Croatian Institute for Brain Research).

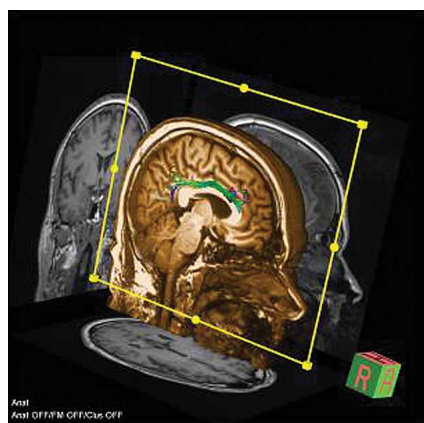


Fig. 2. Figure shows diffusion tensor magnetic resonance imaging (DT-MRI) tractography of cingular gyrus in forensic patient. Imaging is performed in order to analyse possible abnormalities within the limbic system in the brain (Figure obtained from Croatian Institute for Brain Research).

visible pathological alteration in the brain structure^{5,6}. The authors concluded that even delicate damage to the function of frontal brain region in absence of visible structural brain pathology can result in impulsivity, loss of self-control, irresponsible behavior, altered emotionality, and the inability to modify behavior, which can all in turn facilitate violent acts. The most recent study by Yang, Raine and colleagues showed first evidence of focal amygdala abnormalities in psychopathic individuals using fMRI⁷. Results showed that individuals with psychopathy showed significant bilateral volume reductions in the amygdala compared with controls. This study support recent hypotheses of amygdala deficits in individuals with psychopathy and indicate that amygdala abnormalities contribute to emotional and behavioral symptoms of psychopathy. Other abnormalities observed by the PET study of the brain in homicide offenders included

reduced metabolism within neural network in the superior parietal gyrus, left angular gyrus, and the corpus callosum, as well as, atypical asymmetries of activity in the amygdala, thalamus, and medial temporal lobe⁵⁻⁹. It is probable that these effects are related to violence and criminality; because some of these structures are part of the so-called limbic brain, which processes emotions and emotional behavior. Earlier studies suggested that dysfunction within the neural network in specific brain regions might underlie psychopathy and antisocial personality disorder. Such areas of the brain were identified as the amygdale, the area associated with emotions, fear and aggression, and the orbitofrontal cortex, the region which plays role in decision making^{1,10,11}. The most recent study by Craig and colleagues showed that white brain matter tract that connects the amygdala and orbitofrontal cortex, called uncinate fasciculus (UF) is altered in psychopaths. A neuromaging study using DT-MRI or tractography showed significant reduction within the structure of the UF in psychopaths, compared to control groups of people with the same age and IQ, as well as, it was shown that degree of abnormality in UF was significantly related to the degree of psychopathy⁴. These results suggest that violent persons with antisocial personality disorder have biological differences in the brain which may help to explain their aggressive behavior. The recent advances in development of the brain imaging techniques such as DT-MRI are offering a whole new prospective to the neuroscientists in terms of more consistent understanding of the possible brain networks that underlie violent and criminal behavior, and potentially modern approach towards possible prevention and new treatment for psychopathy and antisocial personality disorder. The basic neuroscientific research on animals showed that the right orbitofrontal cortex is involved in fear conditioning and evolutionary based learning by reward and punishment. Studies on rats proved that there is an association in terms of fear between the painful stimulus and the punishment. Human behavior is based on an early conditional learning to avoid antisocial behavior in order to escape from the punishment. Humans have complex brain neural circuits which associates fear of punishment (feeling emotion) to suppression of antisocial behavior. This seems to be a key element in the development of personality. When there is no punishment, or when the person is unable to be conditioned by fear, due to a lesion in the orbitofrontal cortex, for example, or due to lowered neural activity in this area, then it develops an antisocial personality. A recent study of Wahlund, and Kristiansson on aggression and brain imaging emphasized that violent behavior results from a complex network of interacting genetic and environmental factors¹². Authors are also pointing out on certain predictive factors such as antisocial personality disorder and/or psychopathy as high risk factor for relapse in committing the violent offenses. The review indicates a strong agreement within scientific community on the neurobiological basis of violent behavior. According to numerous recent articles on neuroscientific basis of violence there is a strong relationship between dysfunc-

tional parts of the frontal and temporal lobes, antisocial personality disorder and violent behavior. According to authors, the future research should focus on the structure and function within specific parts of the human brain such as limbic system and frontal lobes as »cerebral networks of interest« in the phenomenon of antisocial personality disorder, closely linked to extreme violent behavior in humans¹².

Application of Neuroimaging Techniques in Forensic Psychiatry

Applied neuroscientific knowledge such as brain neuroimaging has widespread application in the medical diagnostic and treatment areas. Neuroscientific progress such as cognitive neuroscience has strong implications in specific medical fields such as forensic psychiatry. Introduction of neuroimaging techniques early in the course of psychiatric evaluation and assessment of violent offenders is now offering a new approach in the understanding the neurobiological basis of criminal behavior. Significant progress in applied neuroscience within the field of forensic psychiatry has recently affected the practice of criminal law, in which an understanding of the complex relationship among mind, brain, and behavior is becoming necessary. Forensic psychiatry is fundamentally concerned with the relationship between psychiatric abnormalities and its relationship to legal violations and crimes. Neuroimaging studies have used classic moral dilemmas to identify the specific brain neural networks underlying moral decision-making in mentally healthy individuals, but until recently it was relatively unknown how this neural networks function in decision making when it comes to individuals with antisocial personality disorders and /or psychopaths which are exhibiting extreme violent behavior with no empathy or remorse for the acts they commit. The term psychopathy should be clarified in order to understand diagnostic criteria in forensic psychiatry. In the review on neurobiological basis of psychopathy by James Blair, psychopathy is well defined and diagnostically separated from antisocial personality disorder¹¹. According to Blair, psychopathy is a disorder, defined by Hare's Psychopathy Checklist – Revised (PCL-R) and characterised in part by a diminished capacity for remorse and poor behavioural controls. Classification of psychopathy is not equal to diagnoses of conduct disorder or antisocial personality disorder it represents an extension of both. These psychiatric diagnoses are poorly specified and concentrate on the antisocial behavior. Because of the inconsistency in diagnostic criteria, the diagnostic rate is over 80% for antisocial personality disorder in adult forensic institutions¹³. In contrast, psychopathy is defined not only by antisocial behavior but also by emotional impairment such as the lack of guilt. Only one third of those who are diagnosed with antisocial personality disorder meet criteria for psychopathy¹³. Moreover, a diagnosis of psychopathy, unlike antisocial personality disorder, is informative regarding a patient's future risk for violent behavior¹⁴. In

the most recent studies using functional magnetic resonance imaging (fMRI) in order to identify brain areas involved in decision making it was found that psychopathic individuals show reduced activity in the amygdala, a complex brain structure involved in processing the emotions during decision-making⁷. A significant reduction of activity in the amygdala and complex neural circuit involved in emotionally processed decision making was identified in highly manipulative individuals, which is one of the typical behavioral characteristics in psychopaths. Moreover, reduced amygdala activity was associated with each of the four factors of psychopathy involving manipulation, deceiving, superficiality and deceitfulness exhibited reduced activity in each of the other regions (medial prefrontal cortex, posterior cingulate and angular gyrus) of the moral neural circuit. These results provide scientific evidence on functional brain abnormalities in psychopaths in terms of deficits in brain regions which are essential for moral judgment in normal individuals. Psychopathy is a personality disorder involving severe disruption in moral behavior accompanied by pronounced deficits in emotion. Emotion is argued to be a critical component of moral behavior. Highly emotional moral dilemmas have been found to evoke activity in the amygdala, medial prefrontal cortex, posterior cingulate and angular gyrus. It has been hypothesized that persistent immoral behavior may result from deficiencies in some components of the moral neural circuit. On the other hand, a recent case report of homicidal patient with visible brain pathology such as large arachnoid cyst in the right brain hemisphere compressing right frontal and temporal cortex with lesions in frontal and temporal cortex and lesion of the white brain matter in insular region of both hemispheres (shown on MRI) supports previous evidence that structural brain abnormalities within frontotemporal region are closely related to extreme violent behavior in impulsive homicide offenders with no evidence of psychopathy^{1,3,4,7,8}. Taken all together, recent advances in nuclear radiology such as brain imaging techniques (fMRI, DT-MRI, PET, SPECT) allow a closer approach to the neural correlates of personality, moral judgments and decision-making. Introduction of neurobiological criteria, based on advanced neuroimaging techniques, into the field of forensic psychiatry and establishing the rules to what extent such biological criteria will be more reliable choice in evaluating mentally ill offenders during the legal processes, would be of fundamental value in the modern forensic psychiatry^{4,8,10,12,15,16}. Psychosocial and subjective criteria in forensic evaluation and assessment of criminal offenders should be completed by precisely defined biopsychosocial and objective criteria, based on scientific evidence and in close agreement with medical scientific community and experts in criminal law. Advances in the neuroimaging techniques bring specificity to the problems underlying the application of neuroscience to criminal law. Future direction in forensic psychiatry should be orientated toward an integrative approach to the complexity of clinical assessment of mental state competence (diminished mental capacity, temporary insanity, insanity) in violent offenders by using all

available scientific data in order to improve the clinical risk assessment and make more accurate decisions in

treatment and prevention of recidivism in violent offenders.

REFERENCES

1. WEBER S, HABEL U, AMUNTS K, SCHNEIDER F, Behav Sci Law, 26 (2008) 7. — 2. PRIDMORE S, CHAMBERS A, MCARTHUR M, Australian and New Zealand Journal of Psychiatry, 39 (2005) 856. — 3. RADELJAK S, ŽARKOVIĆ PALJAN T, KOVAČ M, KOVAČEVIĆ D, Eur Psych, 24 (2009) 838. — 4. CRAIG MC, CATANI M, DEELEY R, Molecular Psychiatry, 14 (2009) 946. — 5. RAINE A, DODGE K, LOEBER R, GATZKE-KOPP L, LYNAM D, REYNOLDS C, STOUTHAMER-LOEBER M, LIU J, Aggressive Behavior, 32 (2006) 159. — 6. RAINE A, YANG Y, Social, Cognitive, and Affective Neuroscience, 1 (2006) 203. — 7. YANG Y, RAINE A, NARR KL, COLLETTI P, TOGA AW, Arch Gen Psychiatry, 66 (2009) 986. — 8. GLENN AL, RAINE A, SCHUG RA, Molecular Psychiatry, 14 (2009) 5. — 9. RAINE, A, LENCZ, T, BIHRLE, S, Archives of General Psychiatry, 57 (2000) 119. — 10. BUFKIN JL, LUTTRELL VR, Trauma Violence Abuse, 2 (2005) 176. — 11. BLAIR RJR, British Journal of Psychiatry, 182 (2003) 5. — 12. WAHLUND K, KRISTIANSSON M, International Journal of Law and Psychiatry, 32 (2009) 266. — 13. HART SD, HARE RD, Current Opinion in Psychiatry, 29 (1996) 129. — 14. HARE RD, Hare Psychopathy Checklist—Revised (PCL-R) (Multi-Health Systems Inc, Toronto, 2003). — 15. AHARONI E, FUNK C, SINNOTT-ARMSTRONG W, GAZZANIGA M, Ann NY Acad Sci, 1124 (2008) 145. — 16. MOSSMAN D, NOFFSINGER SG, ASH P, FRIERSON RL, GERBASI J, HACKETT M, LEWIS CF, PINALS DA, SCOTT CL, SIEG KG, WALL BW, ZONANA HV, J Am Acad Psychiatry Law, 35 (2007) 3.

S. Radeljak

Department of Forensic Psychiatry, Neuropsychiatric Hospital »Dr. Ivan Barbot«, Jelengradska 1, 44317 Popovača, Croatia

e-mail: sanjaradeljak@aol.com

TEHNIKE NEUROPRIKAZA U MODERNOJ PSIHIJATRIJI

SAŽETAK

Primjenjena neuroznanost poput metoda modernih tehnika snimanja mozga, tzv. neuroimaging-a ima veliki značaj u raznim područjima suvremene medicinske dijagnostike i terapije. Napredak u neuroznanstvenim granama kao što je kognitivna neuroznanost ima značajni utjecaj u specifičnim područjima medicine, posebice u forenzičnoj psihijatriji. Razvoj moderne forenzične psihijatrije bitno je utjecao na praktičnu primjenu pravne znanosti u kojoj je postalo neophodno temeljno razumijevanje kompleksnog odnosa između uma, mozga i ljudskog ponašanja što se posebno odnosi na područje kaznenog prava. Forenzična psihijatrija je primarno fokusirana na otkrivanje uzročno-posljedičnih veza između raznih psihijatrijskih poremećaja i počinjenja kaznenih djela. Zbog nedostatka jasno dostupnih bioloških kriterija u forenzičnoj psihijatriji dosadašnji postupak procjene (vještačenja) kod počinitelja kaznenih djela je bio relativno ograničen na psihosocijalne i bazične psihijatrijske kriterije koji se odnose na osobnost počinitelja. Nedavni napredak u području nuklearne medicine i radiologije, poput razvoja sofisticiranih metoda i tehnika snimanja strukture i funkcije ljudskog mozga kao što su tehnike neuroimaging-a (fMRI, DT-MRI, PET, SPECT), omogućava bliži pristup razumijevanju neurobiološke podloge ljudske osobnosti i ponašanja te posljedično ima utjecaj na moralne procjene i donošenje odluka u kompleksnom postupku forenzičnih vještačenja. Uvođenje neurobioloških kriterija temeljenih na razvijenim tehnikama neuroimaginga u područje forenzične psihijatrije kao i postavljanje jasnih i znanstveno opravdanih pravila koja određuju do kojih granica biološki kriteriji mogu biti pouzdan izbor u postupku vještačenja mentalno bolesnih počinitelja kaznenih djela će u bliskoj budućnosti predstavljati iznimni doprinos modernoj forenzičnoj psihijatriji. Na taj način će postojeći psihosocijalni i subjektivni kriteriji koji se primjenjuju u postupku psihijatrijskog vještačenja biti obogaćeni i nadopunjeni biopsihosocijalnim i objektivnim kriterijima. Razvoj tehnika neuroimaginga danas omogućava veću preciznost u rješavanju složenih problema koji se temelje na praktičnoj primjeni i uvođenju neuroznanosti u područje kaznenog prava.