

# Primary vs secondary wound reconstruction in Gustilo type III open tibial shaft fractures: follow-up study of 35 cases

---

Štalekar, Hrvoje; Fučkar, Željko; Ekl, Darko; Šustić, Alan; Lončarek, Karmen; Ledić, Darko

Source / Izvornik: **Croatian Medical Journal, 2003, 44, 746 - 755**

Journal article, Published version

Rad u časopisu, Objavljena verzija rada (izdavačev PDF)

Permanent link / Trajna poveznica: <https://urn.nsk.hr/urn:nbn:hr:184:851365>

Rights / Prava: [Attribution-NonCommercial-NoDerivatives 4.0 International/Imenovanje-Nekomercijalno-Bez prerada 4.0 međunarodna](#)

Download date / Datum preuzimanja: **2024-12-02**



Repository / Repozitorij:

[Repository of the University of Rijeka, Faculty of Medicine - FMRI Repository](#)



## Primary vs Secondary Wound Reconstruction in Gustilo Type III Open Tibial Shaft Fractures: Follow-up Study of 35 Cases

Hrvoje Štalekar, Željko Fučkar<sup>1</sup>, Darko Ekl, Alan Šustić<sup>2</sup>, Karmen Lončarek<sup>3</sup>, Darko Ledić<sup>4</sup>

Departments of Traumatology, <sup>1</sup>Surgery, <sup>2</sup>Anesthesiology, <sup>3</sup>Ophthalmology, and <sup>4</sup>Neurosurgery, Rijeka University Hospital Center, Rijeka, Croatia

**Aim.** To compare primary and secondary wound reconstruction as a treatment method for Gustilo type III open tibial fractures.

**Methods.** Thirty-five consecutive patients with a Gustilo type III open tibial shaft fracture were treated and followed up for 3 years. The patients were divided into two groups depending on the treatment protocol and timing of wound reconstruction: primary wound reconstruction (n = 15) and secondary wound reconstruction (n = 20). After determining median value, the variability was expressed with the 25th and 75th percentiles.

**Results.** In the primary wound reconstruction group, healing was achieved in 13 out of 15 patients. The median time to recovery was 68 (25th-75th percentile = 32-86) weeks, median number of operations was 4 (25th-75th percentile = 3-5), and median Johner and Wruhs score was 4 (25th-75th percentile = 3-5). There were 9 cases with a bone defect and 2 tibial amputations were performed. In the secondary wound reconstruction group, complete recovery was achieved in 18 out of 20 patients. The median time to recovery was 115.5 (25th-75th percentile = 70.0-128.5) weeks, median number of operations 7.5 (25th-75th percentile = 6.5-8.5), and median score according to Johner and Wruhs' criteria 3 (25th-75th percentile = 2-4). There were 19 cases with a bone defect and 1 tibial amputation was performed. Chronic osteomyelitis persisted only in a single patient. Median time to recovery and number of operations were significantly smaller in patients undergoing primary wound reconstruction.

**Conclusion.** Primary wound reconstruction required smaller number of operations and shorter time to recovery than secondary wound reconstruction, mostly due to a significantly smaller proportion of cases with a bone defect.

**Key words:** fractures, open; limb salvage; reconstructive surgical procedures; tibial fractures

Gustilo type III open fractures (1) are both a complex therapeutic problem and an economic burden (2) because of multiple operations needed and long recovery. General indications for flap reconstruction of the wound are exposed bone, blood vessel, nerve, tendon, and open joint cavity.

Timing of the wound closure is the intriguing question for both reconstructive and fracture surgeons (3). Publications on this topic are few, and randomized studies are difficult to perform. Primary wound closure in the Gustilo type III open tibial fractures should be done immediately after radical debridement. According to Godina (4), primary closure provides less complications, better postoperative results, shorter recovery time, and smaller economic burden than secondary soft tissue defect reconstructions, which are performed after 5 or more days on the basis of second-look debridement. Secondary reconstructions are related to higher incidence of flap complications, osteomyelitis, number of operations, and longer time to recovery (4). DeLong and al (5)

have recently reported that there was no statistically significant difference in the incidence of osteomyelitis and delayed union/nonunion rates with respect to time of wound reconstruction. Beside medical indications, the factor influencing the timing of wound reconstruction is the organization of trauma service, ie, availability of prolonged use of operation room at any time (2).

The aim of this prospective study was to analyze the final functional results of the surgical therapy of Gustilo type III open tibial fractures in relation to primary vs secondary soft tissue reconstruction.

### Patients and Methods

#### Patients

All 35 patients with Gustilo type III open tibial fracture admitted to our level-I trauma center between 1993 and 1998 were followed up for 36 months before the final functional analysis. Only a single patient, with bilateral tibial fracture, penetrating thoracic trauma, and pulmonary lesion was excluded from study because he died of sepsis 11 days after admittance. The primary

reconstruction group consisted of 15 and the secondary of 20 cases of Gustilo type III fracture. The groups etiologically included both civilian and war injuries. Mean age in the primary reconstruction group was 25 (25th-75th percentile=23-38) years, and 35 (25th-75th percentile=26.5-39) years in the secondary reconstruction group.

Seven out of 15 cases in the primary reconstruction group and 12 out of 20 cases in the secondary reconstruction group were injured by explosion or bullets. Higher incidence of explosive and bullet traumas (Table 1) could be explained by the 1991-1995 war.

**Table 1.** Etiology, energy transfer, Mangled Extremity Severity Score (MESS) of the injuries causing the fracture

Parameter	Reconstruction (No. of patients)	
	primary (n = 15)	secondary (n = 20)
Etiology of injury:		
traffic accident	8	6
explosion	6	11
bullet	1	1
fall	0	1
crush injury	0	1
Energy transfer:		
low	0	0
medium	1	2
high	14	18
MESS score:		
5	1	0
6	11	15
7	3	4
8	0	1

*Fracture Classification*

Fracture classification was based on the mechanism of injury and type of energy transfer. According to etiology, the fractures in war injuries were classified as explosive or bullet wounds, whereas civilian injuries were classified as professional, traffic, or accidental. These injuries differed in the extent of soft tissue and bone damage. Open tibial diaphyseal fractures of Gustilo type III are caused mostly by high-energy injuries. The energy transfer was assessed from the anamnesis, clinical findings, and radiological evaluation of the fracture. Radiological evaluation of the energy transfer was based on the degree of comminution and dislocation of the fragments correlates with the energy that caused the skeletal injury. Simple tibial diaphyseal fractures (type A) were caused by low-energy; wedge fractures (type B) were caused by medium-energy, and complex fractures (type C) were caused by high-energy transfer wounds (6).

Subclassification of Gustilo type III open tibial fractures (1) is IIIA (extensive soft tissue laceration, adequate bone coverage, and possible soft tissue coverage of the bone); IIIB (very severe loss of coverage, with periosteal stripping, bone exposure, and required soft tissue reconstruction); and IIIC (vascular injury requiring repair).

Mangled Extremity Severity Score (MESS, ref. 7) was calculated from the energy of injury, duration of ischemia, hemodynamic status, and patient age (Table 1). MESS  $\geq 7$  is highly indicative of the necessity for initial or secondary amputation. The most serious disadvantage of MESS is the possibility of error in early indication of amputation in young patients with intact blood vessels, minimal blood loss, and extensive muscle and bone defect (7). Extensive injuries of the tibial shaft could be scored with MESS  $< 7$ , where primary amputation would be the method of choice. Conversely, Gustilo type IIIC tibial injuries can go along with a small wound and complete vessel lesion, MESS  $\geq 7$ , and successful reconstruction of extremity.

*Wound Reconstruction*

The timing of the wound reconstruction (8) of the Gustilo type III open tibial fractures was determined by the following factors: primary reconstruction of the wound (reconstruction immediately after radical debridement during the first operation); delayed primary/early reconstruction of the wound (carried out within 3 to 5 days after primary wound debridement); and sec-

ondary wound reconstruction (made 5 or more days after primary excision).

Primary wound reconstruction was performed by a microsurgical team. The main conditions for the primary reconstruction were radical (oncological) debridement, possibility of the elevation of the local flap or free flap immediately after radical debridement, possibility of wound reconstruction without the residual dead space, and good general condition of the patient.

Secondary soft tissue reconstruction was performed in patients with large, highly contaminated wounds or bad/critical general condition. Furthermore, secondary reconstruction was performed when it was uncertain if the primary debridement was performed radically "into the healthy tissue" and when it was not possible to proceed with the primary flap elevation after initial debridement.

Using the indications for primary or secondary reconstruction and the applied surgical protocol, we divided the patients in two groups: primary reconstruction group, with primary wound reconstruction during the first operation (15 men: one Gustilo type IIIA case, seven IIIB cases, and seven IIIC cases), and secondary reconstruction group, with secondary wound reconstruction (2 women and 18 men: three Gustilo type IIIA cases, 14 IIIB cases, and three IIIC cases). There was no statistically significant difference in the distribution of fracture types between two groups (chi-square=4.31, p=0.068).

Preoperative antibiotics, tetanus prophylaxis, and infusions were routinely administered in both groups.

*Treatment in Primary Reconstruction Group.* Initially, radical debridement was followed by wound irrigation, immediate fracture stabilization, blood vessel reconstruction where indicated, and primary soft-tissue reconstruction (9-12). Bone reconstruction was followed by physical rehabilitation.

Surgical approach to the fracture was performed through the wound in 13 and through the wound expanded with an incision in two out of 15 patients. External fixation for fracture stabilization was used in 13 and internal fixation with a plate and screw in two out of 15 patients (one with Gustilo type III B fracture and one with Gustilo type IIIC fracture, both caused by traffic accidents). Indication for osteosynthesis with a plate and screw in Gustilo type III B and IIIC tibial shaft fractures is exceptional and possible only if followed by primary flap (preferably muscle) reconstruction (6).

The indications for primary wound reconstruction were exposed bone (9 cases), exposed bones and blood vessels (3 cases), exposed muscles and tendons (3 cases).

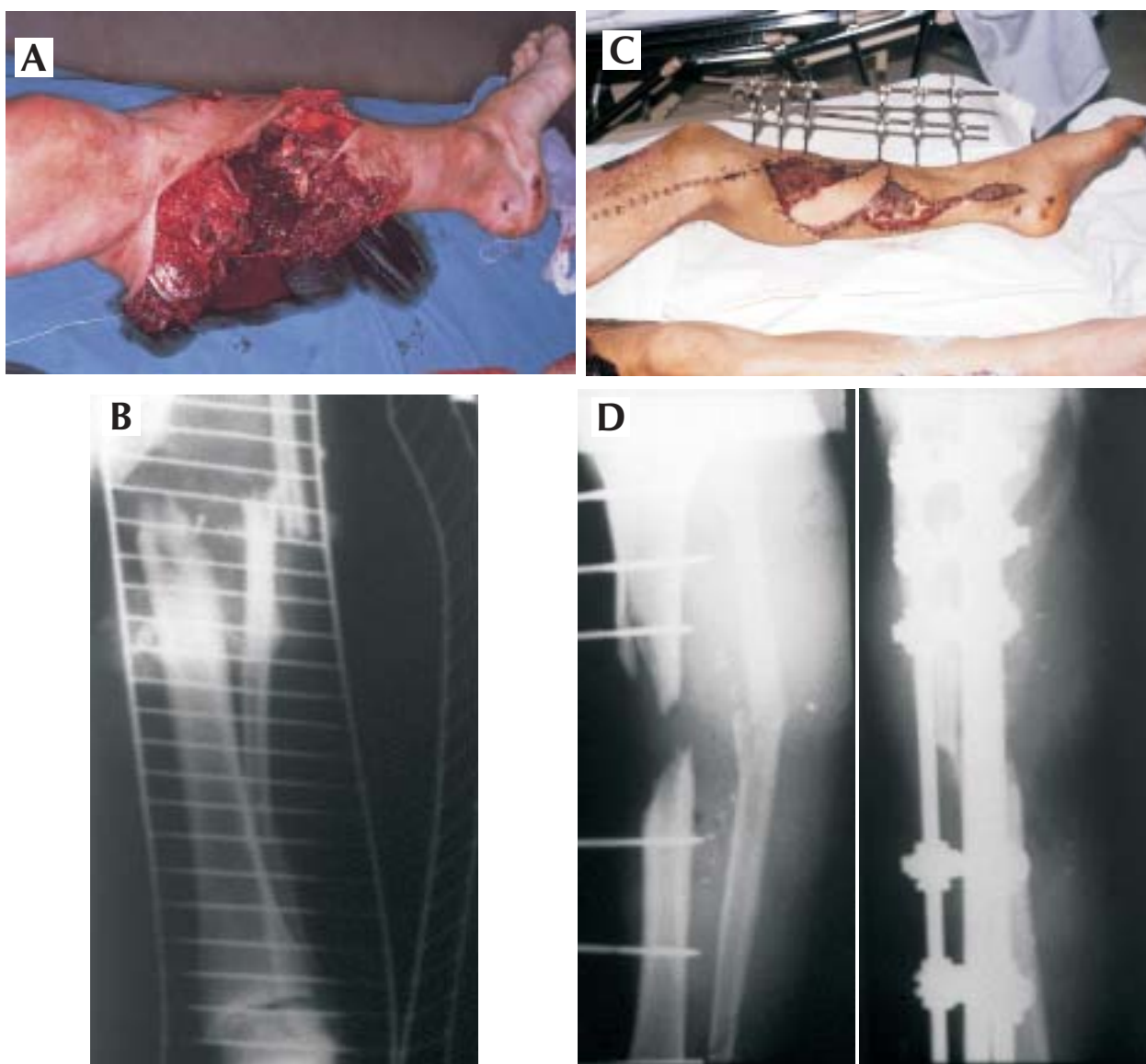
Primary reconstruction was performed during the first anesthesia. The median time from injury to operation was 7 (25th-75th percentile=5-8) hours.

Primary flap reconstruction was undertaken in seven and other surgical or reconstructive methods in eight out of 15 patients. Of seven out of 15 flaps used for wound reconstruction, there were two free latissimus dorsi flaps and five local flaps (medial head of the gastrocnemius muscle in three cases, anterior tibial muscular flap and local skin flap in one case each). In eight out of 15 cases where the flap was not used, the wound was reconstructed immediately with a split skin graft in three cases, imme-

**Table 2.** Wound size and type of flaps for soft tissue reconstruction

Soft tissue reconstruction	Reconstruction		p*
	primary (n = 15)	secondary (n = 20)	
Wound size (cm <sup>2</sup> , mean $\pm$ SD):			
before debridement	50 $\pm$ 61	51 $\pm$ 49	0.955
after debridement	74 $\pm$ 82	102 $\pm$ 72	0.294
Type of flap for soft tissue reconstruction (No. of patients):			
free flap	2	7	0.289
local flap	5	5	0.871
Type of flap for complication treatment (No. of patients):			
free flap	3	5	0.954
local free flap	1	1	0.599

\*T-test for continuous variables and chi-square test for fractions.



**Figure 1.** Primary wound reconstruction of explosive Gustilo IIIC open tibial fracture (case B.M.) – acute phase of surgical treatment. **A.** Explosive Gustilo IIIC tibial shaft fracture. **B.** Comminutive tibial shaft fracture, laterolateral view. **C.** Condition after external fixation, revascularisation, primary flap reconstruction; preserved foot vitality, primary wound healing. **D.** Segmental 4 cm bone defect on antero-posterior view (left). The size of segmental bone defect was unchanged after the primary reconstruction of the wound (antero-posterior (left) and latero-lateral (right) view).

diate primary closure with relaxing incisions in three cases, immediate primary closure in a single case, and tibial shortening and primary split skin also in a single case.

Eleven out of 15 flaps were used in the primary reconstruction group, seven for primary wound reconstruction, and four additional flaps (three free flaps and one local-tissue expander) for the treatment of complications. There was no statistically significant difference between the primary and secondary reconstruction group in any of the parameters (wound size before and after debridement, rates of cases with free flap for soft tissue reconstruction, cases with local flap for soft tissue reconstruction, free flaps used to treat the complications, and local free flaps used to treat the complications) (Table 2).

Out of seven cases with Gustilo type IIIC fracture, injury of anterior and posterior tibial and peroneal artery occurred in three patients, injury of anterior and posterior tibial artery in three patients, and injury of anterior tibial and peroneal artery in one patient.

Peripheral arteriography was performed after clinical assessment in six out of 15 patients (five cases of Gustilo type IIIC

fracture and one case of Gustilo type IIIB fracture). Blood vessel lesion was verified intraoperatively in two patients with Gustilo type IIIC fracture and clinically suspicious blood vessel trauma.

Posterior tibial artery lesion was reconstructed with great saphenous vein graft in five out of seven patients with IIIC fracture (13), direct termino-terminal anastomosis of posterior tibial artery was performed in one patient with tibial shortening, and anterior tibial artery was reconstructed with greater saphenous vein graft in one patient with lesions of anterior tibial and peroneal artery.

Bone defects smaller than 3 cm were treated with spongio-plastics. Segmental bone defects larger than 3 cm were treated by segmental bone transport (14) made with the circular external fixator (Instrumentarija, Zagreb, Croatia). Segmental bone transport was initiated 7 days after corticotomy and was lengthened by 1 mm once a day. Docking place spongio-plastics was performed after the circular external fixator had been replaced with the unilateral external fixator "Zagreb I" (Instrumentarija). External fixator was removed after the formation of calus and the healing of docking place.

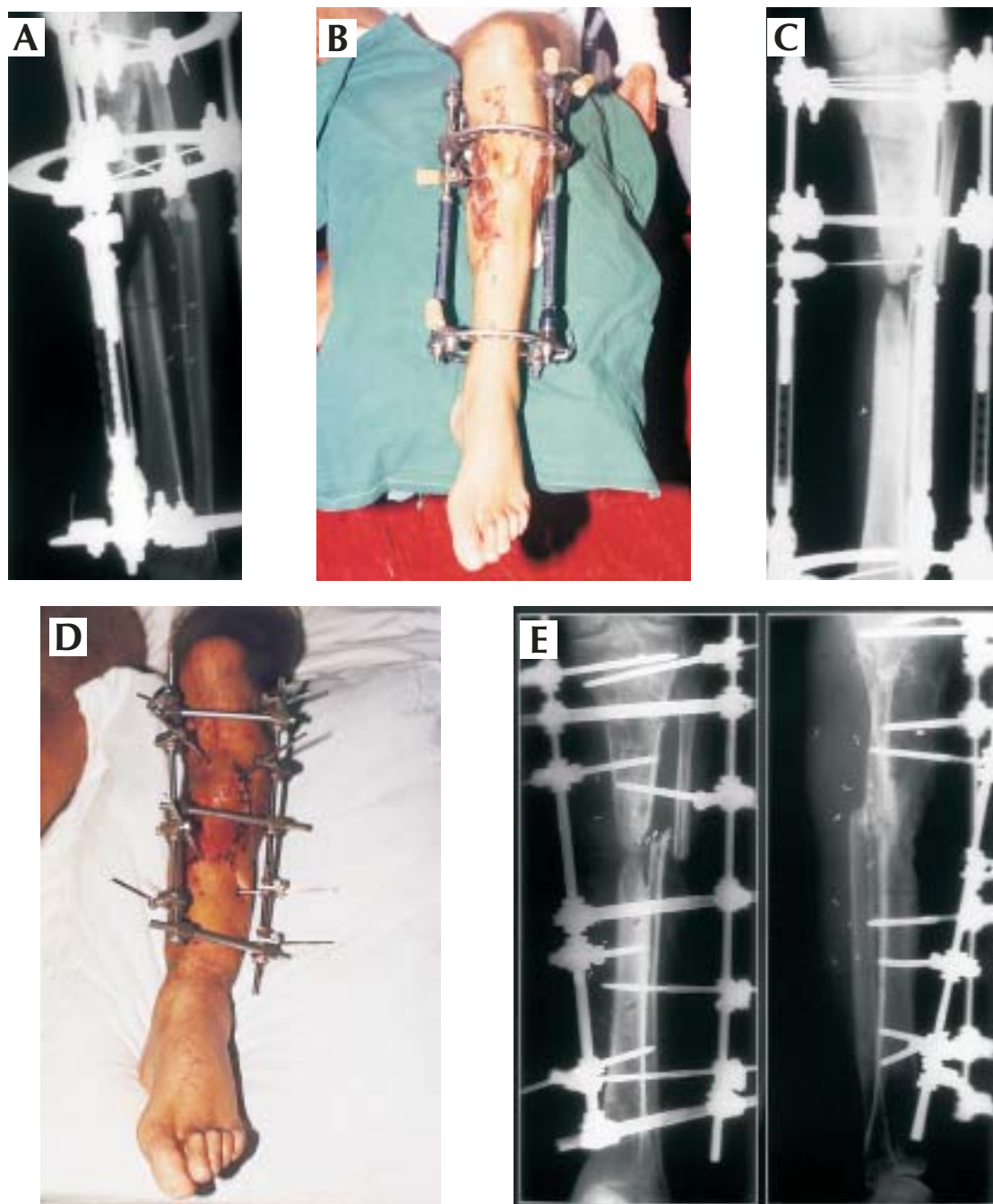


Among nine patients with nonreactive atrophic bone defect, there were three with partially necrotic fragment, two with necrotic fragment, three with segmental defect, and a single case with tibial shortening. Bone defect was surgically treated in six out of 15 patients in the primary reconstruction group as follows: four patients with Ilizarov (15,16) method (three patients with segmental transport; Figs. 1-3, a patient with tibial elongation); a patient with spongioplastics of bone defect; and a patient with tibiofibular synostosis combined with bone grafting in the presence of bone loss (17).

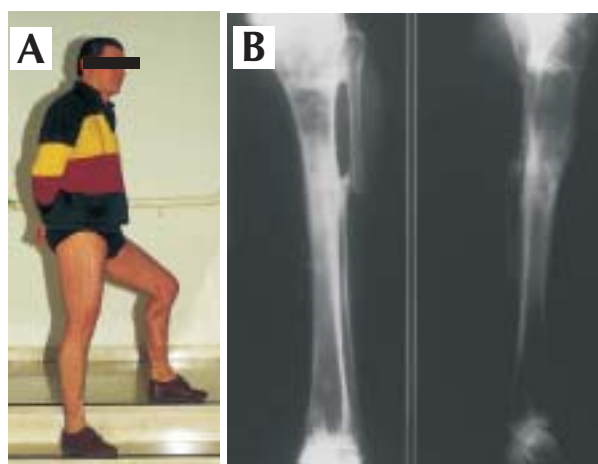
*Treatment in Secondary Reconstruction Group.* This type of treatment was performed in 20 patients: 13 who had been

treated in other institutions before being referred to our level-I trauma center to continue the treatment, and seven initially treated in our center. Further treatment, estimation of final functional results, and patient follow-up were performed by the same surgical team as in the primary reconstruction group.

Operative treatment in the first phase included an immediate debridement, wound irrigation, immediate fracture stabilization, blood vessel reconstruction where indicated, wound left open, serial debridements, and secondary soft tissue defect reconstruction. The second and third phases of the treatment were based on the same principles as in the primary reconstruction group.



**Figure 2.** Primary wound reconstruction of explosive Gustilo IIIC fracture (case B.M.) – reconstruction of segmental bone defect. **A.** Circular external fixator and proximal corticotomy for segmental bone transport (antero-posterior view). **B.** Patient with circular external fixator for segmental bone transport. **C.** Finished segmental bone transport: docking place insufficient for calus formation (antero-posterior view). **D.** Circular external fixator removed, refixation with external fixator, spongioplastics. **E.** Calus formation after the spongioplastics of the docking place (antero-posterior (left) and latero-lateral (right) view).



**Figure 3.** Final result of primary wound reconstruction in explosive Gustilo IIIC fracture, at 24-month follow-up (case B.M.). **A.** Patient condition. **B.** Fracture and place of bone distraction healed (antero-posterior (left) and latero-lateral (right) view).

Surgical approach to the fracture was performed through the wound. External fixation was used in all patients. Wound was left open in all patients in the secondary reconstruction group after primary debridement. After the wound was cleaned by repeated debridements, it was left open or temporarily covered by a split skin graft.

The wound was cleaned and left open in nine out of 20 patients after a median number of 3 (25th-75th percentile=2-4) repeated debridements. In these patients, there was no devitalized bone, wound healed with granulations, split skin graft was not required, and the flap reconstruction was performed after median time of 4 (25th-75th percentile=3-8) weeks.

Temporary secondary split skin graft was used in 11 patients (10 wounds and one stump) after three (25th-75th percentile=2-4) repeated debridements and 21 (25th-75th percentile=9-24) days after the trauma. The technique of temporary wound closure with split skin graft allowed the supervision of the wound healing as well as discovering the potential deep and bone infection in case of insufficient soft tissue or bone debridement. Secondary flap reconstruction was performed in nine patients after 24 (25th-75th percentile=8-56) weeks. Additional flap reconstruction was not required in two patients.

Among 11 patients with a temporary split skin graft, three grafts were made in our center and eight were made in other institutions before referral to our center.

Secondary flap reconstruction in 13 patients initially treated in other institutions was performed after a median time of 10 (25th-75th percentile=7-32) weeks; this time depended on the period from trauma to referral to our center. The secondary flap reconstruction of soft tissue defect in seven patients treated from the beginning in our trauma center was performed after median time of 4 (25th-75th percentile=3-11) weeks.

Secondary flap reconstruction was performed in all patients in the secondary reconstruction group after median time of 9 (25th-75th percentile=3-28) weeks. The flaps were used in 18 patients, and in two patients the wound was left covered with split skin graft as a permanent solution. In 18 patients with a flap, 12 flaps were used for wound reconstruction and 6 to treat the complications of fractures (Table 2).

The indications for flap use in these 20 patients were wound left open (nine patients), wound previously covered with split skin graft (three patients), and complications where the wound was secondarily treated with split skin graft (chronic osteomyelitis in three patients, malunion in one patient, and non-union in two patients).

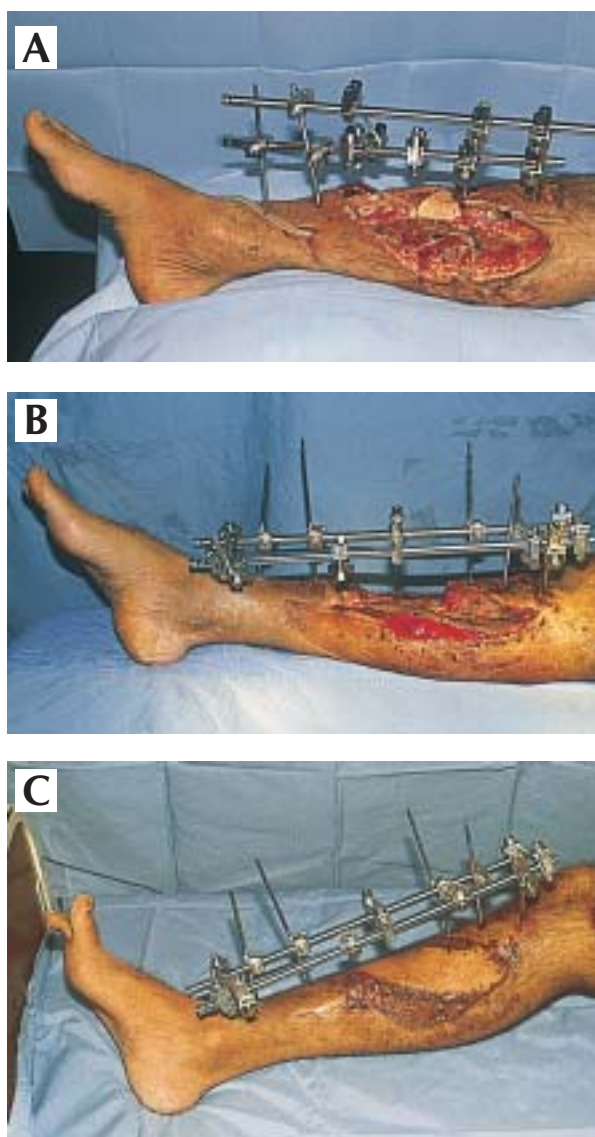
Four types of flaps were used in these 20 patients. Free latissimus dorsi musculocutaneous flap was used in 12 patients, local flap (medial head of gastrocnemius) in three, tissue ex-

pander in two, and cross leg flap (medial head of gastrocnemius) in a single patient. There was no flap failure.

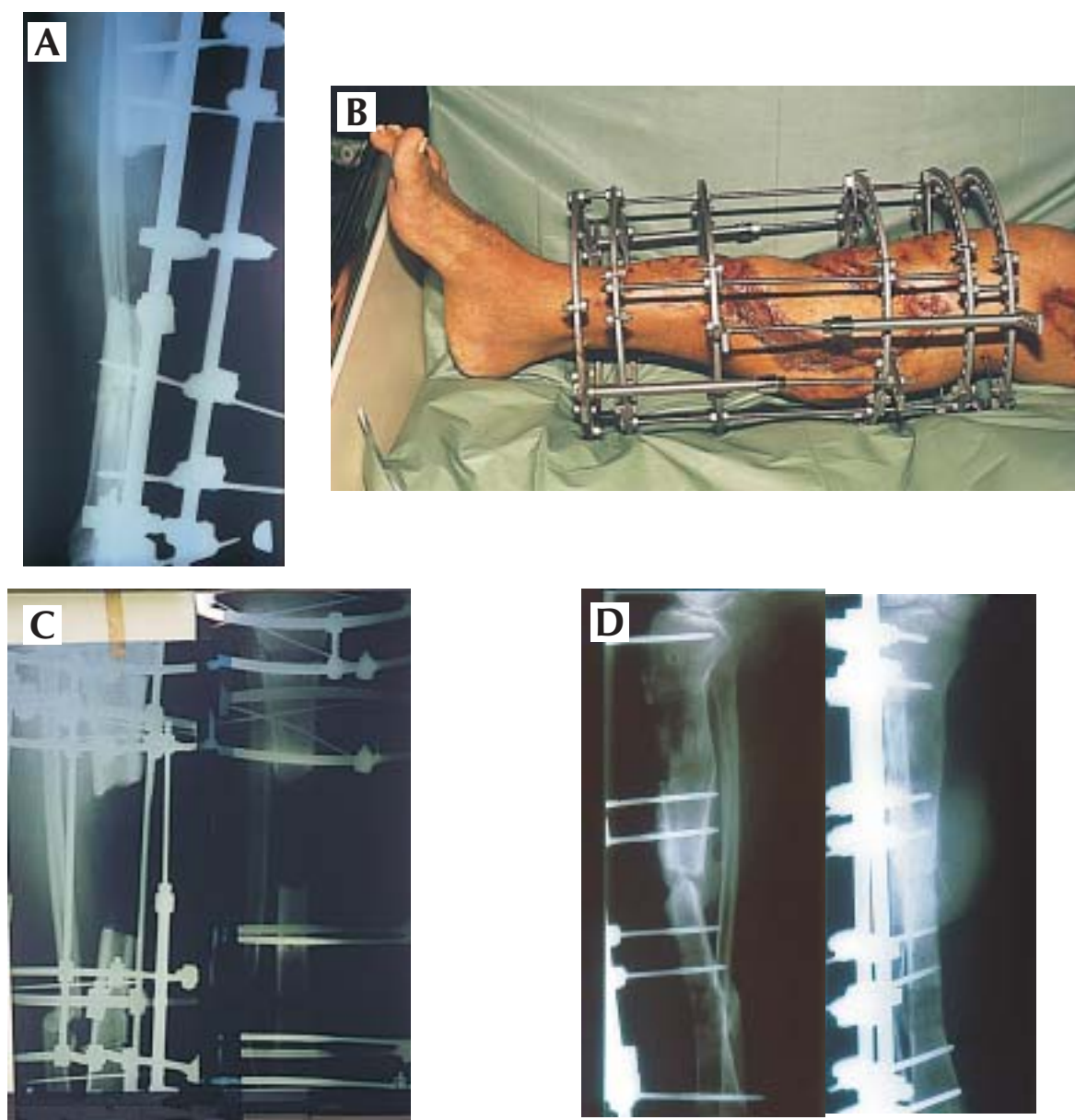
Preoperative peripheral arteriography was performed in two patients with Gustilo type III C fractures. In 11 patients, angiography was performed before the secondary flap reconstruction of the wound.

Anterior tibial artery lesion occurred in nine out of 14 patients with fracture type IIIB, and the ligation of the damaged artery was performed.

There were two cases of Gustilo type IIIC fracture with lesion of anterior and posterior tibial artery. Venous graft was used to repair the lesion of the posterior tibial artery and comitant vein. In a single patient with three-arterial lesion, the posterior tibial artery and comitant vein were reconstructed with greater saphenous vein graft. Early below-knee amputation was done due to failed revascularization.



**Figure 4.** Secondary wound reconstruction of Gustilo IIIB fracture caused by fall from height (case R.V.) – secondary reconstruction of soft tissue defect. The patient referred from the other institution. **A.** External fixation, wound left open, condition after the fourth debridement. Persisting island of soft tissue necrosis, bone exposed. **B.** Fifth debridement, bone defect created by the resection of exposed and necrotic bone; wound temporarily covered with split skin graft. **C.** Free latissimus dorsi flap.



**Figure 5.** Secondary wound reconstruction of Gustilo IIIB fracture (case R.V.) – reconstruction of segmental bone defect. **A.** Segmental bone defect 11 cm. **B.** Segmental bone transport (proximal and distal corticotomy) with Ilizarov apparatus. **C.** Radiogram of the initiation of segmental bone transport (antero-posterior (left) and latero-lateral (right) view). **D.** Finished segmental transport, bone grafting of docking place (antero-posterior (left) and latero-lateral (right) view).

#### *Bone Defect Reconstruction*

Among 19 patients with non-reactive atrophic bone defect, there was a case with partially necrotic fragment, five cases with necrotic fragment, 12 cases with segmental defect, and one case with tibial shortening. Bone defect reconstruction was needed in 19 out of 20 patients in the secondary reconstruction group: 11 patients were treated with Ilizarov method (8 cases with segmental transport; one case with longitudinal half of part of "fibula pro tibia" synostosis transport; a case of double segmental transport (Figs. 4-6); and a case with tibial elongation); five patients with spongioplastics, and three patients with repeated osteosynthesis and interfragmental compression.

Johner and Wruhs' (18) criteria for the evaluation of final functional results after tibial shaft fracture were applied. Their criteria for evaluation of final functional results comprise the analysis of following parameters: nonunion, infection and amputation, axial deformation, motility of knee, ankle, and subtalar joint, pain, gait, and strenuous activities.

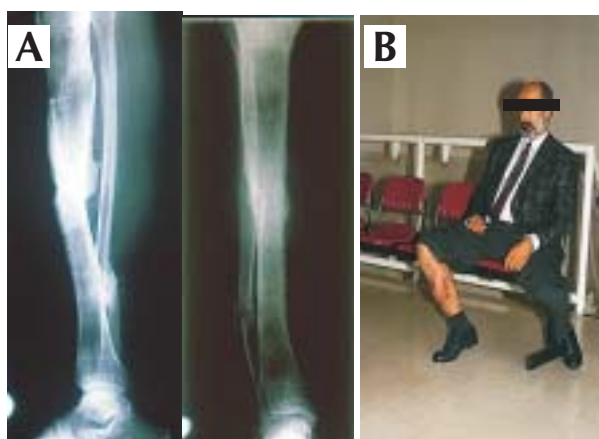Nonunion, osteomyelitis, gross deformity, amputation, and severe pain are undesirable outcomes and often used as criteria of poor result (18). However, osteomyelitis, nonunion, and tibial shortening may ultimately yield a very satisfactory limb after corrective treatment.

#### *Statistical Analysis*

Descriptive statistics, Kolmogorov-Smirnov test for normality, Student's t test, Mann-Whitney U test, and chi-square test were performed by using STATISTICA 6.0 (StatSoft, Inc., Tulsa, OK, USA) software package. When a median was calculated, the variability was expressed with the 25th and 75th percentiles.

Kolmogorov-Smirnov test for normality was used of the analysis of the following parameters: wound size before debridement; wound size after debridement; number of operations per patient; average time to recovery of all cases; duration of treatment of cases without osteomyelitis; duration of treatment of cases with osteomyelitis; and length of bone defect. The test





**Figure 6.** Secondary wound reconstruction of Gustilo IIIB fracture (case R.V.) – final result. **A.** Calus formation on the place of the proximal and distal corticotomy; calus distraction technique applied (antero-posterior (left) and latero-lateral (right) view). **B.** Patient condition.

proved the normal distribution in all tested parameters except the length of the bone defect in the primary reconstruction group (maxD=0.46,  $p < 0.014$ ).

**Results**

There was no significant difference between two groups in the sex ratio (chi-square=0.28,  $p = 0.599$ ), patient age ( $U = 111.500$ ,  $p = 0.199$ ), or ratio of isolated and associated injuries (6:9 in the primary reconstruction group and 9:11 in the secondary reconstruction group; chi-square=0.00,  $p = 0.963$ ). Likewise, no significant differences in the energy transfer (chi-square=0.07,  $p = 0.793$ ) and MESS score (chi-square=0.10,  $p = 0.951$ ) were found between the two groups. There was no statistically significant difference between the two groups in the type of osteosynthesis (chi-square=0.89,  $p = 0.344$ ).

Major bone complications occurred in eight out of 15 patients in the primary reconstruction group after the osteosynthesis and primary wound reconstruction, and in nine out of 20 patients in the secondary reconstruction group after the osteosynthesis and secondary wound reconstruction (Table 3). In the secondary reconstruction group, major bone complications occurred in eight out of 11 patients where the wound was covered with split skin graft, and in only one out of nine patients where the wound was left open to heal with granulations followed with flap reconstruction. There was no statistically significant dif-

**Table 3.** Comparison of major bone complications after primary and secondary reconstruction of Gustilo type III open tibial fractures

Type of complication	Reconstruction (No. of patients)	
	primary (n = 15)	secondary (n = 20)
Lower leg amputation	2	1
Osteomyelitis	3	4
Refracture	1	0
Nonunion	0	2
Malunion	0	1
Lower leg shortening	1	1
Skin necrosis	1	0
Total	8	9

ference in the frequency of major bone complications between the primary and the secondary reconstruction groups (chi-square=0.24,  $p = 0.883$ ; Table 3).

*Complications in the Primary Reconstruction Group*

Flaps for the treatment of complications were required in four patients (3 free flaps and one local flap). Treatment of three patients with osteomyelitis required 2 free flaps and one local flap made with the tissue expander.

The excision of inflamed bone and skin was carried out in two cases. After the improvement of osteomyelitis, bone defect was treated with spongio-plastics and with Ilizarov method in one patient each.

In a patient with osteomyelitis, tissue expander (450 mL) was applied near the border of the unstable scar. After being filled up, the expander was removed; unstable scar was excised, additional sequestrectomy was performed, and soft tissue was reconstructed with a local flap obtained by the tissue expander.

In a patient with the skin necrosis of the wound edge after the primary debridement and medial gastrocnemius flap, additional skin necrectomy and latissimus dorsi flap reconstruction were performed. Residual bone defect was treated with Ilizarov method. A patient with a refracture was treated with reosteosynthesis by using plates and screws. In a patient with tibial shortening, Ilizarov method was used for the bone lengthening. Early amputation was required in two patients after 2 and 4 weeks of trauma, respectively.

*Complications in the Secondary Reconstruction Group*

Among nine out of 20 patients with complications in the secondary reconstruction group, free latissimus dorsi flap was used in five cases, and local flap was used in a single case.

In three patients, free latissimus dorsi flaps were used to treat the osteomyelitis. After the osteomyelitis was cured, bone defect was treated with Ilizarov method in one patient, with intramedullary reosteosynthesis in another patient, and no additional operation was required in the third patient.

In a patient with a history of chronic alcohol abuse, osteomyelitis developed after flap reconstruction and persisted after proximal corticotomy and segmental transport (Ilizarov method of treatment for bone defect), and could not be resolved.

There were two patients with a nonunion. Free flap in one and local flap in the other patient were used for the reconstruction of unstable leg scar, followed by spongio-plastics of the bone defect.

Reconstruction of unstable scar with free latissimus dorsi flap followed by the ankle arthrodesis was done in a case with malunion of the distal tibial shaft fracture. In a patient with tibial shortening, the complication was treated with Ilizarov method. Early below-knee amputation was required 3 weeks after the injury in only one patient.



*Outcome and Duration of Treatment*

Total number of patients with bone defect (9/15 in the primary vs 19/20 in the secondary reconstruction group; chi-square=4.56, p=0.033), number of patients needing the bone defect reconstruction (6/15 vs 19/20, respectively; chi-square=10.15, p=0.001), and distribution of cases with segmental bone defect and tibial shortening (4/9 vs 13/19, respectively; chi-square=3.62, p=0.050) were significantly smaller in the primary reconstruction group.

**Table 4.** Final results according to Johner and Wruhs' criteria in primary and secondary reconstruction groups

Criteria	Reconstruction (No. of patients)*	
	primary (n=13)	secondary (n=19)
Pain:		
none	6	4
occasional	7	12
moderate	0	3
Strenuous activities:		
possible	11	4
limited	1	12
severely limited	0	3
impossible	1	0
Deformity varus-valgus (degrees):		
none	6	5
1-5	5	7
6-10	2	6
>10	0	1
Deformity anteversion-recurvation (degrees):		
none	9	9
1-5	3	3
6-10	1	6
11-15	0	1
Rotational deformity (degrees):		
none	11	13
1-5	1	3
6-10	1	3
Mobility knee:		
normal	12	16
>75%	1	2
rigid knee	0	1
Ankle mobility:		
normal	6	2
>75%	4	10
>50%	2	5
<50%	1	2
Neurovascular disturbances:		
none	11	14
moderate	0	2
minimal	2	3
nonunion	0	0
Leg shortening (mm):		
0-5	12	10
6-10	0	4
11-20	1	1
30-40	0	3
60	0	1

\*Two patients with amputation were excluded from the primary reconstruction group (n=15), and one patient with amputation was excluded from the secondary reconstruction group (n=20), which left 13 and 19 patients, respectively, for final assessment.

There was no statistically significant difference in the average length of segmental bone defect between the primary and secondary reconstruction group (5 cm, 25th-75th percentile=5-11 vs 6 cm, 25th-75th percentile=5-12, respectively; U=13.5, p=0.640).

Final functional results were assessed according to Johner and Wruhs' (18) criteria (Table 4). Final functional results in the primary reconstruction group were excellent or good in 10, fair in two, and poor in three out of 15 patients. Final functional results in the secondary reconstruction group were excellent or good in eight, fair in six, and poor in six out of 20 patients.

Complete recovery was achieved in 13 out of 15 patients in the primary reconstruction group and in 18 out of 20 patients in the secondary reconstruction group. There were no significant differences between the groups in the score of final functional result (U=113.0, p=0.217), median leg shortening (U=10.5, p=0.578), or proportion of completely recovered cases (chi-square=0.010, p=0.940).

The mean time of healing was significantly shorter in the primary (68 weeks, 25th-75th percentile=32-86) than in the secondary (115.5 weeks, 25th-75th percentile=70-128.5) reconstruction group (U=51.0, p=0.004; Table 5).

**Discussion**

Our results show that primary reconstruction of the wound after radical debridement prevents additional bone loss. Smaller total number of cases with bone defect after the primary wound reconstruction in Gustilo type III fracture was the main reason for smaller total number of operations and shorter time to recovery.

The management of the Gustilo type III open fractures starts with the assessment of energy transfer, clinical assessment and radiological examination, fracture classification, and MESS score. The classification of fracture influences the selection of the method of surgical management (6). There are numerous treatment protocols for Gustilo type III open tibial fractures (9-12). They differ in the type of osteosynthesis, timing of soft tissue reconstruction, type of flap, and method of treatment for bone defect. Indication for primary wound reconstruction was significantly more often made by the available microsurgical team. Secondary wound reconstruction was made significantly more often in cases where the treatment was initiated by a general surgeon.

**Table 5.** Number of operations, duration, and results of treatment in primary and secondary reconstruction group

Course of recovery	Reconstruction (median, 25th-75th percentile)		p*
	primary (n=15)	secondary (n=20)	
No. of operations per patient	4.0 (3.0-5.0)	7.5 (6.5-8.5)	<0.001
Time to recovery for all patients (weeks)	68.0 (32.0-86.0)	115.5 (70.0-128.5)	0.004
Duration of treatment in patients without osteomyelitis (weeks)	42.0 (30.0-75.5)	82.5 (54.0-136.0)	0.006
Duration of treatment in patients with osteomyelitis (weeks)	111.0 (68.0-144.0)	120.0 (100.0-125.0)	0.724
Functional result according to Johner and Wruhs' criteria (18)	4.0 (3.0-5.0)	3.0 (2.0-4.0)	0.197
Uncured osteomyelitis	0	1	0.885
Complete recovery	13	18	0.824

\*Mann Whitney U-test for continuous variables and chi-square test for fractions.

### *Debridement and Selection of Flap for Wound Reconstruction*

Wound dimension was defined primarily by the etiology of injury, energy of injury, and surgical debridement (one radical debridement in primary reconstruction, or serial debridements in secondary reconstruction). Wound cleanliness is required for any type of wound closure or reconstruction. The zone of tissue viability (zone of hyperemia) in cases with primary wound reconstruction was achieved with a single radical debridement, and in cases with secondary wound reconstruction it was achieved with repeated debridements.

There was certain numerical, but statistically insignificant difference between the two groups in wound dimension after radical or serial debridement. The need for wound closure/reconstruction is a universal surgical imperative (6). Wound reconstruction provides the best conditions for the healing of soft tissue defects. In our study, dimensions of the soft tissue defect determined the selection of the flap type, as local flaps were used for minor defects and free flaps for larger ones. Since there was no statistically significant difference in the wound size after debridement, there was no statistically significant difference in the number of flaps and the flap types between the groups.

Flap is the method of choice for soft tissue reconstruction. Use of flaps for wound reconstruction in different studies ranged from 65% to 100% (19-21). Our results support such approach. We performed flap reconstructions in 11 patients in the primary reconstruction group and in 18 patients in the secondary reconstruction group. After a single radical debridement or repeated debridements, when the wound margins and bone were viable, it was necessary to cover the soft tissue defect with a flap because the flap transformed the open fracture into the closed one, thus providing the conditions necessary for wound healing and continuing the treatment of the fracture and bone defect. These data justified the high use of flaps in our study.

### *Incidence of Osteomyelitis*

We found no statistically significant difference in the incidence of osteomyelitis and major bone complications between the groups with primary and secondary wound reconstruction. We assume that a single radical ("oncological") debridement in patients with primary wound reconstruction and serial thorough debridements in patients with secondary reconstruction achieve the same goal, ie, complete removal of devitalized or inflammatory changed bone and soft tissue. This is the main factor that contributed to equal incidence of osteomyelitis in both study groups.

### *Bone Defect Reconstruction*

The method of bone defect reconstruction depends on the dimension of a bone defect (22,23). The number of patients with a bone defect caused by the infection was not the main factor influencing the time to recovery in our study because there was no statistically significant difference in incidence of osteomyelitis between the primary and the secondary wound reconstruction groups. There was no statistically sig-

nificant difference between the injuries in the primary and secondary reconstitution group in the energy transfer and the type of fracture, ie, different energy transfer itself was not responsible for the difference in the number of cases with bone defect and size of bone defect between the two groups.

The total number of Gustilo type III open tibial shaft fractures with bone defect and type of residual bone defect depended on the method of debridement and timing of wound reconstruction (method and timing have to be considered as a unique process because debridement is not the purpose but the tool). Radical debridement and immediate wound reconstruction defined the number of cases with a bone defect and type of bone defect, which rarely changed during the successive treatment. Primary wound reconstruction prevented additional bone loss. Time to recovery was significantly shorter in patients with primary wound reconstruction due to smaller number of cases with a bone defect.

Repeated debridement contributed to the increased number of cases with bone defect and dimension of bone defects. In the secondary soft tissue reconstruction of the lower leg, bone was not initially covered with the skin. Bone without adequate circulation and soft tissue coverage during the staged period was predetermined to disintegration. Every repeated debridement of exposed bone increased the bone defect for the size of the zone of newly devitalized bone between the two debridements, until the bone was covered with granulations, local flaps, or free flaps. This substantial change of bone in Gustilo type III open fractures caused by the repeated debridements and with secondary soft tissue reconstruction of wound increased the time to recovery and influenced the final result.

In conclusion, primary reconstruction of Gustilo type III open tibial fractures had statistically significant advantages compared with secondary reconstruction: there were fewer cases with a bone defect, segmental bone defect and tibial shortening occurred less frequently, and bone defect reconstruction was less frequently indicated. These advantages resulted in a smaller total number of operations and shorter time to complete recovery. There was no statistically significant difference between the primary and secondary reconstruction groups in the incidence of osteomyelitis, number of amputations required, non-unions, number of flaps used, and final functional results. Our findings suggest that primary reconstruction is the treatment of choice and should be chosen whenever the general condition of the patient and surgical facility permit its use.

### **Acknowledgment**

We thank Prof. Mladen Petrovečki for his valuable comments while preparing this manuscript.

### **References**

- 1 Gustilo RB, Mendoza RM, Williams DN. Problems in the management of type III (severe) open fractures: a new classification of type III open fractures. *J Trauma* 1984;24:742-6.

- 2 Georgiadis MG, Behrens F, Joyce JM, Earle AS, Simmons AL. Open tibial fractures with severe soft-tissue loss. Limb salvage compared with below-the-knee amputation. *J Bone Joint Surg Am* 1993;75:1431-41.
- 3 Hertel R, Lambert SM, Muller S, Ballmer FT, Ganz R. On the timing of soft-tissue reconstruction for open fractures of the lower leg. *Arch Orthop Trauma Surg* 1999; 119:7-12.
- 4 Godina M. Early microsurgical reconstruction of complex trauma of the extremities. *Plastic Reconstr Surg* 1986;78:285-92.
- 5 De Long WG Jr, Born CT, Wei SY, Petrik ME, Ponzio R, Schwab CW. Aggressive treatment of 119 open fracture wounds. *J Trauma* 1999;6:1049-54.
- 6 Behrens FF. Fractures with soft tissue injuries. In: Browner BD, Jupiter JB, Levine AM, Trafton PG, editors. *Skeletal trauma: fractures, dislocations, ligamentous injuries*. 2nd ed. Philadelphia (PA): Saunders; 1998. p. 391-418.
- 7 Johansen K, Daines M, Howey T, Helfet D, Hansen ST. Objective criteria accurately predict amputation following lower extremity trauma. *J Trauma* 1990;30:568-73.
- 8 Roje Z, Mikuš D, Baković A, Čukelj F, Opačak R, Družijanić N, et al. Surgical treatment of war injuries: experiences with 1,220 patients from the Split University Hospital, Split, Croatia. *Croat Med J* 1997;38: 129-39.
- 9 Olson SA. Open fractures of the tibial shaft. *Instr Course Lect* 1997;46:293-302.
- 10 Yaremchuk MJ. Acute management of severe soft-tissue damage accompanying open fractures of the lower extremity. *Clin Plast Surg* 1986;13:621-9.
- 11 Caudle RJ, Stern PJ. Severe open fractures of the tibia. *J Bone Joint Surg Am* 1987;69:801-7.
- 12 Tornetta P, Bergman M, Watnik N, Berkowitz G, Steuer J. Treatment of grade-IIIb open tibial fractures: a prospective randomized comparison of external fixation to non-reamed locked nailing. *J Bone Joint Surg Br* 1994;76:13-9.
- 13 Keen RR, Meyer JP, Durham JR, Eldrup-Jorgensen J, Flanigan P, Schwarcz TH, et al. Autogenous vein graft repair of injured extremity arteries: early and late results with 134 consecutive patients. *J Vasc Surg* 1991;13: 664-8.
- 14 Reigstad A, Hetland KR, Bye K, Waage S, Rikkum M, Husby T. Free tissue transfer for type III tibial fractures: microsurgery in 19 cases. *Acta Orthop Scand* 1992;63: 477-81.
- 15 Ilizarov GA, Ledyayev V. The classic: the replacement of long tubular bone defects by lengthening distraction osteotomy of one of the fragments. *Clin Orthop Rel Res* 1992;280:7-10.
- 16 Barbarossa V, Kučičec-Tepeš N, Aldova E, Matek D, Stipoljev F. Ilizarov technique in the treatment of chronic osteomyelitis caused by *Vibrio alginolyticus*. *Croat Med J* 2002;43:346-9.
- 17 Müller ME, Allgöwer M, Schneider R, Willenegger, H. *Manual of Internal Fixation Techniques Recommended by the AO-ASIF Group*. 3rd ed. Berlin Heidelberg: Springer-Verlag; 1991.
- 18 Johner R, Wruhs O. Classification of tibial shaft fractures and correlation with results after rigid internal fixation. *Clin Orthop* 1983;178:7-25.
- 19 Velazco A, Fleming LL, Nahai F. Soft tissue reconstruction of the leg associated with use of the Hoffman external fixator. *J Trauma* 1983;23:1052-7.
- 20 Small JO, Mollan RA. Management of the soft tissues in open tibial fractures. *Br J Plast Surg* 1992;45:571-7.
- 21 Gopal S, Majumder S, Batchelor AG, Knight SL, De Boer P, Smith RM. Fix and flap: the radical orthopaedic and plastic treatment of severe open fractures of the tibia. *J Bone Joint Surg Br* 2000;82:959-66.
- 22 Francel TJ, Vander Kolk CA, Hoopes JE, Manson PN, Yaremchuk MJ. Microvascular soft-tissue transplantation for reconstruction of acute open tibial fractures: timing of coverage and long-term functional results. *Plast Reconstr Surg* 1992;89:478-89.
- 23 Reigstad A. Soft tissue defects and bone loss in tibial fractures – treatment with free flaps and bone transport. *Acta Orthop Scand* 1997;68:615-22.

Received: March 17, 2003

Accepted: November 6, 2003

**Correspondence to:**

Hrvoje Štalekar  
Department of Surgery, Division for Traumatology  
Rijeka University Hospital Center  
Tome Strižića 3  
51000 Rijeka, Croatia  
[hstaleka@inet.hr](mailto:hstaleka@inet.hr)