

Spontaneous recanalization of internal carotid artery occlusion

Tuškan-Mohar, Lidija; Legac, Marko; Bralić, Marina; Budiselić, Berislav

Source / Izvornik: **Wiener klinische Wochenschrift, 2010, 122, 633 - 636**

Journal article, Published version

Rad u časopisu, Objavljena verzija rada (izdavačev PDF)

<https://doi.org/10.1007/s00508-010-1490-2>

Permanent link / Trajna poveznica: <https://um.nsk.hr/um:nbn:hr:184:126037>

Rights / Prava: [Attribution-NonCommercial-NoDerivatives 4.0 International/Imenovanje-Nekomercijalno-Bez prerada 4.0 međunarodna](#)

Download date / Datum preuzimanja: **2024-07-23**



Repository / Repozitorij:

[Repository of the University of Rijeka, Faculty of Medicine - FMRI Repository](#)



Spontaneous recanalization of internal carotid artery occlusion

Lidija Tuskan-Mohar¹, Marko Legac¹, Marina Bralic¹, Berislav Budiselic²

¹Department of Neurology, Clinical Hospital Center Rijeka, Rijeka, Croatia

²Department of Radiology, Clinical Hospital Center Rijeka, Rijeka, Croatia

Received February 5, 2010, accepted after revision September 19, 2010, published online November 12, 2010

Spontane Rekanalisierung eines Carotis interna Verschlusses

Zusammenfassung. Wir stellen einen Fall mit spontaner Rekanalisierung eines Carotis interna Verschlusses vor, der bei einem 51-jährigen männlichen Patienten beobachtet wurde. Der Verschluss der rechten Arteria carotis interna war asymptomatisch und ein Zufallsbefund im Rahmen der bildgebenden Untersuchung der Arteria carotis der Gegenseite. Die anschließend durchgeführte neuroradiologische Untersuchung ergab eine flammenartige Okklusion, die den Verdacht einer Dissektion der Arterie nahelegte. Die 1 und 5 Monate später durchgeführte Doppler-Ultraschall-Untersuchungen zeigten eine offene rechte Arteria Carotis mit normalem Fluss.

Summary. We present a case of spontaneous recanalization of the internal carotid artery (ICA) that occurred in a 51-year-old male patient. The occlusion of the right ICA was asymptomatic and was detected incidentally during imaging of the opposite carotid artery. The patient underwent neuroradiologic analysis and a tapered, flame-like occlusion suggestive of the right ICA dissection was detected. One month later, a carotid Doppler ultrasound demonstrated patent right carotid artery with normal spectral flow. Five-month follow-up showed that the ICA remained patent.

Key words: Internal carotid artery, dissection, occlusion, spontaneous recanalization.

Introduction

Spontaneous recanalization (SR) of the internal carotid artery (ICA) is a relatively uncommon phenomenon [1]. The possibility of its low incidence is probably due to the fact

that, until some years ago, its definitive diagnosis could be obtained only by an invasive examination [1, 2]. The mechanism of SR remains unclear [3]. The incidence of SR varies from very rare to as high as 15.8% [1–3].

In this article we report a case of a patient with a SR of the ICA that occurred within 30 days after the initial diagnosis of occlusion. Since occlusion was asymptomatic it was an incidental finding. The patient underwent neuroradiologic analysis and a tapered, flame-like occlusion suggestive of the right ICA dissection was detected.

Case report

A 51-year-old man was referred to neurology department after an acute stroke with right-sided hemiparesis, speech disturbance, and blurry vision in the left eye. The patient had no history of diabetes mellitus or heart disease although his medical history was notable for hypertension and cigarette smoking. Routine blood testing, including coagulation tests and the heart ultrasound all came back normal. Computed tomography (CT) of the brain revealed ischemic infarct at the parietal region of the left cerebral hemisphere (14 × 10 mm) and suspected pons ischemic lesion. Because of suspected ischemic pons lesion magnetic resonance imaging (MRI) of the brain was preformed. MRI finding excluded pons infarction and confirmed ischemic lesions of the left cerebral hemisphere. In addition, on the MRI microischemic changes of both hemispheres were found. A color duplex carotid ultrasound scan revealed high stenosis of the left ICA (70–80%) and an occlusion of the right ICA. One week later patient underwent a selective digital subtraction angiography (DSA) which showed an occlusion of the right ICA and significant stenosis of the left ICA (Figs. 1 and 2).

Due to significant stenosis of the left ICA that was symptomatic and the contralateral ICA occlusion endovascular treatment was performed. Systemic anticoagulation (intravenous bolus of heparin 5000 IU) was given according to standard procedure. DSA after carotid artery stenting (CAS) showed good deployment of the stent in the left ICA, while occlusion of the right ICA remained. No neurophys-

Correspondence: Lidija Tuskan-Mohar, MD, PhD,
 Department of Neurology, Clinical Hospital Center Rijeka,
 Cambierieva 17, 51 000 Rijeka, Croatia, E-mail: ltuskan@net.hr

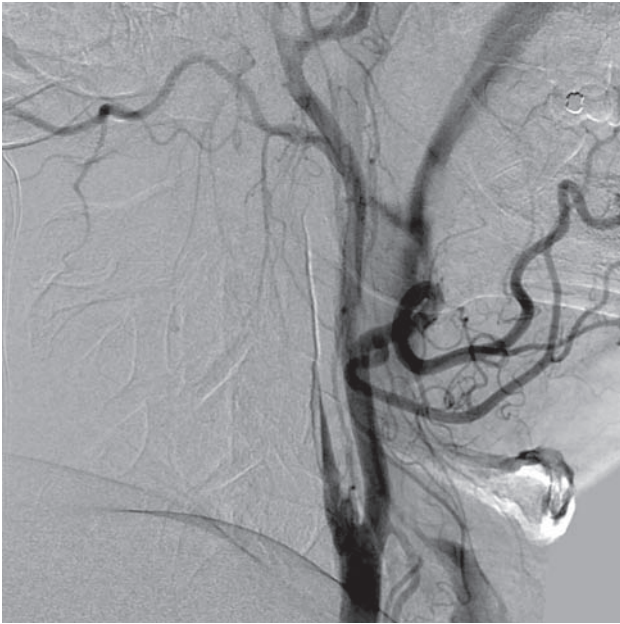

Fig. 1. DSA shows occlusion of the right ICA

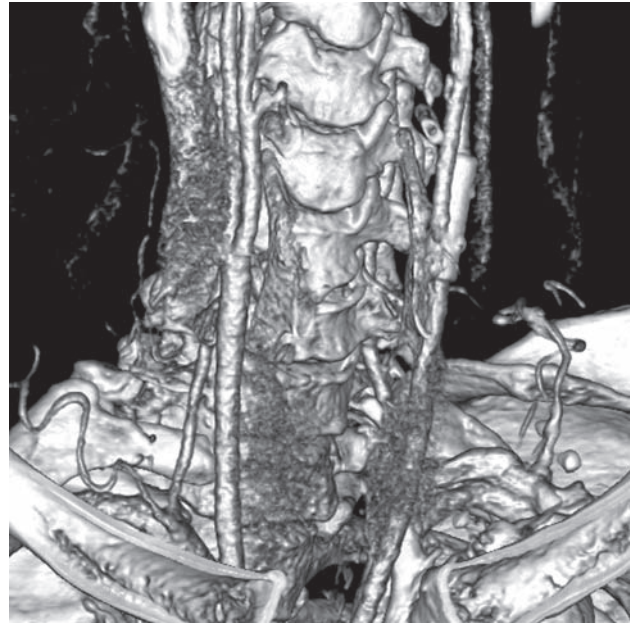


Fig. 3. MSCTA, volume-rendered technique (VRT) shows stent in the left ICA and recanalization of the right ICA

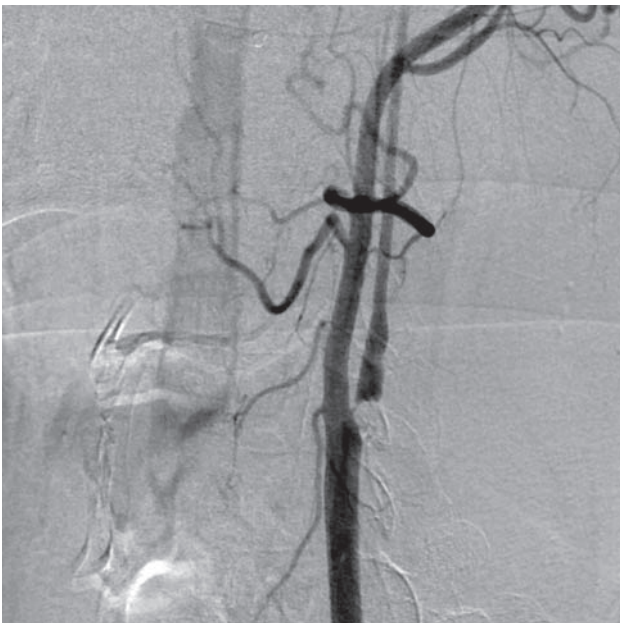


Fig. 2. DSA shows eccentric stenosis of the proximal left ICA

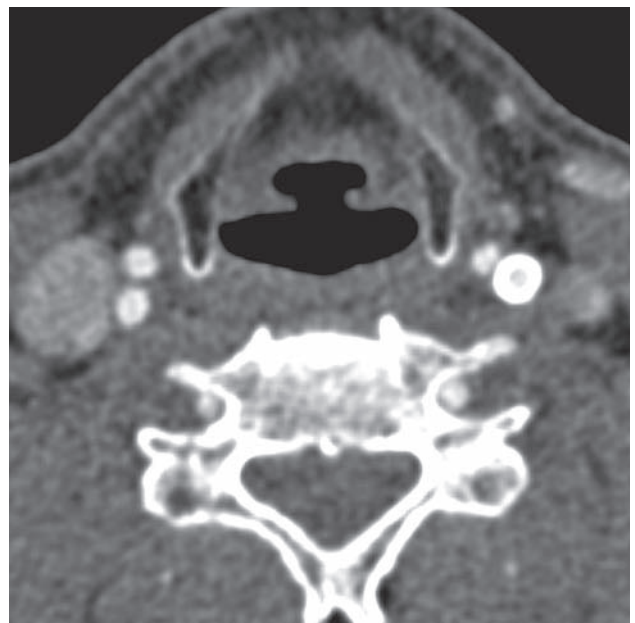

Fig. 4. MSCTA, multi-planar reconstruction (MPR) – axial section – shows stent in the left ICA and recanalization of the right ICA

ologic changes were identified during or after procedure. The patient was discharged home with 75 mg daily dose of clopidogrel and 100 mg daily dose of aspirin as secondary prophylaxis for the prevention of ischemic stroke. He improved from an NIH stroke score (NIHSS) of 10 at the time of admission to an NIHSS of 2 when discharged from hospital. The follow-up color duplex ultrasound was done one month after the CAS, which showed well-positioned stent in the left ICA and recanalization of the right ICA. These findings were confirmed with the MSCT (angiography Figs. 3 and 4). After 5 months, as a routine follow-up a ca-

rotid color duplex scan showed normal blood flow in both internal carotid arteries (Fig. 5).

Discussion

The diagnosis of recanalization of the ICA is not frequent, with no accurate data in the literature about its incidence or most common period of occurrence, since its definitive diagnosis is dependent on an invasive examination that is not free from complications [3, 4].

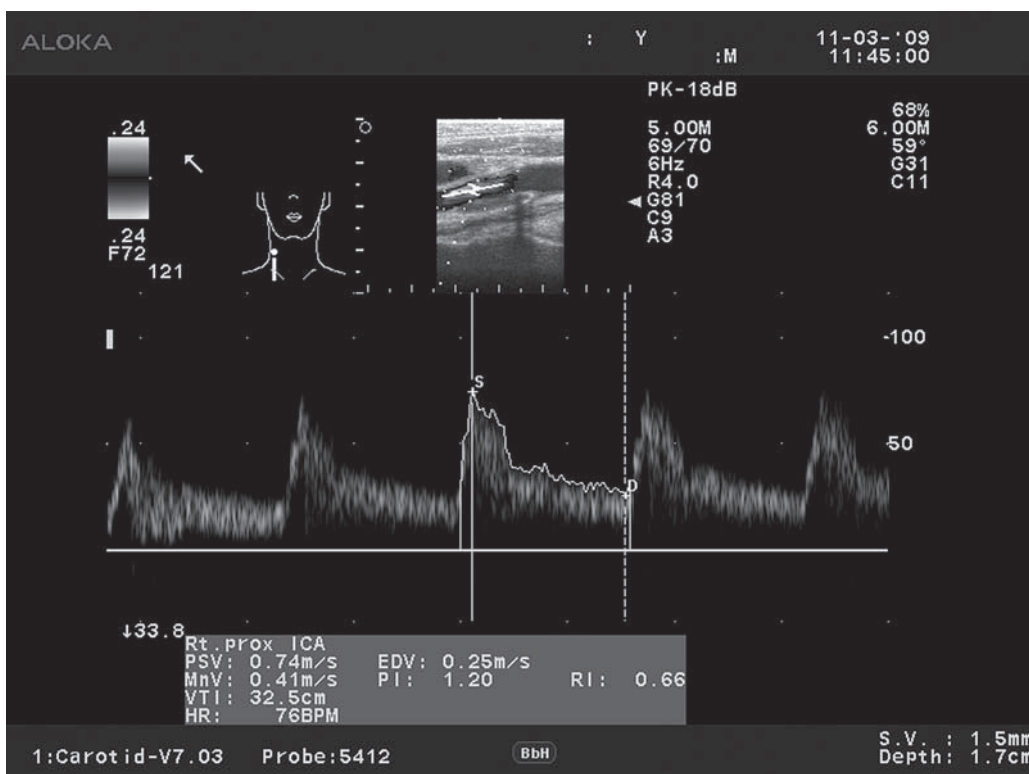


Fig. 5. Color duplex carotid ultrasound scan shows satisfactory blood flow and velocity measurements of spontaneously recanalized right ICA after a 5-month follow-up (ProSound Alpha 10, UST-5412 4-13 MHz 36mm High Frequency Linear Probe with Harmonic Echo Imaging)

According to studies, when spontaneous recanalization of the ICA occurs it is a rather early event, that most commonly happens between 6 hours and 2 weeks [1]. Meves et al. [5] observed spontaneous recanalization of 33% in up to 7 days in 18 patients with the ICA occlusion. In our case SR of ICA occurred within 30 days after the initial diagnosis of occlusion, clearly represents a later recanalization.

Little is known and much is hypothesized about the underlying mechanism of the spontaneous ICA recanalization. Lammie et al. [6] in 1999, advised occlusion as a consequence of ulcerated plaque thrombosis presenting long-term recanalization by thrombolysis.

An explanation proposed by Calleja et al. [7] suggests that an acute intraplaque hemorrhage occurs causing a temporary occlusion at the location of the plaque. With regress of endothelial edema, the vessel recanalizes spontaneously.

Colon et al. [8] published a series of four cases of SR of the ICA, which through imaging examinations and intraoperative finding, proved to be a hypertrophy of *vasa vasorum*, causing reperfusion of the ICA distal to the occlusion. The *vasa vasorum*, in large-caliber vessels, such as the ICA, are present both in adventitia and in tunica media. In case of myointimal hyperplasia or atherosclerotic disease, a neovascularization is induced, this, in the long term, can allow perfusion distal to vessel occlusion [8]. In addition, mechanism of occlusion due to dissection of the ICA was employed by Eljamel et al. [9] in 1990.

In our case, according to angiographic analysis, dissection cannot be ruled out since a tapered, flame-like

occlusion suggestive of artery dissection was detected (Fig. 1).

It is important to make a difference between the ICA dissection and atheromatous disease, which may have a very similar angiographic appearance, since the management is different for these two processes. The ICA dissection can usually be distinguished from atherosclerotic narrowing by location, shape, and associated clinical and angiographic features. The ICA dissection usually occurs at sites that are atypical for atheromatous disease. They are frequently located a few centimeters distal to the common carotid bifurcation, while atheromatous changes are usually located just at the ICA origin [10]. The incidence of carotid artery dissection was reported to be 2.6–2.9 per 100,000/year [11, 12]. The dissections of craniocervical arteries are infrequent but important cause of stroke, especially in the middle-aged. According to the literature, carotid and vertebral artery dissection accounts for up to 25% of strokes in patients younger than 45 years of age [12].

In majority of cases patients with the ICA dissection are symptomatic when the diagnosis is made, but in our case it was detected incidentally in an asymptomatic patient [13, 14]. Spontaneous recanalization of the ICA has been described in ICA dissections in about 57–68% of the cases, but it has rarely been observed in the patients suffering with an underlying atherosclerotic disease or an embolic cause [15, 16].

Labonek et al. [17] in 2006, reported a case of spontaneous resolution of mural thrombus that caused sympto-

matic severe ICA stenosis. He presumed that this stenosis could have been caused by an acute thrombus occurring into an older calcified atherosclerotic plaque. He argues that dissolving was accelerated by heparin bolus (5000 units) that was administered intravenously before ICA opening [17].

In addition, antithrombotic and anticoagulant agents have not been proven effective in the lysis of existing clots. Our patient was placed on dual antithrombotic therapy to reduce the risk of further strokes.

After stent implantation in the ICA follow-up is routinely performed after 24 hours, then at 3, 6, 12 months and after 2 years. In our case during routine follow-up of the contralateral stent of left ICA, recanalization of right ICA as incidental finding was found. According to the literature routine follow-up of all patients with ICA occlusion may not be cost-effective. However, in patients who are routinely followed up with serial duplex scans for the detection of any progressive atherosclerotic occlusive disease in the contralateral ICA, an additional check on the occluded side may be justified [18].

Conclusion

We report an interesting case of a patient with asymptomatic occlusion and spontaneous recanalization of the right ICA. To date, exact mechanism, natural history, and precise management of this rare entity remain unclear.

It is possible that a carotid artery dissection occurred, causing complete occlusion.

It is known that dissection of the ICA is an important cause of stroke, headache, cranial nerve palsy, and ophthalmologic events, especially in young adults. Having that in mind, when the ICA dissection is suspected, the patient should be immediately referred to an appropriate medical specialist for evaluation and treatment.

Conflict of interest

The authors declare that there is no conflict of interest.

References

1. Nguyen-Huynh MN, Lev MH, Rordorf G. Spontaneous recanalization of internal carotid artery occlusion. *Stroke* 2003;34:1032-4.
2. Klonaris C, Alexandrou A, Katsargyris A, Liasis N, Bastounis E. Late spontaneous recanalization of acute internal carotid artery occlusion. *J Vasc Surg* 2006;43:844-7.

3. Binning MJ, Jackson G, Couldwell WT. Spontaneous recanalization of the internal carotid artery resulting in thromboembolic occlusion of the ipsilateral ophthalmic artery and visual loss. *J Clin Neurosci* 2009;16:1244-6.
4. Verlatto F, Camporese G, Bernardi E, Salmistraro G, Rocco S, Mayellaro V, et al. Clinical outcome of patients with internal carotid artery occlusion: a prospective study. *J Vasc Surg* 2000;32:293-8.
5. Meves SH, Muhs A, Federlein J, Buttner T, Przuntek H, Postert T. Recanalization of acute symptomatic occlusions of the internal carotid artery. *J Neurol* 2002;249:188-92.
6. Lammie GA, Sandercock PA, Dennis MS. Recently occluded intracranial and extracranial carotid arteries. Relevance of the unstable atherosclerotic plaque. *Stroke* 1999;30:1319-25.
7. Calleja S, De La Vega V, Llana JM, Lopez-Roger R, Gutierrez JM, Lahoz CH. Spontaneous recanalization of acute internal carotid artery occlusion. *Ann Vasc Surg* 2004;18:490-2.
8. Colon G, Deveikis JP, Dickinson LD. Revascularization of occluded internal carotid arteries by hypertrophied vasa vasorum: report of four cases. *Neurosurgery* 1993;45:634-7.
9. Eljamel MS, Humphrey PR, Shaw MD. Dissection of the cervical internal carotid artery. The role of Doppler/Duplex studies and conservative management. *J Neurol Neurosurg Psychiatry* 1990;53:379-83.
10. Provenzale JM. Dissection of the internal carotid and vertebral arteries: imaging features. *Am J Roentgenol* 1995;165:1099-104.
11. Lee VH, Brown RD Jr, Mandrekar JN, Mokri B. Incidence and outcome of cervical dissection: a population-based study. *Neurology* 2006;67:1809-12.
12. Schievink WI. Spontaneous dissection of the carotid and vertebral arteries. *N Engl J Med* 2001;344:898-906.
13. Biondi A, Katz JM, Vallabh J, Segal AZ, Gobin YP. Progressive symptomatic carotid dissection treated with multiple stents. *Stroke* 2005;36:80-2.
14. Kim EJ, Koh JS, Choi WS. Carotid artery stenting in a patient with spontaneous recanalization of a proximal internal carotid artery occlusion: a case report. *Korean J Radiol* 2006;7:292-6.
15. Mokri B, Sundt TM Jr, Houser OW, Piepgras DG. Spontaneous dissection of the cervical internal carotid artery. *Ann Neurol* 1986;19:126-38.
16. Ozdoba C, Sturzenegger M, Schroth G. Internal carotid artery dissection: MR imaging features and clinical/radiologic correlation. *Radiology* 1996;199:191-8.
17. Labonek M, Sanak D, Herzig R, Burval S, Bachleda P, Vlachova I, et al. An uncommon case of spontaneous resolution of mural thrombus causing symptomatic severe stenosis of the extracranial part of the internal carotid artery. *Biomed Pap Med Fac Univ Palacky Olomouc Czech Repub* 2006;150:299-302.
18. Berkefeld J, Turowski B, Dietz A, Lanfermann H, Sitzer M, Schmitz-Rixen T, et al. Recanalization results after carotid stent placement. *Am J Neuroradiol* 2002;23:113-20.