

Propane-Associated Autoerotic Asphyxiation: Accident or Suicide?

Stemberga, Valter; Bralić, Marina; Bosnar, Alan; Čoklo, Miran

Source / Izvornik: **Collegium antropologicum, 2007, 31, 625 - 627**

Journal article, Published version

Rad u časopisu, Objavljena verzija rada (izdavačev PDF)

Permanent link / Trajna poveznica: <https://um.nsk.hr/um:nbn:hr:184:573553>

Rights / Prava: [Attribution-NoDerivatives 4.0 International](#)/[Imenovanje-Bez prerada 4.0 međunarodna](#)

Download date / Datum preuzimanja: **2025-01-13**



Repository / Repozitorij:

[Repository of the University of Rijeka, Faculty of
Medicine - FMRI Repository](#)



Propane-Associated Autoerotic Asphyxiation: Accident or Suicide?

Valter Stemberga, Marina Bralić, Alan Bosnar and Miran Čoklo

Department of Forensic Medicine, School of Medicine, University of Rijeka, Rijeka, Croatia

ABSTRACT

Autoerotic fatalities refer to a death resulting from the participation in a sex-related activity designed to heighten sexual arousal. The overwhelming majority of these deaths are due to asphyxia, most often by hanging or ligature compression of the neck. Here we report a case of »atypical« autoerotic fatality in which death was not induced by ligature compression. Unusual death of a 24-year-old man, involving propane inhalation and plastic bag suffocation, is described. The special characteristics of propane gas as an asphyxiant agent are discussed, as well as its effect on the human body.

Key words: autoerotic death, asphyxia, propane inhalation

Introduction

Autoerotic fatalities have been well described in the literature and can be defined as deaths during masturbation or during a sexual ritual¹. Most of these case reports support the belief that anoxia intensifies or prolongs the sexual experience, thus these autoerotic deaths are due to asphyxia, usually achieved by neck compression, oxygen deprivation, airway obstruction, and chest compression. Autoerotic fatality caused by hanging or ligature compression of the neck are so-called »typical«. In addition, some autoerotic deaths are more bizarre, and they involve sexual self-stimulation using nitrous oxide, isobutyl nitrite, propane, cocaine, or compounds containing 1-1-1-trichloroethane². We present case where death was caused by the propane gas inhalation. It was difficult to discern death as accidental or suicidal.

Case Report

The decedent was a 24-year old man who was a professional truck driver. In the morning he was found unresponsive in his truck on the parking place in front of the supermarket he was supposed to deliver merchandize. He was lying supine, naked on the bed in his cabin, plastic sacks enwrapped over the whole body. Next to his left side a tank of propane gas was found. The body position suggested masturbation. A plastic sack fixed around the penis contained a seamen residue. A nearby, several other propane containers were found in the cabin (Figures 1, 2).

Autopsy performed the same day when body was found revealed no signs of aggression. No evidence of drug abuse or trauma was discovered. The blood was negative for ethyl alcohol and common drugs of abuse, including cocaine. The physical examination revealed a marked congestion of the face and pinpoint hemorrhagic infiltrates in the conjunctive and sclera. Foam emanating from the mouth and nose was noted. Autopsy results included cerebral congestion, pulmonary and visceral edema and congestion and petechial hemorrhage of the pleura. Identifying and quantifying of the hydrocarbon was performed using a headspace-gas chromatography analysis, following a standard method. Specimens of blood, brain, lungs and liver gave positive results for the propane gas.

Since the postmortem examination did not reveal any evidence of injury or natural disease, death was certified as accidental and the cause of death was listed as »atypical« autoeroticism associated with propane gas abuse.

Discussion

Although the majority of deaths that occur during autoerotic episodes represent accidental deaths, they remain difficult to distinguish from suicide and masked homicide. An accurate police investigation, medico-legal evaluation of the circumstances throughout postmortem

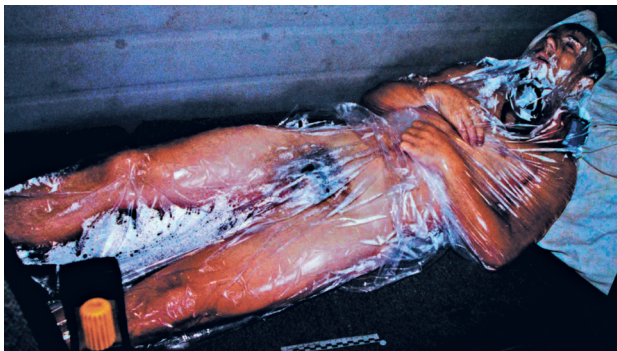

Fig. 1. The decedent was discovered in his cabin enveloped in plastic bag with a tank of propane gas placed underneath.

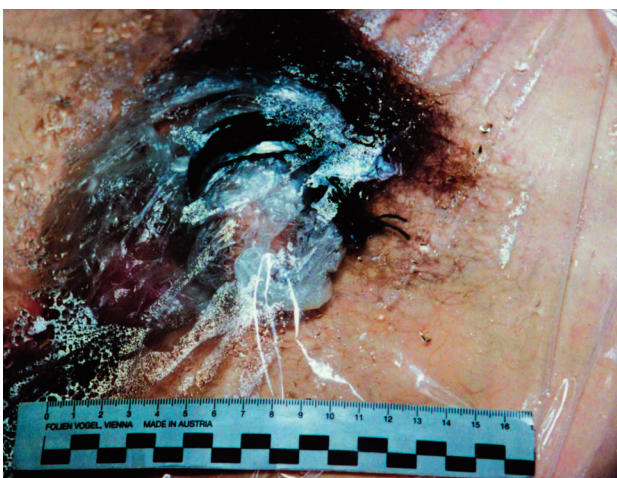


Fig. 2. Ligature about the penis.

examination and inspection are extremely important for determination of the cause and manner of death³.

It is essential to exclude accidental death from suicide and homicide for legal, insurance, social and family psychological purposes. Thus, criteria for the differential diagnosis of sexual asphyxia as accidental death from suicide are very important⁴.

Propane is colorless, odorless gas of the alkane series of hydrocarbons, of formula C_3H_8 . Inhalation of propane gas is known to cause dizziness, nausea, vomiting, confusion, and a feeling of euphoria. In a high concentration

propane has a narcotic effect and its abuse can result in cardiac arrest resulting from suppression of central nervous system⁵. Propane gas inhalation has been found to create a heightened level of physical pleasure and a semi hallucinogenic state, associated with autoerotic pleasures^{6,7}.

Our case satisfies some of the criteria of autoerotic death laid down by Hazelwood⁵. The descent was found locked in cabin of his truck, he was acting alone, and many propane cans around the deceased indicated previous autoerotic sexual activity. No evidence of suicidal note designated accidental death, but lack of any »escape route« raises suspect of suicide.

For distinguishing autoerotic death is very important to interview anyone who may be able to provide insight into the decedent's habits, likes and dislikes^{3,8}. In our case, no formal »psychological autopsy« was performed since the descent was from the foreign country and no documents or information about history of his mental illness was obtained. In this case the hypothesis of accidental death during the course of autoerotic maneuver could be entertained according to scene investigation and autopsy report^{9,10}.

Conclusion

We performed a retrospective study in southwestern Croatia with 350 000 inhabitants in time period from 1968 to 2004. Around 12 000 autopsies were performed, and only this one was attributed to autoerotic fatality. Interestingly, the descent in this case was citizen of one European country. No existence of autoerotic deaths in our Region partially can be attributed to the shame and embarrassment of family members who attempt to conceal the event and in some instances can create difficulties in death scene investigation. Thus, we believe that certain number of autoerotic fatalities was never disclosed in our local community^{11,12}.

In summary, we have presented case of »atypical« autoerotic death in order to alert death investigators that these unusual fatalities may be confused with other causes and manners of death. In such cases the forensic pathologist has a role, not only in establishing the cause and manner of death but also in advising clinicians on how to identify persons involved in this peculiar type of behavior.

REFERENCES

1. BYARD RW, BRAMWELL NH, Am J Forensic Med Pathol, 12 (1991) 74. — 2. GOWITT GT, HANZLICK RL, Am J Forensic Med Pathol, 13 (1992) 115. — 3. JOBES DA, BERMAN AL, JOSSELSOAN AR, J Forensic Sci, 31 (1986) 177. — 4. BREITMEIER D, MANSOURI F, ALBRECHT K, BOHM U, TROGER HD, KLEEMANN WJ, Forensic Sci Int, 137 (2003) 41. — 5. MUSSHOF F, PADOSCH SA, KROENER LA, MADEA B, Am J Forensic Med Pathol, 27 (2006) 188. — 6. HAZELWOOD RR, BURGESS AW, GROTH AN, Soc Sci Med, 15 (1981) 129. — 7. FONSECA CA, AUERBACH DS, SUAREZ RV, Am J Forensic Med Pathol, 23 (2002) 167. — 8.

- HAQ MZ, HAMELI AZ, J Forensic Sci, 25 (1980) 25. — 9. SHIELDS LB, HUNSAKER DM, HUNSAKER JC 3RD, WETLI CV, HUTCHINS KD, HOLMES RM, Am J Forensic Med Pathol, 26 (2005) 53. — 10. WALSH FM, STAHL CJ 3RD, UNGER HT, LILIENSTERN OC, STEPHENS RG 3RD, Leg Med Annu, 12 (1977) 155. — 11. KARLOVIĆ D, GALE R, THALLER V, MARTINAC M, KATINIĆ K, MATOŠIĆ A, Coll Antropol, 29 (2005) 519. — 12. MARCIKIĆ M, UGLJAREVIĆ M, DIJANIĆ T, DUMENČIĆ B, POZGAIN I, Coll Antropol, 27 (2003) Suppl 1:101.

M. Bralić

*Department of Forensic Medicine, School of Medicine, Vukovarska 11, 51000 Rijeka, Croatia
e-mail: bralic_marina@yahoo.com*

**AUTOEROTSKA ASFIKSIJA UZROKOVANA PROPANOM:
NESRETNI SLUČAJ ILI SAMOUBOJSTVO?**

S A Ž E T A K

Autoerotskim smrtima nazivaju se smrtni ishodi koji su posljedica upražnjavanja različitih seksualnih aktivnosti koje se provode kako bi se pojačao seksualni užitak. Uzrok velike većine tih smrti je asfiksija koja se postiže najčešće vješanjem ili ligaturnom kompresijom vrata. U članku prikazujemo slučaj »netipične« autoerotske smrti koja nije uzrokovana ligaturnom kompresijom. Opisujemo neobičnu smrt 24-godišnjeg mladića koja je posljedica udisaja propana i davljenja plastičnom vrećicom. Nadalje, diskutiramo o posebnim značajkama propana kao uzročnika asfiksije te o njegovom utjecaju na ljudski organizam.