

Ventrolateral disc herniation causes psoas muscle compression: A case report

Pavlović, Tomislav; Štefančić, Krunoslav; Rožanković, Marjan; Boban, Luka; Borić, Igor; Molnar, Vilim; Zekan, Paulo; Primorac, Dragan

Source / Izvornik: **Radiology Case Reports, 2020, 15, 136 - 140**

Journal article, Published version

Rad u časopisu, Objavljena verzija rada (izdavačev PDF)

<https://doi.org/10.1016/j.radcr.2019.10.031>

Permanent link / Trajna poveznica: <https://urn.nsk.hr/urn:nbn:hr:184:733026>

Rights / Prava: [Attribution-NonCommercial-NoDerivatives 4.0 International/Imenovanje-Nekomercijalno-Bez prerada 4.0 međunarodna](#)

Download date / Datum preuzimanja: **2025-03-04**



Repository / Repozitorij:

[Repository of the University of Rijeka, Faculty of Medicine - FMRI Repository](#)



Available online at www.sciencedirect.com

ScienceDirect

journal homepage: www.elsevier.com/locate/radcr

Case Report

Ventrolateral disc herniation causes psoas muscle compression: A case report

Tomislav Pavlović, MD^{a,b,*}, Krunoslav Štefančić^b, Marjan Rožanković, MD, PhD^c,
Luka Boban, MD^d, Igor Borić, MD, PhD^{b,e,f}, Vilim Molnar, MD^d, Paulo Zekan, MD^d,
Dragan Primorac, MD, PhD^{a,b,e,f,g,h,i,j,k}

^a Josip Juraj Strossmayer University of Osijek, Faculty of Medicine, Osijek, Croatia

^b Specialty Hospital St. Catherine, Zabok, Croatia

^c University Hospital Center Zagreb, Department of Neurosurgery, Zagreb, Croatia

^d School of Medicine, University of Zagreb, Zagreb, Croatia

^e School of Medicine, University of Split, Split, Croatia

^f School of Medicine, University of Rijeka, Rijeka, Croatia

^g Srebrnjak Children's Hospital, Zagreb, Croatia

^h Eberly College of Science, The Pennsylvania State University, University Park, State College, PA, USA

ⁱ The Henry C. Lee College of Criminal Justice and Forensic Sciences, University of New Haven, CT, USA

^j Regiomed Kliniken, Coburg, Germany

^k Josip Juraj Strossmayer University of Osijek, Faculty of Dental Medicine and Health, Osijek, Croatia

ARTICLE INFO

Article history:

Received 12 August 2019

Revised 19 October 2019

Accepted 26 October 2019

Available online 27 November 2019

Keywords:

Magnetic resonance imaging (MRI)

Lateral disc herniation

Psoas myoedema

Spine

ABSTRACT

We report a case of a 39-year old male patient who presented to us with several months of lower back pain. Following clinical assessment, the patient underwent a magnetic resonance imaging exam, which after using advanced imaging protocols showed a ventrolateral disc herniation toward the psoas muscle. Based upon the findings in the magnetic resonance and the electromyoneurographic examination, the decision was made to treat the patient conservatively. Coronal planes are useful for discerning changes of various origins not usually seen on the sagittal and axial planes. If needed, additional advanced protocol is available for increased specificity and diagnostic accuracy.

© 2019 The Authors. Published by Elsevier Inc. on behalf of University of Washington.

This is an open access article under the CC BY-NC-ND license.

(<http://creativecommons.org/licenses/by-nc-nd/4.0/>)

Acknowledgment: This research did not receive any specific grant from funding agencies in the public, commercial, or not-for-profit sectors.

Conflict of interests: The authors declare that they have no conflict of interest.

* Corresponding author.

E-mail address: tomislav.pavlovic@svkatarina.hr (T. Pavlović).

<https://doi.org/10.1016/j.radcr.2019.10.031>

1930-0433/© 2019 The Authors. Published by Elsevier Inc. on behalf of University of Washington. This is an open access article under the CC BY-NC-ND license. (<http://creativecommons.org/licenses/by-nc-nd/4.0/>)

Introduction

Lower back pain (LBP) is a nonspecific symptom which is experienced globally by almost every person at least once during their lifetime [1]. Unfortunately, in the vast majority experiencing LBP, the actual source remains unknown with the condition being termed nonspecific LBP [2]. The potential causes of LBP include pathologies of the bone and muscle but also adjacent structures like zygapophyseal joints and intervertebral (IV) disc. Discrepancies in the lumbar IV disc are the most common cause of LBP attributed to a specific cause [3]. Degeneration of the IV disc lead to degenerative disc disease and to potential disc displacement causing symptoms depending on the direction and magnitude of the displacement itself [4].

Case report

Our patient was a 39-year old male who presented to us with pain in the lower back. The patient has previously undergone various examinations at a number of institutions, but they were unable to ascertain the cause of his pain. He reports having pain in the medial plane, with the pain progressing towards the left side, but without radiation to the lower extremities. Following the clinical assessment of the patient's status, no radiculopathy changes were evident. Based upon the findings in the anamnesis and following the clinical examination, the decision was made to proceed with magnetic resonance imaging (MRI). The premise was to possibly visualize the pathology causing the symptoms. No clear range of lateral hernia and edema of the psoas muscle could be defined on standard sagittal T1- and T2-weighted turbo spin echo sequence (TSE) or standard axial (T2 TSE, T1 TSE) planes (Fig. 1). In order to improve the visualisation of the aforementioned

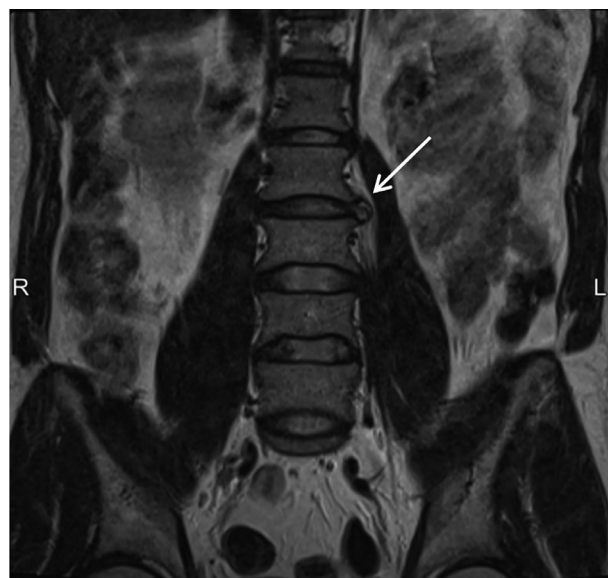


Fig. 2 – The coronal T2-weighted turbo spin echo scan shows significant protrusion of the herniated intervertebral disc at the L2-L3 level towards the left psoas muscle (shown by arrow)

structures, advanced imaging protocols in coronal plane (T2 TSE, T2 TSE FS), in axial plane (T2 space, T2 TSE FS), and sagittal (T2 space) were used. Imaging in the coronal plane (T2-weighted TSE) showed a clear ventrolateral annular disc tear with disc hernia at the L2-L3 level (Fig. 2). The disc hernia was progressing towards the left psoas muscle (Fig. 3). Hyperintense signal in between the muscle fibers was shown on the T2 TSE FS scan which was indicative of intramuscular edema of the left psoas (Fig. 4). The edema was associated with compression of the muscle by the IV disc hernia. Fol-

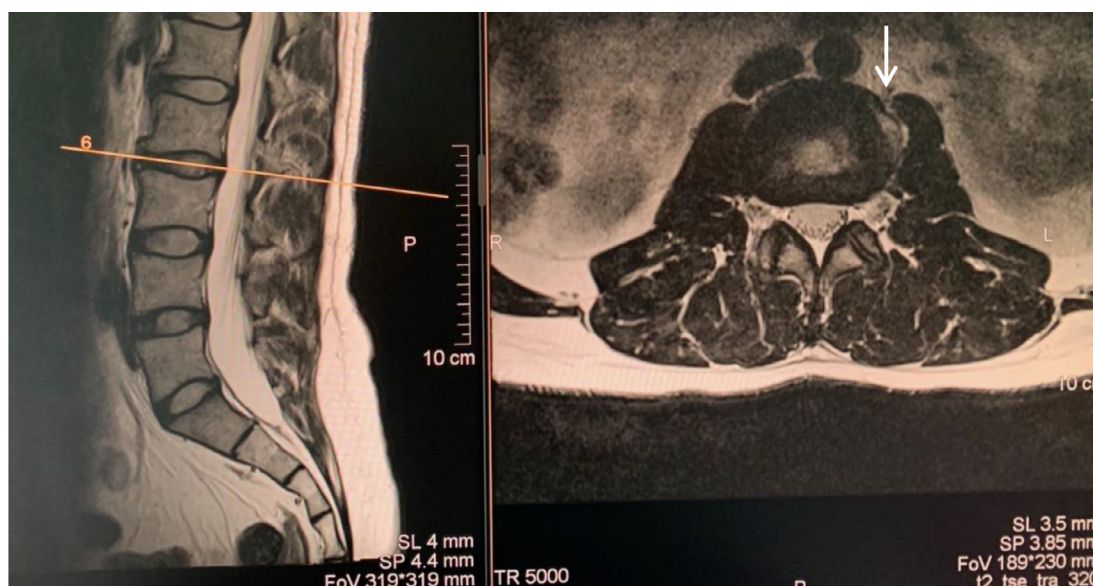


Fig. 1 – Standard (a) sagittal and (b) axial T2-weighted turbo spin echo sequence at the level L2-L3 of the lateral protrusion (shown by arrow)

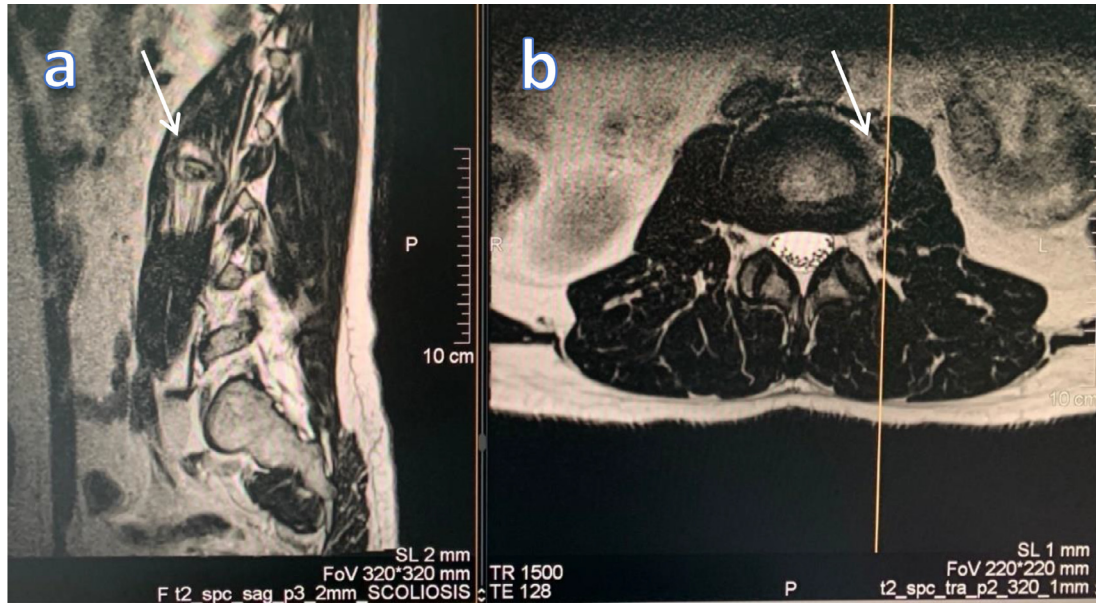


Fig. 3 – (a) sagittal and (b) axial T2-weighted space sequence shows lateral disc hernia at the L2-L3 level progressing towards the left psoas muscle (shown by arrow)

Following the MRI examination, the patient underwent an electromyoneurographic examination. A rare intermediate innervation pattern with widened polyphasic individual potentials, higher amplitudes, and multiple fibrillation at rest was found in the left m. vastus lateralis and tibialis anterior. A similar finding was attributed to the right m. tibialis anterior and to both left and right m. extensor digitorum brevis. For both gastrocnemius and flexor hallucis musculi as well as the right m. vastus medialis and lateralis normal findings were reported. In conclusion, active intermediate neurogenic changes at the L3-L4 levels left as well as minimal bilateral changes

at the L5 level with a left-sided predominance indicative of radiculopathy changes at the L3-L5 levels were reported. Based upon clinical assessment as well as the findings of the MRI and electromyoneurographic examinations, no criteria were met for surgical treatment and the patient was to be treated conservatively. A corticosteroid injection was applied intravenously for inflammation management. The patient was advised to rest until the withdrawal of acute symptoms. Afterwards, he was prescribed physical therapy alongside oral nonsteroidal anti-inflammatory drugs and benzodiazepine for pain management. At six months follow-up, the patient re-

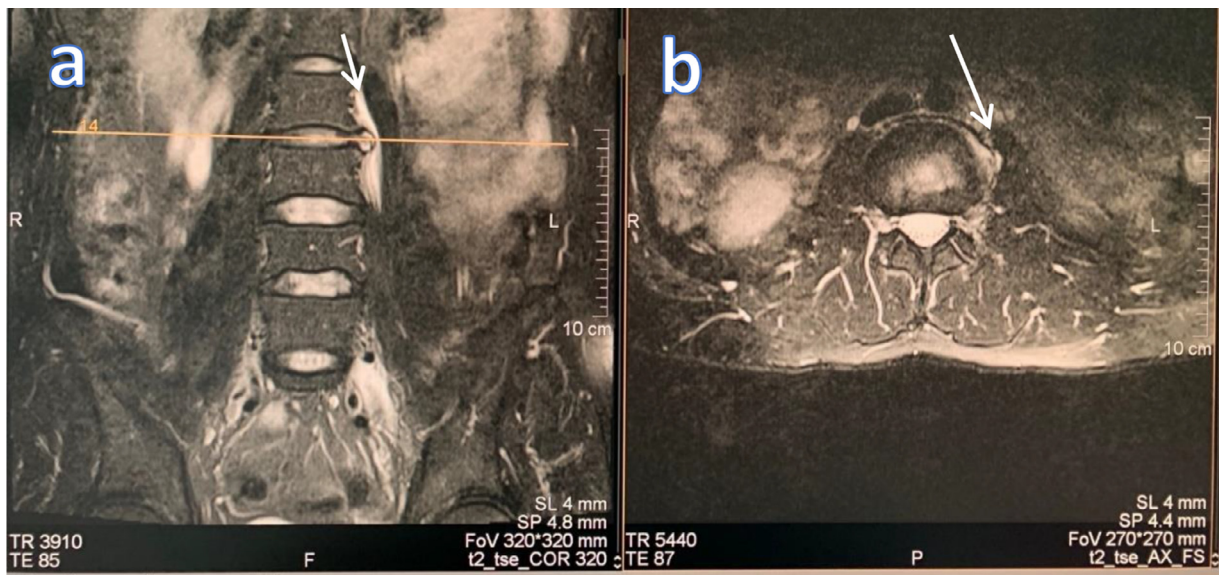


Fig. 4 – T2 turbo spin echo with fat saturation scan in the sagittal and axial plane shows intramuscular edema of the left psoas caused by compression through the herniated material at the L2-L3 level (shown by arrow)

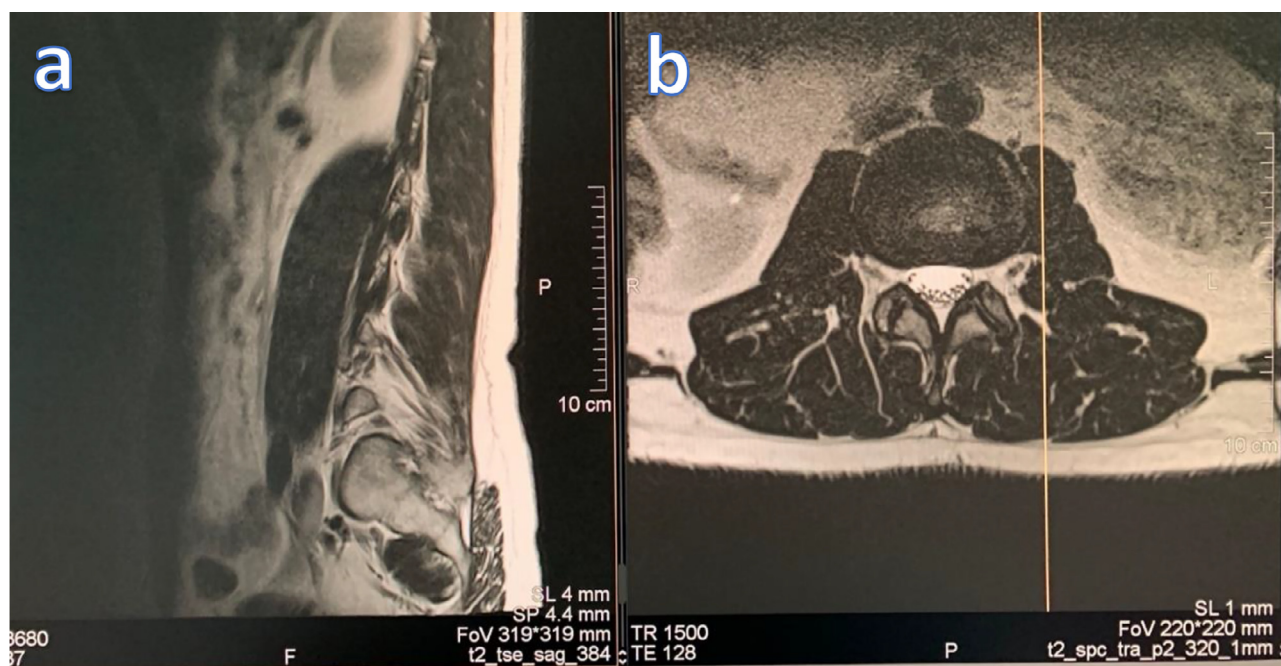


Fig. 5 – The six months follow-up MRI (a) T2-weighted TSE in the sagittal plane and (b) T2-weighted space scan in the axial plane at the L2-L3 level shows significant reduction of the protrusion of the hernia

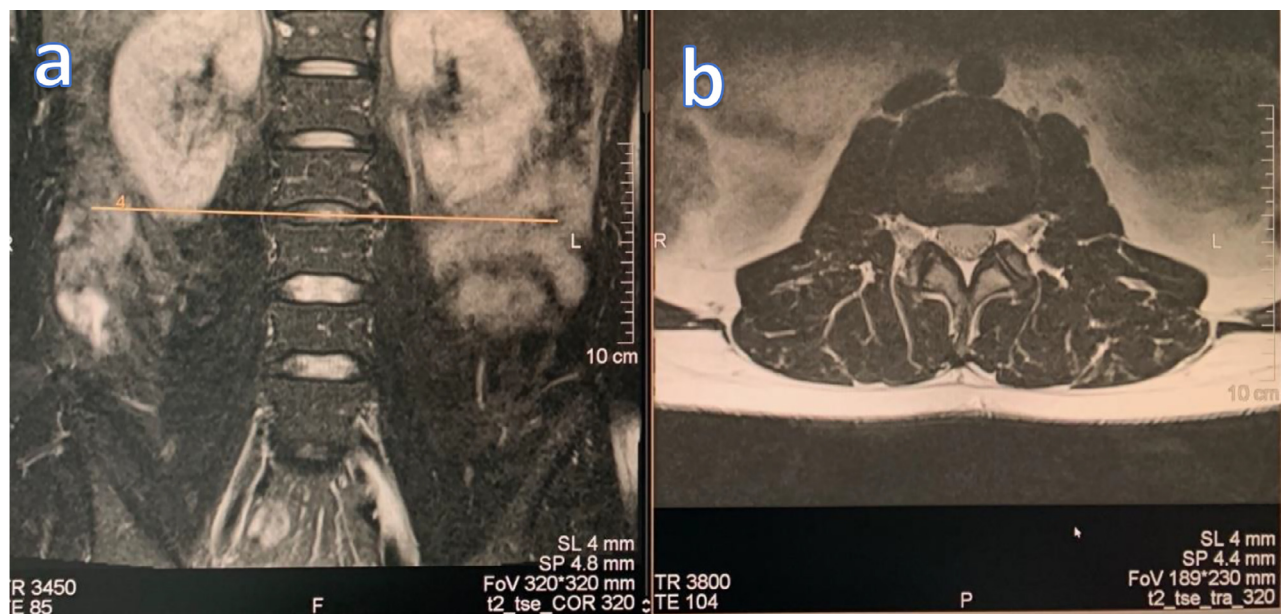


Fig. 6 – The six months follow-up MRI (a) T2 turbo spin echo with fat saturation scan in the coronal and (b) axial plane at the L2-L3 level shows significant reduction of the protrusion and organisation of the hernia, intramuscular edema has withdrawn

ported improved general well-being, substantial reduction in painful sensations, and a gradual return to normal everyday activities. The MRI performed at this point showed a significant decrease in the amount of herniated material as well as normal signal in the area of the psoas muscle (Fig. 5 and Fig. 6). With additional physical therapy, full recovery and return to normal activities is expected.

Discussion

IV disc is made out of an fibrous outer layer named annulus fibrosus and a central liquidus substance called nucleus pulposus. With age, the structure of the disc begins to change in a degenerative fashion which is mostly attributed to the change

in the amount and structure of proteoglycans included in the structure of the IV disc itself [5]. In the case presented, these changes lead to a separation in the annular fibers which is termed annular tear or fissure and to the displacement of disc material beyond the IV disc space [4]. The displaced disc usually compresses the root of the spinal nerve at the corresponding level which in turn causes paresthesias and radicular pain along the distribution of the nerve originating from the compressed roots. As is presented in the case, structures in close proximity to the spine can also be affected and be the source of nociceptive sensations along with area-specific symptoms (reflex deficits, autonomic dysfunctions). Symptoms most often begin to occur around the age of 40 and are most common in the cervical and lumbar region [6]. After clinical evaluation, radiologic imaging is performed in order to localise and better define the pathology. Conventional radiographs have limited use in discerning discal abnormalities as they only visualise osseal structures [3]. MRI serves as the golden standard in discerning pathologies of the IV disc and the space it resides [7]. However, as shown in the case, standard planes used for imaging can sometimes be inconspicuous and the need arises for additional advanced imaging planes in order to visualise the potential abnormality causing the symptoms. Although the area of intramuscular abnormality is much greater than the mass effect of the hernia, the absence of involving the IV disc and adjacent vertebrae, as well as withdrawal of symptoms without antibiotic therapy, suggest that the mass effect is the cause of edema. The majority of patients can be treated using nonoperative methods. Physical therapy remains at the center of conservative treatment [8]. Corticosteroid injections can be used in the acute phase for reducing pain and inflammation [9]. Antidolorozum medication like nonsteroidal anti-inflammatory drugs, benzodiazepines, and opioids can be used for long-term pain management depending on the severity of the pain [10]. If conservative methods fail to produce the desired effect, the patient should undergo operative treatment with minimally invasive procedures being the contemporary golden standard [11].

Conclusion

When dealing with LBP of unknown origin, we recommend doing at least one coronal plane followed by advanced imaging protocols if needed. Coronal MRI plane is useful technique in

the evaluation of the lateral disc herniations in the patients without established intraspinal pathologies.

REFERENCES

- [1] Kamper SJ, Williams CM. Musculoskeletal pain in children and adolescents: a way forward. *J Orthop Sport Phys Ther* 2017;47(10):702–4.
- [2] Hartvigsen J, Hancock MJ, Kongsted A, Louw Q, Ferreira ML, Genevay S, et al. What low back pain is and why we need to pay attention. *Lancet* 2018;391(10137):2356–67.
- [3] Amin RM, Andrade NS, Neuman BJ. Lumbar disc herniation. *Curr Rev Musculoskelet Med*. 2017;10(4):507–16.
- [4] Suthar P, Patel R, Mehta C, Patel N. MRI evaluation of lumbar disc degenerative disease. *J Clin Diagnostic Res*. 2015;9(4):TC04–9.
- [5] Adams MA, Roughley PJ. What is intervertebral disc degeneration, and what causes it? *Spine* 2006;31(18):2151–61.
- [6] Hoy D, Bain C, Williams G, March L, Brooks P, Blyth F, et al. A systematic review of the global prevalence of low back pain. *Arthritis Rheum* 2012;64(6):2028–37.
- [7] Kreiner DS, Hwang SW, Easa JE, Resnick DK, Baisden JL, Bess S, et al. An evidence-based clinical guideline for the diagnosis and treatment of lumbar disc herniation with radiculopathy. *Spine J* 2014;14(1):180–91.
- [8] Jewell DV, Riddle DL. Interventions that increase or decrease the likelihood of a meaningful improvement in physical health in patients with sciatica. *Phys Ther* 2005;85(11):1139–50.
- [9] Kepes ER, Duncalf D. Treatment of backache with spinal injections of local anesthetics, spinal and systemic steroids. *A review Pain*. 1985;22(1):33–47.
- [10] Chen KY, Shaparin N, Gritsenko K. Low back pain. *Pain medicine: an essential review*; 2017.
- [11] Benzakour T., Igoumenou V., Mavrogenis A.F., Benzakour A. Current concepts for lumbar disc herniation *Int Orthop* 2019;43(4):841–851.