

NEFROPATIJA POVEZANA S VARFARINOM - PRIKAZ BOLESNIKA NA TEMELJU BIOPSIJE BUBREGA I PREGLED LITERATURE

Mikolašević, Ivana; Rački, Sanjin; Pavletić Peršić, Martina; Đorđević, Gordana; Mavrincac, Vojko; Orlić, Lidija

Source / Izvornik: **Acta medica Croatica : Časopis Akademije medicinskih znanosti Hrvatske, 2016, 70, 76 - 80**

Journal article, Published version

Rad u časopisu, Objavljena verzija rada (izdavačev PDF)

Permanent link / Trajna poveznica: <https://um.nsk.hr/um:nbn:hr:184:279249>

Rights / Prava: [Attribution-NonCommercial-NoDerivatives 4.0 International/Imenovanje-Nekomercijalno-Bez prerada 4.0 međunarodna](#)

Download date / Datum preuzimanja: **2024-07-14**



Repository / Repozitorij:

[Repository of the University of Rijeka, Faculty of Medicine - FMRI Repository](#)



WARFARIN-RELATED NEPHROPATHY – A CASE REPORT ON RENAL BIOPSY AND REVIEW OF THE LITERATURE

IVANA MIKOLAŠEVIĆ, SANJIN RAČKI, MARTINA PAVLETIĆ PERŠIĆ, GORDANA ĐORĐEVIĆ¹,
VOJKO MAVRINAC² and LIDIJA ORLIĆ

*Rijeka University Hospital Center, Clinical Department of Nephrology, Dialysis and Kidney Transplantation,
¹University of Rijeka, School of Medicine, Department of Pathology and Rijeka University Hospital Center,
²Clinical Department of Gastroenterology, Rijeka, Croatia*

Warfarin-related nephropathy (WRN) is a recently recognized condition in patients with chronic kidney disease (CKD). WRN is clinically detected as an episode of unexplained acute kidney injury (AKI). It is defined as a serum creatinine (sCR) increase >0.3 mg/dL (26.5 μ mol/L) within one week of an international normalized ratio (INR) measurement >3.0 in a patient treated with warfarin without clinical evidence of hemorrhage. Therefore, warfarin therapy can result in AKI by causing glomerular hemorrhage and renal tubular obstruction by red blood cell casts. WRN appears to accelerate the rate of CKD progression and increase the risk of death in susceptible patients. We report on renal biopsy in a patient on warfarin therapy with unexplained AKI and hematuria associated with increased INR. We would like to stress the necessity of an interdisciplinary approach to patients on warfarin therapy.

Key words: warfarin-related nephropathy, acute kidney injury, chronic kidney disease

Address for correspondence: Ivana Mikolašević, MD, PhD
Clinical Department of Nephrology, Dialysis and Kidney Transplantation
Rijeka University Hospital Center
HR-51000 Rijeka, Croatia
E-mail: ivana.mikolasevic@gmail.com

INTRODUCTION

Since its approval in the 1950s, warfarin has become the most commonly prescribed oral anticoagulant which interrupts the synthesis of coagulation factors (II, VII, IX, and X) by inhibiting the C1 subunit of the vitamin K epoxide reductase enzyme complex⁽¹⁾. Warfarin is metabolized and removed primarily in the liver through the cytochrome P450 pathway, which may be affected by a number of medications and dietary factors. Although it is an effective medication, its use is potentially complicated by supratherapeutic anticoagulation. It is strongly protein bound, mainly to albumin. Warfarin use requires close monitoring and hemorrhage is the main complication of its use⁽²⁾.

Patients with chronic kidney disease (CKD) are at an increased risk of thromboembolic events. However, the use of anticoagulation in this population of patients remains a clinical challenge to the treating physician. This is mainly due to the fact that CKD patients have an increased risk of over-anticoagulation as they spend less time in the therapeutic range. Therefore, CKD patients require frequent dose adjustments and have a higher bleeding risk⁽²⁾. According to a recent study, patients with severe CKD were found to need significantly lower warfarin doses to achieve

therapeutic anticoagulation, and they were often over-anticoagulated⁽³⁾.

A new entity has been recently described by Brodsky et al. in patients with CKD, named warfarin-related nephropathy (WRN). According to them, WRN is clinically detected as an episode of unexplained acute kidney injury (AKI) defined as a serum creatinine (sCR) increase >0.3 mg/dL (26.5 μ mol/L) within one week of an international normalized ratio (INR) measurement >3.0 in a patient being treated with warfarin without clinical evidence of hemorrhage. Therefore, warfarin therapy can result in AKI by causing glomerular hemorrhage and renal tubular obstruction by red blood cell (RBC) casts. WRN appears to accelerate the rate of CKD progression and increase the risk of death in susceptible patients. WRN was initially described in CKD patients, but although less frequently, it can develop in non-CKD patients on warfarin therapy as well^(1,4).

Hereby, we report on renal biopsy in a patient on warfarin therapy with unexplained AKI and hematuria associated with increased INR. We would like to stress the necessity of an interdisciplinary approach to patients on warfarin therapy, as well as many other conditions (such as celiac disease, hepatopulmonary and hepatorenal syndrome in patients with liver cirrhosis, nonalcoholic fatty liver dis-

ease, scleroderma, etc.) in order to prevent the consequences of this recently described entity.

CASE REPORT

A 46-year-old woman with a 5-year history of diabetes mellitus type 2 presented to our department of nephrology with acute renal failure (ARF) and a 1-year history of gross hematuria. During the past year, urologic and nephrologic diagnostic tests were unfruitful in finding the cause of hematuria. Urologic studies included abdominal ultrasound, cystoscopy and magnetic resonance urography. On admission, the INR was 4.45 IU. Warfarin had been instituted 8 years before because of mechanical heart-valve replacement. Other medications consisted of carvedilol, 6.25 mg twice daily; ramipril, 2.5 mg daily; and aspirin, 100 mg daily. Her history included pulmonary embolism in 1996 and CKD. Her family history was unremarkable.

At presentation, blood pressure was 180/110 mm Hg and pulse 90 beats per minute. She was afebrile and appeared comfortable. Physical examination was uneventful. Serum creatinine (SCR) level was 304 $\mu\text{mol/L}$. One month before, it was 130 $\mu\text{mol/L}$. Urinalysis results showed gross hematuria and 24-hour urinary protein level was 800 mg. Serology results including antinuclear antibody (ANA), anti-neutrophil cytoplasmic antibody (ANCA) and paraprotein were negative. Serum complement C3 and C4, as well as immunoglobulin levels were within the normal limits. Blood and urine cultures were negative. Chest x-ray showed no abnormalities, while renal ultrasound scan showed 2 normal-sized kidneys without evidence of obstruction. Symptomatic therapy without dialysis treatment consisted of parenteral hydration (crystalloid solutions) and correction of her coagulopathy (vitamin K and low-molecular weight heparin). After this initial therapy, warfarin therapy was continued and a few days later she experienced gross hematuria again, with an INR of 4.03 I.U. Renal biopsy was performed when the INR was normalized with vitamin K and low-molecular-weight heparin.

Morphologically, light microscopy revealed renal cortex with a maximum of 12 glomeruli, 5 of which were globally sclerosed. The viable glomeruli showed varying degrees of mesangial expansion accompanied by segmental thickening of peripheral capillary loops and segmental sclerosis in 3. In 2 glomeruli, segmental fibrous crescents were seen (Fig. 1). Trichrome-stained sections revealed interstitial fibrosis and tubular atrophy, along with thickening of tubular walls and chronic inflammation in 40%-50% of biopsy specimen. Tubulointerstitial nephritis with infiltration of inflammatory, predominantly mononuclear cells, tubular atrophy, accumulation of foamy histiocytes and widespread interstitial fibrosis was interpreted as a sign of chronic renal injury (Fig. 2). We also could see signs of acute inflammation with

focuses of tubulitis accompanied with eosinophils. Numerous occlusive RBC casts predominantly in the distal tubules were seen. Moderate thickening of the walls of the arterioles and of the small and medium-sized arteries with proliferation of elastica was noted. Electron microscopy showed thickened capillary loops and nodular mesangial expansion due to marked increase in mesangial matrix, and sclerosis. We could not confirm immune type dense deposits (Fig. 3). Although we could not confirm immune mediated glomerular injury, the differential diagnosis of possible superimposed postinfectious glomerulonephritis was made.

Figure 1

Glomeruli show excessive mesangial expansion due to matrix multiplication (asterisk), segmental sclerosis (triangle) and segmental fibrocellular crescent (arrow). Between two glomeruli there is fibrosis and tubular atrophy (PAS, X200).

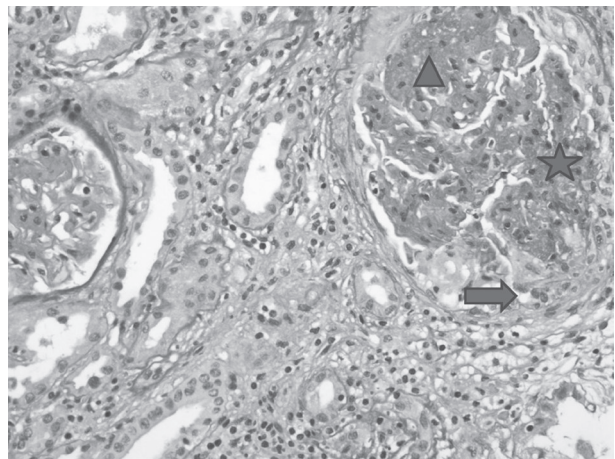


Figure 2

Tubulointerstitial nephritis with heavy infiltration of predominantly mononuclear cells, tubulitis (arrow). Tubular atrophy and fibrosis could be a consequence of underlying diabetic nephropathy (PAS, X100).

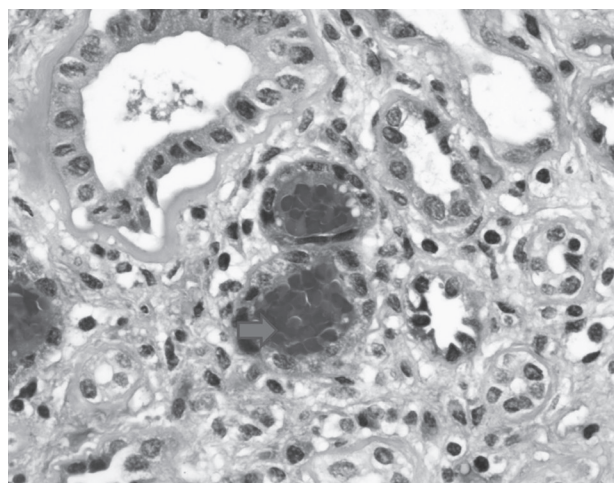
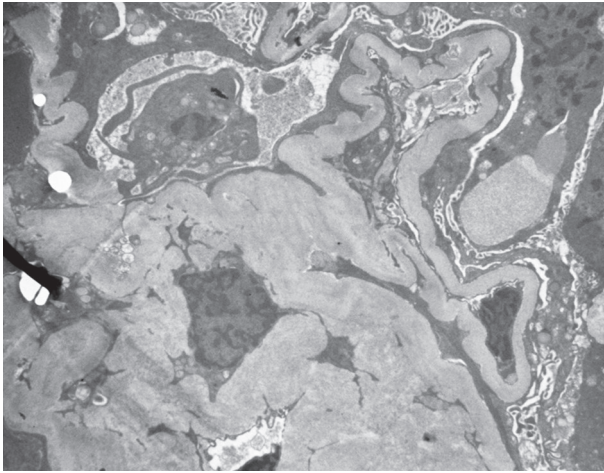


Figure 3

There were no dense immune deposits. Thickened capillary loops and nodular mesangial expansion may be seen in diabetic glomerulosclerosis.



Because of the renal function worsening (sCR 807 $\mu\text{mol/L}$; BUN 22.1 mmol/L) twenty days after admission to the hospital, a central venous catheter was placed through the right internal jugular vein. Hemodialysis was done by ultrafiltration of 2000 mL. A few hours later, the patient developed chest pain, dyspnea, and hemoptysis. There was no evidence for pulmonary embolism, acute myocardial infarction, or complications of the central venous catheter insertion. She was admitted to the intensive care unit and the next day she died because of cardiorespiratory arrest. Autopsy was not performed upon request of her family. The mean values of serum creatinine and INR during hospital stay are shown in Figure 4.

DISCUSSION

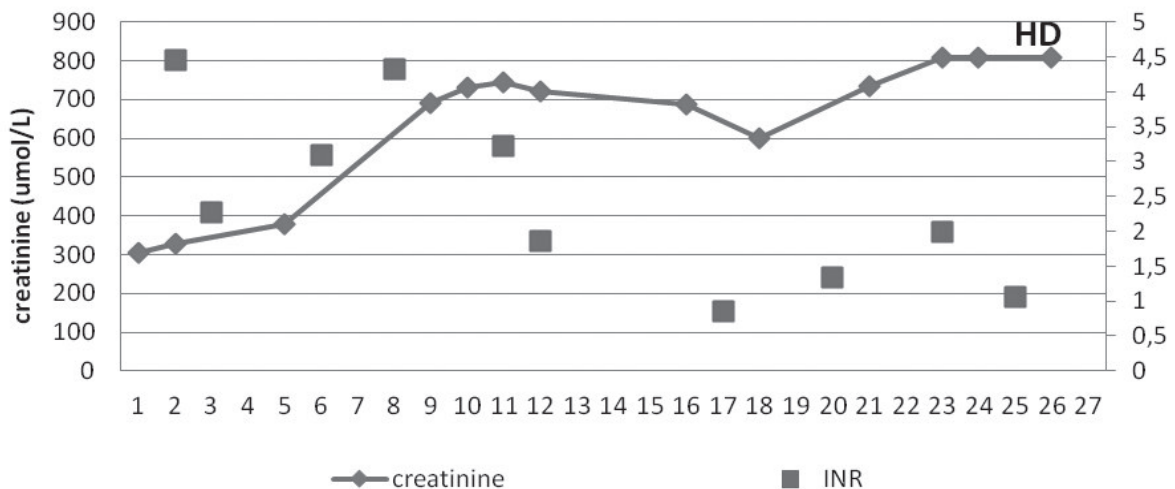
Although the association of hematuria and warfarin use has been reported in the 1960s by Reilly *et al.*, WRN is a relatively new entity described in patients receiving warfarin therapy. The question is why such a common complication of a widely administered medication has been unrecognized until just recently? This can partially be explained by the fact that nephrologists might be reluctant to perform kidney biopsy in patients receiving warfarin, due to the increased risk of hemorrhage.

It is possible that previous undetermined causes of hematuria were due to WRN. The patient had a 1-year history of gross hematuria that was undetermined after extensive medical investigations by urologist and nephrologist. The first report noting that warfarin can cause AKI and glomerular hematuria was published by Abt *et al.*⁽⁵⁾ in a patient with thin glomerular basement membrane nephropathy. A similar syndrome was reported in 2004 by Kabir *et al.*⁽⁶⁾ in a patient with a history of inactive lupus erythematosus (SLE), but abnormally thick glomerular basement membrane. The term WRN was first described by Brodsky *et al.*⁽⁷⁾, who performed retrospective analysis of biopsy specimens from 9 patients that presented with unexplained AKI and hematuria while on warfarin therapy. According to Brodsky *et al.*, the main features of WRN are AKI, acute derangement of INR, and histological findings of glomerular hemorrhage and large obstructive RBC casts in tubular lumina. The best evidence thus far comes from two animal studies showing an increase in sCR with increasing INR, reversible on vitamin K administration^(8,9). It is important to note that WRN does not require severe warfarin coagulopathy. The mean value of INR in our patient was 4.0, the same as in previous reports by Brodsky *et al.*^(4,7).

Figure 4

RB = renal biopsy; HD = hemodialysis

Mean values of serum creatinine and INR during hospital stay.



There are other possible mechanisms by which warfarin could promote kidney injury, such as atheroembolism, interstitial nephritis, and direct effects of warfarin on the glomerulus⁽⁴⁾. Furthermore, a recent study reports that WRN is not an uncommon feature of warfarin use, namely, analysis of more than 15,000 warfarin treated patients has shown that WRN affects approximately 33% of CKD patients and 16% of non-CKD patients that experienced an INR >3.05. As mentioned, the proposed diagnostic criteria for WRN include a 0.3 mg/dL (26.5 µmol/L) increase in sCR in patients that had an INR >3 within the previous week. We wonder if this definition is appropriate for patients that require treatment to reach an INR target of 3.0, such as those with mechanical heart valves, like our patient.

Although previously reported cases occurred in a setting of CKD, recent investigations suggest that WRN may also appear, even less frequently, in the general population, with age, hypertension, diabetes mellitus, and cardiovascular disease being significant risk factors¹. The risk factor for WRN is low serum albumin level because approximately 97% of warfarin is bound to plasma protein, primarily albumin, and the other 3% is the unbound fraction that exhibits pharmacological effects. Therefore, it is not surprising that WRN is more frequent in CKD than in non-CKD patients. Namely, due to malnutrition and expansion of plasma volume that results in hypoalbuminemia in CKD patients, they may have a higher incidence of WRN^(1,2). In the setting of impaired renal function as in our patient, it is possible that such dilutional hypoalbuminemia contributed to over-coagulation and consequently to progression of WRN and further kidney damage.

Another important fact that has been described by Brodsky *et al.* is that therapy which tends to increase glomerular hydrostatic pressure is associated with an increased risk of WRN; this is mainly due to concomitant aspirin use⁴. Our patient took aspirin as part of her chronic therapy.

Furthermore, the question is “does WRN occur early in the course of warfarin therapy, as mentioned by Brodsky *et al.*?” The authors asserted that WRN patients tended to be new to warfarin therapy (warfarin started in the previous 3 months). This definition is doubtful considering that long-term warfarin exposure in animal models results in vascular calcification^(1,10). Furthermore, similar chronic complications have been described in humans, such as tissue necrosis and calciphylaxis^(1,10). Our patient received long-stand warfarin therapy.

Another important complication of WRN was observed by Brodsky *et al.* Beyond its influence in terms of accelerated progression of kidney disease, they observed that WRN could also be associated with an increased risk of death, with CKD patients having a twofold greater risk

found in non-CKD patients. According to Brodsky *et al.*, about one million of three million patients in the USA who receive warfarin therapy may have at least one episode of INR greater than 3.0, and about 200 000 patients can develop WRN with an approximate one-year mortality rate of 30%⁽⁴⁾. Our patient had stable long-standing CKD. The occurrence of WRN probably accelerated the progression of kidney disease, which resulted in death, although the accurate reason of death was not defined because autopsy was not performed.

One of the questions is also whether WRN is unique to vitamin K antagonists and therefore what is the potential impact of anticoagulants other than warfarin? For example, what is the impact of direct thrombin inhibitors such as dabigatran and direct factor Xa inhibitors? Dabigatran has a different mechanism of action and metabolism than warfarin, and it can be used without the need of routine monitoring¹. However, it is contraindicated in patients with estimated glomerular filtration rate (eGFR) ≤30 mL/min/1.73 m², while in patients with eGFR 30-50 mL/min/1.73 m² it has to be used with caution. This is due to the fact that it is predominantly metabolized and removed by kidneys, and its use in CKD patients can lead to life-threatening bleeding without the possibility of using a specific antidote for now. A specific antidote, humanized antibody, is in the phase of animal model investigation. Future studies possibly will investigate if this medication can cause similar complications as WRN or we can safely administer it to CKD patients, especially considering dosage in earlier stages of CKD. According to our experience in a small cohort of patients (unpublished data), dabigatran also causes deterioration of renal function in CKD patients.

In conclusion, WFR appears to be a common clinical problem, although it was unrecognized until recently. Warfarin therapy is a special problem in the population of CKD patients, considering that they have an increased risk of over-anticoagulation and are less in the therapeutic range. Therefore, these patients require frequent dose adjustments. According to current investigations, the pathogenesis of WRN has not yet been properly determined, considering that warfarin is a widely used medication. However, without understanding the pathogenic pathways of the disease, it will be difficult to develop strategies for its prevention and treatment. Further prospective, multicenter studies are needed to define clinical features and the exact prevalence of WRN, and also to investigate and define the features of susceptible patients.

REFERENCES

1. Rizk DV, Warnock DG. Warfarin-related nephropathy: another newly recognized complication of an old drug. *Kidney Int* 2011; 80: 131-3.

2. Lim AKH. Haematuria and acute kidney injury associated with warfarin anticoagulation. *General Med* 2013; 1: 105.
3. Limidi NA, Beasley TM, Baird MF *et al.* Kidney function influences warfarin responsiveness and hemorrhagic complications. *J Am Soc Nephrol* 2009; 20: 912-21.
4. Brodsky SV, Nadasdy T, Rovin BH *et al.* Warfarin-related nephropathy occurs in patients with and without chronic kidney disease and is associated with an increased mortality rate. *Kidney Int* 2011; 80: 181-9.
5. Abt AB, Carroll LE, Mohler JH. Thin basement membrane disease and acute renal failure secondary to gross hematuria and tubular necrosis. *Am J Kidney Dis* 2000; 35: 533-6.
6. Kabir A, Nadasdy T, Nadasdy G, Hebert LA. An unusual cause of gross hematuria and transient ARF in an SLE patient with warfarin coagulopathy. *Am J Kidney Dis* 2004; 43: 757-60.
7. Brodsky SV, Satoskar A, Chen J *et al.* Acute kidney injury during warfarin therapy associated with obstructive tubular red blood cell casts: a report of 9 cases. *Am J Kidney Dis* 2009; 54: 1121-6.
8. Ozcan A, Ware K, Calomeni E *et al.* 5/6 nephrectomy as a validated rat model mimicking human warfarin-related nephropathy. *Am J Nephrol* 2012; 35: 356-64.
9. Ware K, Brodsky P, Satoskar AA *et al.* Warfarin-related nephropathy modeled by nephron reduction and excessive anticoagulation. *J Am Soc Nephrol* 2011; 22: 1856-62.
10. Banerjee C, Woller SC, Holm JR, Stevens SM, Lahey MJ. Atypical calciphylaxis in a patient receiving warfarin, then resolving with cessation of warfarin and application of hyperbaric oxygen therapy. *Clin Appl Thromb Hemost* 2010; 16: 345-50.

SAŽETAK

NEFROPATIJA POVEZANA S VARFARINOM – PRIKAZ BOLESNIKA NA TEMELJU BIOPSIJE BUBREGA I PREGLED LITERATURE

I. MIKOLAŠEVIĆ, S. RAČKI, M. PAVLETIĆ PERŠIĆ, G. ĐORĐEVIĆ¹, V. MAVRINAC² i L. ORLIĆ

Klinički bolnički centar Rijeka, Klinika za nefrologiju, dijalizu i transplantaciju bubrega,

¹Sveučilište u Rijeci, Medicinski fakultet, Klinika za patologiju i

²Klinički bolnički centar Rijeka, Klinika za gastroenterologiju, Rijeka, Hrvatska

Nefropatija povezana s varfarinom (WRN) je odnedavno prepoznato stanje u bolesnika s kroničnom bolešću bubrega (KBB). WRN je klinički prepoznata kao epizoda neobjašnjivog akutnog oštećenja bubrega (AOB). Definira se kao povećanje kreatinina u serumu (sCR) >0,3 mg/dL (26,5 micromol/L) unutar tjedna INR mjerenja >3,0 u bolesnika liječenog varfarinom bez klinički utvrđenog krvarenja. Zbog toga terapija varfarinom može dovesti do AOB uzrokujući glomerularno krvarenje i opstrukciju bubrežnih tubula odljevnim cilindrima eritrocita. Čini se da WRN ubrzava napredovanje KBB i u osjetljivih bolesnika povećava rizik od smrtnog ishoda. Izvješćujemo o biopsiji bubrega u bolesnika na terapiji varfarinom s neobjašnjivim AOB i hematurijom povezanom s povećanim INR. Namjera nam je naglasiti potrebu interdisciplinarnog pristupa bolesnicima na terapiji varfarinom.

Ključne riječi: nefropatija povezana s varfarinom, akutno oštećenje bubrega, kronična bolest bubrega