

Tumor necrosis factor antagonists in the treatment of pyoderma gangrenosum, acne and suppurative hidradenitis (PASH) syndrome

Saint-Georges, Valentina; Peternel, Sandra; Kaštelan, Marija; Brajac, Ines

Source / Izvornik: **Acta Dermatovenerologica Croatica, 2018, 26, 173 - 178**

Journal article, Published version

Rad u časopisu, Objavljena verzija rada (izdavačev PDF)

Permanent link / Trajna poveznica: <https://urn.nsk.hr/urn:nbn:hr:184:217748>

Rights / Prava: [Attribution-NonCommercial-NoDerivatives 4.0 International/Imenovanje-Nekomercijalno-Bez prerada 4.0 međunarodna](#)

Download date / Datum preuzimanja: **2024-08-31**



Repository / Repozitorij:

[Repository of the University of Rijeka, Faculty of Medicine - FMRI Repository](#)



Tumor Necrosis Factor Antagonists in the Treatment of Pyoderma Gangrenosum, Acne, and Suppurative Hidradenitis (PASH) Syndrome

Valentina Saint-Georges¹, Sandra Peternel^{1,2}, Marija Kaštelan^{1,2},
Ines Brajac^{1,2}

¹Department of Dermatology and Venereology, Clinical Hospital Center Rijeka, Rijeka, Croatia; ²University of Rijeka, Faculty of Medicine, Rijeka, Croatia

Corresponding author:

Assist. Prof. Sandra Peternel, MD, PhD
Department of Dermatology and Venereology
Clinical Hospital Center Rijeka
Krešimirova 42
51000 Rijeka
Croatia
sandra.peternel@medri.uniri.hr

Received: May 8, 2017

Accepted: December 5, 2017

ABSTRACT The clinical triad of pyoderma gangrenosum (PG), acne and suppurative hidradenitis (HS) has been described under the acronym PASH syndrome and is considered to represent a distinct entity in the group of autoinflammatory diseases. It is a fairly new, only recently recognized disorder with a limited number of reported cases and without defined treatment recommendations. We aimed to summarize currently available data on the use of tumor necrosis factor (TNF) antagonists in the management of PASH syndrome and report on our own experience with the use of adalimumab in a patient presenting with this specific constellation of clinical signs and symptoms. Among the 11 cases identified in the literature, infliximab and adalimumab were the most commonly used agents, both exhibiting favorable effects in the majority of, but not all, patients. This was particularly evident in terms of relatively rapid remission of PG whereas HS lesions seemed to be more resistant to treatment. In our patient, adalimumab monotherapy resulted in a remarkable and sustained remission, although significant improvement of HS lesions was observed only from week 16 of therapy onwards. In summary, TNF antagonists are a promising treatment for PASH; however, conclusions regarding the choice of a specific agent, optimal dosing or use in combination with other treatment modalities cannot yet be drawn.

KEY WORDS: acne, adalimumab, etanercept, infliximab, pyoderma gangrenosum, suppurative hidradenitis

INTRODUCTION

Clinically characterized by a triad of pyoderma gangrenosum (PG), acne and hidradenitis suppurativa (HS), PASH is a relatively recently described syndrome placed within the spectrum of autoinflammatory diseases (1,2). Only a limited number of PASH cases has been reported in the literature and there are no well-established treatment modalities for this rare disorder. The impact this syndrome has on the

patient's life is profound and traditional treatment options have not demonstrated significant efficacy in terms of decreasing disease severity nor achieving sustained remission. We herein report a case of a male patient with a typical HS, new-onset of PG and previous history of remittent severe acne, in whom adalimumab monotherapy resulted in a remarkable clinical improvement. We also summarize the

available literature data on the use of adalimumab and other tumor necrosis factor (TNF) antagonists in the treatment of PASH.

CASE REPORT

A 41-year-old male Caucasian patient presented with three distinctly different patterns of skin lesions. The axillary vaults, inguinal folds, perianal region and buttocks showcased clusters of chronic abscesses and sinuses draining seropurulent material, with associated scarring (Figure 1, a, b, c). According to the recently established consensus criteria, these features were characteristic for the diagnosis of HS and were further classified as Hurley stage III due to the extensive involvement (3,4). On the lower extremities, there were inflamed, erythematous plaques comprising numerous pinpoint pustules and small punched-out ulcers, indicating a diagnosis of PG (Fig. 1d). On the upper portion of the patient's back, there were multiple open comedones and atrophic scars, consistent with a history of cystic acne throughout puberty (Fig. 1e). The patient first exhibited the signs of PG four years after the initial presentation of HS. His medical history also included a pilonidal sinus surgery 10 years prior to the development of the clinical picture described above.

Histopathology findings of incisional biopsies were consistent with HS and PG. Routine laboratory examinations were within normal reference values aside from an increase in C-reactive protein up to 69.6 mg/L and slight iron-deficiency anemia. Lack of specific symptoms and further laboratory testing ruled out the diagnosis of inflammatory bowel disease and patient denied any symptoms suggestive of arthritis. Cultures taken from leg ulcers, the axillae and the inguinal folds disclosed methicillin-resistant *Staphylococcus aureus*, *Pseudomonas aeruginosa* and *Proteus mirabilis*, respectively, despite multiple previous treatments with systemic antibiotics.

Throughout the 4-year treatment period, various systemic therapies have been used in an attempt to control the disease activity. Initially, treatment with dapsone led to a partial remission, but the patient developed methemoglobinemia. A combination of clindamycin and rifampicin was then used to treat the HS lesions along with relatively high doses of prednisone to treat the PG ulcers, but only modest and temporary improvement was achieved. Subsequently, an immunosuppressive regimen with prednisone and azathioprine resulted in decreased inflammation of HS lesions and partial resolution of PG ulcers into dusky, cribriform, scarring plaques. However, the refractory nature of the disease led to an overall unsatisfactory control, and therefore, adalimumab was introduced into therapy.

In accordance with the treatment scheme used by Miller *et al.* for the treatment of HS (5), we implemented a regime with an induction dose of 160 mg subcutaneously (SC) as 4 injections of 40 mg on Day 0, followed by 80 mg 2 weeks later, and a weekly maintenance dose of 40 mg beginning at week 4. At week 6 of the treatment, the patient presented with multiple pustules on the soles of both feet. A clinical diagnosis of plantar pustulosis was made and the condition was regarded as a side-effect of adalimumab, which was easily controlled with topical corticosteroid therapy. A review of treatment effectiveness was conducted at week 12, when a considerable improvement was evident, but the overall results were still not satisfactory. Even though it has been reported that significant clinical improvement in HS lesions should be expected by week 12 (5), we were prompted to further continue the treatment due to the number of inflammatory lesions still active. At week 16, a significant improvement was noted, with the evolution of HS lesions into scarring. The patient achieved a cumulative response score of 50% from the baseline which was evaluated by the Hidradenitis Suppurativa Clinical Response indicating that a minimum of half of all active HS lesions were suppressed while no new abscesses and draining fistulas have formed (6). Furthermore, the ulcerating lesions on the lower extremities had almost completely receded, leaving residual hyperpigmentation. It should be noted that not only did the patient's clinical picture improve since the introduction of adalimumab, but so did the quality of his life, with initial Dermatology Quality of Life Index (DLQI) score of 13 dropping to 4. This 9-point improvement was much greater than the score change of 4 proposed as minimal clinically important difference of DLQI in inflammatory skin diseases (7). Therefore, even though the treatment did not lead to complete remission of the inflammatory activity, the improvement was substantial enough for the therapy to be continued. Throughout the maintenance period, additional benefit was observed, and at 6 months since the introduction of adalimumab there was only minimal residual erythema and post-inflammatory dyspigmentation (Figure 2). Therapy has continued since the initial dose and the patient did not experience any relapses or side effects throughout the following year.

DISCUSSION

PASH syndrome was first described as an entity by Braun-Falco *et al.* in 2012 and is currently classified as an autoinflammatory disease (1,8). When compared to other recognized or only recently suggested syndromes within the spectrum, such as PAPA (pyogenic

Table 1. Reports of patients with PASH syndrome or related syndromic entities treated with TNF antagonists

Reference	Age, sex	Comorbidities	Treatment	Outcome
Bruzzese (20)	33, M	axial spondyloarthritis	etanercept	no improvement
			infliximab	complete remission
Garzorz <i>et al.</i> (18)	39, F	psoriasis, seronegative arthritis	adalimumab	fairly stable disease control
Hsiao <i>et al.</i> (11)	20, M	iron-deficiency anemia	infliximab (3 doses)	no improvement
			adalimumab (unknown duration)	no improvement
Marzano <i>et al.</i> (2,9)	34, M	bowel bypass surgery for morbid obesity	infliximab (5mg/kg) at weeks 0, 2 and 6 and every 8-12 weeks thereafter	almost complete healing of PG and acne lesions with only mild HS disease activity in the perianal area, partial remission under maintenance schedule
Marzano <i>et al.</i> (9)	45, F	cervicobrachial pain	infliximab (5 mg/kg) at weeks 0, 2 and 6 and every 8-12 weeks thereafter	almost complete healing of PG and acne lesions with only mild HS disease activity in the perianal area, partial remission under maintenance schedule
	43, M	spondyloarthritis, osteitis	infliximab (5mg/kg) at week 0, 2 and 6	remarkable improvement of PG, acne and spondyloarthritis but not of HS lesions
	23, M	Crohn's disease	adalimumab 80 mg at week 0 and 40 mg every 2 weeks thereafter	partial remission with good control of disease activity from week 4 onwards
Moschella (17)	36, F	Crohn's disease	infliximab (5mg/kg) at weeks 0, 2, 6 and 3 infusions every 8 weeks thereafter	significant improvement in both HS and PG lesions; remission maintained 4 months (at least) after discontinuing infliximab
Murphy <i>et al.</i> (16)	26, F	ulcerative colitis	cyclosporine (250 mg 2x/day) + prednisolone (20 mg/day) + 2 doses of infliximab (5mg/kg)	rapid improvement of skin lesions; treatment stopped after 2nd dose due to probable drug hypersensitivity
			adalimumab induction dose (160 mg + 80 mg), followed by maintenance dose of 40 mg every 2 weeks	marked improvement within 2 months, maintained remission with additional healing thereafter
Saraceno <i>et al.</i> (19)	50, M	Psoriasis and psoriatic arthritis, arterial hypertension, diabetes mellitus, hypertriglyceridemia, depression	adalimumab (40 mg every other week)	remission of HS and PG lesions after 4 weeks of treatment, maintained effect over the 36 weeks of treatment
Staub <i>et al.</i> (15)	22, F	-	systemic corticosteroids + etanercept for 10 months	no (or only temporary) improvement
			systemic corticosteroids + dapsone + adalimumab for 5 months	no (or only temporary) improvement
			infliximab (5 mg/kg) + dapsone + cyclosporine	complete resolution of ulcerations in 4 months allowing taper of corticosteroids, with mild relapse after temporary cessation of cyclosporine



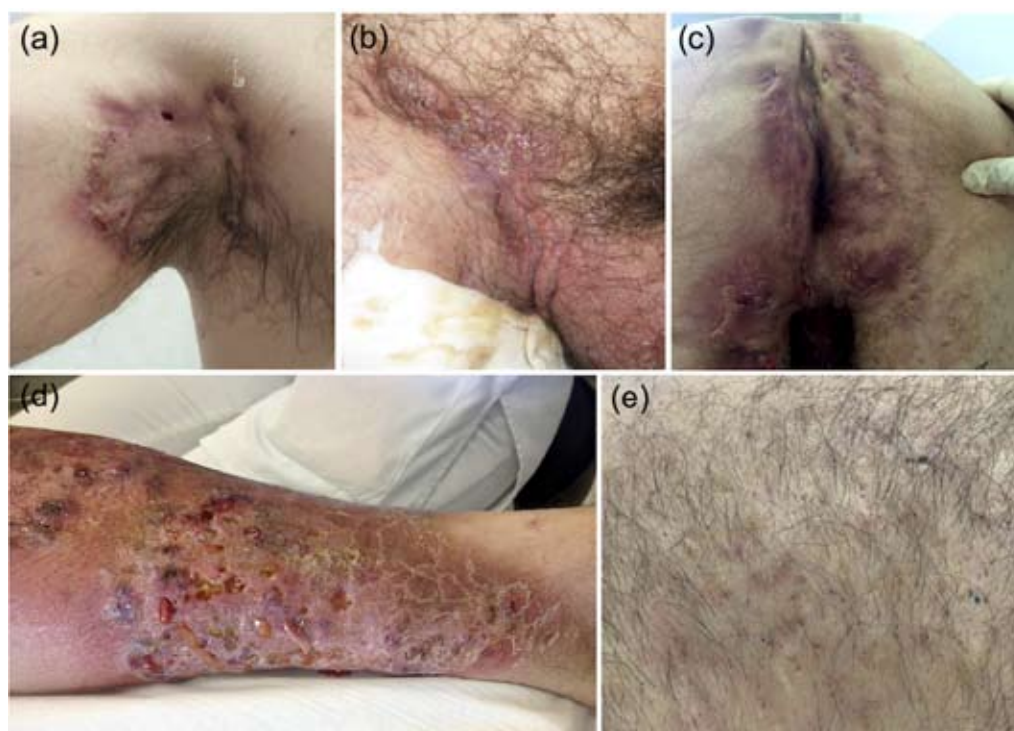


Figure 1. Clinical presentation at baseline. Active HS lesions in (a) the right axilla, (b) the right inguinal, (c) perineal and gluteal regions, (d) PG lesions on the left lower leg comprised of multiple pustules and punched out ulcers and (e) open comedones and depressed scars as sequelae from severe pubertal acne.

arthritis, PG, acne), PAPASH (pyogenic arthritis, PG, acne, HS), PsAPASH (psoriatic arthritis, PG, acne, HS) and PASS (PG, acne, HS and seronegative spondyloarthritis), PASH sets itself apart by showing strong affinity towards the skin, while lacking the presence of arthritis, one of the hallmark features of all aforementioned entities (1,8). While mutations in the gene encoding the proline-serine-threonine-phosphatase-interacting protein 1 (PSTPIP1) have been found specifically in PAPA and PAPASH patients, PASH patients can have a wide array of genetic alterations typically occurring in different autoinflammatory diseases (1,8,9). Suggested pathophysiology common to this whole group of diseases includes hyperactivated innate inflammatory response with increased interleukin-1 beta and TNF-alpha signaling, as well as consequent recruitment and activation of neutrophils (9,10).

Even though we did not perform genetic testing in our patient, PASH syndrome was diagnosed based on distinct constellation of clinical findings. It is interesting to note that Hsiao *et al.* have determined a consistent temporal relationship of PG occurring after the onset of HS (11). The authors suggested that PG is a cutaneous late-onset manifestation of the same underlying inflammatory process that was initially responsible for triggering HS (11). Their hypothesis is

further supported by findings in our patient, since he disclosed a 10-year history of HS, but a only 4 years of PG prior to the first admission to our Department.

One of the traditional therapeutic options for both HS and PG is dapsone because of its power to suppress neutrophil recruitment (12,13). However, development of methemoglobinemia oftentimes limits its use, as was the case in our patient. Currently, corticosteroids and cyclosporine are considered excellent choices for the initial therapy of PG due to the rapid onset of action, which could be followed by dapsone, azathioprine, mycophenolate mofetil and oral tacrolimus (13). Recently, the often observed therapeutic failures of traditional systemic drugs explain the shift towards biologics, so that there are even suggestions that this group of drugs should be considered as the first line of treatment for PG (5,13,14). Still, even though adalimumab has been recently approved for the treatment of moderate to severe HS, both by the European Commission and the US Food and Drug Administration, the current use of TNF antagonists in the treatment of PG is considered off-label.

When considering biologics for PASH, the most often utilized agents thus far have been either TNF antagonists (summarized in Table 1) or the IL-1 receptor antagonist anakinra (1,2,9,11,15-20). Etanercept was employed in 2 patients and didn't show any effect.

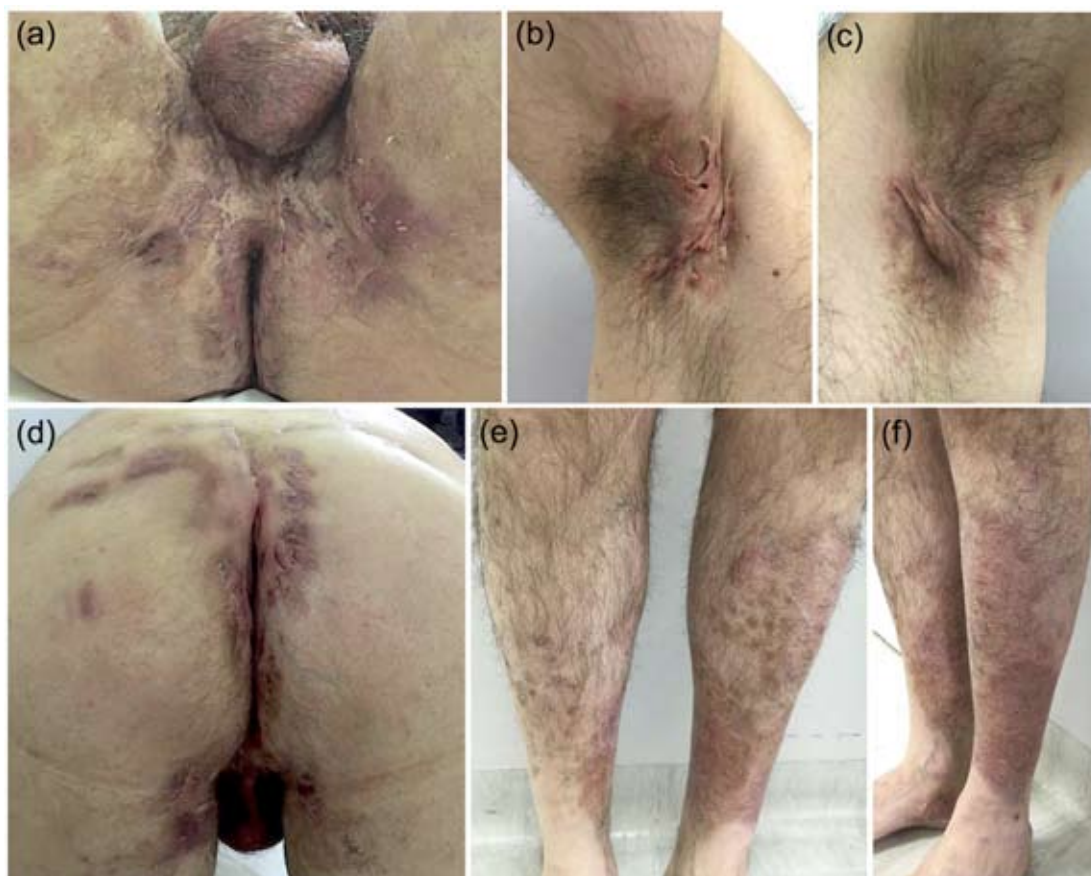

Figure 2. Clinical presentation at 6 months from the beginning of treatment with adalimumab. (a-d) scarring and minimal residual erythema in HS sites and (e, f) complete resolution of PG on the lower legs, with residual postinflammatory dyspigmentation and fine scaling.

Infliximab was used in 8 and adalimumab in 7 cases, including our patient, with comparable success rate. Both drugs showed encouraging results, with adalimumab displaying a slightly more consistent effect regarding remission of HS lesions (Table 1). In our patient, we chose a fully humanized anti-TNF agent due to the lower potential for the development of anti-drug antibodies that could ultimately lead to loss of efficacy, less common adverse effects such as antibody-mediated infusion reactions and the convenience of self-administered SC injections. While implementing the HS treatment scheme provided by Miller *et al.*, our patient did not show the satisfactory control of inflammation in HS lesions by week 12 as was expected (5). However, similarly to the results published by Kimball *et al.* (21), a significant improvement was reached after an additional 4 weeks of treatment, indicating that the treatment should be continued past week 12.

CONCLUSION

The use of TNF antagonists has shown to be a promising treatment for patients with PASH syn-

drome and related syndromic entities. It seems that significant clinical response in HS lesions occurs in a delayed manner and judgment of treatment failure for a given drug should not be made too hastily. However, controlled clinical trials are necessary to adequately evaluate the efficacy of TNF antagonists in patients with this rare syndrome and to allow conclusions regarding the optimal treatment regimens necessary for long-term disease control.

Source of support: Adalimumab was supplied as a donation by AbbVie.

References:

1. Braun-Falco M, Kovnerystyy O, Lohse P, Ruzicka T. Pyoderma gangrenosum, acne, and suppurative hidradenitis (PASH)-a new autoinflammatory syndrome distinct from PAPA syndrome. *J Am Acad Dermatol.* 2012;66:409-15.
2. Marzano AV, Ishak RS, Colombo A, Caroli F, Crosti C. Pyoderma gangrenosum, acne and suppurative hidradenitis syndrome following bowel bypass surgery. *Dermatology.* 2012;225:215-19.

3. Zouboulis CC, Del Marmol V, Mrowietz U, Prens EP, Tzellos T, Jemec GB. Hidradenitis Suppurativa/ Acne Inversa: Criteria for Diagnosis, Severity Assessment, Classification and Disease Evaluation. *Dermatology*. 2015;231:184-90.
4. Lipsker D, Severac F, Freysz M, Sauleau E, Boer J, Emtestam L, *et al.* The ABC of Hidradenitis Suppurativa: A Validated Glossary on how to Name Lesions. *Dermatology*. 2016;232:137-42.
5. Miller I, Lynggaard CD, Lophaven S, Zachariae C, Dufour DN, Jemec GB. A double-blind placebo-controlled randomized trial of adalimumab in the treatment of hidradenitis suppurativa. *Br J Dermatol*. 2011;165:391-8.
6. Kimball AB, Jemec GB, Yang M, Kageleiry A, Signorovitch JE, Okun MM, *et al.* Assessing the validity, responsiveness and meaningfulness of the hidradenitis suppurativa clinical response (HiSCR) as the clinical endpoint for hidradenitis suppurativa treatment. *Br J Dermatol*. 2014;171:1434-42.
7. Basra MK, Salek MS, Camilleri L, Sturkey R, Finlay AY. Determining the minimal clinically important difference and responsiveness of the Dermatology Life Quality Index (DLQI): further data. *Dermatology*. 2015;230:27-33.
8. Marzano AV, Trevisan V, Gattorno M, Ceccherini I, De Simone C, Crosti C. Pyogenic arthritis, pyoderma gangrenosum, acne, and hidradenitis suppurativa (PAPASH): a new autoinflammatory syndrome associated with a novel mutation of the PSTPIP1 gene. *JAMA Dermatol*. 2013;149:762-4.
9. Marzano AV, Ceccherini I, Gattorno M, Fanoni D, Caroli F, Rusmini M, *et al.* Association of pyoderma gangrenosum, acne, and suppurative hidradenitis (PASH) shares genetic and cytokine profiles with other autoinflammatory diseases. *Med Baltimore*. 2014;93:e187.
10. Marzano AV, Borghi A, Meroni PL, Cugno M. Pyoderma gangrenosum and its syndromic forms: Evidence for a link with autoinflammation. *Br J Dermatol*. 2016;175:882-91.
11. Hsiao JL, Antaya RJ, Berger T, Maurer T, Shinkai K, Leslie KS. Hidradenitis suppurativa and concomitant pyoderma gangrenosum: a case series and literature review. *Arch Dermatol*. 2010;146:1265-70.
12. Zouboulis CC, Desai N, Emtestam L, Hunger RE, Ioannides D, Juhász I, *et al.* European S1 guideline for the treatment of hidradenitis suppurativa/acne inversa. *J Eur Acad Dermatol Venerol*. 2015;29:619-44.
13. Patel F, Fitzmaurice S, Duong C, He Y, Fergus J, Raychaudhuri SP, *et al.* Effective strategies for the management of pyoderma gangrenosum: a comprehensive review. *Acta Derm Venereol*. 2015;95:525-31.
14. Agarwal A, Andrews JM. Systemic review: IBD-associated pyoderma gangrenosum in the biologic era, the response to therapy. *Aliment Pharmacol Ther*. 2013;38:563-72.
15. Staub J, Pfannschmidt N, Strohal R, Braun-Falco M, Lohse P, Goerdt S, *et al.* Successful treatment of PASH syndrome with infliximab, cyclosporine and dapsone. *J Eur Acad Dermatol Venerol*. 2015;29:2243-7.
16. Murphy B, Morrison G, Podmore P. Successful use of adalimumab to treat pyoderma gangrenosum, acne and suppurative hidradenitis (PASH syndrome) following colectomy in ulcerative colitis. *Int J Colorectal Dis*. 2015;30:1139-40.
17. Moschella SL. Is there a role for infliximab in the current therapy of hidradenitis suppurativa? A report of three treated cases. *Int J Dermatol*. 2007;46:1287-91.
18. Garzorz N, Papanagiotou V, Atenhan A, Andres C, Eyerich S, Eyerich K, *et al.* Pyoderma gangrenosum, acne, psoriasis, arthritis and suppurative hidradenitis (PAPASH)-syndrome: a new entity within the spectrum of autoinflammatory syndromes? *J Eur Acad Dermatol Venereol*. 2016;30:141-3.
19. Saraceno R, Babino G, Chiricozzi A, Zangrilli A, Chimenti S. PsAPASH: a new syndrome associated with hidradenitis suppurativa with response to tumor necrosis factor inhibition. *J Am Acad Dermatol*. 2015;72:e42-4.
20. Bruzzese V. Pyoderma gangrenosum, acne conglobata, suppurative hidradenitis, and axial spondyloarthritis: efficacy of anti-tumor necrosis factor α therapy. *J Clin Rheumatol*. 2012;18:413-5.
21. Kimball AB, Kerdel F, Adams D, Mrowietz U, Gelfand JM, Gniadecki R, *et al.* Adalimumab for the treatment of moderate to severe hidradenitis suppurativa: a parallel randomized trial. *Ann Intern Med*. 2012;157:846-55.