

Mucormycosis of the Nasal Ala in a Leukemic (M7 AML) Child. Is Surgery of the Nasal Defect Indicated?

Velepič, Marko; Manestar, Dubravko; V Ahel, Vladimir; Linšak, Željko; Malvić, Goran

Source / Izvornik: **Collegium antropologicum, 2012, 36, 535 - 537**

Journal article, Published version

Rad u časopisu, Objavljena verzija rada (izdavačev PDF)

Permanent link / Trajna poveznica: <https://um.nsk.hr/um:nbn:hr:184:986402>

Rights / Prava: [Attribution 3.0 Unported](#)/[Imenovanje 3.0](#)

Download date / Datum preuzimanja: **2024-07-13**



Repository / Repozitorij:

[Repository of the University of Rijeka, Faculty of Medicine - FMRI Repository](#)



Mucormycosis of the Nasal Ala in a Leukemic (M7 AML) Child. Is Surgery of the Nasal Defect Indicated?

Marko Velepčić¹, Dubravko Manestar¹, Vladimir V Ahel², Željko Linšak³ and Goran Malvić¹

¹ University of Rijeka, Rijeka University Hospital Center, Clinic of Otorhinolaryngology, Head and Neck Surgery, Rijeka, Croatia

² University of Rijeka, Rijeka University Hospital Center, Clinic of Maxillofacial and Oral Surgery, Rijeka, Croatia

³ Teaching Institute of Public Health, Rijeka, Croatia

ABSTRACT

Anterior tamponade with Surgicel (oxidized cellulose) was performed on a 5-year-old girl with megakaryoblastic leukemia (M7 AML) and epistaxis. Several days later necrosis of the nasal ala occurred. Debridement was performed and mucormycosis caused by Rhizopus was found in the material. Having cured mucormycosis, a defect of the complete nasal ala remained. The question of a surgical resolution of the disfiguring nasal defect arises.

Key words: child, leukemia, mucormycosis, plastic surgery, quality of life

Introduction

Acute megakaryoblastic leukemia (M7 AML) is a rare subtype of acute myeloid leukemia. It is a highly aggressive disease and the prognosis for patients is poor. Approximately fifty per cent of the patients achieve complete remission with the help of conventional chemotherapy, although only few patients manage to stay alive for more than three years. One of the symptoms of this disease, particularly in the course of its conventional therapy, is disturbed coagulation. It not rarely manifests as epistaxis^{1,2}.

Case Report

Bilateral epistaxis occurred in a five-year-old girl with M7 AML at the end of the induction phase of therapy. A tampon of Surgicel (oxidized cellulose) sufficed to stop the bleeding. Five days later, tamponades were removed from both sides, revealing redness. A few days after that, necrosis of the right nasal ala was noticed. Extensive debridement of the necrosis was performed. Mucormycosis caused by *Rhizopus* was diagnosed by histological and bacteriological analyses of the necrotic tissue.

Having cured the mycotic infection with amphotericin B therapy, a defect of the nasal ala remained: defect of the soft tissues, alar and triangular cartilage, distal part

of the nasal bone and dorsal part of the cartilage of the nasal septum. As a consequence of the defect, scoliosis of the caudal two thirds of the nasal pyramid occurred, as well as sagging of the nasal tip³⁻⁶ (Figure 1 and 2).

With the consent of the parents, it was decided to apply the adhesive silicone prosthesis. A well-adapted prosthesis can be inserted and fixed in the area of the nasal ala defect. The prosthesis imitates the nasal ala, enabling normal breathing through the nose and preventing any further long-term collapse of the nasal tip, as well as scoliosis of the nasal pyramid. Prostheses are changed every three months, one for each season. In that way the colour of prosthesis matches the colour of surrounding skin.

Discussion

We present a child suffering from a malignant disease with poor and maybe even hopeless prognosis. The disease is presently in remission, due to a cytostatic therapy. The general condition of the child is good and she feels healthy. However, six months after curing the mycotic infection, a disfiguring defect of the nasal pyramid remains on her face.

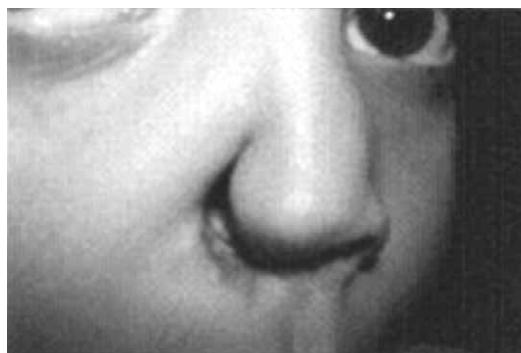

Fig. 1. Defect of the nasal wing in a five-year-old girl with megakaryoblastic leukemia after suffering from nasal mucormycosis.

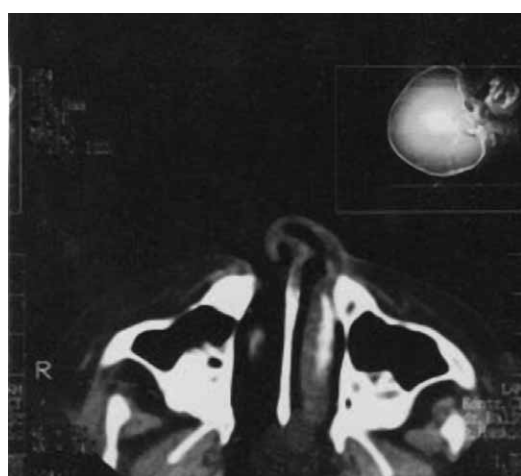


Fig. 2. Computerized tomography showing the defect of the nasal wing and deformation of the nasal pyramid in a five-year-old girl with megakaryoblastic leukemia after suffering from nasal mucormycosis.

In a healthy child such a deformation would beyond doubt be an indication for surgery. However, in case of a child with such a severe disease, the decision to correct the aesthetic problem requires a specific approach. Patient's wishes and her overall state, as well as the parents' opinion must all be taken into account.

REFERENCES

1. GARDET L, LABOPIN M, GORIN NC, POLGE E, BARUCHEL A, MELONI G, ORTEGA J, VOSSSEN J, BUNJES J, LEVERGER G, BLAISE D, FERRANT A, BRUNE M, DORE E, GARNER H, ZINTI F, YANIV I, DINI G, FRASSONI F, Blood, 105 (2005) 405. — 2. DALLY N, HOFFMAN R, HADDAD N, SARIG G, ROWE JM, BRENNER B, Thromb Res, 116 (2005) 109. DOI: 10.1016/j.thromres.2004.11.001. — 3. CHAKRABARTI A, DAS A, SHARMA A, PANDA N, DAS S, GUPTA KL, SAKHUJA V, J Infect, 42 (2001) 261. — 4. WALI YA, AL LAMKI Z, AL KINDI H, TAQ AM, SHAH W, SOLIMAN H, ZACKARIA M, AL OKBI H, Mycoses, 44 (2001) 195. DOI: 10.1046/j.1439-0507.2001.00610.x. — 5. ROUSSEAU A, CORNET M, CARNOT F, BRASNU D, BRUNEVAL P, BADONAL C, Ann Pathol, 25 (2005) 104. DOI: 10.1016/S0242-6498(05)86174-7. — 6. GONZALEZ CE, RINALDI MG, SUGAR AM, Infect Dis Clin North Am, 16 (2002) 895. DOI: 10.1016/S0891-5520(02)00037-5. — 7. LAVIGNE JV, RYAN M, Pediatrics, 63 (1979) 616. — 8. MAGAL-VARDI O, LAOR N, TOREN A,

Our patient is a child who cannot understand the severity and the prognosis of her disease. Due to the characteristics of the disease, such a child is extremely sensitive and attached to her parents. The milieu in which the child lives is mainly the immediate family circle and environment, and thus she is rarely in a situation in which she is subject to the inquisitive looks and merciless criticism of her peers⁷. The question is what, and to what extent, the aesthetic defect means to our patient? What is the relation between her motivation to undergo surgery and the fear of repeated medical interventions and hospitalisation? To what extent would even a very successful surgical correction of the deformity contribute to the child's overall quality of life^{8,9}?

The parents' opinion on this problem should result from their intimate relationship with the child, as well as empathy with her emotions, wishes and anxieties¹⁰. The general condition of the body, compromised with basic morbidity and a permanent cytostatic therapy is also important. Such a condition undoubtedly increases the risk and can have a negative influence on the course and the result of the surgery¹¹.

Therefore, it is necessary to find a compromising solution, which would take into account the complex health state of such a patient and would, to a certain extent, be justified by the aesthetic result. It would be inadvisable to rely on the present condition of the patient and make a premature decision or suggest an algorithm for its solution. It is beyond doubt that in such situations the maximal expectable judgment and solution for each individual patient is most acceptable.

Conclusion

With the application of silicone prosthesis, surgical intervention has been postponed until a later date. The risk and undesired effects, which may be caused by surgery or its unsatisfactory course and results, have been avoided. A simple and satisfactory camouflage of the nasal defect has been achieved, which has facilitated integration of the patient into her environment^{12–14}.

9. STRAUSS L, WOLMER LB, BIELORA I, RECHAVI G, TOREN P, J Nerv Ment Dis, 192 (2004) 872. DOI: 10.1097/01.nmd.0000146881.00129.ec. — 10. FORINDER U, LOF C, WINIARSKI J, Bone Marrow Transplant, 36 (2005) 171. DOI: 10.1038/sj.bmt.1705021. — 11. MELNYK BM, ALPERT-GILLIS L, FEINSTEIN NF, FAIRBANKS E, SCHULTZ-CZARNIAK J, HUST D, SHERMAN L, LEMAINÉ C, MOLDENHAUER Z, SMALL L, BENDER N, SINKIN RA, Pediatrics, 113 (2004) 597. DOI: 10.1542/peds.113.6.e597. — 12. ESPOSITO S, J Chemother, 1 (2001) 12. — 13. LUŠTICA I, VELEPČIĆ M, CVJETKOVIĆ N, BONIFACIĆ M, KIRINČIĆ N, JURETIĆ M, BRAUT Z, Coll Antropol, 25-suppl (2001) 137. — 14. BOUNDARD P, CADRE B, HERMAN D, KRASTINOVA D, SABIN P, Rev Stomatol Chir Maxillofac, 102 (2001) 253. — 15. POLJAK-GUBERINA R, ŽIVKOVIĆ O, MULJAČIĆ A, GUBERINA M, BERNT-ŽIVKOVIĆ T, Coll Antropol, 29 (2010) 603.

D. Manestar

*University of Rijeka, Rijeka University Hospital Center, Department of Otorhinolaryngology, Head and Neck Surgery,
Krešimirova 42, 51000 Rijeka, Croatia
e-mail: dubravko_manestar@net.hr*

**MUKORMIKOZA NOSNOG KRILA KOD DJEVOJČICE S LEUKEMIJOM (M7 AML). DA LI JE
INDICIRANA KIRURŠKA TERAPIJA DEFEKTA NOSA?**

S A Ž E T A K

Djevojčici s megakarioblastičnom leukemijom (M7 AML) i epistaksom, staroj 5 godina, učinjena je prednja tamponada nosa surdicelom. Nekoliko dana kasnije razvila se nekroza nosnog krila. Napravljen je debridman, a u materijalu dijagnosticirana mukormikoza uzrokovana rhizopus-om. Nakon izlječenja mukormikoze ostao je defekt kompletnog nosnog krila. Postavlja se pitanje kirurškog rješavanja nagrdjućeg defekta nosa.