

# Full Thickness Cartilage Palisade Tympanoplasty with Malleus Interposition : A Study of the Long Term Results

---

**Velepič, Marko M.; Manestar, Dubravko; Starčević, Radan; Česnik Velepič, Barbara; Zubović Velepič, Sanja; Linšak, Željko**

*Source / Izvornik:* **Collegium antropologicum, 2014, 38, 283 - 287**

**Journal article, Published version**

**Rad u časopisu, Objavljena verzija rada (izdavačev PDF)**

*Permanent link / Trajna poveznica:* <https://urn.nsk.hr/urn:nbn:hr:184:632174>

*Rights / Prava:* [Attribution 3.0 Unported](#)/[Imenovanje 3.0](#)

*Download date / Datum preuzimanja:* **2024-06-17**



*Repository / Repozitorij:*

[Repository of the University of Rijeka, Faculty of Medicine - FMRI Repository](#)



# Full Thickness Cartilage Palisade Tympanoplasty with Malleus Interposition: A Study of the Long Term Results

Marko M. Velepić<sup>1</sup>, Dubravko Manestar<sup>1</sup>, Radan Starčević<sup>1</sup>, Barbara Česnik Velepić<sup>2</sup>, Sanja Zubović Velepić<sup>3</sup> and Željko Linšak<sup>4</sup>

<sup>1</sup> University of Rijeka, Rijeka University Hospital Center, Clinic of Otorhinolaryngology, Head and Neck Surgery, Rijeka, Croatia

<sup>2</sup> University of Rijeka, Rijeka University Hospital Center, Clinic of Anesthesiology, Rijeka, Croatia

<sup>3</sup> University of Rijeka, Rijeka University Hospital Center, Department of Transfusiology, Rijeka, Croatia

<sup>4</sup> Teaching Institute of Public Health of Primorsko-Goranska County, Rijeka, Croatia

## ABSTRACT

The aim of this retrospective study is to review long term results of full-thickness cartilage palisade tympanoplasty (FTCPT) with malleus head interposition performed on 51 patients (56 ears); 36 women and 15 men (7–73 years, 44 years average). The pathology of ears which encourages this technique of tympanoplasty is presented. On average 12 years after surgery we have elaborated anatomic and functional results. Anatomic results were categorized based on empiric evaluation of the new tympanic membrane status: 40 (71%) tympanic membranes without anatomic irregularities, 14 (25%) with irregularities and 2 (4%) with secondary perforation. Functional results (tonal audiogram) are based on pure tone average air-bone gap (PTA-ABG) at 4 frequencies. Main functional results of 51 ears (51 audiograms performed): pre- and post-operative average PTA-ABGs were  $27.07 \pm 9.98$  and  $10.77 \pm 7.85$  dB ( $t=10.36$ ;  $p<0.001$ ). In the group of ears with a tympanic membrane with no anatomic irregularities, pre- and post-operative average PTA-ABGs were  $27.30 \pm 10.56$  and  $10.82 \pm 8.33$  dB ( $t=8.09$ ;  $p<0.001$ ). In the group of ears with cartilage resorption, pre- and post-operative PTA-ABGs were  $24.92 \pm 8.19$  and  $9.33 \pm 6.58$  dB ( $t=6.21$ ;  $p<0.001$ ). The differences between the two groups are irrelevant. Postoperative PTA-ABG values of ears after first surgery ( $N=34$ ) and revision surgery ( $N=17$ ) was significantly different ( $8.75 \pm 5.75$  and  $15.16 \pm 9.62$  dB) ( $t=2.60$ ;  $p=0.016$ ). In spite of the thickness of the new tympanic membrane, FTCPT is a successful technique for solving advanced ear pathology.

**Key words:** cartilage tympanoplasty, chronic otitis media, ear surgery, ossicular replacement, tympanic membrane reconstruction

## Introduction

Temporal muscle fascia and tragal perichondrium are good autografts for closure of an eardrum defect on an ear with a good tubal function.

In ears with poor tubal function, after a long-term period, atrophy and transplant degeneration often occurs. It could lead to illness relapse. Therefore cartilage is used in tympanoplasty, either for stabilization or reconstruction of the whole eardrum<sup>1–3</sup>.

A number of different methods of cartilage tympanoplasty have been published during the last fifteen years<sup>4–6</sup>.

The aim of this retrospective study is to analyze our long-term anatomic and functional results of full-thickness cartilage palisade tympanoplasty (FTCPT) technique with malleus head interposition<sup>7–10</sup>.

## Patients and Methods

In the five-year period (1997–2002), 74 patients had undergone FTCPT. On average 12 years later (mid 2011), 51 patients (56 operated ears) came forward. At the time

of the operation patients were 44 years old on average (7–73)- 36 women and 15 men.

First surgery was performed on 37 ears (32 patients), and revision surgery was performed on 19 ears (19 patients).

The technique was performed only on ears with an advanced ear pathology. Two to four dominant clinical pathological conditions were present: subtotal or total eardrum defect, adhesive otitis with malleus rotation where umbo touches or even adheres to the promontory, malleus head fixation, resorption of the malleus manubrium or cholesteatoma.

All the ears had preserved stapes superstructure. Malleus was removed from all ears due to the clinical situation and the technique performed.

Retroauricular approach was used in all operations. For eardrum reconstructions conchal cartilages at least 1mm thick were used. We cut them in 2–3 millimeters wide palisades with perichondrium on both sides. In that way bending of the palisades was avoided. Cartilage palisades (5–7) were put in order from anterior to posterior in vertical direction. The anterior ones (1–3) were placed under the bony annulus, and the posterior ones above it. Small pieces of cartilage were put under the anterior 1–2 palisades to support them if it was necessary (architaves).

Those architaves were used in 13 ears. In six ears they were put to support inferior ends of the palisades, in two ears superior ends and in five ears both ends.

As an alternative to the interposition, an autograft of the malleus head was used. It was shaped as an hourglass with a diamond drill, with all the soft tissue removed from it. In that way it could be properly adjusted on the stapes<sup>11</sup>.

A senior surgeon performed all the operations.

On average 11 years after the operation patients were called for the examination.

Otomicroscope was used to evaluate anatomic results and tonal audiogram was used to evaluate functional results.

We set criteria to evaluate anatomic results based on the appearance of the »eardrum« of operated ears:

- A. »normal« eardrum (palisades in place without resorption)
- B. cartilage resorption:
  - a. slight resorption: spindle-shaped resorption between the palisades, palisade ends resorption lesser than one palisade surface;
  - b. extensive resorption: resorption greater than one palisade surface
- C. perforation of the eardrum.

Pure tone average air-bone gap (PTA-ABG) was used at 0.5, 1, 2 and 3 kHz for the functional results analysis.

Anatomic and functional results were separately analyzed for the operated ears. The results were analyzed between groups of ears that were operated for the first

time and ears that were reoperated after previous unsuccessful surgery where a different method had been used.

We compared functional results of the group of ears with a »normal« eardrum and the group of ears with cartilage resorption and eardrum perforation.

All the patients signed informed consent to the work. The study was approved by the Ethical committee of the Rijeka University Hospital Center.

## Results

### Anatomic results

All operated ears

Out of 56 operated ears, »normal« eardrum was found in 40 ears (71%) – cartilage formed the whole eardrum. Cartilage resorption was found in 14 ears (25%). 11 ears had slight, mostly spindle-shaped resorption between the palisades, 2 ears had larger resorption and 1 had extensive resorption with protrusion of the malleus graft. There were two ears with small and dry eardrum perforation (4%).

Comparison of anatomic results after first and revision surgery

In the group of ears after first surgery (N=37) we had 25 (68%) »normal« eardrums, 11 (30%) eardrums with resorption and 1 (1%) perforation.

In the group of ears after revision surgery (N=19) we had 15 (79%) »normal« eardrums, 3 (16%) eardrums with resorption and 1 (5%) perforation.

Further statistical analysis (hypothesis test for proportion) showed that in all ears ( $z=3.550$ ;  $p<0.001$ ), including those that went through the first surgery as well those that underwent revision surgery ( $z=2.283$ ;  $p=0.011$  and  $z=4.512$ ;  $p<0.001$ ), the number of »normal« eardrums was significantly bigger.

### Functional results

Only 51 ears were included in the audiometric assessment (preoperatively 4 ears had no response at 3 kHz and the evaluation of an ear with eardrum perforation was not made due to objective reasons).

All ears ( $n=51$ ) had pre- and post-operative average PTA-ABG  $27.07\pm 9.98$  and  $10.77\pm 7.85$  dB ( $t=10.36$ ;  $p<0.001$ ). The group after first surgery (N=34) had pre- and post-operative average PTA-ABG  $26.19\pm 9.77$  and  $8.75\pm 5.75$  dB ( $t=9.20$ ;  $p<0.001$ ), and the group after revision surgery (N=17) had average PTA-ABG  $28.71\pm 10.35$  and  $1.16\pm 9.62$  dB ( $t=5.08$ ;  $p<0.001$ ) (paired-samples t-test).

For all ears, as well as for both groups, a significant difference between pre- and post-operative average PTA-ABG was established.

Comparison of functional results after first and revision surgery

In further statistical analysis (independent-samples t-test) pre- and post-operative values of average PTA-ABG

of the group after first surgery were compared with those of the group after revision surgery.

Pre-operative values did not differ notably ( $t=0.85$ ;  $p=0.398$ ). Nevertheless, post-operative values of average PTA-ABG of the first surgery group was significantly lower than in the revision surgery group ( $8.57 \pm 5.75$  and  $15.16 \pm 9.62$  dB) ( $t=2.60$ ;  $p=0.016$ ) (Figure 1).

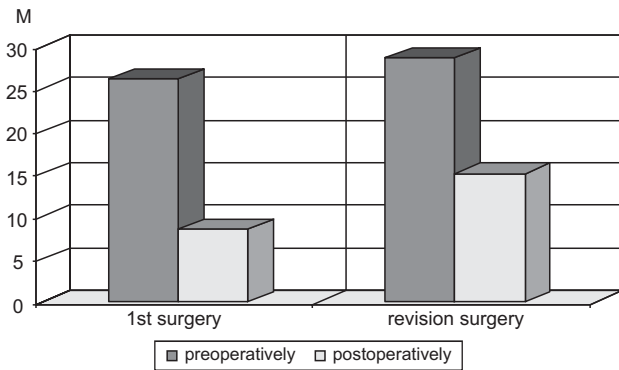


Fig. 1. Comparison of pre- and post-operative Pure Tone Average Air-Bone Gap (PTA-ABG) of the group of ears after first surgery (N=34) and the group after revision surgery (N=17).  $\bar{X}$  – average ABG in dB.

TABLE 1

POSTOPERATIVE HEARING GAIN IN GROUPS: ALL EARS (N=51); FIRST SURGERY (N=34); REVISION SURGERY (N=17)

Air-bone gap (dB)	Number (%) of ears		$\chi^2$	D.F.	p
	Pre-operatively	Post-operatively			
<b>All ears</b>					
0–10	2 (4)	35 (69)	50.57	4	<0.001
11–20	13 (25)	8 (16)			
21–30	18 (35)	7 (14)			
31–40	13 (25)	1 (2)			
≥40	5 (10)	0 (0)			
<b>First surgery</b>					
0–10	2 (6)	26 (76)	41.13	4	<0.001
11–20	9 (26)	7 (21)			
21–30	12 (35)	1 (3)			
31–40	7 (21)	0 (0)			
≥40	4 (12)	0 (0)			
<b>Revision surgery</b>					
0–10	0 (0)	8 (47)	13.00	4	0.011
11–20	3 (18)	3 (18)			
21–30	7 (41)	5 (29)			
31–40	5 (29)	1 (6)			
≥40	2 (12)	0 (0)			

D.F. – Degree of Freedom, p – probability

Hearing gain is shown in Table 1. All ears (N=51), as well as groups after first surgery (n=34) and after revision surgery (N=17) had a considerable hearing improvement. All three groups pre-operatively had a significant majority of ears in the categories 11–20, 21–30, 31–40 and above 40 dB, and post-operatively a majority in the category 0–10 dB (Chi-square test).

Analysis of ABG at different frequencies

Further study included the analysis of ABGs at different frequencies (500, 1000, 2000 and 3000 Hz). A significant difference (paired-samples t-test) between pre- and post-operative values was recorded at all frequencies (Table 2, Figure 2).

TABLE 2  
PREOPERATIVE AND POST-OPERATIVE PURE TONE AVERAGE AIR-BONE GAP (PTA-ABG) OF ALL EARS (N=51) AT FREQUENCIES OF 500, 1000, 2000, 3000 Hz. (PAIRED SAMPLES T-TEST)

		$\bar{X}$	SD	t; p
500 Hz	Pre-operatively	33.01	12.97	t=7.29
	Post-operatively	13.06	13.34	p<0.001
1000 Hz	Pre-operatively	33.22	14.62	t=8.41
	Post-operatively	11.73	10.74	p<0.001
2000 Hz	Pre-operatively	21.14	10.86	t=8.84
	Post-operatively	6.59	7.35	p<0.001
3000 Hz	Pre-operatively	22.76	10.35	t=6.96
	Post-operatively	11.65	8.17	p<0.001

$\bar{X}$  – arithmetic mean; SD – Standard Deviation; t – t-test value; p – probability

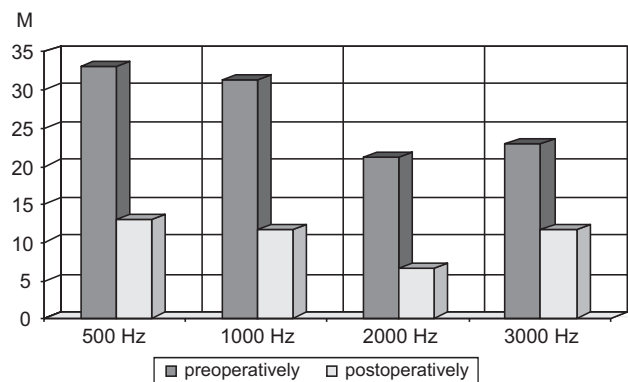


Fig. 2. Comparison of pre- and post-operative Air-Bone Gap (ABG) at different frequencies.  $\bar{X}$  – average ABG in dB.

Additional statistical processing of the obtained values (repeated measures ANOVA by the Bonferroni post-hoc test) showed that ABG at different frequencies significantly differs, both pre-operatively and post-operatively ( $F=20.58$ ;  $p<0.001$  and  $F=9.07$ ;  $p<0.001$ ). The same method showed that the average pre-operative values of

ABG at 500 and at 1000 Hz are considerably higher than at 2000 and 3000 Hz, and post-operatively at 500, 1000 and 3000 Hz considerably higher than at 2000 Hz.

Comparison of functional results between groups with »normal« ears and ears with eardrum resorption

An audiogram was done on 36 ears in the group with »normal« eardrum, and on 14 ears in the group with resorption (4 ears had no hearing at 3 kHz and 2 ears with perforation were excluded from the audiological examination). There is a statistically significant difference between pre- and post-operative values of the average PTA-ABG in both groups, group with »normal« eardrum ( $27.30 \pm 10.56 - 10.82 \pm 8.33$ ) ( $t=8.09$ ;  $p<0.001$ ) and group with resorption ( $24.92 \pm 8.19 - 9.33 \pm 6.58$ ) ( $t=6.21$ ;  $p<0.001$ ) (paired-samples t-test). Pre-operative values of the average PTA-ABG of the group with anatomically regular tympanic membranes and the group with cartilage resorption do not differ greatly ( $27.30 \pm 10.56 - 24.94 \pm 8.19$  dB) ( $t=0.73$ ;  $p=0.471$ ). In the post-operative values of the average PTA-ABG, contrary to the expected, there is also statistically no important difference ( $10.82 \pm 8.33 - 9.33 \pm 6.58$  dB) ( $t=0.58$ ;  $p=0.563$ ) (independent-samples t-test) (Figure 3).

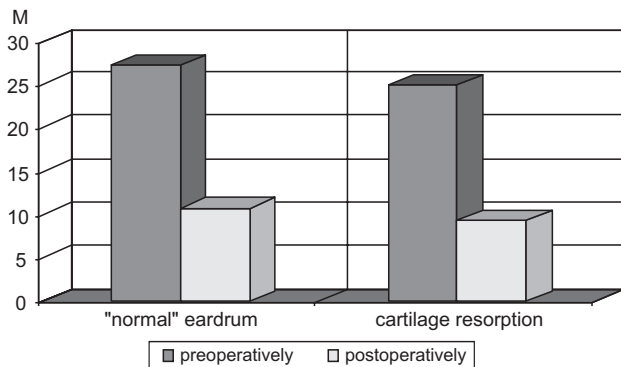


Fig. 3. Comparison of pre- and post-operative values of the Pure Tone Average Air-Bone Gap (PTA-ABG) in the group of ears with tympanic membranes with no irregularities and with tympanic membranes with resorption of cartilage (M – PTA-ABG in dB).

Subjectively, patients from neither group have difficulties. A smaller cartilage resorption should therefore not be considered as a compromising factor in evaluating anatomic results.

**Discussion**

When dealing with advanced ear pathology it is known that cartilage is a stable material in tympanoplasty. It is useful for the reconstruction of the eardrum as well as other structures of the tympanic cavity.

It is more resistant to absorption than all the other grafts. It connects well to the adjacent tissue since it is from mesenchymal origin<sup>12,13</sup>. It successfully resists negative pressure due to its toughness. It is most important in ears with tubal dysfunction<sup>14</sup>. Sound vibrations are transmitted well through it because of its elasticity.

In tympanoplasty cartilage behaves differently than perichondrium or fascia. A surgeon can model it in various ways so it can take different forms, sizes and thicknesses. The perichondrium can be left on one, on both sides or it can be peeled off. The middle ear can be successfully reconstructed with these fragments.

The characteristics of the cartilage give otosurgeons the possibility to create new methods of cartilage tympanoplasty<sup>15</sup>.

Neumann et al. and Yung give a review of a number of different techniques of cartilage tympanoplasty in their works<sup>4,5</sup>.

Different methods of cartilage tympanoplasty have emerged. Therefore, in 2008 Tos presented their proposals for classification. In his work he stresses that for evaluation of any of these methods serious clinical research and comparisons of long-term results between them is necessary<sup>6</sup>.

According to these works, one could expect that different novel methods could yield better results than »classic« FTCPT.

The thickness of the cartilage is the main issue with full thickness palisade tympanic membrane reconstruction. It is presumed that it compromises the transmission of sound vibrations.

Zahnert et al. and Mürbe et al. presented their work regarding the issue. They conclude that the thickness of cartilage for the reconstruction of the eardrum should be maximum 0.5 mm<sup>16,17</sup>.

In spite of this thesis, in 2003 Dornhoffer points out that in his clinical research of a vast number of cartilage tympanoplasties, functional results of tympanoplasties performed with full thickness cartilages were very good. He notes that reconstruction with a full-thickness cartilage is safer<sup>18</sup>.

Finally, Aarnisalo et al. using laser and stroboscopic holography demonstrated that the thickness of the cartilage and its connection to the bony annulus do not affect sound transmission<sup>19,20</sup>.

We believe that only vast clinical researches of long-term anatomic and audiological results of specific operating techniques could give us an acceptable answer. A real evaluation of the efficiency of a certain technique should finally be made according to the effect of both hearing and anatomic results affecting the quality of life of the patient.

**Conclusion**

Based on our own clinical experience, we can say that tympanic membrane reconstruction with full-thickness palisades lined with perichondrium on both sides can be done with precision and exactitude. They adhere together along their full length, which we consider significant for a successful operation on difficult ears. Compact palisades are favorable for the stability of any alternative columella reconstruction, and therefore also for the interpolated homograft of a malleus head.

This retrospective clinical study, motivated by new insights into the mechanics of the middle ear cartilage, is

intended to evaluate FTCPT as a successful surgical technique<sup>18,19</sup>.

## REFERENCES

- BUCKINGHAM RA, *Ann Otol Rhinol Laryngol*, 101 (1992) 755. —
- ANDERSON J, CAYE-THOMASEN P, TOS M, *Otol Neurotol*, 25 (2004) 856. DOI: 10.1097/00129492-200411000-00002. —
- SPREM N, BRANICA S, DAWIDOWSKY K, *Coll Antropol*, 26 (2002) 267. —
- NEUMANN A, JAHNKE K, HNO, 53 (2005) 573. —
- YUNG M, *J Laryngol Otol*, 122 (2008) 663. DOI: 10.1017/S00222151 08001813. —
- TOS M, *Otolaryngology-Head Neck Surg*, 139 (2008) 747. DOI: 10.1016/j.otohns.2008.09.021. —
- CAYE-THOMASEN P, ANDERSEN J, UZUN C, HANSEN S, TOSM, *Laryngoscope*, 119 (2009) 944. DOI: 10.1002/lary.20195. —
- NEUMANN A, KEVENHOERSTER K, GOSTIAN AO, *Otol Neurotol*, 31 (2010) 936. DOI: 10.1097/MAO.0b013e3181e71479. —
- OZBEK C, CIFTCI O, OZDEM C, *Eur Arch Otorhinolaryngol*, 267 (2010) 507. DOI: 10.1007/s00405-009-1084-7. —
- VELEPICI MM, STARCEVIC R, TICAC R, KUJUNDZIC M, VELEPICI SM, *Int J Pediatr Otorhinolaryngol*, 76 (2012) 663. DOI: 10.1016/j.ijporl.2012.01.036. —
- VERCRUYSE JP, OFFECIERS FE, SOMERS T, SCHATTEMEN J, GOVAERTS PJ, *Laryngoscope*, 112 (2002) 1782. —
- YAMAMOTO E, IWANAGA M, FUKUMOTO M, *Otolaryngol Head Neck Surg*, 98 (1988) 546. —
- HAMED M, SAMIR M, EL BIGERMY M, *Auris Nasus Larynx*, 26 (1999) 257. DOI: 10.1016/S0385-8146(99)00012-7. —
- VELEPICI SM, BONIFACIO M, MANESTAR D, VELEPICI MM, BONIFACIO D, *Otol Neurotol*, 22 (2001) 430. DOI: 10.1097/00129492-200107000-00002. —
- HEERMANN J, Thirty years autograft tragal and conchal cartilage perichondrium palisade tympanum, epitympanum, antrum and mastoid plasties – 13,000 cases. In: CHARACHON R, GARCIA-IBANES E (Eds) *Long term results and indications in otology and otoneuro-surgery* (Amsterdam, Kugler Publications, 1992). —
- ZAHNERT T, HÜTTENBRINK KB, MÜRBE D, BOMITZ M, *Am J Otol*, 21 (2000) 322. DOI: 10.1016/S0196-0709(00)80039-3. —
- MÜRBE D, ZAHNERT T, BOMITZ M, HÜTTENBRINK KB, *Laryngoscope*, 112 (2002) 1769. —
- DORNHOFFER JL, *Laryngoscope*, 113 (2003) 1844. DOI: 10.1097/00005537-200311000-00002. —
- AARNISALO AA, CHENG JT, RAVICZ ME, HULLI N, HARRINGTON EJ, HEMANDEZ-MONTES MS, FURLONG C, MERCHANT SN, ROSOWSKI JJ, *Otol Neurotol*, 30 (2009) 1209. DOI: 10.1097/MAO.0b013e3181bc398e. —
- AARNISALO AA, CHENG JT, RAVICZ ME, FURLONG C, MERCHANT SN, ROSOWSKI JJ, *Hear Res*, 263 (2010) 78. DOI: 10.1016/j.heares.2009.11.005.

M. M. Velepčić

University of Rijeka, University Hospital Center Rijeka, Clinic of Otorhinolaryngology, Head and Neck Surgery, Krešimirova 42, 51 000 Rijeka, Croatia  
e-mail: marko.velepici123@gmail.com

## PALISADNA TIMPANOPLASTIKA PUNOM DEBLJINOM HRSKAVICE I INTERPOZICIJOM GLAVICE ČEKIĆA: STUDIJA DUGOROČNIH REZULTATA

### SAŽETAK

Namjera ove retrospektivne studije je analiza dugoročnih rezultata timpanoplastike s rekonstrukcijom bubnjića punom debljinom hrskavice uške i interpozicijom glavice čekića učinjene kod 51 bolesnika (56 uha); 36 žena i 15 muškaraca u dobi od 7 do 33 godine (prosjeck 44 godine). Prikazuje se uznapredovala patologija uha na osnovu koje je indicirana ova tehnika timpanoplastike. Prosječno 12 godina nakon operacije elaboriraju se anatomske i funkcionalne rezultati. Anatomske rezultati se kategoriziraju na osnovi empirijske evaluacije stanja novostvorenog bubnjića: 40 (71%) bubnjića bez anatomske iregularnosti, 14 (25%) s iregularnostima i 2 (4%) s sekundarnom perforacijom. Funkcionalne rezultati se temelje na ispitivanju konduktivne komponente u tonalnom audiogramu (pure tone average air bone gap; PTA-ABG) kod 4 frekvencije. Funkcionalne rezultati kod 51 ispitanog uha (51 učinjen audiogram) su slijedeći: prosječni pre i postoperativni PTA-ABG iznosi 27,07±9,98 i 10,77±7,85 decibela (dB) (t=10,36; p<0,001). U skupini uha bez anatomske iregularnosti novostvorenog bubnjića prosječni pre i postoperativni PTA-ABG je 27,30±10,56 i 10,82±8,33 dB (t=8,09; p<0,001). Kod skupine uha s resorpcijom hrskavice bubnjića prosječni pre i postoperativni PTA-ABG iznosi 24,92±8,19 i 9,33±6,58 dB (t=6,21; p<0,001). Između skupina nema statističke značajne razlike. Postoperativne vrijednosti PTA-ABG kod uha nakon primarne operacije (N=34), odnosno reoperacije (N=17) značajno su različite (8,75±5,75 i 15,16±9,62 dB) (t=2,60; p=0,016). Uprkos debljini novostvorenog bubnjića navedena tehnika timpanoplastike je uspješna u rješavanju uznapredovale patologije uha.

