

# Metastaza svjetlostaničnog karcinoma bubrežnih stanica u grkljan: kratki literaturni pregled i prezentacija rijetkog slučaja produljenog preživljavanja

---

Vrebac, Ilinko; Braut, Tamara; Marijić, Blažen; Zahirović, Dag; Dekanić, Andrea; Vukelić, Jelena; Maršić, Matej; Velepich, Marko

Source / Izvornik: **Medicina Fluminensis, 2021, 57, 391 - 395**

Journal article, Published version

Rad u časopisu, Objavljena verzija rada (izdavačev PDF)

[https://doi.org/10.21860/medflum2021\\_264895](https://doi.org/10.21860/medflum2021_264895)

Permanent link / Trajna poveznica: <https://urn.nsk.hr/urn:nbn:hr:184:291366>

Rights / Prava: [Attribution 4.0 International](#)/[Imenovanje 4.0 međunarodna](#)

Download date / Datum preuzimanja: **2024-07-13**



Repository / Repozitorij:

[Repository of the University of Rijeka, Faculty of Medicine - FMRI Repository](#)



# Metastasis of clear cell renal cell carcinoma to the larynx: a short literature review and presentation of a rare case of prolonged survival

## Metastaza svjetlostaničnog karcinoma bubrežnih stanica u grkljan: kratki literaturni pregled i prezentacija rijetkog slučaja produljenog preživljavanja

Ilinko Vrebac<sup>1+</sup>, Tamara Braut<sup>1,4\*+</sup>, Blažen Marijić<sup>1,4</sup>, Dag Zahirović<sup>2</sup>, Andrea Dekanić<sup>3,4</sup>, Jelena Vukelić<sup>1,4</sup>, Matej Maršić<sup>1</sup>, Marko Velepčić<sup>1,4</sup>

**Abstract.** Renal clear cell metastatic carcinoma of the larynx is an extremely rare diagnosis with poor survival. The objective of this short review is to provide insight into current state of literature on this rare neoplasm. Additionally we include the case of a patient with metastatic process of the thyroid cartilage that was treated with novel targeted therapies which enabled prolonged survival and good quality of life. These findings support their inclusion in treatment protocols of patients with metastatic renal clear cell carcinoma of the larynx, especially in those refusing surgery which is the main treatment option in literature so far.

**Key words:** clear cell renal cell carcinoma; intensity-modulated radiotherapy; larynx; neoplasm metastasis; quality of life; targeted therapy

**Sažetak.** Metastaza svjetlostaničnog karcinoma bubrežnih stanica u grkljan izuzetno je rijetka dijagnoza s lošim preživljavanjem. Cilj je ovog kratkog preglednog članka pružiti uvid u trenutno stanje literature o ovoj rijetkoj novotvorini. Uz to uključujemo i slučaj pacijenta s metastatskim procesom tiroidne hrskavice koji je liječen novim ciljanim terapijama koje su omogućile produljeno preživljavanje i dobru kvalitetu života. Ova otkrića potkrepljuju njihovo uključivanje u protokole liječenja pacijenata sa svjetlostaničnim metastatskim karcinomom grkljana, posebno kod pacijenata koji odbijaju kirurško liječenje, što je dosad glavni modalitet liječenja prema dostupnoj literaturi.

**Ključne riječi:** ciljana terapija; grkljan; intenzitetno modulirana radioterapija; kvaliteta života; metastaza; svjetlostanični karcinom bubrežnih stanica

<sup>1</sup>Clinic of Otorhinolaryngology, Head and Neck Surgery, Clinical Hospital Center Rijeka, Rijeka, Croatia

<sup>2</sup>Clinic of Radiotherapy and Oncology, Clinical Hospital Center Rijeka, Rijeka, Croatia

<sup>3</sup>Clinical department of Pathology and Cytology, Clinical Hospital Center Rijeka, Rijeka, Croatia

<sup>4</sup>University of Rijeka, Faculty of Medicine, Rijeka, Croatia

\*These authors contributed equally to this work.

**\*Corresponding author:**

Prof. dr. sc. Tamara Braut, dr. med.  
Clinic of Otorhinolaryngology, Head and Neck Surgery, Clinical Hospital Center Rijeka  
Krešimirova 42, 51000 Rijeka, Croatia  
E-mail: tamara\_braut@hotmail.com

<http://hrcak.srce.hr/medicina>

## INTRODUCTION

Metastatic neoplasms from any region of the body account for only 0.1% to 0.4% of all laryngeal tumors<sup>1,2</sup>. Clear cell metastatic carcinoma of the larynx is a very unusual diagnosis. It is the most prevalent subtype of renal cell carcinoma (RCC) which is seen in 75% to 85% of RCC patients<sup>2</sup>. RCC comprises 2% to 3% of all adult tumors and 85% of primary kidney tumors. While RCC frequently metastasizes to lungs, lymph

Clear cell metastatic carcinoma of the larynx is an extremely rare diagnosis with low survival rate. While most patients in literature are treated with a combination of surgical and oncologic therapy, we present a case where prolonged survival was achieved in a patient who opted only for oncological treatment.

nodes, brain and bones, a metastasis to the larynx is an extremely rare event<sup>1,2</sup>. It is an aggressive neoplasm with a high recurrence and short survival time<sup>1,2</sup>. In our case we achieved a rare prolonged survival of the patient of over 5 years after the diagnosis of laryngeal clear cell metastasis. While most patients with laryngeal clear cell metastasis are treated with a combination of surgical and oncological therapy, our patient refused a surgical procedure and was treated with novel targeted therapies. Nowadays in oncological guidelines sunitinib is approved in the treatment of patients with advanced renal cell carcinoma<sup>3-6</sup>. It is a multitargeted tyrosine kinase inhibitor that inhibits all receptors for platelet-derived growth factor (PDGF-Rs) and vascular endothelial growth factor receptors (VEGFRs), which play a role in both tumor angiogenesis and tumor cell proliferation<sup>4,5</sup>. The simultaneous inhibition of these targets therefore reduces tumor vascularization and triggers cancer cell apoptosis and thus results in tumor shrinkage. In cases of tumor progression despite the therapy with sunitinib, second-line options are available, one of them being nivolumab. It is a human immunoglobulin G4 (IgG4) anti-programmed cell death protein 1 (PD-1) monoclonal antibody that works as a checkpoint inhibitor, it blocks programmed

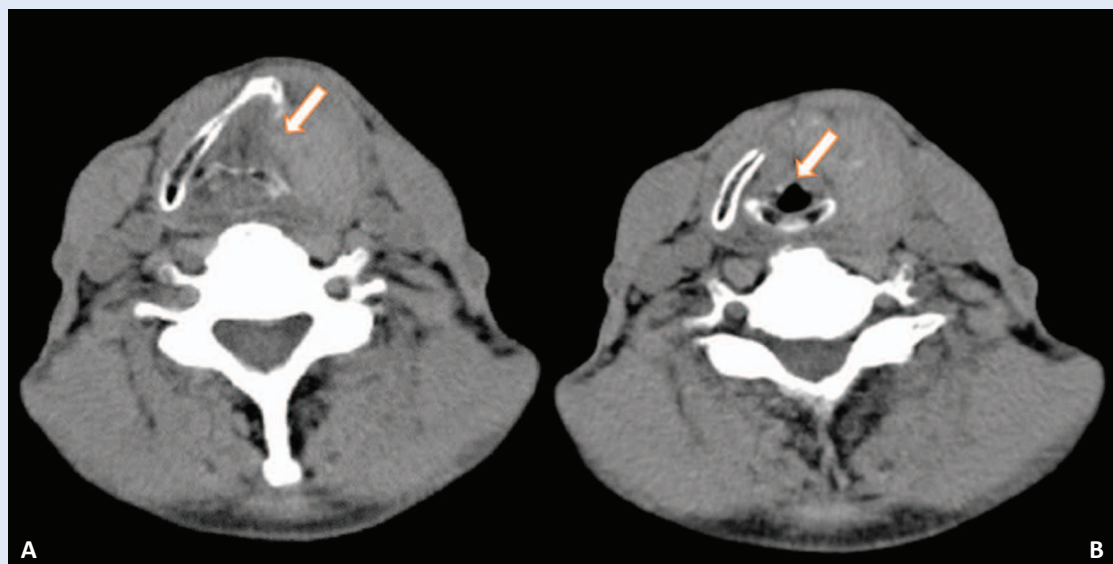
cell death-ligand 1 (PD-L1) binding to PD-1 which allows T cells to attack the tumor<sup>3,6</sup>. The above mentioned drugs were applied in our case, and even without surgical treatment they enabled long survival and good quality of life for our patient.

## SHORT LITERATURE REVIEW

Renal cell carcinoma have the potential of atypical metastases that can develop years after diagnosis even after radical nephrectomy. Renal clear cell metastasis of the larynx is very rare and appears mainly at a progressive stage, predominantly with laryngeal cartilage erosion and positive neck lymphadenopathy. Usually supraglottic tumor presents with globus sensation and/or dysphagia, glottic tumor manifests with hoarseness and/or dyspnea while subglottic tumor tends to compromise the airway<sup>7</sup>.

Patients will often present with hoarseness and dyspnea which can be life threatening, that is why we see it reasonable to address this lesion aggressively. Most authors will agree total laryngectomy with bilateral radical neck dissection (and total thyroidectomy if needed) is the surgical treatment of choice for this laryngeal metastasis. If the metastatic process is very advanced or the patient has contraindications for such extensive surgical procedure, a palliative metastasectomy can contribute to prolonged survival, combined with locoregional intensity modulated radiotherapy to help relief pressure symptoms<sup>8</sup>. Nowadays we have additional options in the treatment of renal clear cell metastasis to the larynx even for those patients refusing mutilating surgical procedures or with contraindications for the same. New insights based on molecular genetics, enabled the introduction of novel targeted therapies in oncological protocols of defined cancer.

A review of the literature describing metastasis of clear cell renal cell carcinoma to the larynx was conducted using PubMed database. Reviewing the literature we found eighteen reports of renal clear cell metastasis to the larynx. Most of those studies reported solitary metastasis to supraglottic region<sup>9-12</sup>, three of the studies reported solitary glottic metastasis<sup>13-15</sup>, three described



**Figure 1. (A)** Axial native computed tomography scan showing tumor mass infiltrating the thyroid cartilage (supraglottic level) causing “mass effect” on laryngeal structures (arrow) and asymmetry in vocal fold movement on flexible nasopharyngolaryngoscopy, but without vocal fold infiltration as it is shown on the glottic level (arrow) in image **(B)**.

solitary subglottic metastasis while the rest described involvement of two or all regions<sup>17,18</sup>.

In our case metastasis appeared in thyroid cartilage, but later evolved into transglottic metastatic process with positive neck lymph nodes.

#### CASE

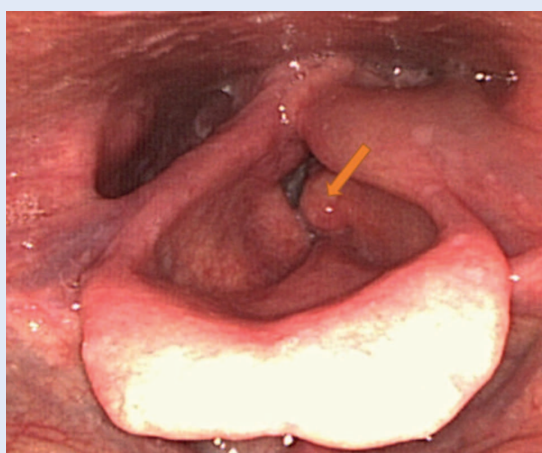
We present the case of a 66-year-old man that underwent left radical nephrectomy after the diagnosis of renal cell carcinoma (pT1bN0M0). He did not show any relapse or metastasis for 7 years after surgery. He was examined at our ENT Clinic in 2015 for prolonged hoarseness, without any other symptoms. His medical history was unremarkable except for the renal cell carcinoma and the nephrectomy, while his social history was smoking for most of his life. Through anamnesis we discovered he had voice changes from time to time over the past 3 years but he didn't give them major importance. Palpatory examination of the neck discovered a firm mass of the thyroid cartilage. Flexible nasolaryngoscopy showed unevenness of the left side of the larynx, causing asymmetry in the movement of the vocal folds, while their surface appeared intact. Computed tomography scan of the neck showed a mass of the left thyroid cartilage (42 × 19 × 42 mm) which

We accomplished a prolonged survival and good quality of life of over 5 years after the diagnosis of laryngeal metastasis with targeted therapy, regardless of surgical treatment. These findings support inclusion of novel targeted therapies in treatment protocols of patients with metastatic clear cell carcinoma of the larynx.

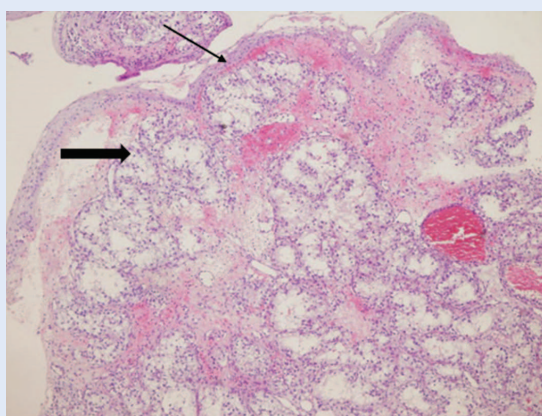
was causing “mass effect” on laryngeal structures (Figure 1). In the head and neck region there was no lymphadenopathy. We performed neck biopsy and histopathology revealed metastatic renal clear cell carcinoma. Additional imaging (positron emission tomography-CT) showed a mass of the right suprarenal gland. Treatment options were presented to the patient (surgical and oncological) who refused surgery and opted for oncological treatment. After multidisciplinary team evaluation targeted therapy with sunitinib was initiated. Sunitinib was applied orally in a dose of 50 milligrams for 4 weeks with 2 weeks of pause between cycles. The patient received 18 cycles of sunitinib in total. In this therapy window of 3 years the patient didn't show any progression of the metastases or symptoms in head and neck region.



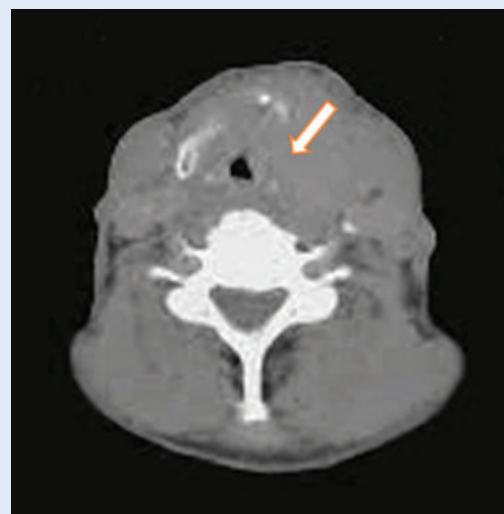
In September 2018 the patient presented at our clinic with evolution of hoarseness, and new symptoms: dysphagia to solids and liquids with mild dyspnea and sensation of pressure in the neck region. Flexible nasolaryngoscopy revealed a mass of the left vocal fold with impaired vocal mobility, while the right vocal appeared intact (Figure 2). Histopathology examination confirmed metastasis of renal clear cell carcinoma infiltrating the vocal fold (Figure 3). Control PET-CT scan showed advancement of the laryngeal clear cell metastasis to the left vocal fold, paratracheal lymph nodes, deep cervical lymph nodes on the left side of the neck and progression in size of the suprarenal me-



**Figure 2.** Flexible nasopharyngolaryngoscopy image of the larynx showing a tumor mass infiltrating the left vocal fold (arrow) while the right vocal fold appears intact.



**Figure 3.** Biopsy specimen representing clusters of metastatic clear cells infiltrating the stroma of the left vocal fold (thick arrow). The squamous epithelial lining of the surface is intact (thin arrow), hematoxylin and eosin stain, magnification  $\times 40$ .



**Figure 4.** Axial section of positron emission tomography with native low dose computed tomography scan demonstrating tumor mass infiltrating the thyroid cartilage and the left vocal fold (arrow) – showing progression of the tumor mass from the supraglottic to the glottic area in comparison with figure 1.

tastasis (Figure 4). After the multidisciplinary team reevaluation, and in accordance to the latest guidelines, we started the second-line therapy with nivolumab, including also 12 fractions (3600 cGy) of locoregional palliative intensity modulated radiotherapy to relieve pressure symptoms. Nivolumab was administered intravenously in a dose of 240 milligrams, once every 2 weeks. The patient completed 12 cycles of the treatment. Although showing minimal objective regression of the vocal fold metastasis, he is reporting subjective improvement, no pressure symptoms, dysphagia or dyspnea, while mild hoarseness is remaining as the main manifestation and disturbance at his latest control check-up.

## DISCUSSION

In most cases reported so far, surgery was the main treatment. We found only two cases of authors using targeted therapy without second-line treatment options. The first group of authors, Demir et al. reported two cases with renal clear cell metastases to the thyroid gland and larynx<sup>18</sup>. In the first case, palliative radiotherapy, interferon alpha-2a and sunitinib was applied. For the second patient, the authors used surgical therapy and interferon alpha-2a. Upon publication, the

first patient was in the tenth month of treatment with minimal objective regression of the tumor mass, while the second patient was in his twelve month of therapy, reporting no symptoms. The second group of authors, Nielsen et al. presented a metastatic process of the left vocal fold<sup>15</sup>. They locally excised the tumor from the left vocal fold while the patient was under targeted therapy with sunitinib, which was initiated after total nephrectomy few months prior to the metastasis of the larynx. Upon publication, their patient had a survival time of 4 months but died of causes unrelated to the laryngeal metastasis.

In a recent article authors Lieder et al. evaluated 671 patients with RCC and found 22 cases of metastases to the head and neck region<sup>19</sup>. All patients received surgical treatment while only 9 of them were treated by targeted therapy. They reported mean survival time of 38 months from the moment patients received diagnosis of RCC metastasis.

As our patient refused surgical treatment our multidisciplinary team opted for novel targeted therapies which enabled rare survival time of 5 years. According to the latest oncological guidelines, we can select targeted therapies that can keep the tumor progression under control, relieve symptoms and prolong the patient's survival, as it is clearly presented in our case.

## CONCLUSION

We highly suggest targeted therapies being included in the life-sustaining treatment protocols for renal clear cell metastasis to the larynx, allowing better quality of life of our patients. We hope that future studies and research in targeted therapies will allow novel drugs and protocols, as well as therapeutic options, especially in complicated and rare oncological cases, like the above presented.

**Conflicts of interest:** Authors declare no conflicts of interest.

## REFERENCES

- Pritchik KM, Schiff BA, Newkirk KA, Krowiak E, Deeb ZE. Metastatic renal cell carcinoma to the head and neck. *Laryngoscope* 2002;112:1598-602.
- Fields JA. Renal carcinoma metastasis to the larynx. *Laryngoscope* 1966;76:99-101.
- Bando Y, Hinata N, Omori T, Fujisawa M. A prospective, open-label, interventional study protocol to evaluate treatment efficacy of nivolumab based on serum-soluble PD-L1 concentration for patients with metastatic and unresectable renal cell carcinoma. *BMJ Open* 2019;9:030522.
- Manz KM, Fenchel K, Eilers A, Morgan J, Wittling K, Dempke WCM. Efficacy and Safety of Approved First-Line Tyrosine Kinase Inhibitor Treatments in Metastatic Renal Cell Carcinoma: A Network Meta-Analysis. *Adv Ther* [Internet]. 2020;37:730-744. [cited 2020 Nov 10]. Available from: <https://link.springer.com/article/10.1007%2Fs12325-019-01167-2>.
- Graham J, Shah AY, Wells JC, McKay RR, Vaishampayan U, Hansen A et al. Outcomes of Patients with Metastatic Renal Cell Carcinoma Treated with Targeted Therapy After Immuno-oncology Checkpoint Inhibitors. *Eur Urol Oncol* 2019;4:102-111.
- Powles T, Staehler M, Ljungberg B, Bensalah K, Canfield SE, Dabestani S et al. Updated EAU Guidelines for Clear Cell Renal Cancer Patients Who Fail VEGF Targeted Therapy. *Eur Urol* [Internet]. 2016;69:4-6. [cited 2020 Nov 10]. Available from: <https://www.sciencedirect.com/science/article/abs/pii/S0302283815009987?via%3Dihub>.
- Barnes L. Metastases to the head and neck: an overview. *Head Neck Pathol* [Internet]. 2009;3:217-224. [cited 2020 Nov 13]. Available from: <https://link.springer.com/article/10.1007%2Fs12105-009-0123-4>.
- Ljungberg B. The role of metastasectomy in renal cell carcinoma in the era of targeted therapy. *Curr Urol Rep* 2013;14:19-25.
- Miyamoto R, Helmus C. Hypernephroma metastatic to the head and neck. *Laryngoscope* 1973;83:898-905.
- Mochimatsu I, Tsukuda M, Furukawa S, Sawaki S. Tumours metastasizing to the head and neck—a report of seven cases. *J Laryngol Otol* 1993;107:1171-3.
- Issing PR, Heermann R, Ernst A, Kuske M, Lenarz T. Fernmetastasierung von Nierenzellkarzinomen in den Kopf-halsbereich [Distant metastasis of renal cell carcinomas to the head-neck area]. *Laryngorhinootologie* 1996;75:171-174.
- Dee SL, Eshghi M, Otto CS. Laryngeal Metastasis 7 Years After Radical Nephrectomy. *Arch Pathol Lab Med* 2000;124:1833-4.
- Maung R, Burke RC, Hwang WS. Metastatic renal carcinoma to larynx. *J. Otolaryngol* 1987;16:16-8.
- Hittel JP, Born IA. Unusual metastatic site of a kidney carcinoma: a case report with review of the literature. *Laryngorhinootologie* 1995;74:642-644.
- Nielsen SB, Swan CZ. Renal cell carcinoma metastasis to the vocal cord: A case report. *Case Stud Surg* 2017;19:3-11.
- Greenberg RE, Cooper J, Krigel RL, Richter RM, Kessler H, Petersen RO. Hoarseness; a unique clinical presentation for renal cell carcinoma. *Urology* 1992;40:159-61.
- Mehdi I, Satayapal N, Abdul Aziz MI, Bhatnagar G, Al-Bahrani BJ. Renal Cell Carcinoma metastasizing to larynx: a case report. *Gulf J Oncolog* 2012;11:70-74.
- Demir L, Erten C, Somali I, Can A, Dirican A, Bayoglu V, et al. Metastases of renal cell carcinoma to the larynx and thyroid: Two case reports on metastasis developing years after nephrectomy. *Can Urol Assoc J* 2012;6:209.
- Lieder A, Guenzel T, Lebentrau S, Schneider C, Franzen A. Diagnostic relevance of metastatic renal cell carcinoma in the head and neck: An evaluation of 22 cases in 671 patients. *Int Braz J Urol* 2017;43:202-208.