

Intestinalna pseudoopstrukcija u pacijenta sa sindromom Kleefstra: prikaz slučaja

Golem, Nikolina; Nikolić, Harry; Sršen Medančić, Suzana; Bosak Veršić, Ana

Source / Izvornik: **Medicina Fluminensis, 2021, 57, 426 - 429**

Journal article, Published version

Rad u časopisu, Objavljena verzija rada (izdavačev PDF)

https://doi.org/10.21860/medflum2021_264900

Permanent link / Trajna poveznica: <https://urn.nsk.hr/urn:nbn:hr:184:062285>

Rights / Prava: [Attribution 4.0 International](#)/[Imenovanje 4.0 međunarodna](#)

Download date / Datum preuzimanja: **2024-12-02**



Repository / Repozitorij:

[Repository of the University of Rijeka, Faculty of Medicine - FMRI Repository](#)



Intestinal pseudo-obstruction in a patient with Kleefstra syndrome: a case report

Intestinalna pseudoopstrukcija u pacijenta sa sindromom Kleefstra: prikaz slučaja

Nikolina Golem^{1*}, Harry Nikolić^{1,2}, Suzana Sršen Medančić^{1,2}, Ana Bosak Veršić^{1,2}

¹Sveučilište u Rijeci, Medicinski fakultet, Rijeka, Hrvatska

²Klinika za dječju kirurgiju, Klinički bolnički centar Rijeka, Rijeka, Hrvatska

Abstract. Aim: To present a case of intestinal pseudo-obstruction in a paediatric patient with Kleefstra syndrome type 1 as a new clinical feature of this rare genetic disorder. **Case report:** A seven-year-old patient was admitted to the emergency department for nausea and vomiting. Clinical examination showed distended, meteoristic abdomen without detectable peristaltic sound. Abdominal X-ray revealed air-fluid levels and possible right subdiaphragmatic air collection. An urgent exploratory laparotomy was indicated. Intraoperatively, extremely dilated loops of small and large intestine up to the distal sigmoid colon were noted. No anatomical or mechanical causes of obstruction were found. The postoperative course was complicated by dysfunctional intestinal motility and urinary catheter-related infection which required prokinetics and intravenous antibiotic therapy. The patient was transferred to a paediatric centre specialized in intestinal motility disorders for further treatment. **Conclusion:** This is the first case of intestinal pseudo-obstruction described as a part of clinical presentation of Kleefstra syndrome type 1. Further research and re-evaluation of patients with KS1 is needed to determine if intestinal pseudo-obstruction is a new clinical manifestation depending on the size of the deletion or a repercussion of hypotonia sequential to an underlying syndrome.

Key words: genetic disorder; hypotonia; intestinal pseudo-obstructions; 9q34.3 microdeletion syndrome

Sažetak. Cilj: Prikazati slučaj sedmogodišnjeg pacijenta sa sindromom Kleefstra tipa 1 i akutnim nastupom intestinalne pseudoopstrukcije. **Prikaz slučaja:** Sedmogodišnji pacijent primljen je u hitnu medicinsku službu zbog mučnine i povraćanja. Kliničkim pregledom utvrđen je distendirani, meteorističan abdomen, nečujne peristaltike. Nativni radiogram abdomena prikazao je aerolikvidne nivoe i srpoliku transparentiju ispod desne kupole dijafrazme. Sukladno kliničkoj slici i radiološkom nalazu postavljena je sumnja na ileus i moguću perforaciju šupljeg organa te je indicirana hitna eksplorativna laparotomija. Intraoperativno su uočene ekstremno dilatirane vijuge tankog i debelog crijeva sve do završnog dijela sigmoidnog kolona. Eksplorativnom laparotomijom nije pronađena perforacija šupljeg organa niti mehanički uzrok opstrukciji pasaže pa se postavila sumnja na intestinalnu pseudoopstrukciju u sklopu osnovnog sindroma. Poslijeoperacijski tijek zakomplicirao se otežanim uspostavljanjem peristaltike i uroinfekcijom kao posljedicom duže kateterizacije, što je zahtijevalo uvođenje prokinetika i terapiju antibioticima. Pacijent je prebačen u užu specijaliziranu ustanovu na daljnje liječenje. **Zaključak:** U prikazanom slučaju intestinalna pseudoopstrukcija po prvi je put opisana u sklopu sindroma Kleefstra tipa 1. Budući da je ovo prvi takav opisani slučaj, potrebna su daljnja istraživanja i reevaluacija pacijenata sa sindromom Kleefstra tipa 1 kako bi se utvrdilo radi li se o novoj kliničkoj manifestaciji ovisnoj o veličini delecije ili posljedici generalizirane hipotonije u sklopu osnovnog sindroma.

Ključne riječi: genetski poremećaj; hipotonija; intestinalne pseudoopstrukcije; 9q34.3 mikrodelecijski sindrom

***Corresponding author:**

Nikolina Golem, dr. med.

Sveučilište u Rijeci, Medicinski fakultet

Braće Branchetta 20, 51000 Rijeka, Hrvatska

E-mail: nikolina.golem96@gmail.com

<http://hrcak.srce.hr/medicina>

INTRODUCTION

Kleefstra syndrome (KS) is a rare genetic disorder divided into two types depending on the affected gene. Kleefstra syndrome type 1 (KS1) is caused by a microdeletion of the 9q34.3 chromosomal region or a heterozygous mutation in the euchromatin histone methyltransferase 1 (EHMT1) gene¹. It is characterized by intellectual disability, childhood hypotonia, and distinct facial features. Additional clinical features include seizures, behavioural abnormalities, congenital heart defects, and urogenital anomalies^{1,2}. The main phenotypic features arise from haploinsufficiency for the EHMT1 gene². The estimated prevalence is 1 per 200,000 individuals diagnosed with intellectual disability³. Gastrointestinal (GI) disorders aren't a part of initial clinical presentation of KS1. GI disorders described so far as a part of clinical presentation of KS1 are anal atresia and gastro-oesophageal reflux^{2,3}. Intestinal pseudo-obstruction is a gastrointestinal motility disorder characterized by recurrent intestinal obstruction, without evidence of mechanical or anatomical occlusion⁴. Intestinal motility disorders, to our knowledge, have not been previously described as part of KS1. This case report presents a seven-year-old boy with KS1 and acute onset of intestinal pseudo-obstruction.

CASE REPORT

A seven-year-old boy with KS1 was admitted to the paediatric emergency department for nausea and vomiting. At the age of 21 months, the patient was referred to genetic testing due to generalized hypotonia, developmental delay, facial dysmorphisms, recurrent bronchoobstruction, hypertrophic obstructive cardiomyopathy, and atrial septal defect. Multiplex ligation-dependent probe amplification (MLPA) detected deletion of the EHMT1 gene in 9q subtelomeric region as well as deletion of CACNA1B and NELF gene (known as NSMF gene) in the 9q34.3 chromosomal region. The patient's family did not consent to further genetic testing. At admission to the paediatric emergency department, the abdomen was distended, meteoristic, soft, and painful, with absent peristaltic sounds.

The abdominal X-ray revealed significant colonic distension with air-fluid levels and right subdiaphragmatic sickle-shaped transparency (Figure 1). Differentials included ileus and hollow organ perforation. A bisacodyl suppository and nasogastric tube were applied to provoke stool. The day after admission, a clinical exacerbation was noticed with a distended and tender abdomen. Abdominal X-ray showed persistent air-fluid levels with dilated bowel and a possible air collection beneath the right costal arch. After a pre-

No organ perforation or mechanical cause of obstruction was found. The pathohistological examination of the sigmoid colon described no ganglion cell disorders that would indicate Hirschsprung's disease. Specimens of the ileum and appendix were normal.

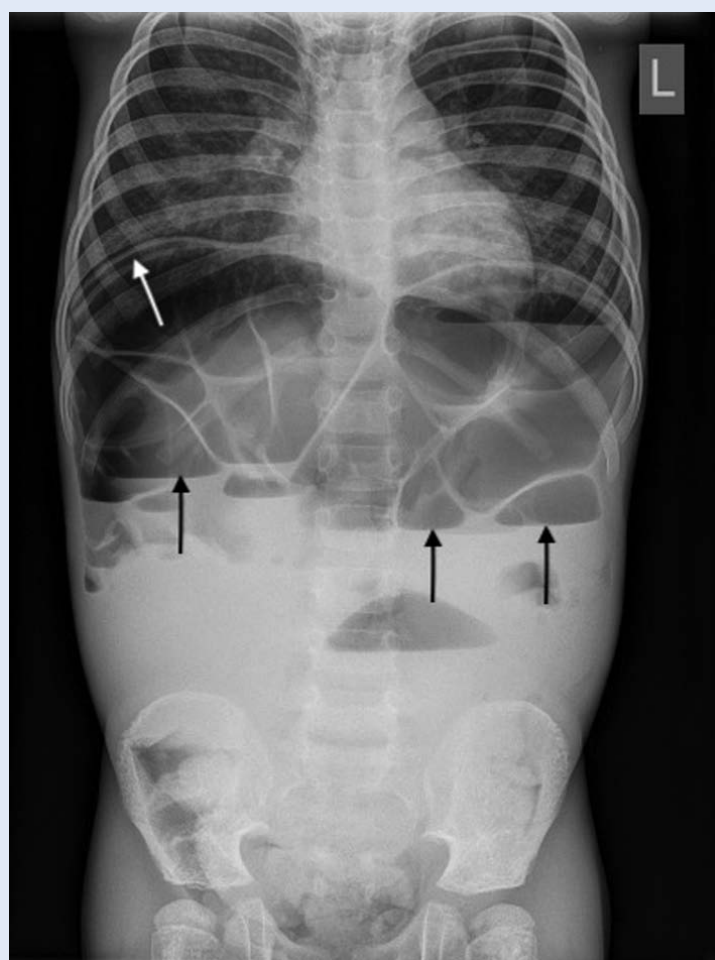


Figure 1. Abdominal X-ray revealing air-fluid levels (black arrow) and subdiaphragmatic sickle-shaped transparency (white arrow).

operative assessment, the patient underwent urgent exploratory laparotomy. Intraoperatively, extremely dilated loops of small and large intestine up to the distal sigmoid colon were noted. Appendectomy was performed, and intestinal decompression was achieved by enterotomy. The biopsy specimens of the terminal ileum and sigmoid colon were collected for pathohistological analysis. No organ perforation or mechanical cause of obstruction was found. The suspicion of intestinal pseudo-obstruction as part of the un-

The suspicion of intestinal pseudo-obstruction as part of the underlying syndrome was raised. Intestinal pseudo-obstruction may be a new clinical feature of Kleefstra syndrome type 1.

derlying syndrome was raised. Postoperatively, the patient was hemodynamically stable. An increase in inflammatory markers prompted the introduction of intravenous ceftriaxone. On the fifth postoperative day, an urgent laparotomy was indicated due to wound dehiscence. Intraoperatively, dilated small and large intestine loops were observed. Perforation of the sigmoid colon occurred at the site of previously taken biopsy. Due to slower wound healing and poor motility, *anus praeter* was performed at the descendent colon level.

The postoperative course was complicated by dysfunctional intestinal motility and urinary catheter-related infection which required prokinetics and antibiotic therapy.

The pathohistological examination of the sigmoid colon described no ganglion cell disorders that would indicate Hirschsprung's disease. Specimens of the ileum and appendix were normal. The patient was transferred to a paediatric centre specialized in intestinal motility disorders for further treatment. An ileostomy was formed, and Percutaneous Endoscopic Gastrostomy (PEG) was placed.

DISCUSSION

Kleefstra syndrome type 1 is a rare genetic disorder with the estimated prevalence of 1 per 200,000 individuals diagnosed with intellectual

disability³. Even though they are not a part of initial clinical presentation, GI disorders described so far include anal atresia and gastroesophageal reflux^{2,3}. This could be the first case of intestinal pseudo-obstruction as a clinical manifestation of KS1.

Intestinal pseudo-obstruction may be acute or chronic. Acute pseudo-obstruction occurs due to drug toxicity, electrolyte abnormalities, infection, trauma, or postoperatively^{4,5}. Chronic pseudo-obstruction causes are visceral neuropathies, myopathies, and anomalies of the gastrointestinal (GI) tract^{4,5}. In our case, intestinal biopsy showed no abnormalities, excluding myenteric plexus disorders and GI smooth muscle disorders as the cause. According to previous medical history, no underlying cause could be found.

The most common clinical presentation of KS1 includes severe developmental delay and intellectual disability, behavioural disorders, childhood hypotonia, and distinct craniofacial dysmorphisms^{6,7}. Other associated clinical findings include congenital heart defects, urogenital anomalies, epilepsy, and increased body weight^{6,7}. Due to the diagnosed KS1, the patient suffered from hypotonia, developmental delay, facial dysmorphisms, recurrent bronchoobstruction, hypertrophic obstructive cardiomyopathy, and atrial septal defect. MLPA detected deletion of the EHMT1 gene in the 9q subtelomeric region as well as deletion of CACNA1B and NELF gene in 9q34.3 chromosomal region. Deletion of the EHMT1 gene is responsible for the main phenotypic features of KS1⁸. As Harada et al. have reported, CACNA1B gene is a voltage-dependent calcium channel gene that encodes an N-type calcium channel involving neurotransmitter release from neurons⁹. The aforementioned authors also reported that the reduction of N-type calcium channel activity may be an additional factor for the occurrence of epilepsy or developmental delay and intellectual disability⁹.

NELF gene encodes nasal embryonic luteinizing hormone-releasing hormone (LHRH) factor⁹. During embryonic development, *Nelf* is expressed in peripheral and central nervous systems, including olfactory sensory cells and LHRH cells⁹. As Kramer et al have reported, it is suggested that

Nelf plays a role in guidance for olfactory axon projections and neutrophilic migration of LHRH cells¹⁰.

According to the genetic testing which has been done, the size of the deletion cannot be determined. Depending on the size of the deletion, there is a possibility that a gene has been affected which could explain the intestinal motility disorder and the onset of intestinal pseudo-obstruction. As Gamboa H. E. et al. have reported, genetic abnormalities and syndromes often present with intestinal pseudo-obstruction⁵. They presented several syndromes caused by identified genetic mutations with intestinal pseudo-obstruction as a phenotypic feature⁵. For example, Congenital myopathy and gastrointestinal pseudo-obstruction syndrome caused by mutation of *POLG1* gene presents with severe hypotonia and generalized muscle weakness, abdominal distension, and hypoactive bowel⁵.

However, concerning the patient in question, this would have had to be confirmed with further genetic testing which was not consented to in this case.

Intestinal pseudo-obstruction, to our knowledge, has never been described as a clinical presentation of KS1. The proposed pathophysiological mechanism of decreased intestinal motility is hypotonia of intestinal smooth muscle⁴. The patient's medical history noted occasional constipation. The exacerbation of decreased motility might have caused pseudo-obstruction. We suggest further research and re-evaluation of patients with KS1 to determine if intestinal pseudo-obstruction is a new clinical manifestation depending on the size of the deletion or a repercussion of hypotonia sequential to an underlying syndrome.

CONCLUSION

Kleeftstra syndrome type 1 is a rare genetic disorder caused by a microdeletion of the 9q34.3 chromosomal region or a heterozygous mutation

in the *EHMT1* gene¹. Intestinal pseudo-obstruction, to our knowledge, has not been previously described as a part of KS1.

To summarize, further research and re-evaluation of patients with KS1 is needed to determine if intestinal pseudo-obstruction is a new clinical manifestation of KS1.

Conflicts of interest: Authors declare no conflicts of interest.

REFERENCES

1. Ciaccio C, Scuvera G, Tucci A, Gentilin B, Baccarin M, Marchisio P et al. New Insights into Kleeftstra Syndrome: Report of Two Novel Cases with Previously Unreported Features and Literature Review. *Cytogenet Genome Res* 2018;156:127-133.
2. Kleeftstra T, Brunner HG, Amiel J, Oudakker AR, Nillesen WM, Magee A et al. Loss-of-function mutations in euchromatin histone methyl transferase 1 (*EHMT1*) cause the 9q34 subtelomeric deletion syndrome. *Am J Hum Genet* 2006;79:370-377.
3. Torga AP, Hodax J, Mori M, Schwab J, Quintos JB. Hypogonadotropic Hypogonadism and Kleeftstra Syndrome due to a Pathogenic Variant in the *EHMT1* Gene: An Under-recognized Association. *Case Rep Endocrinol* 2018;2: 428.
4. Peck SN, Altschuler SM. Pseudo-obstruction in children. *Gastroenterol Nurs* 1992;14:184-188.
5. Gamboa HE, Sood M. Pediatric Intestinal Pseudo-obstruction in the Era of Genetic Sequencing. *Curr Gastroenterol Rep* 2019;21:70.
6. Schwaibold EMC, Smogavec M, Hobbiebrunken E, Winter L, Zoll B, Burfeind P et al. Intragenic duplication of *EHMT1* gene results in Kleeftstra syndrome. *Mol Cytogenet* 2014;7:74.
7. Willemsen MH, Vulto-van Silfhout AT, Nillesen WM, Wis-sink-Lindhout W M, Van Bokhoven H, Philip N et al. Update on Kleeftstra Syndrome. *Mol Syndromol* 2012;2:202-21.
8. Yatsenko SA, Cheung SW, Scott DA, Nowaczyk MJ, Tarnopolsky M, Naidu S et al. Deletion 9q34.3 syndrome: genotype-phenotype correlations and an extended deletion in a patient with features of Opitz C trigonocephaly. *J Med Genet* 2005;42:328-35.
9. Harada N, Visser R, Dawson A, Fukamachi M, Iwakoshi M, Okamoto N et al. A 1-Mb critical region in six patients with 9q34.3 terminal deletion syndrome. *J Hum Genet* 2004;49:440-444.
10. Kramer PR, Wray S. Novel gene expressed in nasal region influences outgrowth of olfactory axons and migration of luteinizing hormone-releasing hormone (LHRH) neurons. *Genes Dev* 2000;14:1824-34.