

# Middle ear tuberculosis in an immunocompromised patient: Case report and review of the literature

---

**Velepič, Marko; Vukelić, Jelena; Dvojković, Žana; Škrobonja, Ivana; Braut, Tamara**

*Source / Izvornik:* **Journal of Infection and Public Health, 2021, 14, 139 - 142**

**Journal article, Published version**

**Rad u časopisu, Objavljena verzija rada (izdavačev PDF)**

<https://doi.org/10.1016/j.jiph.2020.10.011>

*Permanent link / Trajna poveznica:* <https://urn.nsk.hr/urn:nbn:hr:184:111484>

*Rights / Prava:* [Attribution-NonCommercial-NoDerivatives 4.0 International/Imenovanje-Nekomercijalno-Bez prerada 4.0 međunarodna](#)

*Download date / Datum preuzimanja:* **2025-01-13**



*Repository / Repozitorij:*

[Repository of the University of Rijeka, Faculty of Medicine - FMRI Repository](#)





## Middle ear tuberculosis in an immunocompromised patient: Case report and review of the literature



Marko Velepici<sup>a</sup>, Jelena Vukelic<sup>a,\*</sup>, Zana Dvojkovic<sup>b</sup>, Ivana Skrobonja<sup>c</sup>, Tamara Braut<sup>d</sup>

<sup>a</sup> Department for Otolaryngology and Head and Neck Surgery, Clinical Hospital Center Rijeka, Kresimirova 42, 51000 Rijeka, Croatia

<sup>b</sup> Department for Otolaryngology, Srebrnjak Children's Hospital, Srebrnjak 100, 10000 Zagreb, Croatia

<sup>c</sup> Clinical Department for Clinical Microbiology, Clinical Hospital Center Rijeka, Kresimirova 42, 51000 Rijeka, Croatia

<sup>d</sup> Department for Otolaryngology and Head and Neck Surgery, Clinical Hospital Center Rijeka, Kresimirova 52, 51000 Rijeka, Croatia

### ARTICLE INFO

#### Article history:

Received 22 April 2020

Received in revised form 25 August 2020

Accepted 8 October 2020

#### Keywords:

Immunocompromised patient

Liver transplant

*Mycobacterium tuberculosis*

Suppurative otitis media

Tympanoplasty

### ABSTRACT

Tuberculosis is an airborne disease caused by *Mycobacterium tuberculosis*. In 15–20% cases of active disease extrapulmonary tuberculosis may occur, most commonly in the head and neck region. Tuberculous otitis media accounts for 0.1% of the total number of tuberculosis patients. This paper provides insight into current state of literature of tuberculous otitis media. It also includes the case of a 53-year-old patient with tuberculous otitis media. The patient had a liver transplantation and she showed an atypical manifestation of the disease including acute otitis media and coinfection with *Achromobacter xylosoxidans*. The paper describes in detail the methods of diagnosis and the infection treatment. Considering the polymorphic clinical presentation of tuberculous otitis media in cases with long lasting otorrhea differential diagnosis should include an infection with *Mycobacterium tuberculosis*.

© 2020 Published by Elsevier Ltd on behalf of King Saud Bin Abdulaziz University for Health Sciences. This is an open access article under the CC BY-NC-ND license (<http://creativecommons.org/licenses/by-nc-nd/4.0/>).

### Contents

Introduction .....	139
Case report .....	140
Discussion and literature review .....	141
Conclusion .....	141
Funding .....	142
Conflict of interest .....	142
Ethical approval .....	142
References .....	142

### Introduction

Tuberculosis (TB) is an airborne disease caused by *Mycobacterium tuberculosis* [1]. The most common place of primary infection with *M. tuberculosis* (MTB) are lungs, but in 15–20% of active cases, the infection spreads outside the lungs, causing extrapulmonary tuberculosis [2]. 95% of the cases involve head and neck region and may affect larynx, lymph nodes, tonsils, pharynx, oral cavity, salivary glands, and external and middle ear [3]. MTB infections are significantly more frequent in immunocompromised

patients. Regarding often co-infections and frequent use of antibiotic therapy, such patients are prone to developing resistance to standardised treatment and therefore their treatment is significantly more demanding [4].

Tuberculous otitis media (TBOM) is a rare form of tuberculosis and it accounts for 0.1% of all cases of TB. In clinical presentation, long lasting otorrhea that persists despite applied antibiotic therapy is the most common symptom. In addition, the disease is characterised by profound hearing loss and possible facial palsy. Physical examination reveals eardrum perforation, sometimes with multiple and abundant granulation tissue formations. Considering a nonspecific clinical presentation that mimics other suppurative middle ear infections, setting up the diagnosis is often difficult and delayed.

\* Corresponding author.

E-mail address: [jl.vukelic@gmail.com](mailto:jl.vukelic@gmail.com) (J. Vukelic).

The paper provides insights into current state of literature of tuberculous otitis media. This case report of atypical clinical presentation of above mentioned disease, highlights the rarity of the condition and its propensity to masquerade as common otological conditions. Delayed recognition of such a condition could postpone timely treatment and proper management of the disease.

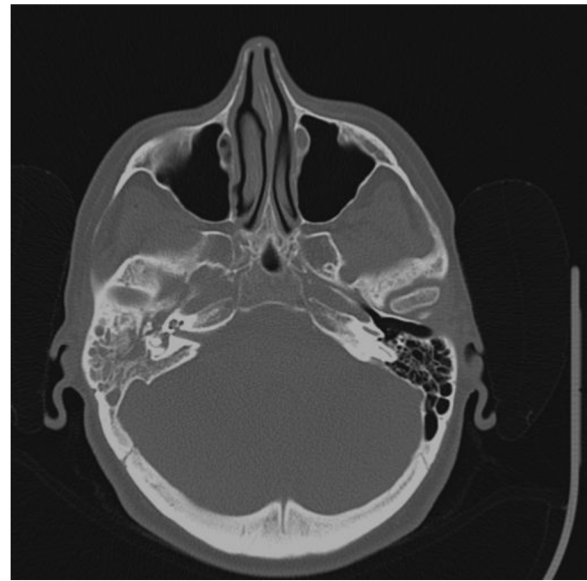
### Case report

A 53-year-old woman was presented with hearing loss and mild pain in the right ear. She presented with hearing loss during a month period and her ear pain started 5 days prior to the examination. She didn't have vertigo or tinnitus. An otomicroscopic examination was performed, and acute inflammation of the middle ear was observed: bulging, reddish eardrum with white, pus-like secretion in the middle ear cavity.

The audiometry of the right ear indicated mixed hearing loss with a hearing threshold between 65 and 100 dB. The tympanogram of the right ear was type B, while on the left ear it was type A. The laboratory findings showed increased inflammatory parameters (leukocytes  $13,3 \times 10^9/L$ , neutrophils  $9,39 \times 10^9/L$ ) that indicated acute bacterial infection.

Having consulted the patient's findings from her medical history, it was found out that two years ago the patient had a liver transplantation because of autoimmune hepatic cirrhosis. Because of that she was taking Prograf (tacrolimus) 0,15 mg/kg/day divided in two doses. Considering that the patient was immunocompromised, it was assumed that there was a great probability for the development of otogenic complications and therefore a right ear myringotomy was performed. The purulent secretion from the middle ear cavity was sent to microbiology testing. The patient received empirical intravenous therapy with ceftriaxone 2 g/day for 7 days. On the 7<sup>th</sup> postoperative day, the control otomicroscopic examination revealed a dry ear with perforation of lower quadrants of 1 mm in diameter. The control microbiology smear of the right ear showed sterile specimen, so the patient was discharged from hospital.

After three weeks, the patient came back for a check-up because of purulent ear discharge. An otomicroscopic examination revealed subtotal perforation of the eardrum. Although the ear was full of suppurative discharge, the malleus handle was intact. An ear secretion sample was proceeded to microbiologic analysis. The results showed *coagulase negative staphylococci* (CoNS), sensitive to tobramycin. The treatment with tobramycin ear drops 3 times a day for 2 weeks was initiated. In addition, otomicroscopic ear cleaning was regularly performed. Since the treatment showed no improvement, the microbiologic analysis of the ear secretion was repeated. The findings showed *Staphylococcus epidermidis* MRSE, sensitive to rifampicin. In the next two weeks, the patient was treated with rifampicin eardrops 3 times daily with regular otomicroscopic cleanings for 2 weeks. Since there was still no improvement, the patient was sent to temporal bone computerised tomography (CT) scan. The CT scan revealed no pneumatization in the right mastoid and cells on the base of the right pyramid (Fig. 1). There was a presence of hypodense substrate in the middle ear cavity. The ossicles were intact and no bone destruction was observed. The patient was further treated according to the latest findings of ear swab with moxifloxacin hydrochloride drops 3 times daily for 2 weeks. The goal was to achieve the maximum effects and create optimal conditions for operative treatment. The operation was performed in general endotracheal anaesthesia. The inflamed tissue was removed from the mastoid cavity and sent to microbiological and pathophysiological analysis. After mastoidectomy tympanoplasty with chondroperichondrial island



**Fig. 1.** The CT scan revealed no pneumatization in the right mastoid and cells on the base of the right pyramid. There is a presence of hypodense substrate in the middle ear cavity with intact ossicles. No bone destruction is observed.

graft from the cymba conchae was performed. The findings of microbiological analysis proved to be sterile. Therefore, due to satisfactory local finding and her general condition, the patient was discharged.

The findings of pathohistological analysis showed chronic granulomatous inflammation, the type of hard tubercle, with caseous necrosis, surrounded with epithelioid cells, lymphocytes and Langhans giant cells. According to histopathology findings, middle ear tuberculosis was diagnosed. The family medical history revealed that the patient's husband had lung tuberculosis 20 years ago. As a part of standard pretransplant evaluation tuberculin test was performed being negative no further testing was done. In the course of the treatment the ear dressing was removed and otomicroscopic examination revealed a defect of the eardrum on the margin of the graft and an unusual ear discharge. In this case because of family history, the ear swab was made on special substrate for acid-resistant bacteria and proceeded to microbiological analysis. An *Achromobacter xylosoxidans* was isolated. According to the antibiogram, parenteral intravenous therapy with meropenem 500 mg 3 times daily for 10 days was administered. Considering resistance to all tested topical antibiotics, daily otomicroscopic cleaning was carried out with 10% Betadine solution (povidone iodide) diluted in 1:1 ratio with 0.9% saline solution. After ten days, a control ear swab was performed and the specimen results showed to be sterile. Lung tuberculosis was excluded through pulmonological evaluation. Bronchoscopy with bronchoalveolar lavage was made with no TB findings. The QuantiFERON test was positive, >17.84 IU/L. According to the recommendation of pulmonologist, an anti-tuberculosis therapy was initiated. The patient received 425 mg of Eutizon<sup>®</sup>B6 capsule (400 mg isoniazid and 25 mg pyridoxylchloride) once daily, Etambutol 1200 mg (ethambutol chloride 400 mg) once daily and Rimactan 600 mg (rifampicin 300 mg) once daily for 9 months. Every two weeks the liver enzymes were checked-up and the patient had regular gastroenterology follow-ups. After completion of anti-TB therapy, the otomicroscopic examination showed successfully treated inflammation with no secretion or perforation. The control audiometry of the right ear showed mixed hearing loss with a hearing threshold between 55 and 85 dB.

## Discussion and literature review

A thorough literature search on Medline was performed. It included only articles in English. In searching the tuberculosis otitis as a keyword, 431 articles were found. Searching the keyword tuberculosis acute otitis, was found in 44 articles. From those articles only 5 of them discussed about tuberculosis otitis but none of them addressed acute otitis media. Eswaran et al. reported a case of primary tuberculous otitis media who presented with Bezold's abscess [5]. Maniu et al. described case of middle ear tuberculosis that had predominating otological symptoms including mastoiditis, hearing loss, and subsequently facial nerve palsy [6]. Oh et al. described a case with primary tuberculosis arising in the Eustachian tube that presented as aural fullness and hearing disturbance [7]. Manigandan et al. reported a case of a five year old boy that had features of tuberculous otitis media but also developed a suppurative complication due to *Staphylococcus aureus* [8]. This clinical presentation included painless and clear discharge from both ears with fever. Awan et al. described two cases of tuberculous otitis media that presented as chronic otitis media [9]. Searching the keyword immunocompromised tuberculosis otitis media, only 7 articles were found. Only one of those papers written by Ergün et al. described a case of diagnosed tuberculous otitis media after recurrent chronic otitis media in a renal transplant recipient [10]. None of those papers included patient with tuberculous otitis media and liver transplantation. It is also important to point out that none of the described cases presented with acute otitis media and multiple co-infections with various bacteria including *A. xylosoxidans*.

Immunocompromised patients, including those who were subjected to organ transplantation, are all prone to high risk activation of a TBC latent form [11].

The TBC treatment lasting for two months mainly starts with initial drug cocktails, followed by 4–6 months of maintenance treatment. A large number of antibiotics is used to anticipate quick spontaneous mutation of a causative agent. If needed, the treatment is further adjusted in multidrug resistance cases which do not respond to standard therapy [1,12].

Middle ear tuberculosis is a rare disease and it is easily overlooked in initial diagnosis and early treatment period. The infection may be primary if the infected secretion reaches the middle ear cavity through the Eustachian tube, or secondary if coughing causes colonisation of nasopharynx with microorganisms from the lungs [13]. The latter may also be the consequence of haematogenous spread.

In 1953. Wallmer was the first to describe the clinical presentation of tuberculous otitis media [14]. It included painless chronic otorrhea, multiple drum perforations, granulation tissue in the middle ear and mastoid cavity, bone necrosis with progressive conductive hearing loss and facial nerve paralysis. Nowadays, the clinical disease presentation is variable and polymorphous. Hearing loss is present in 90% of patients. Its most common form is sensorineural or mixed, but pure conductive hearing loss can also be found in some cases. Sensorineural hearing loss can be attributed to vasculitis of cochlear veins, disposal of immune complex deposits in the cochlea, or to the presence of granulomatous tissue affecting the acoustic nerve [15]. Peripheral facial nerve paralysis may be a part of the clinical presentation.

The diagnostic workup begins with clinical examination, followed by microbiological examinations of the ear secretion. Only in 5–35% of cases the result is positive to MBT. The Tuberculin (PPD or Mantoux) tests as well as the QuantiFERON tests have a low specificity because of possible false positive results in patients who had tuberculosis or have been vaccinated [16]. Furthermore, as a part of diagnostic workup it is necessary to carry out a temporal bone CT scan. The CT scan usually shows inflamed tissue inside the middle ear and mastoid cavity, with or without bone erosion [17]. It is

possible to find similar finding in patients with chronic ear inflammation or cholesteatoma [18]. All those non-invasive diagnostic methods are nonspecific and therefore, it is necessary to perform a surgical exploration of the middle ear and mastoid [14,19]. Canal wall up mastoidectomy in combination with tympanoplasty is recommended for removing necrotic bone and granulation tissue. Finally, the pathohistological finding represents a gold standard in the tuberculous otomastoiditis diagnosis [16]. Nevertheless, the role of surgical approach as a method of treatment remains controversial, and the final consensus on the subject has not yet been definitely established. A group of authors consider that surgery is not required, unless complications are present. The same group of authors also consider that there is no indication for ossicular chain reconstruction until the resolution of symptoms appears [16,19]. On the other hand, Kwon et al. proved higher incidence of dry ear if surgery preceded chemotherapy, versus only chemotherapy treatment [20]. To confirm that opinion Varty et al. described that combined approach, surgical and medical, show best results [21]. We agree that although operative treatment represents cure basis it is unlikely that infection will be eradicated without long lasting antibiotic therapy. Only combined approach, conservative and surgical, can lead to a successful outcome.

The differential diagnosis of chronic otorrhea as a leading symptom in patients with TBOM includes a variety of diseases including fungal infections, Wegener's granulomatosis, midline granuloma, sarcoidosis, syphilis, necrotizing otitis externa, lymphoma, histiocytosis X and cholesteatoma [22].

In our patient, the diagnosis was made within 6 months from her first examination, which is rather early according to the group of authors that described setting the diagnosis within one year [23].

Facial nerve paralysis occurs in 15–40% of patients with TBOM [24]. Our patient didn't have it, which made the diagnosis more difficult considering the fact that otorrhea with facial nerve paralysis would considerably earlier indicate TBOM.

Otomicroscopic examination of TBOM patients usually reveals pale granulomatous tissue, serous to purulent otorrhea, multiple eardrum perforations with eroded malleus handle. Regarding those symptoms, our patient also had an atypical clinical presentation since her findings included subtotal eardrum perforation, intact malleus and purulent otorrhea.

Our patient had mixed hearing loss that did not significantly improve after the treatment was performed. This can be explained by the fact that the conductive component can be partially repaired by a surgical approach with tympanoplasty, while the sensorineural component of hearing loss cannot be significantly affected. Akkara et al. describe similar results in their research [4].

No cases of TBOM co-infection and *A. xylosoxidans* were found in the available literature. The treatment with povidone iodide was successful, but additional research should confirm its effectiveness.

Limitations of our case report came from the fact of false negative tuberculin test performed as a part of pretransplant evaluation. Given the fact that literature states 10 and even up to 20% of false negative results perhaps this should have been taken into consideration earlier in the evaluation accelerating the accurate diagnosis.

Early diagnosis is extremely important because of prompt start of anti-tuberculous therapy as an etiologic treatment. This significantly increases the success of the treatment as we have demonstrated by curing our patient.

## Conclusion

It is important to point out that TBOM can present as acute otitis media that does not respond to standard antibiotic therapy. We believe that one of the reasons for such a presentation is due to

the immunosuppression of patient. Further investigations should be done to confirm our hypotheses. Additionally, attention should be paid to possible coinfections which may additionally complicate the treatment. Timely diagnosis and early onset of treatment are unquestionably associated with a better treatment outcome. Additional efforts should be made in developing simpler and easily accessible TBOM diagnostic methods.

### Funding

No funding sources.

### Conflict of interest

None declared.

### Ethical approval

The authors assert that all procedures contributing to this work comply with the ethical standards of the relevant national and institutional guidelines on human experimentation (Clinical hospital centre Rijeka, Croatia) and with the Helsinki Declaration of 1975, as revised in 2008.

### References

- [1] Fogel N. Tuberculosis: a disease without boundaries. *Tuberculosis* 2015;95(5):527–31.
- [2] Janmeja AK, Mohapatra PR, Aggarwal D. Extrapulmonary tuberculosis. In: Jindal SK, editor. *Textbook of pulmonary and critical care medicine*. New Delhi: Jaypee brothers Medical Publishers; 2017. p. 538–57.
- [3] De Sousa RT, Briglia MFS, De Lima LCN, De Carvalho RS, Teixeira ML, et al. Frequency of otorhinolaryngologies' manifestations in patients with pulmonary tuberculosis. *Int Arch Otorhinolaryngol* 2010;14(2):156–62.
- [4] Akkara SA, Singhania A, Akkara SAG, Shah A, Adalja M, Chauhan N. A study of manifestations of extrapulmonary tuberculosis in the ENT region. *Indian J Otolaryngol Head Neck Surg* 2014;66(1):46–50.
- [5] Eswaran S, Kumar S, Kumar P. A rare case of primary tuberculous otitis media with Bezold's abscess. *Indian J Otolaryngol Head Neck Surg* 2019;71(Suppl 2):1462–6.
- [6] Maniu AA, Harabagiu O, Damian LO, Ștefănescu EH, Fănuță BM, Cătană A, et al. Mastoiditis and facial paralysis as initial manifestations of temporal bone systemic diseases—the significance of the histopathological examination. *Rom J Morphol Embryol* 2016;57(1):243–8.
- [7] Oh SJ, Yi KI, Lee CH, Cho KS. Primary tuberculous otitis media with effusion. *Am J Otolaryngol* 2015;36(4):575–7.
- [8] Manigandan G, Venkatesh C, Gunasekaran D, Soundararajan P. Tuberculous otitis media and *Staphylococcus aureus* coinfection in a five-year-old boy with miliary tuberculosis. *J Glob Infect Dis* 2013;5(1):26–8.
- [9] Awan MS, Salahuddin I. Tuberculous otitis media: two case reports and literature review. *Ear Nose Throat J* 2002;81(11):792–4.
- [10] Ergün I, Keven K, Sengül S, Kutlay S, Sertcelik A, Ertürk S, et al. Tuberculous otitis media in a renal transplant recipient. *Am J Kidney Dis* 2004;43(6):e1–3.
- [11] Metry AM, Al Salmi I, Al-Abri S, Al Ismaili F, Hala A, et al. Epidemiology and outcome of tuberculosis in immunocompromised patients. *Saudi J Kidney Dis Transpl* 2017;28:806–11.
- [12] Shim TS, Jo KW. Medical treatment of pulmonary multidrug-resistant tuberculosis. *Infect Chemother* 2013;45(4):367–74.
- [13] Hand JM, Pankey GA. Tuberculous otomastoiditis. *Microbiol Spectr* 2016;4(6).
- [14] Wallmer LJ. Tuberculous otitis media. *Laryngoscope* 1953;63:1058–77.
- [15] Bhalla RK, Jones TM, Rotburn MM, Swift AC. Tuberculous otitis media—a diagnostic dilemma. *Auris Nasus Larynx* 2001;28:241–3.
- [16] Liktor B, Liktor B, Liktor Jr B, Kalman J, Horvath B, Sziklai I, et al. Primary tuberculous otitis media of the middle ear cleft: diagnostic and therapeutic considerations. *Eur Arch Otorhinolaryngol* 2014;271:2083–9.
- [17] Bruschini L, Ciabotti A, Berrettini S. Chronic tuberculous otomastoiditis: a case report. *J Int Adv Otol* 2016;12(2):219–21.
- [18] Sens PM, Almeida CI, Valle LO, Costa LH, Angeli ML. Tuberculosis of the ear, a professional disease? *Braz J Otorhinolaryngol* 2008;74:621–7.
- [19] Saunders NC, Albert DM. Tuberculous mastoiditis: when is surgery indicated? *Int J Pediatr Otorhinolaryngol* 2002;65:59–63.
- [20] Kwon M, Choi SW, Chung JW. Roles of an anti-tuberculosis medication and surgery in patients with tuberculous otitis media. *Acta Otolaryngol* 2010;130:679–86.
- [21] Varty S, Vaidya D, Parasram K, Prabhat D, Joshi S. Tuberculous otitis media—are we missing it? *Indian J Otolaryngol Head Neck Surg* 2000;52:143–6.
- [22] Halla RK, Jones TM, Rotburn MM, Swift AC. Tuberculous otitis media—a diagnostic dilemma. *Auris Nasus Larynx* 2001;28:241–3.
- [23] Quaranta N, Petrone P, Michailidou A, Miragliotta L, Santantonio M, Del Prete R, et al. Tuberculous otitis media with facial paralysis: a clinical and microbiological diagnosis—a case report. *Case Rep Infect Dis* 2011. Article ID 932608.
- [24] Hwang GH, Jung JY, Yum G, Choi J. Tuberculous otitis media with facial paralysis combined with labyrinthitis. *Korean J Audiol* 2013;17(1):27–9.