

# Cell Death and Cell Proliferation in Mouse Submandibular Gland during Early Post-irradiation Phase

---

**Bralić, Marina; Muhvić Urek, Miranda; Stemberga, Valter; Golemac, Mijo; Jurković, Slaven; Borčić, Josipa; Braut, Alen; Tomac, Jelena**

*Source / Izvornik:* **Acta medica Okayama, 2005, 59, 153 - 159**

**Journal article, Published version**

**Rad u časopisu, Objavljena verzija rada (izdavačev PDF)**

*Permanent link / Trajna poveznica:* <https://urn.nsk.hr/urn:nbn:hr:184:671192>

*Rights / Prava:* [Attribution 4.0 International](#)/[Imenovanje 4.0 međunarodna](#)

*Download date / Datum preuzimanja:* **2024-04-20**



*Repository / Repozitorij:*

[Repository of the University of Rijeka, Faculty of Medicine - FMRI Repository](#)



## Cell Death and Cell Proliferation in Mouse Submandibular Gland during Early Post-irradiation Phase

Marina Bralic<sup>a\*</sup>, Miranda Muhvic-Urek<sup>b</sup>, Valter Stemberga<sup>c</sup>, Mijo Golemac<sup>a</sup>,  
Slaven Jurkovic<sup>a</sup>, Josipa Borcic<sup>b</sup>, Alen Braut<sup>b</sup>, and Jelena Tomac<sup>a</sup>

<sup>a</sup>Department of Histology and Embryology, Faculty of Medicine, <sup>b</sup>Prosthodontics, School of Dental Medicine,  
<sup>c</sup>Forensic Medicine, Faculty of Medicine, University of Rijeka 51000, Croatia and  
<sup>d</sup>Department of Radiology and Oncology, Clinical Hospital Centre Rijeka, Rijeka 51000, Croatia

The effects of irradiation on different cell compartments in the submandibular gland were analyzed in adult C57BL/6 mice exposed to X-ray irradiation and followed up for 10 days. Apoptosis was quantified using the terminal deoxynucleotidyl transferase (TdT)-mediated dUTP-digoxigenin nick end labeling method (TUNEL). Cell proliferation was detected using immunohistochemistry for proliferating cell nuclear antigen (PCNA). Radiation-induced apoptosis occurred rapidly, reaching a maximum 3 days post-irradiation. The percentage of apoptotic cells increased with the irradiation dose. At day 1 post-irradiation, cell proliferation was significantly reduced in comparison to sham-irradiated controls. After post-irradiation arrest of the cell cycle, proliferation increased in all gland compartments, reaching a maximum at day 6 post-irradiation. The proliferation response corresponded to the dose of irradiation. We suggest that the reason for gland dysfunction could be the coexistence of high apoptotic and proliferative activity in the irradiated gland.

**Key words:** apoptosis, early post-irradiation phase, proliferation, submandibular gland

**T**reatment of oral carcinomas commonly involves radiotherapy, using either external beam irradiation alone (external radiotherapy) or combined with brachytherapy (or interstitial therapy), where radioactive sources in the form of iridium needles or pellets are implanted in or close to the neoplasm [1]. The exposure of salivary glands during radiotherapy leads to secretory hypofunction and several complications, including mucositis, xerostomia, dysphagia, oral infections, oesophagitis, and gustatory dysfunction [2-5]. Although the effects of irradiation have been recognized as a significant clinical problem for more than 90 years, the mechanism

of these effects remains unknown, and no adequate prevention or treatment is yet available.

Because of the slow turnover rates of their cells, the salivary glands are expected to be relatively radio-resistant. Yet the changes in the quality and composition of the saliva that occur shortly after radiotherapy indicate that the gland tissue is an acutely responding tissue [5, 6].

These nondividing cells manifest apoptosis that appears to be responsible for salivary gland impairment. Apoptosis induced by irradiation is hypothesized to be one of the major causes of acute radiation injury [7, 8]. Apoptosis and acute impairment have been investigated in monkeys and rats [8, 9]. However, little is known about radiation-induced apoptosis in mice. Most researchers have studied saliva production and have focused their

analysis on radioprotection of the gland, but no data about apoptotic activity in mouse submandibular glands are available [10, 11].

The complex relationship between cell proliferation, differentiation, and apoptosis is a cardinal feature in maintenance of the normal architecture and function of the submandibular gland. Repopulation of tissue is an important feature of the recovery of radiation-induced injury.

Limited data are available on the proliferation of submandibular glands. Theuring *et al.* [12] have investigated the increase in the proliferation activity of salivary glands after irradiation, but their study provides only limited information because all gland compartments were not included in the study. The question arises as to whether replacement takes place in all gland compartments. To fully understand the repopulation of damaged salivary glands, it is necessary to examine the proliferation of each structural component, including acinar cells, granular convoluted tubule cells, and intercalated duct cells. Furthermore, an attempt has been made to determine the radiation-related changes in proliferation activity.

The role of apoptosis and proliferation in the submandibular gland, which differs histologically from the parotid gland, has received little attention.

The present study was undertaken to clarify the role of apoptosis and proliferation in mouse submandibular gland and to determine the relationship of cell death and cell proliferation during the early post-irradiation phase.

## Materials and Methods

**Animals.** Inbred 8 to 10-week-old male C57BL/6 mice were obtained from a colony maintained at the Medical Faculty, University of Rijeka. Mice were kept under standard housing conditions (laboratory rodent chow and water *ad libidum* and a 12-hr light-day cycle). The animal experiments were carried out in accordance with Medical Faculty Policies and Guidelines for the Care and Use of Laboratory Animals. All efforts were made to minimize animal suffering.

**Irradiation.** The X-ray irradiation was carried out on a medical linear accelerator (6 MV; Mevatron MD-2, Siemens Medical Laboratories Inc., Concord, CA, USA) at a dose rate of 191 cGy/min. The total irradiation field size was asymmetrical ( $15 \times 0 \times 3$  cm), and the distance from the source was 100 cm. The animals were irradiated while under general anesthesia. Anesthesia was induced by intraperitoneal injection of

sodium-pentobarbital (40 mg/kg body weight). Each mouse was locally irradiated in the region of the head and neck by a single dose exposition of 7.5 or 15 Gy. We used radiation doses that were within the range of those used in previous studies and that were expected to cause significant gland impairment [13-15]. Control animals were anesthetized and sham-irradiated.

**Experimental design.** Mice were randomly divided into 3 groups: I-Unirradiated control (sham-irradiated) (N = 20); II-Irradiated mice treated with single dose of 7.5 Gy (N = 20); III-Irradiated mice treated with single dose of 15 Gy (N = 27). Five mice from each group were sacrificed at 1, 3, 6, and 10 days post-irradiation [15].

**Body weight.** The body weights of all animals were determined prior to irradiation and as indicated in the experimental design. Relative body weights were calculated by the formula:  $W_t = (w_x/w_o - 1) \times 100\%$ , where  $W_t$  is the change in body weight observed at a certain time after irradiation treatment, and  $w_o$  and  $w_x$  are the body weights at the start of the experiment (day 0) and on specific days after treatment, respectively.

**Tissue preparation.** The submandibular glands were fixed in 4% paraformaldehyde and processed for paraffin embedding according to a standard procedure. Serial sections with a thickness of  $2 \mu\text{m}$  were prepared and stained with hematoxylin-eosin (HE).

**TUNEL.** To detect apoptotic cells, the TUNEL method was performed using the "In Situ Cell Death Detection Kit-POD" (Roche Diagnostics GmbH, Mannheim, Germany) [16]. The sections were incubated with TdT and fluorescein dUTP without proteinase K pretreatment. After PBS rinsing, anti-fluorescein-peroxidase antibody was applied, and the reaction was visualized by 3,3'-diaminobenzidine (DAB) (Sigma Chemical Company, St. Louis, MO, USA). Sections were counterstained with hematoxylin. Negative control sections were incubated with distilled water in the absence of TdT.

**Immunohistochemistry.** To examine proliferation, sections were incubated with anti-PCNA monoclonal antibody (DAKO A/S, Glostrup, Denmark), a marker of proliferating cells [17], followed by biotinylated rabbit anti-mouse polyclonal antibody (DAKO A/S, Glostrup, Denmark). Sections were then incubated with streptavidin-biotin-peroxidase complex (Boehringer, Mannheim, Germany) and visualized by 3-amino-9-ethyl-carbazol substrate, (AEC) (DAKO, Carpinteria, CA, USA). Hematoxylin was used for counterstaining.

Negative control sections were incubated with PBS in the absence of primary antibody.

**Quantification of apoptotic index.** The apoptotic index (AI) was determined by calculating the percentage of TUNEL positive cells per animal using the following method [18]. To ensure the objectivity of the analysis, the evaluation was carried out by 2 independent observers (M M-U, MB). Five sections were randomly chosen for each animal. Approximately 1000 cell nuclei from each cell population (acinar cells, granular convoluted tubule (GCT) cells, intercalated duct (ID) cells) were counted for each section at  $400\times$  magnification (BX 40, Olympus, Optical Co Ltd., Tokyo, Japan), and the number of apoptotic nuclei is expressed as a percentage of the total. Striated ducts were omitted from the study since too few of them were examined to provide useful information. For control values, animals from days 1 and 10 were used, and data are expressed as an average.

**Quantification of proliferative index.** Quantification of the proliferative index (PI) was carried out as explained above instead that cell nuclei were stained with PCNA antibody [18].

**Statistical analysis.** The data values are presented as mean value  $\pm$  standard deviation (SD). The statistical significance of differences was determined by two-way analysis of variance, followed by the Tukey's honestly significant difference (HSD) post hoc test. The differences were considered to be statistically significant if  $P < 0.05$ .

## Results

**Survival period.** With the exception of the 15 Gy group, all 7.5 Gy-irradiated and control mice survived the whole study period. In the group irradiated with 15 Gy, 7 of 27 mice (25.9% mortality) died within 10 days post-irradiation.

**Total body weight.** Irradiated animals exhibited a dose-dependant reduction in body weight. The extent of body weight gain was the greatest for control mice and the least for mice irradiated with 15 Gy. The body weight of control mice increased throughout the experimental period, in contrast to the 7.5 Gy-irradiated mice whose body weight decreased until day 3. After day 3, these mice began to gain weight. Mice irradiated with 15 Gy began to gain weight at day 6 post-irradiation. A significant difference in body weight was observed between control and 15 Gy-irradiated animals at days 3,

6, and 10 post-irradiation (Fig. 1). Also, a significant difference was detected among irradiated groups at days 6 and 10 post-irradiation ( $P < 0.001$  for both time points).

**Pathohistology of submandibular gland post-irradiation.** In irradiated mice, pathohistological changes were observed in both irradiated groups, and these changes were aggravated with the higher irradiation dose. The first changes were expressed as vacuolization of acinar cells, and pyknotic nuclei were noted 24h post-irradiation. Predominantly single cells were affected. Injury of secretory tissue was maximal at day 6 post-irradiation. Lysis of entire acini and GCT was observed. A few acinar cells showed cytoplasmic vacuoles. Salivary glands irradiated with a dose of 7.5 Gy showed recovery of gland morphology over a period of 10 days, whereas no significant recovery was noticed with an irradiation dose of 15 Gy (data not shown).

**Apoptosis.** In all gland compartments (acinar cells, ID cells, and GCT cells), apoptotic activity was seen to increase with a higher dose of irradiation. Generally, the following was observed: AI increased rapidly up to day 3 post-irradiation when it reached a maximum. At day 6 in acinar cells irradiated with 15 Gy, similar levels of AI were maintained, while in other cell compartments the AI levels fell. AI declined by day 10

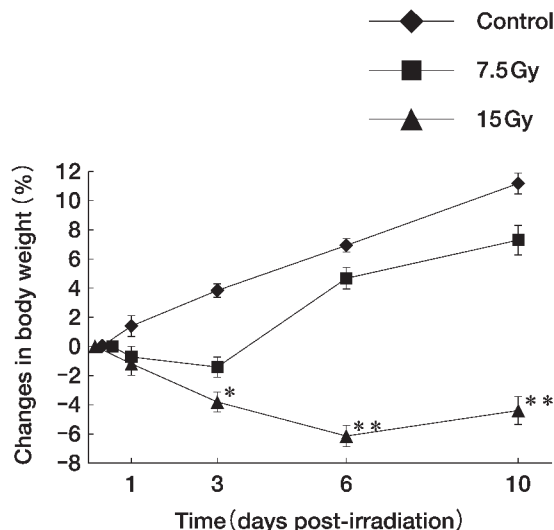
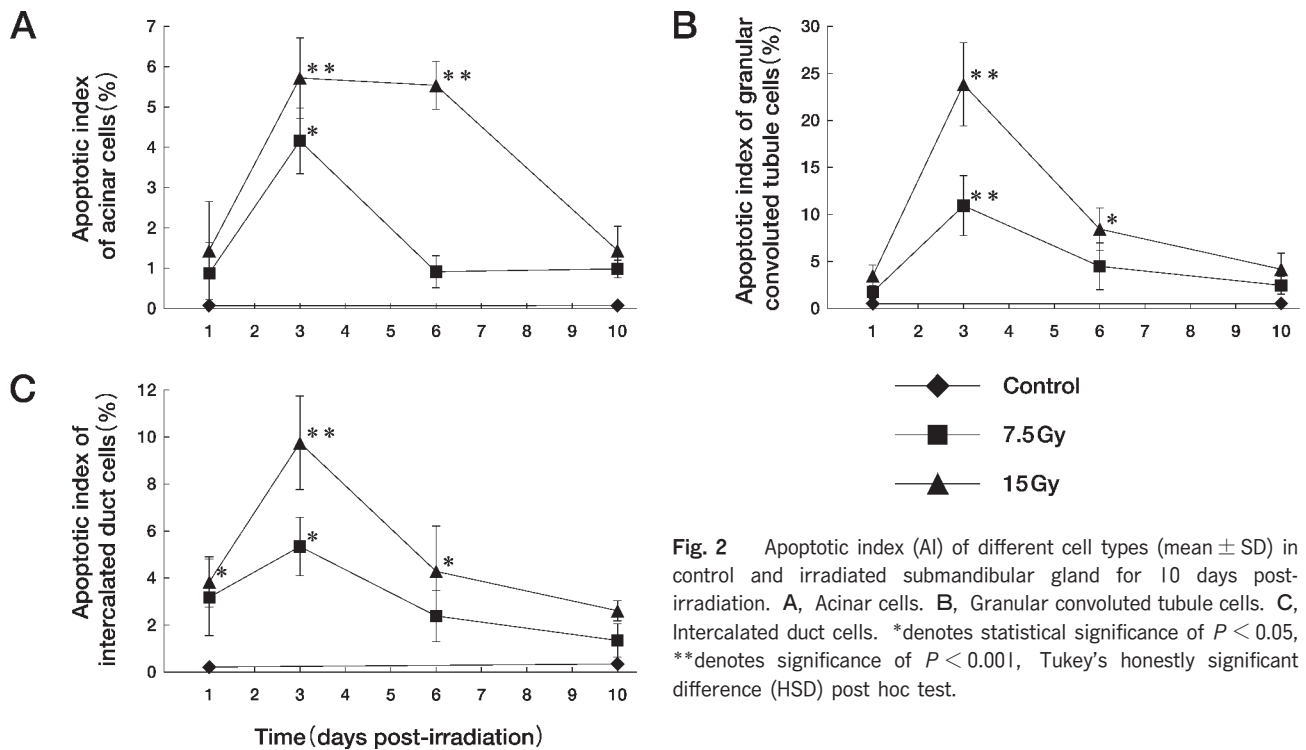


Fig. 1 Changes in body weight in X-irradiated mice. Values are given as means  $\pm$  SD. Body weights at the beginning of the experiment were determined as 0%, and changes were calculated by the formula described in the text. \*denotes statistical significance of  $P < 0.05$ , \*\*denotes significance of  $P < 0.001$ , Tukey's honestly significant difference (HSD) post hoc test.

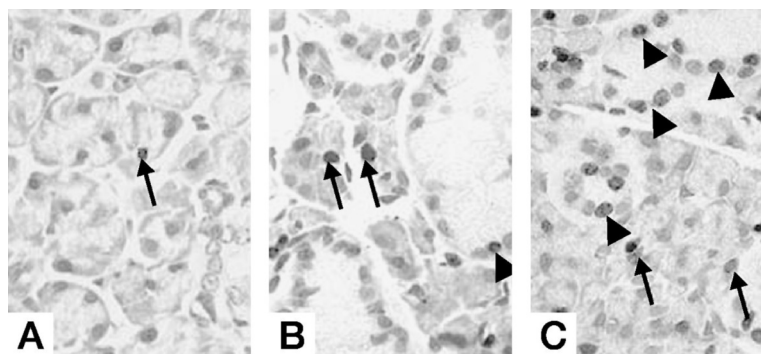
post-irradiation, at which point almost no apoptotic nuclei could be observed (Figs. 2 and 3). Apoptotic activity was the greatest in GCT cells (Fig. 2B) followed by ID cells (Fig. 2C), while mucous acinar cells (Fig. 2A) were relatively resistant to apoptosis. At day 3 post-irradiation, a significant difference in AI between the 2 irradiated groups was observed ( $P = 0,046$  in acinar cells;  $P < 0.001$  in GCT cells;  $P = 0.005$  in ID cells). The

difference was also detected at day 6 post-irradiation in acinar cells ( $P < 0.001$ ) and in GTC cells ( $P = 0.003$ ).

**Proliferation.** After the initial decline in the number of proliferating cells observed on day 1, there was a subsequent increase in proliferation. The proliferative index increased rapidly by day 6 post-irradiation. At day 6 in all cell types, maximum labeling was observed. Afterwards, there was a labeling decrease, and by day 10



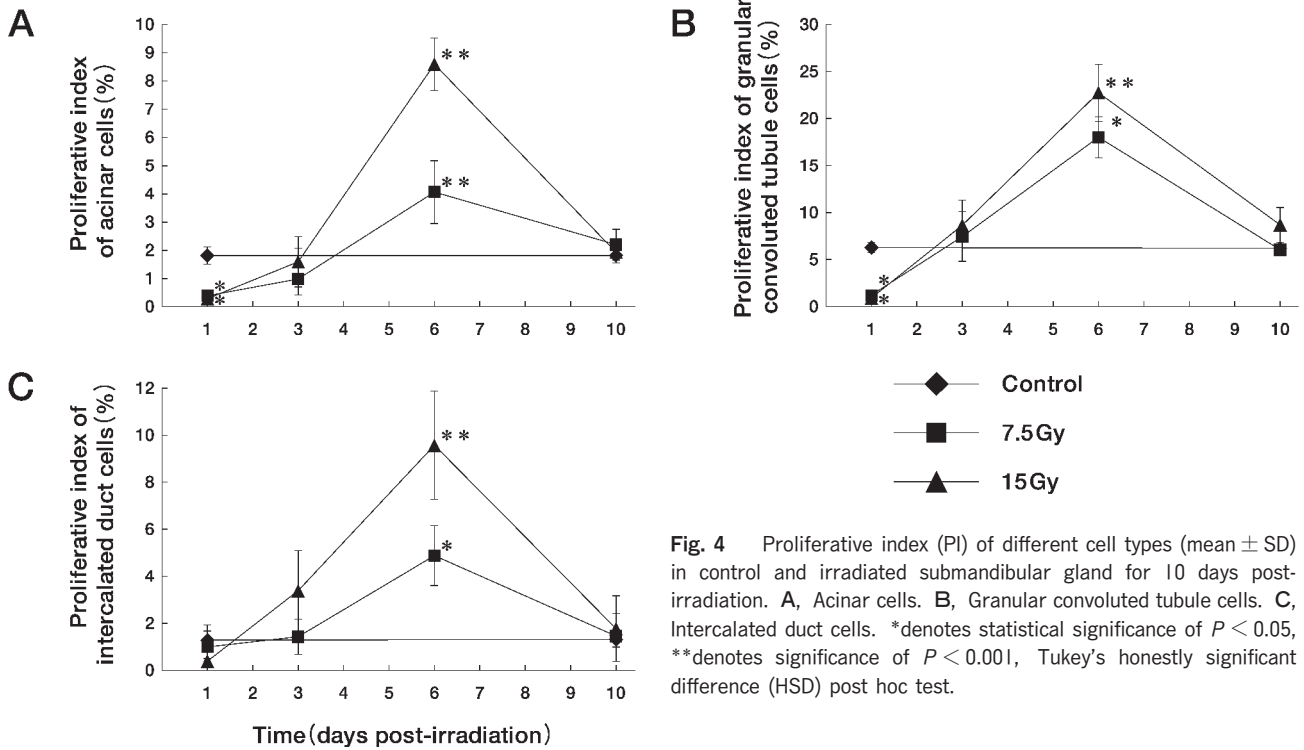
**Fig. 2** Apoptotic index (AI) of different cell types (mean  $\pm$  SD) in control and irradiated submandibular gland for 10 days post-irradiation. **A**, Acinar cells. **B**, Granular convoluted tubule cells. **C**, Intercalated duct cells. \*denotes statistical significance of  $P < 0.05$ , \*\*denotes significance of  $P < 0.001$ , Tukey's honestly significant difference (HSD) post hoc test.



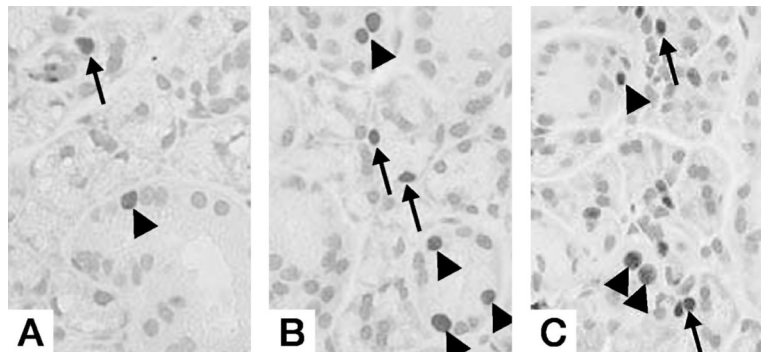
**Fig. 3** TUNEL staining. **A**, Unirradiated control submandibular gland. Rare TUNEL positive cell (arrow). **B**, 7.5 Gy-irradiated gland at day 3 post-irradiation. TUNEL positive cells are identified in acini (arrows) and GCT cells (arrowhead). **C**, 15 Gy-irradiated gland at day 3 post-irradiation. Many acinar cells (arrows) and GCT cells (arrowheads) show TUNEL positivity. Magnification: 400  $\times$ .

it was similar to control animals in all gland compartments (Figs. 4 and 5). The proliferation response was equivalent to the radiation dose; therefore, higher proliferation was observed in the group irradiated with a dose of 15 Gy than in that irradiated with 7.5 Gy group. On day 1, in both irradiated groups PI statistically declined in acinar and GTC cells, in contrast to ID cells where it was

similar to the control group. At day 6 post-irradiation, all cell compartments demonstrated significantly higher PI than the control group. The highest PI was observed in GCT cells (Fig. 4B), while ID cells (Fig. 4C) and acinar cells (Fig. 4A) showed an almost identical proliferation capacity. At day 6 post-irradiation, a significant difference in PI between the 2 irradiated groups was



**Fig. 4** Proliferative index (PI) of different cell types (mean  $\pm$  SD) in control and irradiated submandibular gland for 10 days post-irradiation. **A**, Acinar cells. **B**, Granular convoluted tubule cells. **C**, Intercalated duct cells. \*denotes statistical significance of  $P < 0.05$ , \*\*denotes significance of  $P < 0.001$ , Tukey's honestly significant difference (HSD) post hoc test.



**Fig. 5** PCNA staining. **A**, Unirradiated control submandibular gland. A few PCNA positive cells are seen in acinar (arrow) and GCT cells (arrowhead). **B**, 7.5 Gy-irradiated gland at day 6 post-irradiation. More acinar (arrows) and GCT cells (arrowheads) show PCNA positivity. **C**, 15 Gy-irradiated gland at day 6 post-irradiation. Many PCNA positive cells are detected in acinar (arrows) and GCT cells (arrowheads). Magnification: 400  $\times$ .

observed ( $P < 0.001$  in acinar and ID cells).

## Discussion

In irradiated submandibular glands, an imbalance between gland morphology and gland function has been observed. It remains unresolved why, with no prominent microscopic changes, gland function is impaired. Our study provides combined data regarding apoptosis and proliferation in irradiated submandibular gland. Until now, investigations have focused on 1 process only.

**Body weight.** Our results indicating that body weight is dose-dependent are in accordance with those of authors who have performed similar experiments using a rat model [13, 19, 20]. The possible cause of weight loss could be oropharyngeal syndrome. Irradiated mice were starving due to ulceration of the tongue and soft palate, which could explain their poor food intake.

**Apoptosis.** In the present study, for the first time, the TUNEL method was used to identify apoptotic cells in irradiated gland tissue. Until now, radiation-induced apoptosis was analyzed according to morphology after HE staining.

According to our study, ionizing irradiation triggers apoptosis in all gland compartments, but the extent is not identical for all cell types. GCT cells were the most sensitive, followed by ID cells and mucous acinar cells. Because GCT cells represent the serous portion of mouse submandibular gland and serous cells are far more radiosensitive than mucous cells, our finding was expected. Furthermore, in both irradiated groups the labeling index was dose-dependent and the maximum was reached at day 3 post-irradiation. The results from this study are not consistent with the results of Paardekooper *et al.* [9] and Peter *et al.* [21], who have reported lower apoptotic activity. It must be mentioned that the indicated authors based their analysis not on the TUNEL method, but on observation of aberrant nuclei in HE staining.

In a study on radiation-induced damage, Shinohara *et al.* [22] compared techniques on apoptosis (*e.g.* HE and TUNEL assay) and concluded that 66% of apoptotic cells were detected with HE staining, confirming that the TUNEL method is more sensitive in detecting cells in the process of apoptosis. Therefore, our result showing higher apoptotic activity can be applied to different techniques used for detecting apoptosis.

**Proliferation.** Tissue homeostasis requires a balance between proliferation and death of cells via

apoptosis. In former studies, an initial drop in cell proliferation was observed in the acute post-irradiation phase [23]. We presume that cell arrest observed in all cell types at day 1 post-irradiation can be attributed to delay of the S phase of the cell cycle induced by irradiation. Our data are in agreement with those of Peter *et al.* [23], who reported a depleted labeling index soon after irradiation. After the initial decline in proliferation, it subsequently rises and reaches a maximum at day 6 post-irradiation in all parenchymal cell types. In the present study, the proliferation activity in animals irradiated with 15 Gy was higher than that in the group irradiated with 7.5 Gy.

The present results indicate that proliferation is taking place in all gland compartments. The highest proliferation was observed in GCT cells, while acinar and ID cells exhibited lower proliferation capacity. Peter *et al.* [23] have suggested that replacement of lost acinar and ductal cells occurs by differentiation of progenitor cells situated in ID cells. According to our study, proliferation of progenitor cells is not sufficient to replenish all cell types in irradiated glands.

Repopulation of irradiated glands can be explained if results observed by Danny *et al.* [24] are considered first. They indicate that self-proliferation of cells plays a significant role in some compartments and that approximately 70% of the cell population is maintained by self-proliferation, as opposed to 30% by differentiation from progenitor cells.

Our data confirms the mutual existence of 2 processes in irradiated glands: apoptosis and proliferation. Apoptosis was followed by proliferation in all gland compartments during the early post-irradiation phase.

In conclusion, these findings suggest that the reason for gland dysfunction could be the coexistence of high apoptotic and proliferative activity in irradiated glands.

## References

1. Store G, Evensen J and Larheim TA: Osteoradionecrosis of the mandible. Comparison of the effects of external beam irradiation and brachytherapy. *Dentomaxillofac Radiol* (2001) 30: 114-119.
2. Bergonie J and Speder F: Surquelques formes de reactions prococes apres des irradiation. *Arch Elect Med* (1911) 19: 241-245.
3. Silverman S Jr: Oral cancer: complications of therapy. *Oral Surg Oral Med Oral Pathol Oral Radiol Endod* (1999) 88: 122-126.
4. Meraw SJ and Reeve CM: Dental considerations and treatment of the oncology patient receiving radiation therapy. *J Am Dent Assoc* (1998) 129: 201-205.
5. Vissink A, Burlage FR, Spijkervet FK, Jansma J and Coppes RP:

- Prevention and treatment of the consequences of head and neck radiotherapy. *Crit Rev Oral Biol Med* (2003) 14: 213-225.
6. Nagler RM: The enigmatic mechanism of irradiation-induced damage to the major salivary glands. *Oral Dis* (2002) 8: 141-146.
  7. Stephens LC, Schultheiss TE, Ang KK and Peters LJ: Pathogenesis of radiation injury to the salivary glands and potential methods of prevention. *Cancer Bull* (1989) 41: 106-109.
  8. Stephens LC, Schultheiss TE, Price RE, Ang KK and Peters LJ: Radiation apoptosis of serous acinar cells of salivary and lachrymal glands. *Cancer* (1991) 67: 1539-1543.
  9. Paardekooper GM, Cammelli S, Zeilstra LJ, Coppes RP and Konings AW: Radiation - induced apoptosis in relation to acute impairment of rat salivary gland function. *Int J Radiat Biol* (1998) 73: 641-648.
  10. Vissink A, Kalicharan D, 's-Gravenmade EJ, Jongebloed WL, Ligeon EE, Nieuwenhuis P and Konings AW: Acute irradiation effects on morphology and function of rat submandibular glands. *J Oral Pathol Med* (1991) 20: 449-456.
  11. Nagler RM and Laufer D: Protection against irradiation-induced damage to salivary glands by adrenergic agonist administration. *Int J Radiat Oncol Biol Phys* (1998) 40: 477-481.
  12. Theuring F, Reichel G and Schmidt W: The effect of x-irradiations on proliferation kinetics of rat salivary glands. *Radiobiol Radiother (Berl)* (1976) 17: 397-404.
  13. Nagler RM, Baum BJ and Fox PC: Effects of X irradiation on the function of rat salivary glands of 3 and 40 day. *Radiat Res* (1993) 136: 392-396.
  14. Peter B, Van Waarde MA, Vissink A, 's-Gravenmade EJ and Konings AW: The role of secretory granules in radiation-induced dysfunction of rat salivary glands. *Radiat Res* (1995) 141: 176-182.
  15. Nagler RM: Short - and long - term functional vs morphometrical salivary effect of irradiation in a rodent model. *Anticancer Res* (1998) 18: 315-320.
  16. Gorczyca W, Gong J and Darzynkiewicz Z: Detection of DNA strand breaks in individual apoptotic cells by the in situ terminal deoxynucleotidyl transferase and nick translation assays. *Cancer Res* (1993) 53: 1945-1951.
  17. Roos G, Landberg G, Huff JP, Houghten R, Takasaki Y and Tan EM: Analysis of the epitopes of proliferating cell nuclear antigen recognized by monoclonal antibodies. *Lab Invest* (1993) 68: 204-210.
  18. Takahashi S, Shinzato K, Nakamura S, Domon, Yamamoto T and Wakita M: Cell death and cell proliferation in the regeneration of atrophied rat submandibular glands after duct ligation. *J Oral Pathol Med* (2004) 33: 23-29.
  19. Vissink A, 's-Gravenmade EJ, Ligeon EE and Konings WT: A functional and chemical study of radiation effects on rat parotid and submandibular/sublingual gland. *Radiat Res* (1990) 124: 259-265.
  20. Coppes RP, Vissink A, Zeilstra LJ and Konings AW: Muscarinic receptor stimulation increases tolerance of rat salivary glands function to radiation damage. *Int J Radiat Biol* (1997) 72: 615-625.
  21. Peter B, Van Waarde MA, Vissink A, 's-Gravenmade EJ and Konings AW: The role of secretory granules in the radiosensitivity of rat salivary gland acini - A morphological study. *Radiat Res* (1994) 140: 419-428.
  22. Shinohara C, Gobbel GT, Lamborn KR, Tada E and Fike JR: Apoptosis in the subependyma of young adult rat after single and fractionated doses of X-rays. *Cancer Res* (1997) 57: 2694-2702.
  23. Peter B, Van Waarde MA, Vissink A, 's-Gravenmade EJ and Konings AW: Radiation-induced cell proliferation in the parotid and submandibular gland of the rat. *Radiat Res* (1994) 140: 257-265.
  24. Denny PC, Chai Y, Klauser DK and Denny PA: Parenchymal cell proliferation and mechanisms for maintenance of granular duct and acinar cell populations in adult mouse submandibular gland. *Anat Rec* (1993) 235: 475-485.