

Gallbladder Expression of Metallothionein I/II in Cholecystolithiasis. A Pilot Study

Grbas, Harry; Jakovac, Hrvoje; Kovač, Dražen; Radošević-Stašić, Biserka

Source / Izvornik: **Annual Research & Review in Biology**, 2015, 6, 278 - 287

Journal article, Published version

Rad u časopisu, Objavljena verzija rada (izdavačev PDF)

<https://doi.org/10.9734/ARRB/2015/15587>

Permanent link / Trajna poveznica: <https://urn.nsk.hr/urn:nbn:hr:184:244249>

Rights / Prava: [Attribution 4.0 International](#)/[Imenovanje 4.0 međunarodna](#)

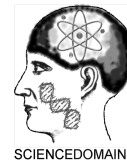
Download date / Datum preuzimanja: **2024-12-26**



Repository / Repozitorij:

[Repository of the University of Rijeka, Faculty of Medicine - FMRI Repository](#)





Gallbladder Expression of Metallothionein I/II in Cholecystolithiasis. A Pilot Study

Harry Grbas^{1*}, Hrvoje Jakovac^{2*}, Dražen Kovač³
and Biserka Radošević-Stašić^{2**}

¹Department of Surgery, Clinical Hospital Center, Medical Faculty, University of Rijeka, Croatia.

²Department of Physiology and Immunology, Medical Faculty, University of Rijeka,
B. Branchetta 22, 51000 Rijeka, Croatia.

³Department of Pathology, Medical Faculty, University of Rijeka, Croatia.

Authors' contributions

Study was carried out in collaboration between all authors. Author HG conducted the laparoscopic cholecystectomies and collected the samples of gallbladders. Author HJ performed the immunohistochemical analyses. Author DK performed the pathohistological analyses and author BRS designed the study and wrote the manuscript. All authors read and approved the final manuscript.

Article Information

DOI: 10.9734/ARRB/2015/15587

Editor(s):

(1) George Perry, University of Texas at San Antonio, USA.

Reviewers:

(1) Kim Vaiphei, Histopathology, PGIMER, Chandigarh, India.

(2) Lau Wan Yee, Joseph, The Chinese University of Hong Kong, China.

Complete Peer review History: <http://www.sciencedomain.org/review-history.php?iid=799&id=32&aid=7950>

Original Research Article

Received 6th December 2014
Accepted 5th January 2015
Published 29th January 2015

ABSTRACT

Aims: To investigate the expression of metallothioneins (MTs) and free zinc content in gallbladder associated with cholecystolithiasis.

Study Design: Gallbladder tissue samples were obtained from patients, subjected to laparoscopic cholecystectomy, owing to the cholecystolithiasis, verified by hematological examination and by ultrasonography. Operations were performed in clinical stable phase of gallstone disease.

Place and Duration of Study: Department of Surgery, Clinical Hospital Center, Departments of Physiology and Immunology and Department of Pathology, Medical Faculty, University of Rijeka, between June 2011 and June 2012.

Methodology: In 25 collected gallbladders the degree of inflammation was classified as subacute (SA) or chronic cholecystitis (CC), according to the standard pathohistological analysis and intensity of NF- κ B expression. The tissue expression of MT-I/II isoforms and free zinc content were visualized by immunohistochemistry, using the monoclonal anti-MT I+II antibodies and zinc

*Corresponding author: E-mail: biserkars@medri.uniri.hr;

fluorophore-Zinquin. The cell-based staining quantification was performed by Cell F v3.1 software.

Results: The data have shown that in 20 patients out of 25 patients the gallstones induced the CC with upregulation of NF- κ B in gallbladder epithelium, as well as that high inflammation was followed by overexpression MTs and accumulation of Zn. in 15 and 12 out of 20 patients, respectively. Furthermore, histomorphometric analysis revealed that the average grey values for MT I/II in CC arose from 49.8 +/- 3.3 (in SC) to 195.4 +/- 15.5 (in epithelial cells) and from 62.3 +/- 21.0 to 194.8 +/- 20.1 (in stromal cells) (P<0.01). Similarly, average values for zinc ions increased from 25.6 +/- 7.4 (in SC) to 118.8 +/- 5.7 (in epithelial cells). Besides, in areas of high inflammation several CD3+ cells were found in contact with MT+ epithelial, endothelial and monocyte-like cells.

Conclusion: The data point to high local activation of MT/zinc network in chronic cholecystitis associated by gallstones, emphasizing its regulatory functions in inflammatory environment.

Keywords: Cholecystolithiasis; cholecystitis; metallothionein I/II; labile zinc; NF- κ B; inflammation; immune response.

1. INTRODUCTION

Metallothioneins (MTs) are phylogenetically old cysteine-rich proteins, which may be found in all eukaryotes and some prokaryotes. Owing to high affinity for physiological metals, such as zinc and copper, they are critical components of zinc-finger transcription factors and other regulatory proteins involved in cell growth and multiplication. Besides, providing cytoprotective action against toxic heavy metals and oxidative damages of DNA, proteins, and lipid membrane structures, they participate in anti-apoptotic and anti-inflammatory pathways, as well as in immune regulation and carcinogenesis [1-6]. The issue is covered by more than thousands of articles published from the discovery of MT in 1957 by Margoshe and Vallee [7] (reviewed recently by Capdevila and coworkers [8]). These data also show that various MTs isoforms and subtypes may have cell specific functions that occasionally differ in animals and humans [3,9-11].

Since, the clinical observations about the functions of MTs in inflammation are still limited, in this study we attempted to visualize the expression of MT-I/II in gallbladder during the gallstones disease, taking into account the evidence that cholecystolithiasis is often followed by local inflammation [12,13], as well as that MT excretion from liver to bile may affect the biliary levels of calcium and other trace elements [14,15].

The data clearly showed that the expression of MTs in gallbladder correlated with the intensity of cholecystitis and NF κ B activation, as well as with the expression of free Zn⁺⁺ and infiltration of CD3+ lymphocytes, implying that metalloproteins might have regulatory role in local inflammatory processes during the gallstone disease.

2. MATERIALS AND METHODS

2.1 Subjects

Samples of gallbladders were obtained from 25 patients subjected to elective laparoscopic cholecystectomy owing to the presence of gallstones. Cholecystolithiasis was verified by ultrasonography and by hematological analyses, pointing to cholestasis (hyperbilirubinemia and elevation of alkaline phosphatase). Patients underwent laparoscopic cholecystectomy when the attack of acute cholecystitis subsided. Operations were made by a standardized technique in general anesthesia, as we previously described [16]. Mean age of patients was 55.5 years (range 28 to 82) for 21 women and 4 men. The study protocol was consistent with the ethical guidelines of the Helsinki Declaration and was approved by Ethical Committee of the local Clinical Hospital Center and Medical Faculty and University.

2.2 Tissue Preparation

The tissue samples of gallbladders were deliberated from gallstones, fixed in 10% formalin, embedded in paraffin wax and cut into sections of 4 μ m using HM 340 E microtome (Microtom, Germany). After standard haematoxylin and eosin (H&E) staining the intensity of local inflammation was determined and classified as subacute and chronic cholecystitis, depending on the presence of edema, necrosis, lymphatic cells infiltration and degree of tissue disintegration. The pathohistological diagnosis was confirmed by independent review of two pathologists. All the gallbladders have a uniform fixation and dissection protocol prior to histopathological examination.

2.3 Immunohistochemistry

Immunohistochemistry was performed on formalin-fixed paraffin-embedded tissues, after heat induced epitope retrieval, using the DAKO EnVision+System, Peroxidase (DAB) kit (DAKO Corporation, USA), as previously described [17,18]. Endogenous peroxidase activity was eliminated with peroxidase block. MT I+II antigens were detected by monoclonal anti-MT I+II antibody (clone E9; DakoCytomation, USA), diluted 1:50 in phosphate-buffered saline supplemented with bovine serum albumin. The specificity of the reaction was confirmed by substitution of antigen-specific antibody with mouse irrelevant IgG1 kappa immunoglobulin (clone DAK-G01; Dako, USA), used in the same conditions and dilutions as a primary antibody.

The same protocol was used for the visualization of nuclear factor kappa B (NF- κ B) immunoreactivity after the application of anti-NF κ B p65 monoclonal antibodies, in the dilutions of 1: 1000 (AbcamInc; Cambridge, MA). Dehydrated slides were mounted for light microscopy evaluation.

For the detection of CD3+ T lymphocytes and T lymphocytes expressing MT I/II, the single or dual fluorescent labeling of cells was used. The tissue sections were submitted to heat induced antigen retrieval. The nonspecific binding was blocked by one-hour incubation with 1% BSA in PBS at room temperature. MT and CD3 expression were detected by primary monoclonal antibodies and secondary Alexa Fluor 488 goat anti-mouse and Alexa Fluor 555 goat anti-rabbit antibodies (Abcam) diluted 1:500. Nuclei of the cells were stained with DAPI (Invitrogen) diluted 1:1000 in PBS, after incubation for 5 minutes at room temperature. Finally, slides were washed, mounted with Mowiol (Sigma-Aldrich) and analyzed under fluorescent microscope.

2.4 Free Zn Ions Labeling

For labeling of free zinc ions the specific zinc fluorophore Zinquin (Zinquin ethyl ester, Sigma-Aldrich) was used, as previously described [19]. The sections were analyzed on fluorescent microscope under UV light. Negative control slides were incubated in the same conditions with PBS alone.

2.5 Immunohistochemical Staining Quantification

Immunohistochemical staining quantification of MT expression and free Zn ions levels was performed using Cell F v3.1 software (Olympus Soft Imaging Solutions). Captured images were subjected to intensity separation. They were subsequently inverted, resulting in grey scale images with different intensity range, depending on the strength of immunohistochemical signals. Regions of interest were set up to cover the cytoplasm of immunopositive cells to measure grey intensity. Twenty regions of interests were analyzed per field (400 x) in the ten fields per microscopic slide of tissue samples in an evaluator-blinded manner. The analysis was made in 3 gallbladder tissue samples and the data were expressed as average mean \pm SE per grade of cholecystitis group.

In groups of subacute and chronic cholecystitis the staining intensity of MT was also recorded by an ordered metric scale as negative-0, weakly (+), moderately (++) or highly (+++) positive (more than 50% of cells was stained).

2.6 Statistical Analysis

Statistical analyses were performed using MedCalc for Windows, version 12.2.1.0 (MedCalc Software, Ostend, Belgium). Differences between groups were assessed by Friedman one-way analysis of variance (ANOVA), by Chi-square analysis and by Students t-test. P values less than 0.05 were considered statistically significant.

3. RESULTS

3.1 Metallothionein I/II and Free Zinc Ions Expression in Chronic Cholecystitis

Samples of gallbladder were obtained by laparoscopic cholecystectomy from 25 patients suffering of cholelithiasis, as we previously described [16]. The intensity of local inflammation, associated potentially with the presence of gallstones, was then determined by standard pathohistological analysis in paraffin tissue sections stained with HE and by immunohistochemical detection of NF- κ B activation that might occur upon release of proinflammatory cytokines and microbial products, such as tumor necrosis factor alpha (TNF- α), IL-1 β , and lipopolysaccharide (LPS), or

upon environmental stress. In these two groups, showing different grade of inflammation, we then compared MT/zinc status in the gallbladder. On such a way we also ensured that all tissue samples were removed from patients under the similar operative conditions and partially compensated our inability to obtain the samples of healthy gallbladders from humans. Regarding the latter, it should be, however, emphasized that MT expression was found to be completely negative in tissue of normal gallbladder, obtained by cholecystectomy, after its traumatic perforation or from patients undergoing the transplantation of the liver [20].

The data showed that cholecystolithiasis was, only in 5 patients, followed by low grade of inflammation, characterized by intact epithelium and absence of NF- κ B expression (Fig. 1A a, b) and by inflammatory cell infiltrates, expressing nuclear NF- κ B staining (Fig. 1A c). In contrast, in all other patients (N=20) gallstones induced tissue changes that might be characterized as chronic cholecystitis (atrophic mucosa, ulceration, capillary congestion and numerous aggregates of mononuclear cells) (Fig. 1C a, b). Moreover, in these gallbladder samples, a high NF- κ B expression was found in epithelial cells, as well as in numerous mononuclear lymphatic cells in the stroma (Fig. 1B a, b, c) implying that during the chronic cholecystolithiasis the activation of canonical NF- κ B pathway was induced by proinflammatory cytokine receptors and pattern recognition receptors, as it might occur during the chronic inflammation in intestinal epithelial tissues [21].

Subsequent, immunohistochemical analyses in these groups also showed that the expressions of MTs and free zinc ions correlated with the intensity of tissue inflammation. Thus, in subacute cholecystitis the MT I/II were expressed only locally on some cells in stroma (Fig. 1A f), while in chronic cholecystitis they were highly upregulated in areas expressing high NF- κ B activity, such as gallbladder epithelium (Fig. 1B d, e), mononuclear lymphatic and stromal cells and vascular endothelium (Fig. 1B f). Moreover, only in chronic cholecystitis the intensive accumulation of free Zn⁺⁺ was found in MT-positive areas (Fig. 1B g-i), pointing to putative metal-dependent, regulatory activity of MT I/II in chronic pro-inflammatory environment. The data were confirmed also by the immunohistochemical staining quantification analysis, showing that the

MT expression in epithelium and stroma in chronic cholecystitis was significantly greater than that in subacute cholecystitis (average grey values arose from 49.8 +/- 3.3 (in SC) to 195.4 +/- 15.5 (in epithelial cells) and from 62.3 +/- 21.0 to 194.8 +/- 20.1 (in stromal cells), p<0.01, Fig. 1E). Similarly, during chronic inflammation it was found that the free zinc ions accumulate particularly in the columnar epithelium of the gallbladder (the grey average value increased from 25.6 +/- 7.4 (in SC) to 118.8 +/- 5.7, p<0.01, Fig. 1F).

The data are summarized on Table 1, which shows the frequency of cases found in staining categories of MT and zinc, defined as high, moderate, weak or negative. As visible, in group of subacute cholecystitis both expressions were predominantly moderate or weak, while in group of chronic cholecystitis the expressions of MT and zinc were high in 15 and 12 out of 20 patients (p<0.05).

3.2 Metallothionein Expression in Local Lymphatic Cells

Since MT and Zn ions have high influence on the immune homeostasis [22-24] in chronic cholecystitis we tried also to visualize the relationship of MT I/II to CD3+ T cells, using single and double immunofluorescence staining method. The data clearly showed that in area of inflammation were present CD3+ T cells (Fig. 2a-c) and numerous MT I/II positive epithelial, endothelial and monocyte-like cells (Fig. 2d-f). Moreover, several CD3+ cells were found in direct contact with MT positive cells (Fig. 2h), and some cells exhibited double CD3 and MT-immunoreactivity (Fig. 2i).

4. DISCUSSION

The data show that the presence of gallstones in the majority of patients was followed by chronic cholecystitis and by upregulation of NF- κ B in gallbladder epithelium, as well as that these changes correlated with the expression of MT I/II and free zinc content in gallbladder tissue. The findings seem to be new in the field of gallstone disease, but they are in high agreement with reported evidence pointing to important cytoprotective roles of MTs in inflammatory bowel diseases [25,26] and in other inflammatory states in humans [4,6,27,28].

Table 1. Expressions grades of MT I/II and zinc ions in subacute and chronic cholecystitis

	High	Moderate	Weak	Negative	Total
MT-I/II					
Subacute	0	2 (40%)	2 (40%)	1 (20%)	5 (100%)
Chronic	15 (75%)	4 (20%)	1 (5%)	0	20 (100%)
Zn ions					
Subacute	1 (20%)	3 (60%)	1 (20%)	0	5 (100%)
Chronic	12 (60%)	6 (30%)	2 (10%)	0	20 (100%)

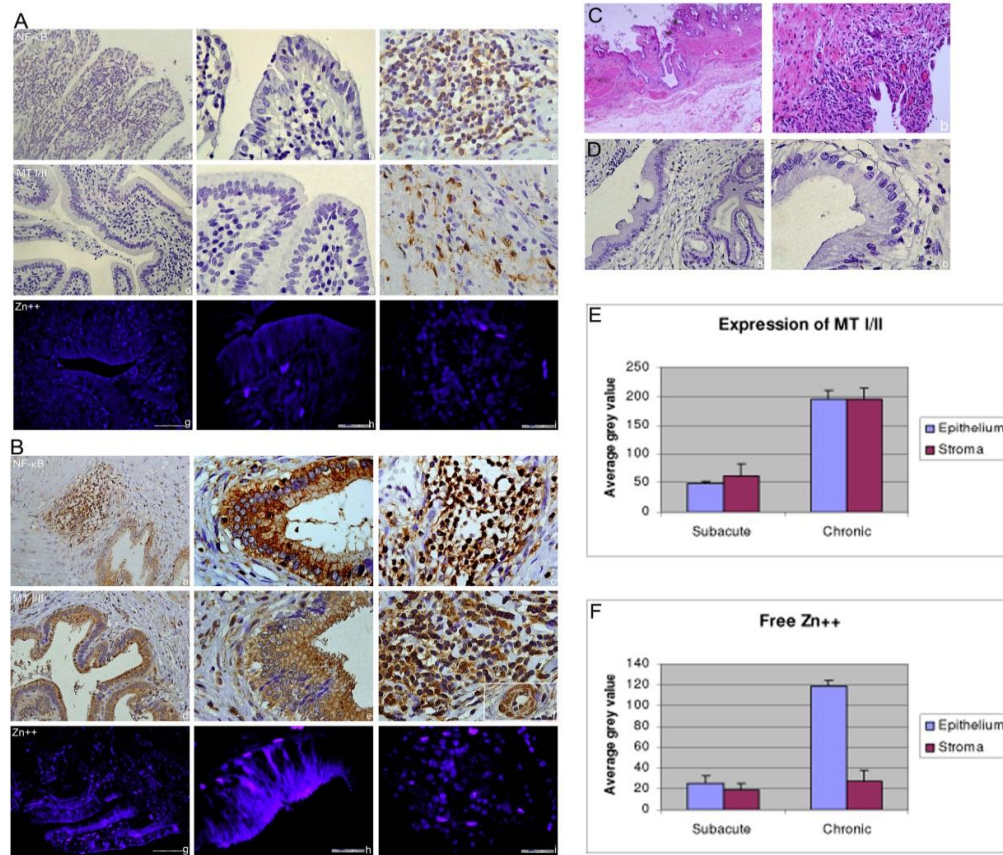


Fig. 1. Expression of NF-κB, metallothioneins and zinc ions in subacute (A) and chronic cholecystitis (B) induced by cholecystolithiasis

The data are the representative examples of histological and immunohistochemical changes in paraffin-embedded tissue sections (4µm) of gallbladders, stained with anti-NFκB p65 monoclonal antibody (a-c), with anti-MT I/II antibody (d-f) and with Zinquin (g-i). Magnitudes in columns are x100 and x1000. **C**) The representative pathohistological changes in chronic cholecystitis in H&E stained slides. **D**) Negative (IgG1 kistype) control for NF-κB and MT I/II staining in chronic cholecystitis. **E and F**) Immunohistochemical, cell-based staining quantification of MT I/II and free zinc ions in subacute and chronic cholecystitis. Average grey distribution was calculated from twenty regions of interest per field (magnitude x400) in the ten fields per microscopic slides of tissue samples. Results are mean ± SE.

The underlining mechanisms need to be elucidated, but the hypothesis is supported by widespread data showing that the transcription of MT gene may be induced in response to several compounds that are constantly generated during

the inflammation, such as pro-inflammatory mediators (IL-1, IL-6, TNF-α, IFN-γ), hydrogen peroxide, superoxide, nitric oxide (NO) and hydroxyl (OH) radicals, as well as by alteration of cellular Zn homeostasis which,

acting independently or in combination, may stimulate MT response element (MRE)-binding transcription factor-1 (MTF-1), antioxidant response elements (ARE), elements activated by signal transducers and activators of transcription (STAT) proteins and glucocorticoid response element (GRE) at the promoter regions of metallothionein gene [3,29,30]. This, usually leads to an anti-inflammatory effect [6,25,27], since MTs act as potent scavengers of reactive oxygen species (ROS) and as donors of zinc ions that are required for the function of over 2,000 transcription factors and more than 300 Zn-containing enzymes, including structural proteins, cytokines and receptors, which regulate cell proliferation, differentiation and apoptosis [22,24,28,31].

Our data, showing that high overexpression of MTs and labile zinc in chronic cholecystitis correlates with the intensity of NF- κ B immunoreactivity and lymphatic infiltration seem to support these mechanisms, but the complex interrelationships of MT/zinc network with underlying molecular signaling pathways, permit as only to speculate about the feedback mechanisms. Furthermore, published results often vary depending on pathophysiological conditions that are explored, on type of affected cell and on the stimulus by which MTs are induced [25,27]. Thus, in inflammatory bowel diseases, characterized by an increased level of ROS oxidative DNA and protein damage and immune cell infiltration in the intestinal mucosa, it was proposed that the functions of MTs are primarily intracellular and linked with their ability to maintain the zinc homeostasis, to regulate the activation of the transcription factor NF- κ B and to sequester the harmful oxygen and nitrogen intermediates that are generated during the inflammatory response [25]. In addition, MTs may affect the inflammation through specific extracellular effects, leading to the modulation of leukocyte chemotaxis and T and B cells activation and differentiation [32]. The outcome is, however, often dependent on cell types and on intensity of inflammation. Thus, the free zinc ions may induce the production of proinflammatory cytokines in LPS-treated human monocytes [33], but also inhibit the LPS-induced hepatic TNF- α secretion through abrogation of oxidative stress-sensitive NF- κ B pathway [34]. The mechanisms have been related with the permissive effects of intracellular free zinc on phosphorylation dependent signaling acting

upstream to NF- κ B activation [33], with effects of zinc ions on the expression of the zinc finger protein A20 that sequesters NF- κ B in the cytoplasm and inhibits IL-1- and TNF- α -induced activation of NF- κ B [35], as well as with the direct effect of MT I/II on NF- κ B or on ROS and RNS scavenging [25,36,37].

Besides, it has been shown that the elevation in labile zinc induced by NO-MT signaling, may inhibit the processes of LPS-induced apoptosis [31], as well as that during the inflammation MTs may block the leukocyte and macrophage activation and migration and promote the processes of tissue repair and angiogenesis, increasing the expression of anti-inflammatory and regenerative factors [4,38]. Additionally, the MTs and Zn network have been implicated in direct regulation of innate and adaptive immunity, affecting the development, maturation, and functions of several cellular and humoral mediators and the balance between the different subsets the T cells [22,24,28,39], as well as the LPS-induced upregulation of major histocompatibility complex proteins and co-stimulatory molecules on antigen presenting cells (APC) and the TLR4-dependent downstream signaling pathways [33,40]. In this sense, our data, showing the presence of several CD3+ lymphocytes in the contact with MT I/II expressing cells and double positive CD3/MT cells in gallbladder stroma (Fig. 2), imply that MTs and/or Zn⁺⁺ might affect the functional state of some APC and immune cells during the chronic inflammation, but this speculation needs to be proven.

Our immunohistochemical data do not permit further discussion in this direction, but overall they imply that during chronic cholecystolithiasis the MT/Zn network was activated to protect the cells from the potentially damaging effects of inflammation, induced by activation of canonical NF- κ B signaling pathway by proinflammatory cytokine receptors and pattern recognition receptors in gallbladder epithelium and in local lymphoid cells. In this context, it should be emphasized that recent data point to critical regulatory functions of NF- κ B transcriptional program particularly in epithelial tissues, such as the intestine and the skin, where it maintains the immune homeostasis and controls cellular responses to microbial and other environmental factors through its both - detrimental and beneficial functions [21].

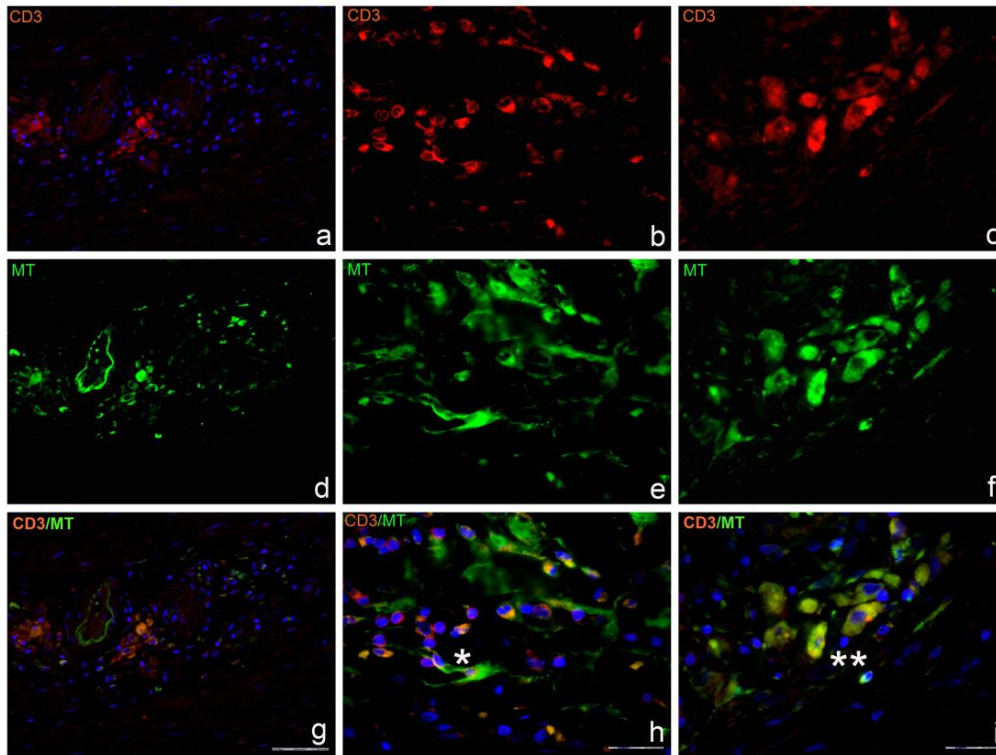


Fig. 2. Distribution of CD3 reactive cells and their relationship to cells expressing MT in the chronic cholecystitis

The results are representative findings in samples of gallbladders, obtained from patient suffering from chronic cholecystolithiasis. Red marks CD3+ cells, green marks MT+ cells, blue marks DAPI staining of nuclei and yellow marks the overlapping of CD3 and MT I/II. Asterisk on h points to direct contact of CD3 + cells with cells expressing MT I/II. Double asterisk on i points to cells with double CD3/MTs immunoreactivity. Magnitudes are x100 (first column) and x1000 (second and third column)

Summarizing, we would like also to underline that cholecystolithiasis is often followed by cholestasis-induced hepatic injuries [16], as well as that proinflammatory cytokines and other types of stress induce not only local, but also the systemic changes, as a part of acute phase response. In this condition, the synthesis of MTs in the liver markedly increases [29,41], leading to the redistribution of zinc into the cellular compartments. This may contribute to the hepatic tissue restoration [42-44], but also to the development of immune dysfunction, related with the impaired zinc homeostasis [45] and with increased demand for zinc in chronic inflammation [22,25,46]. Besides, hepatic MT/IL-6 may affect the balance between the cytotoxic TH17 and regulatory T cells [47], the NK-cells mediated cytotoxicity [45] and accelerate the transition from innate to acquired immunity in injured area [48].

It should be also emphasized that hepatic MT and its degradation products could be excreted into bile against a high bile/plasma concentration gradient [49], as well as that MTs might affect the biliary levels of calcium and other trace elements [14,15]. This evidence implies that MT-induced pathways may contribute also to the pathogenesis of gallstones, but at the present, we do not have data related with the possible link of MT and zinc overexpression in gallbladder with the chemical, structural, and elemental composition of the gallstones in our patients.

Furthermore, we would like to notice that MT-overexpression in gallbladder might point to the initiation of carcinogenic processes, as it was reported by Shukla and coworkers [20]. In carcinoma, however, the MT immunoreactivity was predominantly of nuclear type and it positively correlated with the dedifferentiation of the carcinoma, similarly as it was found in other types of human tumors [5,50].

5. CONCLUSION

In spite of the unclear mechanisms of action and unknown causal relationship between the pathogenesis of gallstones and local inflammation, in this pilot study, we point to high activation of MT I/II/Zn⁺⁺ network in chronic cholecystitis, detected in patients with cholelithiasis. The data emphasize the regulatory effects of MTs and zinc in the maintenance of epithelial tissue and immune homeostasis in human tissues, but this hypothesis needs further work to validate its reliability.

ACKNOWLEDGEMENTS

This work was supported by grants from the University of Rijeka, Croatia (project 13.06.1.1.16).

COMPETING INTERESTS

The authors declare that they have no competing interests.

REFERENCES

- Theocharis SE, Margeli AP, Koutselinis A. Metallothionein: A multifunctional protein from toxicity to cancer. *The International Journal of Biological Markers*. 2003; 18(3):162-9.
- Vallee BL. The function of metallothionein. *Neurochemistry International*. 1995;27(1): 23-33.
- Coyle P, Philcox JC, Carey LC, Rofe AM. Metallothionein: The multipurpose protein. *Cell Mol Life Sci*. 2002;59(4):627-47.
- Penkowa M. Metallothioneins are multipurpose neuroprotectants during brain pathology. *The FEBS Journal*. 2006; 273(9):1857-70.
- Pedersen MO, Larsen A, Stoltenberg M, Penkowa M. The role of metallothionein in oncogenesis and cancer prognosis. *Progress in Histochemistry and Cytochemistry*. 2009;44(1):29-64.
- Thirumoorthy N, Shyam Sunder A, Manisenthil Kumar K, Senthil Kumar M, Ganesh G, Chatterjee M. A review of metallothionein isoforms and their role in pathophysiology. *World Journal of Surgical Oncology*. 2011;9:54.
- Margoshes M, Vallee B. A cadmium protein from equine kidney cortex. *J Am Chem Soc*. 1957;79:4813-4.
- Capdevila M, Bofill R, Palacios O, Atrian S. State-of-the-art of metallothioneins at the beginning of the 21st century. *Coordination Chemistry Reviews*. 2012;256:46- 62.
- West AK, Hidalgo J, Eddins D, Levin ED, Aschner M. Metallothionein in the central nervous system: Roles in protection, regeneration and cognition. *Neuro Toxicology*. 2008;29(3):489-503.
- Moffatt P, Denizeau F. Metallothionein in physiological and physiopathological processes. *Drug Metabolism Reviews*. 1997;29(1-2):261-307.
- Miles AT, Hawksworth GM, Beattie JH, Rodilla V. Induction, regulation, degradation and biological significance of mammalian metallothioneins. *Critical Reviews in Biochemistry and Molecular Biology*. 2000;35(1):35-70.
- Schirmer BD, Winters KL, Edlich RF. Cholelithiasis and cholecystitis. *J Long Term Eff Med Implants*. 2005;15:329-38.
- Stinton LM, Shaffer EA. Epidemiology of Gallbladder Disease: Cholelithiasis and cancer. *Gut and Liver*. 2012;6(2):172-87.
- Verma GR, Pandey AK, Bose SM, Prasad R. Study of serum calcium and trace elements in chronic cholelithiasis. *ANZ Journal of Surgery*. 2002;72(8):596-9.
- Jaw S, Jeffery EH. Role of metallothionein in biliary metal excretion. *J Toxicol Environ Health*. 1989;28(1):39-51.
- Grbas H, Mrakovcic I, Depolo A, Radosevic-Stasic B. Perforin expression in peripheral blood lymphatic cells of patients subjected to laparoscopic or open cholecystectomy. *Mediators Inflamm*. 2009;2009:125152.
- Grebic D, Jakovac H, Mrakovcic-Sutic I, Tomac J, Bulog A, Micovic V, et al. Short-term exposure of mice to gasoline vapor increases the metallothionein expression in the brain, lungs and kidney. *Histology and Histopathology*. 2007;22(6):593-601.
- Jakovac H, Grebic D, Tota M, Barac-Latas V, Mrakovcic-Sutic I, Milin C, et al. Time-course expression of metallothioneins and tissue metals in chronic relapsing form of experimental autoimmune encephalomyelitis. *Histology and Histopathology*. 2011;26(2):233-45.
- Jakovac H, Tota M, Grebic D, Grubic-Kezele T, Barac-Latas V, Mrakovcic-Sutic I, et al. Metallothionein I+II expression as

- an early sign of chronic relapsing experimental autoimmune encephalomyelitis in rats. *Curr Aging Sci.* 2013;6(1):37-44.
20. Shukla VK, Aryya NC, Pitale A, Pandey M, Dixit VK, Reddy CD, et al. Metallothionein expression in carcinoma of the gallbladder. *Histopathology.* 1998;33(2):154-7.
 21. Wullaert A, Bonnet MC, Pasparakis M. NF- κ B in the regulation of epithelial homeostasis and inflammation. *Cell Res.* 2011;21(1):146-58.
 22. Haase H, Rink L. Zinc signals and immune function. *Biofactors.* 2013;40:27-40.
 23. Mocchegiani E, Muzzioli M, Giacconi R. Zinc, metallothioneins, immune responses, survival and ageing. *Biogerontology.* 2000;1(2):133-43.
 24. Prasad AS. Clinical, immunological, anti-inflammatory and antioxidant roles of zinc. *Experimental Gerontology.* 2008;43(5):370-7.
 25. Waeytens A, De Vos M, Laukens D. Evidence for a potential role of metallothioneins in inflammatory bowel diseases. *Mediators Inflamm.* 2009;2009:729172.
 26. Ioachim E, Michael M, Katsanos CAD, Tsianos EV. The immunohistochemical expression of metallothionein in inflammatory bowel disease. Correlation with HLA-DR antigen expression, lymphocyte subpopulations and proliferation-associated indices. *Histology and Histopathology.* 2003;18:75-82.
 27. Inoue K-i, Takano H, Shimada A, Satoh M. Metallothionein as an anti-inflammatory mediator. *Mediators Inflamm.* 2009;2009:101659.
 28. Mocchegiani E, Malavolta M, Costarelli L, Giacconi R, Cipriano C, Piacenza F, et al. Zinc, metallothioneins and immunosenescence. *Cambridge Journals Online.* 2010;69:290-9.
 29. Sato M, Yamaki J, Hamaya M, Hojo H. Synergistic induction of metallothionein synthesis by interleukin-6, dexamethasone and zinc in the rat. *International Journal of Immunopharmacology.* 1996;18(2):167-72.
 30. Davis SR, Cousins RJ. Metallothionein Expression in Animals: A physiological perspective on function. *The Journal of Nutrition.* 2000;130:1085-8.
 31. Thambiayya K, Kaynar AM, St Croix CM, Pitt BR. Functional role of intracellular labile zinc in pulmonary endothelium. *Pulmonary Circulation.* 2012;2(4):443-51.
 32. Lynes MA, Zaffuto K, Unfricht DW, Marusov G, Samson JS, Yin X. The physiological roles of extracellular metallothionein. *Experimental Biology and Medicine (Maywood, NJ).* 2006;231(9):1548-54.
 33. Haase H, Ober-Blobaum JL, Engelhardt G, Hebel S, Heit A, Heine H, et al. Zinc signals are essential for lipopolysaccharide-induced signal transduction in monocytes. *J Immunol.* 2008;181(9):6491-502.
 34. Zhou Z, Wang L, Song Z, Saari JT, McClain CJ, Kang YJ. Abrogation of nuclear factor-kappaB activation is involved in zinc inhibition of lipopolysaccharide-induced tumor necrosis factor-alpha production and liver injury. *The American Journal of Pathology.* 2004;164(5):1547-56.
 35. Jaattela M, Mouritzen H, Elling F, Bastholm L. A20 zinc finger protein inhibits TNF and IL-1 signaling. *J Immunol.* 1996;156(3):1166-73.
 36. Maret W. Redox biochemistry of mammalian metallothioneins. *J Biollnorg Chem.* 2011;16(7):1079-86.
 37. Vařák M, Meloni G. Chemistry and biology of mammalian metallothioneins. *J Biollnorg Chem.* 2011;16(7):1067-78.
 38. Pedersen MO, Jensen R, Pedersen DS, Skjolding AD, Hempel C, Maretty L, et al. Metallothionein-I+II in neuroprotection. *Bio Factors (Oxford, England).* 2009;35(4):315-25.
 39. Borghesi LA, Youn J, Olson EA, Lynes MA. Interactions of metallothionein with murine lymphocytes: Plasma membrane binding and proliferation. *Toxicology.* 1996;108(1-2):129-40.
 40. Rink L, Haase H. Zinc homeostasis and immunity. *Trends in Immunology.* 2007;28(1):1-4.
 41. Nagamine T, Nakajima K. Significance of Metallothionein Expression in Liver Disease. *Current Pharmaceutical Biotechnology.* 2013;14:420-6.
 42. Mocchegiani E, Verbanac D, Santarelli L, Tibaldi A, Muzzioli M, Radosevic-Stasic B, et al. Zinc and metallothioneins on cellular immune effectiveness during liver regeneration in young and old mice. *Life Sciences.* 1997;61(12):1125-45.
 43. Cherian MG, Kang YJ. Metallothionein and liver cell regeneration. *Exp Biol Med (Maywood).* 2006;138-44.

44. Jakovac H, Grebic D, Mrakovcic-Sutic I, Tota M, Broznic D, Marinic J, et al. Metallothionein expression and tissue metal kinetics after partial hepatectomy in mice. *Biol Trace Elem Res.* 2006;114(1-3):249-68.
45. Mocchegiani E, Muzzioli M, Giacconi R, Cipriano C, Gasparini N, Franceschi C, et al. Metallothioneins/PARP-1/IL-6 interplay on natural killer cell activity in elderly: Parallelism with nonagenarians and old infected humans. Effect of zinc supply. *Mechanisms of Ageing and Development.* 2003;124(4):459-68.
46. Foster M, Samman S. Zinc and regulation of inflammatory cytokines: Implications for cardiometabolic disease. *Nutrients.* 2012; 4(7):676-94.
47. Kimura A, Kishimoto T. IL-6: Regulator of Treg/Th17 balance. *Eur J Immunol* 2010; 40:1830-5.
48. Manso Y, Adlard PA, Carrasco J, Vasak M, Hidalgo J. Metallothionein and brain inflammation. *J Biollnorg Chem.* 2011; 16(7):1103-13.
49. Sato M, Bremner I. Biliary excretion of metallothionein and a possible degradation product in rats injected with copper and zinc. *The Biochemical Journal.* 1984; 223(2):475-9.
50. Theocharis SE, Margeli AP, Klijanienko JT, Kouraklis GP. Metallothionein expression in human neoplasia. *Histopathology.* 2004; 45(2):103-18.

© 2015 Grbas et al.; This is an Open Access article distributed under the terms of the Creative Commons Attribution License (<http://creativecommons.org/licenses/by/4.0>), which permits unrestricted use, distribution, and reproduction in any medium, provided the original work is properly cited.

Peer-review history:

The peer review history for this paper can be accessed here:
<http://www.sciencedomain.org/review-history.php?iid=799&id=32&aid=7950>