

BONE TUMORS IN CHILDREN

Roganović, Jelena

Source / Izvornik: **Pedijatrija danas (Paediatrics Today), 2011, 7, 1 - 9**

Journal article, Published version

Rad u časopisu, Objavljena verzija rada (izdavačev PDF)

<https://doi.org/10.5457/p2005-114.8>

Permanent link / Trajna poveznica: <https://um.nsk.hr/um:nbn:hr:184:984591>

Rights / Prava: [Attribution-NonCommercial 4.0 International/Imenovanje-Nekomercijalno 4.0 međunarodna](#)

Download date / Datum preuzimanja: **2025-01-12**



Repository / Repozitorij:

[Repository of the University of Rijeka, Faculty of Medicine - FMRI Repository](#)



BONE TUMORS IN CHILDREN

Jelena ROGANOVIĆ

Department of Pediatrics
Clinical Hospital Center Rijeka
& Chair of Pediatrics
School of Medicine
University of Rijeka
Republic of Croatia

Jelena Roganović
Department of Pediatrics
Clinical Hospital Center Rijeka
Istarska 43
HR - 51000 Rijeka
Croatia
e-mail: jelena.roganovic1@ri.t-com.hr
Tel.: + 385 51 659 103/109
Fax: + 385 51 623 126

Received: November 11, 2010

Accepted: December 26, 2010

Copyright © 2009 by University
Clinical Center Tuzla. E-mail
for permission to publish:
pedijatrijadas@ukctuzla.ba

Bone tumors in children are rare, accounting for 5% of all childhood cancer. Although rare, bone cancer deserves a special attention in pediatric oncology. Given an overall 5-year survival rate of approximately 65% for pediatric patients, malignant bone tumors should be diagnosed and treated rapidly and accurately in specialized centers.

Key words: Bone tumors ▪ Child

Introduction

Malignant bone tumors in children occur rarely. Estimated annual incidence is 7 cases per 1.000.000 children under the age of 16. Due to its rare occurrence and often unspecific signs and symptoms, a lot of physicians do not consider this diagnosis early enough. Therefore it is not surprising that the majority of patients are referred to the pediatric oncologist when the disease is already in advanced stage. The aim of this review is to summarize basic facts regarding bone tumors, in order to help primary care pediatricians and general practitioners to recognize these neoplasms as soon as possible. Besides malignant, there will be a short review of benign tumors and tumor-like lesions.

Clinical manifestations

Bone tumors in children could be presented with various symptoms, depending on the localization, the size and the nature of the tumor. Predominant symptom is pain, initially present during the night or during certain activities, but later the intensity rises. On clinical examination unusually

swelling can be seen or palpated. Additional clinical findings may include limitation of motion, skin changes, neurological deficits, vascular defects or pathological fractures. General symptoms, like fever, fatigue and weight loss, are more frequent in children with metastatic diseases.

Diagnostic procedure

Together with thorough history, a complete physical examination is very important, including muscle strength and tendon reflexes assessment. First imaging modality should be x-ray. Radiological images in two directions can reveal the entire affected bone. The method is simple, inexpensive, and available in smaller institutions, delivers minimal amounts of radiation and does not require general anesthesia. Radiographic changes can determine most probable tumor type, since many malignant bone tumors have characteristic radiological findings. Benign tumors more often have smooth, straight line borders, whereas malignant have irregular ones. Benign tumors mostly grow slowly enough so the bone can separate tumor from the normal bone tissue. In contrast, malignant tumors are characterized by rapid growth and normal bone tissue cannot limit the process. Since the symmetry is crucial in assessing the findings, it is appropriate to compare the contra lateral bone. In patients with malignant bone tumors x-ray of the lungs is required to reveal possible metastases. Computerized tomography (CT) is more advanced method and can create the three-dimensional view of bone, so the tumor can be identified more precisely and provides additional information about its size and location. Disadvantages of CT such as higher doses of radiation, expensiveness, and the need for general anesthesia in young children, are negligible compared to the importance of early diagnosis. Magnetic resonance imaging (MRI) compared to CT provides more detailed information regarding the soft tissues

surrounding bone, including muscles, tendons, ligaments, nerves and blood vessels. MR can also demonstrate the possible penetration of the tumor through the compact part of the bone and through the surrounding soft tissue. Furthermore there is no ionizing radiation. The main disadvantages are higher cost and limited availability. Ultrasound can be used only for soft tissue analysis. Radioactively labeled technetium scintigraphy shows areas of rapid growth and bone remodeling, and the results are positive much earlier than radiological. This method displays whole skeleton and can show the possible involvement of other bones. The final step in the diagnostic process is surgical biopsy and histological analysis of tissue sample. Needle biopsy or aspiration biopsy may be useful in case of soft tissues involvement (1, 3).

Malignant bone tumors

Primary malignant bone tumors are more common in children and adolescents than in adults. Etiopathology is mostly unknown. Tumors may arise in areas of rapid growth. Besides accelerated bone growth, possible risk factors include trauma and radiation therapy for other neoplasms. They are more common in boys and in the white race. There are rare hereditary syndromes with an increased risk for bone tumors, such as hereditary retinoblastoma and Li-Fraumeni syndrome (hereditary gene mutation with a tendency to develop multiple neoplasms, particularly breast cancer, adrenal gland cancer, brain tumor, leukemia and soft tissues sarcomas) (1, 4).

According to generally accepted ICCC (International Classification of Childhood Cancer), malignant bone tumors in children are divided into osteosarcoma, hondrosarcoma, Ewing tumor and related bone sarcomas, "other specified malignant bone tumor" and "unspecified malignant bone tumor." Two types of malignant bone tumors predominate in children - osteosarcoma and Ewing's sarcoma (5).

Osteosarcoma is the most common primary malignant bone tumor in children and adolescents. The annual incidence is 5.6 per 1 million children under the age of 15. It usually occurs in the age group 10-25 years, more frequently in boys (4, 6). The greatest risk for osteosarcoma is during the adolescent growth acceleration, which suggests the association of rapid bone growth and malignant transformation. Patients with osteosarcoma are taller than their peers. In almost half of the patients, osteosarcoma is situated in the area of the knee joint, the distal edge of the femur or proximal edge of the fibula, but also in every other long bone. Tumor process develops in the bone spongiosa, destroying corticalis and gradually expands into the surrounding soft tissue. Periosteum reaction is characteristic radiological sign, with the creation of calcifications radiating from the corticalis to the periphery (Figure 1). It can metastasize to other bones, or more often to the lungs. Prognosis depends on the location and size of the primary tumor and the degree of necrosis after neoadjuvant chemotherapy. Localization on the shoulder girdle, shoulder blade, collarbone, ribs, vertebrae, pelvic bones and proximal parts of extremities is related with worse outcome. Overall five year survival is around 65% (6).

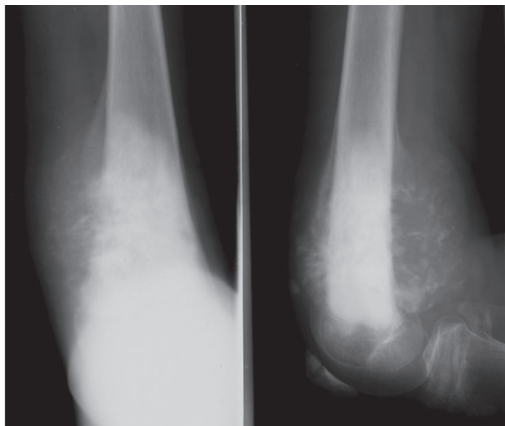


Figure 1 Osteosarcoma. Osteosclerosis and cortical lytic lesions of the distal femur, with periosteal reaction and soft tissue swelling

Ewing's sarcoma is the most aggressive bone tumor. The annual incidence is 2.1 per 1 million children. It is more common in boys aged between 4 and 15 years, and very rare after 30 years of age (7). The origin of this tumor is the subject of numerous discussions. Although it was thought to arise from primitive neuroectoderm, there are many indications that arises from mesenchymal stem cells. It is typically situated at the diaphysis of long bones of arms and legs. Cytogenetic and molecular analysis in 90% of cases shows a reciprocal translocation $t(11;22)(q24, q12)$, which results in EWS-FLI1 fusion gene (8). On radiological images it is displayed as symmetrical fusiform thickening of the bone. Additionally, irregular areas of osteolysis and sclerosis can be seen. The radiological footage seems very unclear and blurred, and the bone appears as "eroded by moths" (Figure 2). Two-thirds of patients have extraosseous permeation of the tumor in the soft tissues. At the time of diagnosis 25% of children have hematogenous metastases in the lungs, bones, pleura, or bone marrow. Three-year survival is around 65%. In children with metastatic disease at the time of diagnosis, the prognosis is significantly worse, with 30% survival (7, 8).

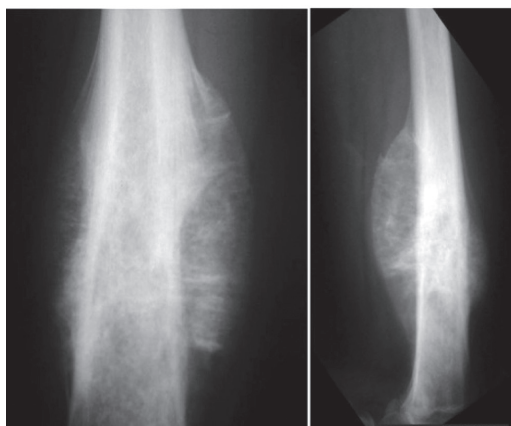


Figure 2 Ewing sarcoma. Permeative patchy lesion of the diaphysis of the femur with laminated periosteal reaction and soft tissue swelling

Chondrosarcoma is a rare malignant bone tumor in children, more common after 40 years of age. It originates from cartilage cells and can be either very aggressive or relatively slow in growth. It affects all bones, more often pelvis and hips more. It can metastasize to the lungs and lymph nodes. Five-year survival for aggressive forms is only 30%, yet 90% for slowly growing tumors (9).

Fibrosarcoma is extremely rare in children. It affects predominantly the diaphysis of the long bones. It grows slowly and reoccurs late. Radiological findings show blurred osteolytic area. Clinically, a rigid infiltrate surrounding the affected bone can be detected. One third of patients are presented with pathological fractures (1, 10).

Angiosarcoma is also very rare in children. This extremely vicious vascular tumor often involves the long and short tubular bones of the extremities (usually the femur, tibia and humerus). On radiologic images multiple eccentric osteolytic lesions can be seen (10).

Benign bone tumors

In children benign bone lesions are much more frequent than malignant. However, there is no certain anamnestic data or diagnostic test that is reliable enough to exclude a malignant neoplasm. Benign bone tumors may be painless but also painful, especially in the case of pathological fracture. Rapid growth is common in malignant tumors, but some benign lesions such as aneurismatic bone cysts, can dramatically increase its size (1). Osteochondroma is the most common benign tumor of the locomotor system. Since the majority of them are asymptomatic and unrecognized exact incidence is not known. The most commonly is discovered in children aged 5-15 years when the parents or the child notice a painless rigid formation associated with bone. Radiological sign is so-called osteocartilaginous exostosis – a shar-

ply limited growth with a base closer to the epiphyseal part of the bone, which expands towards the surface (Figure 3). Towards the periphery the bony part is covered with lobulated cartilage. As the cartilage cap is not seen radiologically, the lesion is always larger on palpation. It can be solitary or multiple. It is not recommended to be routinely removed if it does not cause difficulties or start to grow rapidly. In 1% of the patients the malignant transformation after full growth has been described (11).

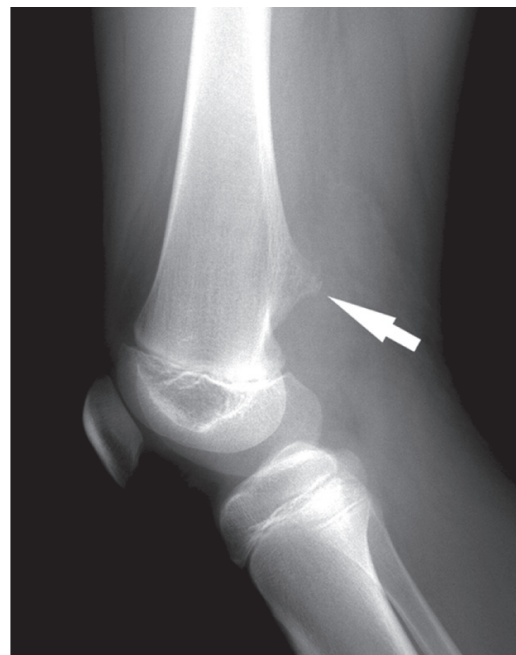

Figure 3 Osteochondroma. Broad-based cortical lesion at the posterior distal femoral diaphysis, without adjacent bone changes

Osteoid osteoma is a small benign tumor of bone. The majority are diagnosed between the fifth and twentieth year, more frequently in men. Patients typically feel a constant pain that intensifies over time, that is stronger during the night and weakens if salicylates are used. Radiological sign is the central illumination of the sclerotic part of the bone, so called. “nest” or “nidus” (Figure 4). In 25% of cases osteoid osteoma is not visible on the

classic radiological images, but it can be visualized by CT scan. Treatment is surgical (12).

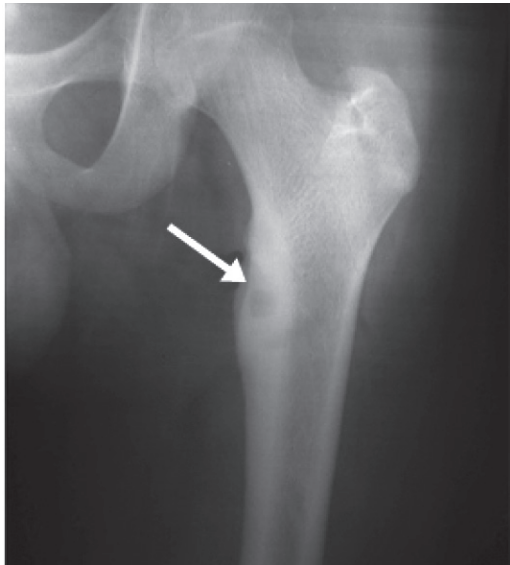


Figure 4 Osteoid osteoma. Subcortical lesion of the proximal femoral metaphysis with centrally located radiolucent area (nidus) surrounded by a zone of uniform bone sclerosis

Enchondroma is a benign tumor of hyaline cartilage, which usually occurs between 20 and 30 years of age. It is usually asymptomatic and located on the short tubular bones of hands and feet. Radiological finding is sharply limited osteolytic lesion in the medulla, sometimes with calcifications. Ordinarily it is solitary. Multiple enchondromas with a predilection for malignant transformation occur in Ollier disease (short stature, bone dysplasia, joint deformities, unequal length of limbs) or Maffucci syndrome associated with soft tissue angiomas (13).

Eosinophilic granuloma is a benign form of Langerhans cell histiocytosis. It is characterized by solitary or multiple bone lesions without extraosseal involvement. It usually occurs in the first 3 decades, more common in boys between 5 and 10 years of age. Any bone can be affected, but they are more likely to be localized on the skull, mandible, ribs and femur. When there are multiple lesi-

ons, the new lesions usually occur within 1-2 years. Solitary lesions may be asymptomatic, or accompanied with localized pain and swelling. Pathological fractures are possible. Radiological image usually displays lytic lesion with or without sclerotic edge (Figure 5), but it can mimic many benign and malignant bone lesions. Therefore, biopsy is often necessary. There are different treatment options: observation since the majority of bone lesions regress spontaneously and does not recur, low-dose radiotherapy, local injection of steroids and surgical treatment (14).

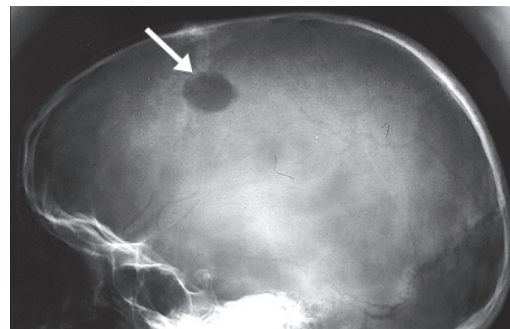


Figure 5 Eosinophilic granuloma. Solitary osteolytic lesion in the frontoparietal region of the skull

Timor-like formations

Timor-like formations are listed in the text because they are often confused with genuine tumors.

Solitary bone cyst (juvenile, simple or unicameral bone cyst) occurs at any age but is rare in children younger than 3 years or after completion of growth. The etiology is unknown. It is located mostly on the edge of the proximal humerus and femur. It may be asymptomatic or presents with pain and pathological fractures. Radiologically, it appears as a solitary, centrally located osteolytic lesion (Figure 6). It is often treated by aspiration and injection of corticosteroids with prolonged activity (15).

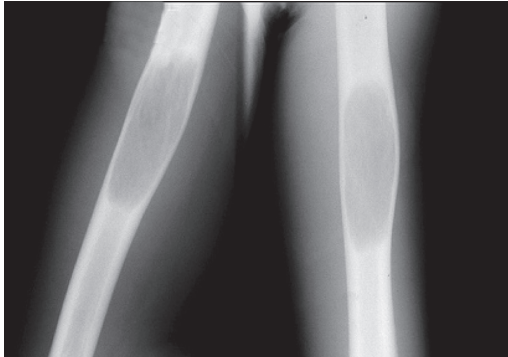

Figure 6 Solitary (unicameral) bone cyst. Sharply demarcated osteolytic lesion with cortical thinning and mild expansion of the bone

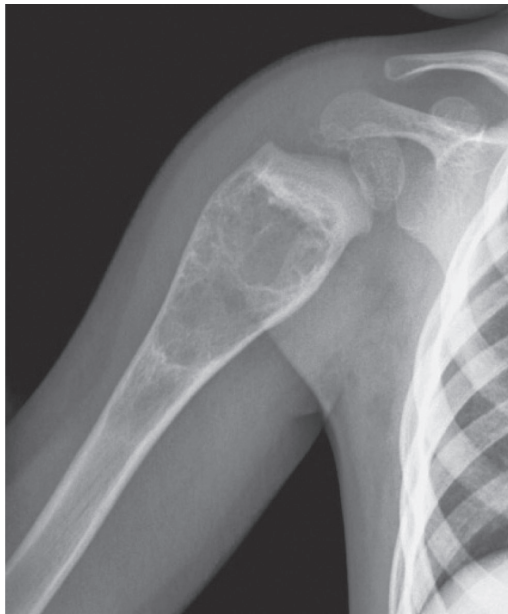


Figure 7 Aneurysmal bone cyst. Expansile osteolytic lesion of the proximal humeral metaphysis with irregular trabecular pattern and thin sclerotic margins

Aneurismatic bone cyst is a reactive bone lesion, characterized with cavernous spaces filled with blood. It most commonly affects the femur, tibia and spine. In the children the course is usually very aggressive because of the rapid growth. Radiologically there is bone destruction with eccentric expansion of the affected part, along with the reaction of the periosteum, which creates a thin layer

of newly formed bone (Figure 7). Treatment is surgical. It recurs in 20-30% of patients, more frequently in younger children and within two years after treatment (1, 15).

Fibroma (non-ossifying fibroma, cortical fibrous defect, metaphyseal fibrous defect) is a defect of ossification that occurs in 40% of children older than 2 years. Most of these fibrotic lesions are asymptomatic and discovered as an incidental finding on X-ray of the bone after trauma. Pathological fractures are rare. In 50% of cases lesions are bilateral or multiple. Radiographical sign is osteolytic area in cortical region with a clear sclerotic border towards the surrounding healthy spongiosa. Because of the typical radiological findings, biopsy is rarely necessary. After skeletal maturation spontaneous regression can be expected (10).

Fibrous dysplasia is a developmental defect characterized by the replacement of spongy bone by fibrous tissue. The lesion may be solitary (monostotic form) or multifocal (polyostotic form). Polyostotic fibrous dysplasia, premature puberty and skin pigmentation found together are also known as Albright syndrome. Most children are asymptomatic, but pain may be present together with pathological fractures and skeletal deformities. Radiological sign is erasure of the bone structure with cystic illuminations, with some septa preserved. Typical sign is the bending of the upper edges of the femur, such as “shepherd’s crook” (16).

Treatment of malignant bone tumors

Combination of chemotherapy, surgery and radiotherapy is most commonly used the treatment of children and adolescents with malignant bone tumors. Close cooperation between pediatric oncologists, radiologists, pathologists, orthopedists, physiatrists and radiotherapist is required in planning the op-

timal therapy. The main goals of treatment are longer survival combined with strict control of malignant disease and a higher life quality.

Neoadjuvant chemotherapy causes preoperative necrosis and control of the possible hematogeneous metastases. Cytotoxic effect is evaluated after surgery by percentage of necrotic tumor cells. A higher percentage of necrosis indicates greater effectiveness of chemotherapy. The first grade is tumor necrosis less than 50%, which is a bad response, necrosis of 50% to 90% represents second stage, more than 90% necrosis equals the third grade, and fourth grade is 100% necrosis, which indicates the best response (1, 4).

Surgical treatment of bone tumors has significantly changed during the last quarter of century. While amputation has been the standard treatment for many years, limb-saving surgery is nowadays performed in 85% of patients. "Salvage surgery" involves resection of the tumor in the block with the surrounding healthy tissue, but preserving the affected extremity. The ideal is that the operating margins do not contain cancer cells. There are four ways of tumor resection in relation to the surgical edge, and the type of tissue that is removed along with the tumor. Resection through the tumor itself is called intracapsular. Marginal resection is the surgical removal of tumor through the reactive zone. Wide resection means that the tumor is removed outside the reactive zone through the normal bone. Radical resection means removing the entire affected bone. After the orthopedic treatment it is necessary to make the reconstruction of the defect. There are various forms of reconstruction, depending on patient age, tumor localization and extent of resection. For the reconstruction of the bone extrinsic materials can be used (bone cement, polyethylene or usually metal prosthesis) or biological materials (autotransplant or homotransplant). Bone

healing is best when autotransplant is used, usually fibula. A special form of biological reconstruction is so-called rotational plastics, when the preserved parts of the limbs are used for the rotation, and the tumor is removed while preserving the blood vessels. An example is the use of rotated ankle joint at the knee instead of the resected knee joint. After the successful reconstruction of the skeleton in children, the most common problem is limb length difference. For this purpose so-called growing endoprosthesis are used, which allow an extension of the limbs for equalizing the length during the growth. After orthopedic surgery and radiotherapy, chemotherapy is often re-applied to eradicate remaining tumor cells, so-called adjuvant chemotherapy. In some malignant tumors of the bone it is necessary to apply mega-dosage therapy with autologous hematopoietic stem cell transplantation (1, 4).

Risks and side effects exist in each therapeutic modality. The main risks of orthopedic treatment are infections (often following the installation of extrinsic materials), local recurrences and injury of surrounding tissues resulting in weakness, loss of sensation or fractures of the remaining bone. Appropriate physical therapy improves strength and function of the extremities. The most common side effects of chemotherapy are susceptibility to infections, hair loss, nausea, vomiting, and fatigue. Modern supportive therapy can prevent, alleviate or eliminate a large number of side effects of chemotherapy, which significantly improves the quality of life of children during treatment and has a positive effect on disease outcome. The main early adverse effect of radiotherapy is damage to the surrounding skin and soft tissue, and delayed are effects on physical growth and development of secondary tumors (4).

Advance in the understanding and treatment of bone tumors in children and adolescents has resulted in improved techniques

of radiation (three-dimensional conformal radiotherapy, beams of variable intensity, proton therapy), modern combinations of chemotherapy and new orthopedic techniques. Today's research is directed towards establishing or facilitating own reparative processes using bio-materials that stimulate the production of normal bone, gene the-

rapy for tumors with known genetic aberrations and so-called targeted therapy, focused on specific elements of the tumor cells with minimal effect on normal cells.

Conflict of Interest: The author declare that she have no conflict of interest. This study was not sponsored by any external organisation.

References

1. Arndt CAS. Neoplasms of bone. In: Nathan DG, Orkin SH, Ginsburg D, Look TA, editors. *Nathan and Oski's Hematology of Infancy and Childhood*. Philadelphia: W.B. Saunders Company; 2007. p. 2146-51.
2. McCarville MB. The child with bone pain: malignancies and mimickers. *Cancer Imaging*. 2009;(Spec No A):S115-21.
3. Wyers MR. Evaluation of pediatric bone lesions. *Pediatr Radiol*. 2010; 40(4):468-73.
4. Heare T, Hensley MA, Dell'Orfano S. Bone tumors: osteosarcoma and Ewing's sarcoma. *Curr Opin Pediatr*. 2009;21(3):365-72.
5. Steliarova-Foucher E, Stiller C, Lacour B, Kaatsch P. *International Classification of Childhood Cancer, Third Edition*. *Cancer*. 2005;103(7):1457-67.
6. Kim HJ, Chalmers PN, Morris CD. Pediatric osteogenic sarcoma. *Curr Opin Pediatr*. 2010;22(1):61-6.
7. Karosas AO. Ewing's sarcoma. *Am J Health Syst Pharm*. 2010;67(19):1599-605.
8. Maheshwari AV, Cheng EY. Ewing sarcoma family of tumors. *J Am Acad Orthop Surg*. 2010; 18(2):94-107.
9. Gelderblom H, Hogendoorn PC, Dijkstra SD, van Rijswijk CS, Krol AD, Taminau AH, et al. The clinical approach towards chondrosarcoma. *Oncologist*. 2008;13(3):320-9.
10. Vlychou M, Athanasou NA. Radiological and pathological diagnosis of paediatric bone tumours and tumour-like lesions. *Pathology*. 2008;40(2):196-216.
11. Kitsoulis P, Galani V, Stefanaki K, Paraskevas G, Karatzias G, Agnantis NJ, et al. Osteochondromas: review of the clinical, radiological and pathological features. *In Vivo*. 2008;22(5):633-46.
12. Lee EH, Shafi M, Hui JH. Osteoid osteoma: a current review. *J Pediatr Orthop*. 2006;26(5):695-700.
13. Romeo S, Hogendoorn PC, Dei Tos AP. Benign cartilaginous tumors of bone: from morphology to somatic and germ-line genetics. *Adv Anat Pathol*. 2009;16(5):307-15.
14. Khan AN, Chandramohan M, Turnbull I, MacDonald S. Eosinophilic granuloma, skeletal; c1994-2010 [updated 2008 May 14]. Available from: <http://emedicine.medscape.com/article/389350>
15. Parman LM, Murphey MD. Alphabet soup: cystic lesions of bone. *Semin Musculoskelet Radiol*. 2000;4(1):89-101.
16. Feller L, Wood NH, Khammissa RA, Lemmer J, Raubenheimer EJ. The nature of fibrous dysplasia. *Head Face Med*. 2009;5:22.
17. Abed R, Grimer R. Surgical modalities in the treatment of bone sarcomas in children. *Cancer Treat Rev*. 2010;36(4):342-7.