

CT PERITONEOGRAPHY - DIAGNOSTIC METHOD OF DETECTING SWEET HYDROTHORAX IN PATIENTS ON PERITONEAL DIALYSIS

Markić, Dean; Gršković, Antun; Rahelić, Dražen; Materljan, Mauro; Trošelj, Marin; Pavletić Peršić, Martina; Vujičić, Božidar; Orlić, Lidija; Vujičić, Vanesa; Pavlović, Ivan; ...

Source / Izvornik: **Acta medica Croatica : Časopis Akademije medicinskih znanosti Hrvatske, 2016, 70, 81 - 84**

Journal article, Published version

Rad u časopisu, Objavljena verzija rada (izdavačev PDF)

Permanent link / Trajna poveznica: <https://urn.nsk.hr/urn:nbn:hr:184:065619>

Rights / Prava: [Attribution 4.0 International](#)/[Imenovanje 4.0 međunarodna](#)

Download date / Datum preuzimanja: **2024-10-02**



Repository / Repozitorij:

[Repository of the University of Rijeka, Faculty of Medicine - FMRI Repository](#)



CT PERITONEOGRAPHY – DIAGNOSTIC METHOD OF DETECTING SWEET HYDROTHORAX IN PATIENTS ON PERITONEAL DIALYSIS

DEAN MARKIĆ, ANTUN GRŠKOVIĆ, DRAŽEN RAHELIĆ, MAURO MATERLJAN, MARIN TROŠELJ, MARTINA PAVLETIĆ PERŠIĆ¹, BOŽIDAR VUJIČIĆ¹, LIDIJA ORLIĆ¹, VANESA VUJIČIĆ², IVAN PAVLOVIĆ³ and SANJIN RAČKI¹

Rijeka University Hospital Center, Clinical Department of Urology,

¹Department of Nephrology and Dialysis, ²University of Rijeka, School of Medicine, and

³Rijeka University Hospital Center, Department of Radiology, Rijeka, Croatia

Peritoneal dialysis (PD) can be considered as the first method to start dialysis treatment because it improves the patient quality of life and survival compared to hemodialysis (in the first two years). Hydrothorax is a rare complication of PD. We present a 66-year-old female patient diagnosed with end-stage renal disease caused by chronic tubulointerstitial nephritis. One month after peritoneal catheter had been inserted, the patient started continuous ambulatory PD. Several weeks after PD had been introduced, the patient complained of cough and weight gain. Chest x-ray revealed pleural effusion on the right side and pleural puncture proved a high concentration of glucose in the aspirate, and the diagnosis of 'sweet hydrothorax' was made. Additionally, computerized tomography (CT) peritoneography clearly showed contrast leak from peritoneal cavity to thoracic cavity. PD was stopped and the catheter for PD removed. Now, the patient is on the waiting list for kidney transplantation. 'Sweet hydrothorax' is a rare complication of PD and CT peritoneography is the most sensitive noninvasive diagnostic tool. In most patients, PD is replaced by hemodialysis, although surgical treatment is also possible.

Key words: end stage renal disease, computerized tomography peritoneography, peritoneal dialysis

Address for Correspondence: Dean Markić, MD, PhD, FEBU
Clinical Department of Urology
Rijeka University Hospital Center
Tome Strižića 3
HR-51000 Rijeka, Croatia
E-mail: dean.markic@ri.htnet.hr

INTRODUCTION

Hydrothorax is a rare complication of peritoneal dialysis (PD), with the incidence ranging from 1.6% to 6%⁽¹⁻³⁾. Clinical presentation may vary from incidental findings in asymptomatic patients to respiratory compromise, so its incidence cannot be determined with certainty. The time to developing complication ranges from several hours to up to 8 years^(1,2). Hydrothorax developing in PD patients is a consequence of communication created between pleural and peritoneal space³. These communications can be primary (congenital) or secondary (acquired). Primary communications, i.e. congenital diaphragmatic hernia, are produced by failure of the diaphragm to fuse properly during fetal development⁽³⁾. Secondary communications develop due to high pressure within the abdominal cavity during dialysate exchange, which leads to separation of the diaphragmatic collagen fibers and

results in opening of the pleuroperitoneal communication. This consequently leads to the passage of the PD solution in the pleural space⁽³⁾.

In this report, we present a patient who developed hydrothorax after starting PD.

CASE REPORT

A 66-year-old female patient was diagnosed with end-stage renal disease. Kidney biopsy confirmed that the cause of chronic kidney disease was chronic tubulointerstitial nephritis due to seronegative spondyloarthritis B27 positive (Reiter's syndrome) treated with low dose prednisolone. The patient also suffers from type 2 diabetes mellitus, which is treated with oral hypoglycemics.

The patient was hospitalized because permanent deterioration of kidney function was observed. Serum urea

was 21.5 mmol/L and creatinine 452 $\mu\text{mol/L}$, while the estimated glomerular filtration rate (eGFR) was 8.5 mL/min/1.73 m². After predialysis education, the patient opted for PD and peritoneal catheter was inserted. A month and a half after starting PD, the patient noticed weight gain of 6 kg. She also complained of dry cough and leg swelling around the ankle, while denying pain and shortness of breath. Physical examination showed that there was no respiration on the right side and chest x-ray was ordered to show right-sided pleural effusion. The patient underwent thoracentesis and 1200 mL of fluid was evacuated. Biochemical analysis showed ‘sweet’ hydrothorax. Pleural “leak” and pleural-peritoneal space communication was suspected. In order to prove pleural “leak”, computerized tomography (CT) peritoneography was performed.

Before performing CT peritoneography, the peritoneal cavity was completely drained of dialysate. Next, 100 mL of nonionic contrast material containing iodine 300 mg/mL (Omnipaque 300, Amersham, Princeton, New Jersey, USA) was mixed with about 2 L of dialysate and infused into the peritoneal cavity. Dialysate was administered one hour before scanning and the patient was encouraged to walk and strain for appropriate fluid distribution to delineate any leak. Scanning was performed with the patient in supine position, one hour after contrast administration. The contrast material dialysate mixture was drained at the end of the procedure. CT peritoneography showed that the contrast from abdominal cavity leaked in the right pleural space (Figs. 1 and 2).

Consequently, it was decided to suspend PD and the catheter for PD was removed. After 15 days, a forearm arteriovenous fistula was constructed. The patient is currently on the waiting list for kidney transplantation.

DISCUSSION

Although there are many causes of hydrothorax, it can also occur as a complication of some diagnostic and therapeutic procedures^(1,4). Pleural effusion is rarely caused by PD. Right-sided predominance in PD patients occurs because the heart and pericardium prevent the passage of fluid through the left hemidiaphragm. An increased intra-abdominal pressure in the right subphrenic space, enhanced with breathing and physical activity, contributes to this phenomenon⁽⁵⁾.

“Sweet” hydrothorax is more common in women, and the phenomenon can be explained by dilatation of the diaphragm during previous pregnancy and the possible damage to the diaphragm during that time^(5,6).

Diagnosis is mostly based on the history of shortness of breath (sudden or gradual) and chest pain⁽⁷⁾. However, in our 66-year-old female patient, the symptoms were nonspecific, including dry cough and weight gain with negative ultrafiltration that had started two weeks before. After physical examination, chest x-ray is the initial diagnostic method, followed by pleural puncture of the effusion. Thoracentesis with pleural fluid analysis is an important step in the process.

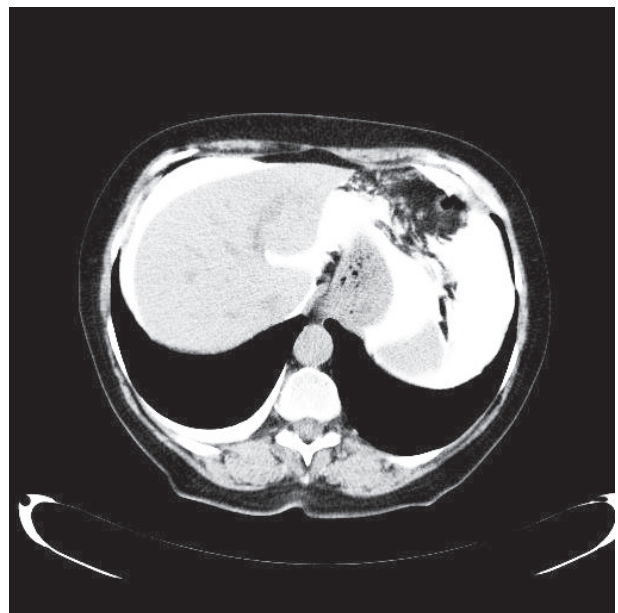
Figure 1

Computerized tomography peritoneography demonstrated leakage of dialysate from the peritoneum to the right pleural space.

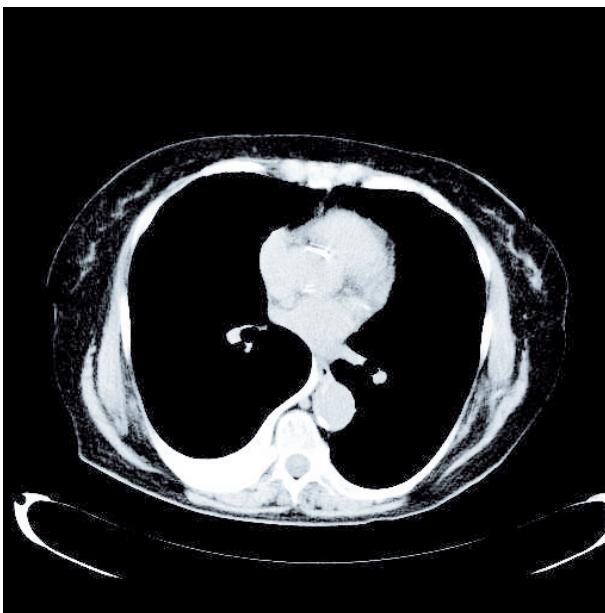

Figure 2

Computerized tomography peritoneography showed good contrast distribution in the abdominal cavity but also in the right pleural space.



High concentration of glucose in pleural effusion ('sweet hydrothorax') is an important finding, since no other type of hydrothorax has elevated glucose level⁽⁷⁾. A glucose gradient (pleural-fluid glucose level minus simultaneous serum glucose level) of more than 50 mg/dL (2.7 mmol/L) has a 100% sensitivity and specificity to detect 'sweet hydrothorax'. However, some patients have a lower glucose gradient, probably secondary to glucose reabsorption by pleural mesothelium^(6,8).

Computerized tomography peritoneography involves CT of the abdomen and pelvis after administration of a mixture of contrast material in dialysate^(4,7). Scanning is performed with the patient in supine position, one hour after contrast instillation. Delayed 4-hour scanning may be repeated if 1-hour scan is negative. Lateral decubitus or prone position may be performed for questionable findings⁽⁷⁾. CT peritoneography can demonstrate a variety of complications of PD such as peritoneal leaks, hernias and abscesses. Disadvantages of the method are exposure to ionizing radiation and iodinated contrast media⁽⁷⁾. Peritoneal scintigraphy with technetium-99m is a diagnostic method that can also be used to detect this condition⁽⁹⁾.

Different therapeutic approaches are proposed. The first-line treatment is temporary intermission of PD procedures for 1-4 months with redirection to hemodialysis. This conservative approach can be effective in half of the cases^(4,7). Other treatment options include chemical and surgical pleurodesis (obliteration of the pleural space) with talc, tetracycline, autologous blood and other agents⁽⁷⁾.

Greater diaphragmatic defects can be closed during thoracotomy by suturing and at the same time, pleurodesis by pleurectomy or pleural abrasion can be performed. Pleural abrasion and/or endoscopic closure of the diaphragmatic defects can also be performed by video-assisted thoracoscopy⁽¹⁰⁾.

In conclusion, 'sweet' hydrothorax is a rare complication of PD. It is important to include this condition in the differential diagnosis of PD patients with respiratory problems. Whereas clinical manifestations can be diverse, from asymptomatic patients to respiratory failure in significant hydrothorax, it is necessary, even in the slightest doubt, to refer suspected patients to additional diagnostic tests, of which the most sensitive and noninvasive is CT peritoneography. The treatment can be conservative or surgical.

REFERENCES

1. Light RW. Clinical practice. Pleural effusion. *N Engl J Med* 2002; 346: 1971-7.
2. Maretl M, Zrustova M, Stasny B, Light RW. The incidence of pleural effusion in a well-defined region. Epidemiologic study in central Bohemia. *Chest* 1993; 104: 1486-9.
3. Szeto CC, Chow KM. Pathogenesis and management of hydrothorax complicating peritoneal dialysis. *Curr Opin Pulm Med* 2004; 10: 315-9.
4. Chow KM, Szeto CC, Li PK. Management options for hydrothorax complicating peritoneal dialysis. *Semin Dial* 2003; 16: 389-94.
5. Michel C, Devy A, Lavaud F, Lavaud S, Lebarqy F. A 'sweet' hydrothorax. *Presse Med* 2001; 30: 1401-3.
6. Nomamoto Y, Suga T, Nakajima K *et al.* Acute hydrothorax in continuous ambulatory peritoneal dialysis collaborative study of 161 centers. *Am J Nephrol* 1989; 9: 363-7.
7. Mangana P, Arvanitis D, Vlassopoulos D. Acute hydrothorax in peritoneal dialysis patients: diagnosis and treatment options. *Nephrol Dial Transplant* 2003; 18: 2451-2.
8. Garcia Ramon R, Carrasco AM. Hydrothorax in peritoneal dialysis. *Perit Dial Int* 1998; 18: 5-10.
9. Rajnish A, Ahmad M, Kumar P. Peritoneal scintigraphy in the diagnosis of complications associated with continuous ambulatory peritoneal dialysis. *Clin Nucl Med* 2003; 28: 70-1.
10. Van Dijk CM, Ledesma SG, Teitelbaum I. Patient characteristics associated with defects of the peritoneal cavity boundary. *Perit Dial Int* 2005; 25: 367-73.

SAŽETAK

CT PERITONEOGRAFIJA – DIJAGNOSTIČKA METODA U OTKRIVANJU “SLATKOG HIDROTORAKSA” U BOLESNIKA NA PERITONEJSKOJ DIJALIZI

D. MARKIĆ, A. GRŠKOVIĆ, D. RAHELIĆ, M. MATERLJAN, M. TROŠELJ, M. PAVLETIĆ PERŠIĆ¹,
B. VUJIČIĆ¹, L. ORLIĆ¹, V. VUJIČIĆ², I. PAVLOVIĆ³ i S. RAČKI¹

Klinički bolnički centar Rijeka, Klinika za urologiju,

¹Zavod za nefrologiju i dijalizu,

²Sveučilište u Rijeci, Medicinski fakultet i Klinički bolnički centar Rijeka,

³Klinički zavod za radiologiju, Rijeka, Hrvatska

Peritonejska dijaliza (PD) se može smatrati metodom dijalitičkog izbora, jer u odnosu na hemodijalizu poboljšava kvalitetu života i preživljenje bolesnika u prve dvije godine. Hidrotoraks je rijetka komplikacija PD. Prikazujemo 66-godišnju bolesnicu kojoj je dijagnosticiran završni stadij kronične bubrežne bolesti uzrokovan kroničnim tubulointersticijskim nefritisom. Jedan mjesec od postavljanja katetera za PD bolesnica je započela s dijalitičkim liječenjem. Nekoliko tjedana od početka dijalitičkog liječenja bolesnica se počela žaliti na kašalj i porast težine. RTG snimka prsnih organa pokazala je desnostrani pleuralni izljev. Njegovom punkcijom dokazana je visoka koncentracija glukoze u aspiratu te je postavljena dijagnoza “slatkog hidrotoraksa”. CT peritoneografija je nedvojbeno pokazala da kontrast iz abdominalne šupljine ide u pleuralnu. PD je zaustavljena, a kateter za PD izvađen. Sad se bolesnica nalazi na listi čekanja za transplantaciju bubrega. “Slatki hidrotoraks” je rijetka komplikacija bolesnika na PD, a CT peritoneografija je najosjetljiviji neinvazivni dijagnostički test. U većine bolesnika PD se zamijeni hemodijalizom, ali je moguće i kirurško liječenje.

Ključne riječi: završni stadij kronične bubrežne bolesti, CT peritoneografija, peritonejska dijaliza