

# Myotubular myopathy associated with hypoxic-ischemic encephalopathy as a cause of prolonged ventilatory dependency

---

Lah Tomulic, Kristina; Dessardo, Sandro; Zamolo, Gordana; Gallati, Sabina; Gazdik, Miljen; Kučić, Natalia; Fleta, Neven

Source / Izvornik: **Signa vitae : journal for intensive care and emergency medicine**, 2006, 1, 33 - 35

Journal article, Published version

Rad u časopisu, Objavljena verzija rada (izdavačev PDF)

Permanent link / Trajna poveznica: <https://urn.nsk.hr/urn:nbn:hr:184:070380>

Rights / Prava: [Attribution 4.0 International](#)/[Imenovanje 4.0 međunarodna](#)

Download date / Datum preuzimanja: **2024-07-26**



Repository / Repozitorij:

[Repository of the University of Rijeka, Faculty of Medicine - FMRI Repository](#)



# Myotubular myopathy associated with hypoxic-ischemic encephalopathy as a cause of prolonged ventilatory dependency

KRISTINA LAH TOMULIĆ • SANDRO DESSARDO • GORDANA ZAMOLO •  
SABINA GALLATI • MILJEN GAZDIK • NATALIA KUČIĆ • NEVEN FLETA

KRISTINA LAH TOMULIĆ (✉) •  
SANDRO DESSARDO •  
MILJEN GAZDIK • NEVEN FLETA  
Pediatric Intensive Care Unit  
Department of Pediatrics  
University Hospital Rijeka  
HR-51000 Rijeka, CROATIA,  
Istarska 43/3  
Fax: +385-(0)51-62 31 26  
e-mail: k.lahtomulic@hi.htnet.hr

SABINA GALLATI  
Department of Paediatrics,  
Div of Human Genetics,  
Inselspital Bern, Switzerland

GORDANA ZAMOLO  
Department of Pathology,  
Medical Faculty, University of Rijeka

NATALIA KUČIĆ  
Department of Physiology and Immunology,  
Medical Faculty, University of Rijeka

**Key words: myotubular myopathy, muscle biopsy, genetic analysis hypoxic-ischemic encephalopathy**

## Introduction

Myotubular myopathy (centronuclear myopathy) is a rare congenital disease which can manifest as a neonatal form, a form with an early onset, and as an adult form. Muscle histopathological examination is characterised by small, rounded muscle fibres with centrally located nuclei surrounded by a perinuclear halo. These fibres resemble fetal myotubes suggesting that impaired muscle maturation underlies the pathology (1). However, recent findings strongly support the hypothesis that the X-linked myotubular myopathy (XLMTM) fibres might be intrinsically normal, and that an involvement of the peripheral nervous system may explain muscular defects observed in the disease (2).

The severe neonatal form is X-linked (XLMTM) affecting mainly male infants, and is characterized by a severe generalized hypotonia, global muscular weakness and respiratory failure. Prenatal onset of the disease is usually indi-

cated by polyhydramnios and reduced fetal movements. In the absence of significant hypoxia neuromental neuronal development is normal. Infants who survive the first few months the cryptorchidism, long fingers and toes, and a head circumference above the 90th percentile are noted. In long term survivors (more than one year), complications such as pyloric stenosis, spherocytosis, gallstones and nephrocalcinosis have been described (3). The MTM1 gene is located on Xq28 and was identified in 1996 by positional cloning (4). MTM1 contains 15 exons, it is genomically stretched over 100 kb, and encodes a phosphoinositide phosphatase, called myotubularin, involved in regulating intracellular trafficking and vesicular transport processes (5,6). A total of 192 different diseases caused by these mutations, have been described so far (7). Heterozygous female carriers of MTM1 gene mutations are usually asymptomatic, although they may demonstrate abnormal muscle biopsies and sometimes present with a mild facial weakness. Recently, rare manifesting carriers with mild to very severe symp-

toms due to structural abnormalities of one X chromosome or skewed X-inactivation have been described (8,9). Autosomal dominant and recessive forms show similar histopathological findings, however they seem to be associated with a milder clinical course.

Hypoxic-ischemic encephalopathy and respiratory distress syndrome are frequent causes of respiratory insufficiency in premature infants. Clinical signs of neuromuscular dysfunction may also be present depending on the location and severity of the brain damage. Severe forms of hypoxic-ischemic encephalopathy (grade IV), especially those forms affecting the region of frontal horns of the lateral ventricle, are presented as a generalized muscular weakness with respiratory insufficiency, which may persist for weeks (10).

## Case report

A male infant was prematurely born at 32 week's gestation to healthy, unrelated parents after a pregnancy complicated by polyhydramnios and weak fetal movements. Apgar score was 1/1/3 necessitating intubation and

artificial ventilation. The child's fingers were thin and long, and the testicles bilaterally undescended. The mother's cousin's son died a few days after birth because of the respiratory failure. The mother has a healthy 14-year old daughter from her first marriage. The laboratory findings showed a mild respiratory acidosis; chest x-ray was typical for respiratory distress syndrome. Three doses of surfactant were administered. After temporary improvement, respiratory insufficiency reoccurred and reiteration of mechanical ventilation was necessary. The brain ultrasonography showed mild ventriculomegaly. The child was hypotonic, with minimal movements of the extremities, poor tendon reflexes and insufficient spontaneous breathing. Serum creatine kinase levels were within normal ranges. A control neurosonography showed progression of the ventriculomegaly. Computed tomography of the brain revealed dilated ventricular cavities with frontal cortical brain atrophy. The electromyographic analysis showed a myopathic pattern. The muscle biopsy demon-

strated classical features of myotubular myopathy with small fibers containing centrally located nuclei surrounded by a perinuclear halo (Fig 1). The muscle vimentin and desmin were positive. During the first three months several attempts to wean the baby from the respirator had failed and the child became ventilator-dependent. After 13 months of mechanical ventilation the boy died. Molecular genetic analyses of the mother's DNA detected the frameshift mutation 593insA in exon 8 of the MTM1 gene identifying her as a proven XLMTM carrier. In the DNA sample from her 14-year-old daughter the 593insA mutation was not found excluding her from being an XLMTM carrier.

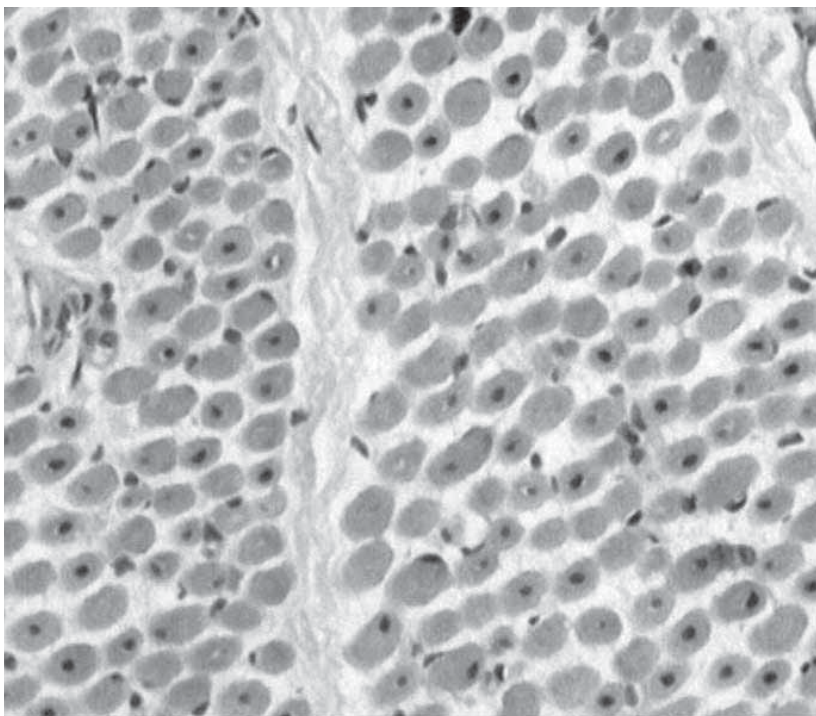
### Discussion

X-linked myotubular myopathy manifests in boys as generalized hypotonia with respiratory insufficiency. In cases where significant perinatal hypoxia can be prevented, the neuromental sequels are minimized. In complex cases where presence of myotubular myopathy and hypoxic-

ischemic encephalopathy coexist, a precise diagnosis is difficult to establish. Diagnosis of MTM1 has traditionally relied upon finding characteristic pathology in muscle biopsies. However, since the detection and isolation of the disease-causing gene MTM1, much more reliable diagnosis and carrier detection can be offered to patients and their families.

Our premature 'floppy' infant presented with severe respiratory insufficiency immediately after birth. As the chest radiograph indicated a hyalomembranous disease, he was artificially ventilated and surfactant was administered. At the same time the possibility of hypoxic-ischemic brain damage was taken into account (low Apgar score). Neurosonographic findings of periventricular changes, with progressive ventriculomegaly and frontal cortical atrophy as well as brain computed tomography confirmed the diagnosis of hypoxic-ischemic encephalopathy. The infant was still extremely hypotonic, areflexic, with minimal spontaneous movements of the arms and legs and required continuous mechanical ventilation that could not be explained by brain damage alone. The suspected underlying neuromuscular disease was confirmed by electroneuromyography and muscle biopsy findings and definitively confirmed by DNA analysis. The diagnosis was fairly unexpected, although the early death of a male infant in the mother's family could have been an indication of a positive family history. However, the exact cause of death in that case was never established as the family refused molecular genetic testing. In conclusion, we suggest that a muscle biopsy as well as molecular genetic analyses should be performed in 'floppy' infants with respiratory distress, particularly if damage of the central nervous system does not account for the child's muscle weakness and respiratory insufficiency. Since most male infants with such severe symptoms die within the first year, a rapid and accurate diagnosis is crucial, allowing the carrier testing of the mother, and, if required, a prenatal diagnosis in any subsequent pregnancy.

**Fig.1 Muscle biopsy finding: Small-sized muscle fibre with central nuclei in (centronuclear) myotubular myopathy (hemalaun-eosin x 400)**



---

## REFERENCES

- 1 Sarnat HB. Myotubular myopathy: arrest of morphogenesis of myofibres associated with persistence of fetal vimentin and desmin. Four cases with fetal and neonatal muscle. *Can J Neurol Sci* 1990; 17: 109-123.
- 2 Dorchies OM, Laporte J, Wagner S, Hindelang C, Warter JM, Mandel JL et al. Normal innervation and differentiation of X-linked myotubular myopathy muscle cells in a nerve-muscle coculture system. *Neuromuscul Disord* 2001; 11: 736-746.
- 3 Herman GE, Finegold M, Zhao W, de Gouyon B, Metzberg A. Medical complications in long-term survivors with x-linked myotubular myopathy. *J Pediatr* 1999; 134: 206-214.
- 4 Laporte J, Hu LJ, Kretz C, Mandel JL, Kioschis P, Coy JF et al. A gene mutated in x-linked myotubular myopathy defines a new putative tyrosine phosphatase family conserved in yeast. *Nature Genetics* 1996; 13: 175-182.
- 5 Blondeau F, Laporte J, Bodin S, Superti-Furga G, Payastre B, Mandel J-L. Myotubularin, a phosphatase deficient in myotubular myopathy, acts on phosphatidylinositol 3-kinase and phosphatidylinositol 3-phosphate pathway. *Hum Molec Genet* 2000;15:2223-9
- 6 Laporte J, Blondeau F, Buj-Bello A, Mandel JL. The myotubularin phosphatase family: from genetic diseases to phosphoinositide metabolism. *Trends Genet* 2001; 4:221-8.
- 7 Biancalana V, Caron O, Gallati S, Baas F, Kress W, Novelli G et al. Characterization of mutations in 77 patients with x-linked myotubular myopathy, including a family with very mild phenotype. *Human Genetics* 2003: 112: 135-142.
- 8 Hammans SR, Robinson DO, Moutou C, Kennedy CR, Dennis NR, Hughes PJ et al. A clinical and genetic study of a manifesting heterozygote with X-linked myotubular myopathy. *Neuromuscul Disord* 2000; 10:133-7.
- 9 Sutton IJ, Winer JB, Norman AN, Liechti-Gallati S, MacDonald F. Limb girdle and facial weakness in female carriers of X-linked myotubular myopathy mutations. *Neurology* 2001;5:900-902.
- 10 Volpe JJ. Brain injury in the premature infant: Neuropathology, clinical aspects, pathogenesis and prevention. *Clin Perinatol* 1997; 3: 567-587.