

Noninvasive technique of preventing thrombin escape into the systemic circulation during ultrasound-guided thrombin injection (UGTI) of the postcatheterization pseudoaneurysms

Juranić, Jurica; Protić, Alen; Sokolić, Jadranko; Šustić, Alan

Source / Izvornik: **Critical Ultrasound Journal, 2011, 3, 119 - 122**

Journal article, Published version

Rad u časopisu, Objavljena verzija rada (izdavačev PDF)

<https://doi.org/10.1007/s13089-011-0084-1>

Permanent link / Trajna poveznica: <https://urn.nsk.hr/urn:nbn:hr:184:142920>

Rights / Prava: [Attribution 4.0 International](#)/[Imenovanje 4.0 međunarodna](#)

Download date / Datum preuzimanja: **2025-01-03**



Repository / Repozitorij:

[Repository of the University of Rijeka, Faculty of Medicine - FMRI Repository](#)



Noninvasive technique of preventing thrombin escape into the systemic circulation during ultrasound-guided thrombin injection (UGTI) of the postcatheterization pseudoaneurysms

Jurica Juranic · Alen Protic · Jadranko Sokolic · Alan Sustic

Received: 27 June 2011 / Accepted: 1 November 2011 / Published online: 10 November 2011
© Springer-Verlag 2011

Abstract

Introduction Iatrogenic, postcatheterization pseudoaneurysms (PSA) of the femoral artery are a common complication after diagnostic and interventional procedures, with up to 7.7% incidence. Treatment includes surgical repair, ultrasound-guided compression (USGC) repair of the tract of the PSA, or recently ultrasound-guided thrombin injection (UGTI). Large (>1.8 cm) PSA sac with short (<3 mm) and/or wide (>3 mm) tract has higher complication ratio such as thromboembolic events after UGTI. Those cases are considered for protective balloon inflation during thrombin injection. The aim of our study was to evaluate the success rate of preventing escape of the thrombin during UGTI with simultaneous manual compression on ipsilateral iliac artery.

Methods and results We reported 46 patients, 17 males and 29 females, aged 53–74 years, with iatrogenic, postcatheterization femoral artery PSA. Out of 46 patients, 7 were successfully treated with USGC. The rest of the patients were treated with UGTI with simultaneous manual compression on ipsilateral iliac artery to stop the flow in PSA, and to avoid thrombin escape into the native circulation. Success rate of UGTI with manual compression of ipsilateral iliac artery was 97% with the complication rate of 2.6%.

Conclusion Our study confirms that UGTI treatment of the PSA of the femoral artery combined with compression of the ipsilateral iliac artery could be a safe and reliable method of the thrombin escape prevention into the systemic circulation, as good as more invasive and demanding methods.

Keywords Pseudoaneurysm · Thrombin escape · Thrombin injection · Ultrasound-guided

Introduction

Iatrogenic, postcatheterization pseudoaneurysms (PSA) of the femoral artery are a common local complication after diagnostic and interventional procedures, with up to 7.7% incidence [1–3]. In many cases, postcatheterization PSA spontaneously thromboses in a few weeks, but PSA of 1.8 cm in diameter and larger, or PSA in patients on anticoagulant/antiplatelet therapy most commonly have to be treated [4]. Treatment includes surgical repair, ultrasound-guided compression (USGC) repair of the tract of the PSA, or recently ultrasound-guided thrombin injection (UGTI) [1, 2, 5, 6]. UGTI is reserved for PSA sac larger than 1.8 cm in diameter and/or multisacular PSA, where ultrasound compression as a treatment failed [5]. It is well described that patients with large (>1.8 cm) PSA sac, with short (<3 mm) and/or wide (>3 mm) tract have higher complications ratio such as thromboembolic events after thrombin injection. Those patients are considered for UGTI with protective balloon inflation during thrombin injection which is technically and resourcefully more demanding. The aim of this study was to evaluate success rate of preventing escape of the thrombin during UGTI with simultaneous manual compression on ipsilateral iliac artery.

Methods

During the period of 3 years, we analyzed 46 patients who underwent the catheterization of the femoral artery due to therapeutic endovascular procedures. A written informed

J. Juranic (✉) · A. Protic · J. Sokolic · A. Sustic
Department of Anesthesiology and Intensive Care Unit,
University Hospital Rijeka, T. Strizica 3, 51 000 Rijeka, Croatia
e-mail: jjurica30@yahoo.com

consent was obtained from all the patients, and approved by the Institutional Review Board. Patients were clinically examined, and color Doppler examination was performed (with a 5–10 MHz linear vascular transducer, Aloka SSD-3500, Aloka, Tokyo, Japan). Before the procedure, pulse oximeter was placed on the great toe of the affected limb, and saturation was recorded before, during, and 10 min after the procedure. Pulse oximetry was used to evaluate oxygen saturation in distal parts of the affected limb. If there was a sudden fall in saturation during the procedure, we assumed possible thrombin escape into the circulation. We used VAS scale (visual analog pain scale) to evaluate pain during the compression. If VAS Scale result was more than 4, before or during the procedure, we used analgesia/sedation regime (sufentanil 5–10 μg i.v./midazolam 1–3 mg i.v.). In all the cases, the tract of the PSA was treated for 20 min with USGC repair. In the patients where USGC repair failed, we used UGTI. Ultrasound-guided

puncture with 25 G spinal needle was performed using free hand, in-plane technique. In the case of multisacular PSA, thrombin was injected into the sac closer to the artery, which usually results in thrombosis of all the other sacs. First operator analyzes blood flow through femoral artery and PSA sac, using real time US Doppler. When the position of the PSA sac, femoral artery, and neck of the PSA are confirmed, first operator performs US-guided puncture of the PSA. The whole length of the needle has to be visible during the procedure, and after precise visualization of the tip of the needle in the center of the PSA (Fig. 1), assistant operator performs manual compression of the ipsilateral iliac artery for 30 s (Fig. 2). During this period of time first operator has to be aware of the needle position and blood flow cessation in the PSA sac. After the initial 30 s first operator injects human thrombin during the next 30 s. Total amount of human thrombin [500–1,500 IU (1–3 ml) Baxter AG TISSEEL Lyo, Human Thrombin] is guided on real-time US imaging, simultaneously monitoring the formation of a stable thrombus inside the PSA sac. Before injection color Doppler has to be off to clearly see, in real time US, the formation of the thrombus inside the PSA sac. The assistant operator holds the compression for 60 more seconds after the thrombin injection is completed and then slowly releases the compression, while simultaneously the first operator monitors if there is any residual flow in the PSA sac on real-time US Doppler. The whole procedure is presented in Fig. 3. If there is present flow in the PSA sac, we perform the whole procedure again. Ten minutes after the thrombin injection, we perform color Doppler ultrasound examination of the blood flow through femoral, popliteal, and tibial posterior arteries. If there were no clinical and ultrasound signs of the peripheral artery insufficiency, no change in pulse oximetry recordings, pulmonary embolism, or systemic allergic reactions, patients were transferred to ward. Control color Doppler exam was scheduled 24 h after the procedure. We considered USGC repair or UGTI successful, if there was no blood flow in the PSA sac, 10 min and 24 h after the

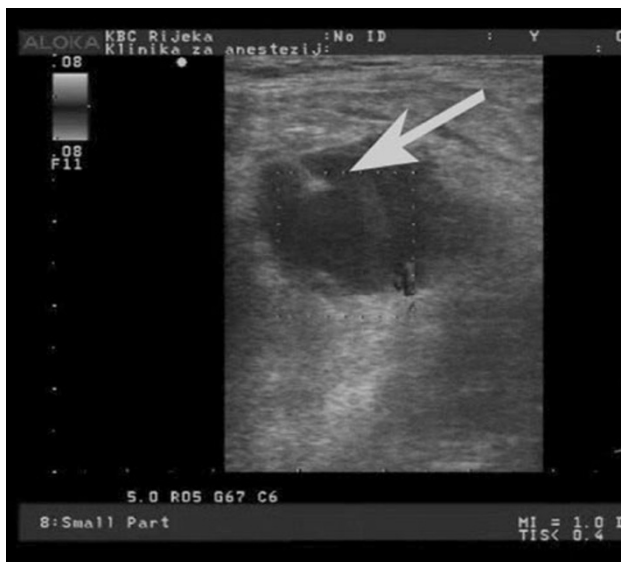
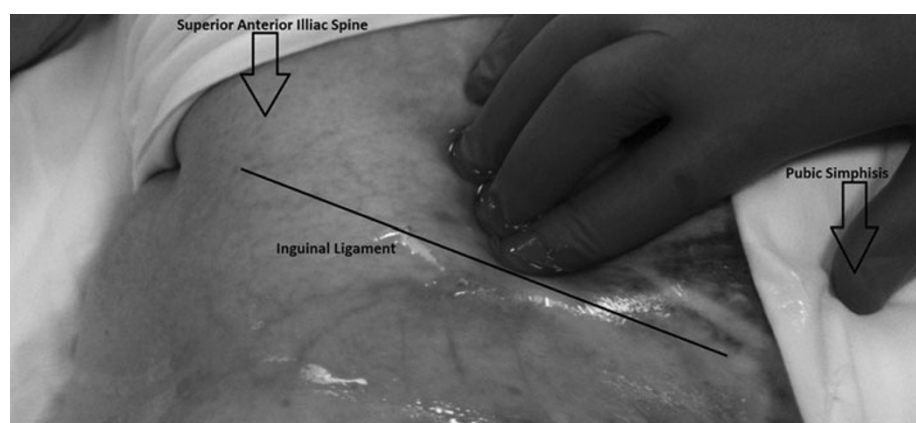


Fig. 1 There is clearly visible tip of the needle in the center of the pseudoaneurysm sac. Also whole length of the needle is visible

Fig. 2 Compression of ipsilateral iliac artery during UGTI (ultrasound-guided thrombin injection) procedure



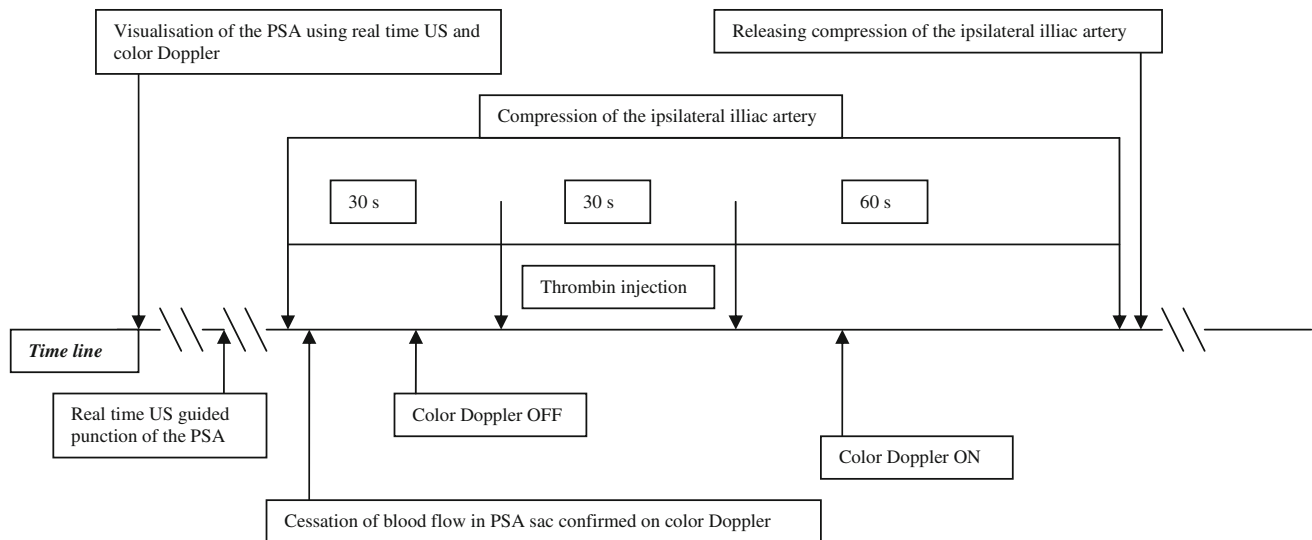


Fig. 3 The whole UGTI (ultrasound-guided thrombin injection) procedure is presented on the flow diagram. Precise timing of compression, puncture, and injection is presented on the time line.

Black arrows represent the beginning and finishing of each critical action during the procedure. PSA pseudoaneurysm, US ultrasound

procedure. In the case of complete thrombosis of the PSA without residual flow, patients were declared free of the PSA and next color Doppler exam was scheduled in 30 days.

Results

We successfully treated 46 consecutive patients, 17 males and 29 females, aged 53–74 years (median 60 years). All the patients at the time of the procedure were on antiplatelet/anticoagulation therapy for more than 3 days. All the patients included in the study were treated with USGC/UGTI within first 72 h after the puncture of the femoral artery. Seven of 46 patients were treated with USGC repair method, and 39 with UGTI with manual, ipsilateral iliac artery compression. Sixteen of 39 patients (41%) had PSA with short (<3 mm) and/or wide (>3 mm) tract. Success rate of UGTI with manual compression of ipsilateral iliac artery in this group was 100%. Success rate in the other group was 96% (PSA with longer >3 mm and narrow <3 mm tracts). Overall success rate was 97% with the complication rate of 2.6%. One patient developed thromboembolic occlusion of the distal arteries after UGTI. This patient had PSA with short (<3 mm) and wide (>3 mm) tract. Ten seconds after thrombin injection pulse oximeter recordings decreased from 96 to less than 80%. On US Doppler imaging, a significantly lower flow through the posterior tibial artery was recorded. The patient was immediately treated with intravenous heparin (desired PTT range 46–70 s) resulting in full circulation recovery in the next 12 h. None of the patients enrolled in the study

Table 1 Success and complications of the UGTI (ultrasound-guided thrombin injection) technique with simultaneous manual compression on ipsilateral iliac artery regarding two different categories of the PSA (pseudoaneurysm)

	UGTI	UGTI _(s/w)	Total
No. of patients	23	16	39
Successful procedures (%)	22 (96%)	16 (100%)	38 (97%)
Complications (%)	0	1 (6.3%)	1 (2.6%)

UGTI PSA with long (>3 mm) and narrow (<3 mm) tract, UGTI_(s/w) PSA with short (<3 mm) and/or wide (>3 mm) tract

developed infection of the puncture site or allergic reactions. Results are presented in Table 1.

Discussion

Postcatheterization PSA of the femoral artery is a relatively common complication. The fact is that catheterization of the femoral artery is a more and more performed procedure in everyday clinical practice, and the incidence of the postcatheterization PSA becomes a clinically relevant concern [2, 3]. Treatment includes open surgical repair, USGC repair of the pseudoaneurysm, and UGTI [5]. USGC repair and UGTI are proposed as first choice techniques [6]. Clinical studies report high success, with very low complications rate. USGC repair technique has some disadvantages. Compression of the PSA is very painful and demands systemic analgesia and sedation of the patient. Sometimes is hard to maintain the ultrasound probe in the proper position during the period of 20 min. In patients on

antiplatelet/anticoagulation therapy the success rate is significantly lower (63–70%). We assumed that very low success rate of the USGC repair method in our study (15%) is due to mandatory anticoagulation or/and antiplatelet therapy of our patients. In opposite, UGTI is a simple method with low complication rate and well tolerated by patients [1, 6, 10, 13, 14]. Therapeutic results of the UGTI are highly successful and complete thrombosis of the PSA is achieved in 93–100% of cases [2, 5]. Complications of the UGTI procedure (up to 4%) are most frequently due to escape of the thrombin into the systemic circulation and allergic reactions [7]. Complications like distal embolisation require more invasive and active therapy, such as application of the activator of tissue plasminogen, intravenous heparin, or open surgical exploration [2, 11]. Two methods of UGTI are described: with protective balloon placement and without it. The aim of the protective balloon placement is to avoid thrombin escape from the pseudoaneurysm sac, usually through the wide or/and short tract of the PSA [2]. Despite the fact that balloon protection is not suggested in routine use, in cases of short (<3 mm) or/and wide (>3 mm) PSA tract, numerous studies recommend it [2, 8–10, 12]. As a method to avoid thrombin escape into the circulation in this study, we used noninvasive manual compression on the ipsilateral iliac artery to stop the flow in PSA, 30 s before, 30 s during the procedure, and 60 s after the UGTI procedure. We performed this simple maneuver on all our patients regardless of the sizes of the PSA tract, but finally our aim was to protect those patients with short (<3 mm) and/or wide (>3 mm) pseudoaneurysm tract. There is a need for larger series of patients to confirm our results. Our study confirms that UGTI treatment of the PSA of the femoral artery combined with compression of the ipsilateral iliac artery could be a safe and reliable method of preventing thrombin escape into the systemic circulation, as effective as more invasive and demanding methods.

Conflict of interest None.

References

1. Ahmad F, Turner SA, Torrie P, Gibson M (2008) Iatrogenic femoral artery pseudoaneurysms—a review of current methods of diagnosis and treatment. *Clin Radiol* 63:1310–1316
2. Morgan R, Belli AM (2003) Current treatment methods for postcatheterization pseudoaneurysms. *J Vasc Interv Radiol* 14:697–710
3. San Norberto García EM, González-Fajardo JA, Gutiérrez V, Carrera S, Vaquero C (2009) Femoral pseudoaneurysms post-cardiac catheterization surgically treated: evolution and prognosis. *Interact Cardiovasc Thorac Surg* 8:353–357
4. Webber GW, Jang J, Gustavson S, Olin JW (2007) Contemporary management of postcatheterization pseudoaneurysms. *Circulation* 115:2666–2674
5. La Perna L, Olin JW, Goines D, Childs MB, Ouriel K (2000) Ultrasound-guided thrombin injection for the treatment of postcatheterization pseudoaneurysms. *Circulation* 102:2391–2395
6. Paschalidis M, Theiss W, Kölling K, Busch R, Schömig A (2006) Randomised comparison of manual compression repair versus ultrasound guided compression repair of postcatheterisation femoral pseudoaneurysms. *Heart* 92:251–252
7. Luedde M, Krumsdorf U, Zehelein J, Ivandic B, Dengler T, Katus HA, Tiefenbacher C (2007) Treatment of iatrogenic femoral pseudoaneurysm by ultrasound-guided compression therapy and thrombin injection. *Angiology* 58:435–439
8. Matson MB, Morgan RA, Belli AM (2001) Percutaneous treatment of pseudoaneurysms using fibrin adhesive. *Br J Radiol* 74:690–694
9. D' Ayala M, Smith R, Zanieski G, Fahoum B, Tortólani AJ (2008) Acute arterial occlusion after ultrasound-guided thrombin injection of a common femoral artery pseudoaneurysm with a wide, short neck. *Ann Vasc Surg* 22:473–475
10. Elford J, Burrell C, Freeman S, Roobottom C (2002) Human thrombin injection for the percutaneous treatment of iatrogenic pseudoaneurysms. *Cardiovasc Interv Radiol* 25:115–118
11. Sadiq S, Ibrahim W (2001) Thromboembolism complicating thrombin injection of femoral artery pseudoaneurysm: management with intraarterial thrombolysis. *J Vasc Interv Radiol* 12:633–636
12. Kruger K, Zaehring M (2005) Postcatheterization pseudoaneurysm: results of US-guided percutaneous thrombin injection in 240 patients. *Radiology* 236:1104–1110
13. Paulson EK et al (2001) Sonographically guided thrombin injection of iatrogenic femoral pseudoaneurysms. *AJR* 177:309–316
14. Brophy DP et al (2000) Iatrogenic femoral pseudoaneurysms: thrombin injection after failed US-guided compression. *Radiology* 214:278–282