

HISTOLOGICAL CHORIOAMNIONITIS AND RETINOPATHY OF PREMATURITY: IS THERE A CAUSAL RELATIONSHIP?

Jurišić, Nikolina

Master's thesis / Diplomski rad

2018

Degree Grantor / Ustanova koja je dodijelila akademski / stručni stupanj: **University of Rijeka, Faculty of Medicine / Sveučilište u Rijeci, Medicinski fakultet**

Permanent link / Trajna poveznica: <https://um.nsk.hr/um:nbn:hr:184:993103>

Rights / Prava: [In copyright](#)/[Zaštićeno autorskim pravom.](#)

Download date / Datum preuzimanja: **2024-11-30**



Repository / Repozitorij:

[Repository of the University of Rijeka, Faculty of Medicine - FMRI Repository](#)



SVEUČILIŠTE U RIJECI

MEDICINSKI FAKULTET

INTEGRIRANI PREDDIPLOMSKI I DIPLOMSKI

SVEUČILIŠNI STUDIJ MEDICINE

Nikolina Jurišić

HISTOLOŠKI KORIOAMNIONITIS I RETINOPATIJA PREMATURITETA:

POSTOJI LI UZROČNOPOSLEDIČNA POVEZANOST?

Diplomski rad

Rijeka, 2018.

SVEUČILIŠTE U RIJECI

MEDICINSKI FAKULTET

INTEGRIRANI PREDDIPLOMSKI I DIPLOMSKI

SVEUČILIŠNI STUDIJ MEDICINE

Nikolina Jurišić

HISTOLOŠKI KORIOAMNIONITIS I RETINOPATIJA PREMATURITETA:

POSTOJI LI UZROČNOPOSLEDIČNA POVEZANOST?

Diplomski rad

Rijeka, 2018.

Mentor rada: izv. prof. dr. sc. Sandro Dessardo, dr. med.

Diplomski rad, ocjenjen je dana _____ u/na _____

_____, pred povjerenstvom u sastavu:

1. _____

2. _____

3. _____

Rad sadrži 28 stranica, 3 slika, 3 tablica, 33 literaturnih navoda.

Zahvala

Zahvaljujem svom mentoru prof.dr.sc. Sandru Dessardu, dr.med. na ukazanom strpljenju i nesebičnom djeljenju podataka svog istraživanja za pisanje ovog rada.

Neizmjerno hvala mojoj obitelji (roditeljima, sestri te baki i djedu), koji su mi omogućili da živim svoje snove i na tom putu bili vjerna podrška.

Hvala mojim dragim prijateljima i kolegama (Luciji, Fridi, Viktoriji, Nives, Josipu, Ani, Boženi i Franki) koji su moje školovanje učinili ljepšim i zabavnijim.

I veliko hvala mojoj najboljoj prijateljici Belli. Ovaj rad posvećen je njoj, za koju sam se uvijek nadala da će biti sa mnom u ovim sretnim trenucima.

Contents:

INTRODUCTION.....	1
Preterm birth.....	1
Chorioamnionitis:.....	1
Reematurityinopathy of pr:	3
PURPOSE	6
METHODS.....	7
Patients	7
Placental examination.....	8
Perinatal variables	8
Statistics	8
Path analysis.....	9
RESULTS.....	11
Population characteristics and outcome	11
Standard statistics	13
Path-analysis:.....	16
DISCUSSION	18
SUMMARY	22
CONCLUSION	23
REFERENCES.....	24

INTRODUCTION

Preterm birth

According to World Health Organization (WHO) preterm is defined as: “newborns born alive before 37 weeks of pregnancy are completed”. There are sub-categories of preterm birth, based on gestational age: extremely preterm (less than 28 weeks), very preterm (28 to 32 weeks) and moderate to late preterm (32 to 37 weeks)". Every year, an evaluated 15 million babies are born preterm worldwide (more than 1 in 10 babies), and this number is rising. Problem is that globally, complications from prematurity are the leading cause of death in children under the age of 5. Preterm birth can be caused by many various reasons (multiple pregnancies, infections and many chronic conditions of mother) but often no cause is identified. (1)

Chorioamnionitis:

One of the main risk factors of preterm birth is chorioamnionitis or intraamniotic infection (IAI) which is an acute inflammation of the membranes and chorion of the placenta. (2)

Usually it is a result of ascending polymicrobial bacterial infection in the setting of membrane rupture, but uncommonly it can occur with intact membranes and this appears to be especially common for Ureaplasma species and Mycoplasma hominis, found in the lower genital tract (cervix and vagina) of over 70% of women. (3)

„That induce the development of maternal and fetal inflammatory response characterized by the release of a combination of cytokines and chemokines. The inflammatory response leads to prostaglandin release, ripening of the cervix, membrane injury and labor at term or premature birth.” (2)

Risk factors of the development of chorioamnionitis are various and include: null parity, multiple vaginal exams, internal monitoring of labor, colonization with group B streptococcus, bacterial vaginosis, sexually transmitted genital infections and vaginal colonization with Ureaplasma, smoking, alcohol or drug abuse, immune-compromised states and epidural anesthesia. (2)

There are two types of chorioamnionitis: clinical, suggested by the name is diagnosed by clinical signs and symptoms and histological chorioamnionitis (HCA) which could be subclinical. With an improvement in prenatal care, pregnant women with clinical presentations of chorioamnionitis are becoming less frequent (less than 40% of cases of histological chorioamnionitis.) (4)

Because of that it is very important to reach an early diagnosis in these patients and histologic examination of the placenta is essential to confirm the diagnosis. (5)

“The characteristic clinical picture is always represented as maternal fever (body temperature $> 38.5^{\circ}\text{C}$) plus two or more of the following symptoms and signs: maternal tachycardia (>120 beats per minute [bpm]), fetal tachycardia (bpm $> 160-180$), maternal leukocytosis (white blood cells [WBC] $> 15,000$ cells/mm³), uterine tenderness, purulent or foul-smelling amniotic fluid or vaginal discharge and with no other infections. If there are present at least two of the criteria the risk of neonatal sepsis is increased. “(6)

The diagnosis is confirmed by laboratory tests which include complete blood count (CBC) (maternal leukocytosis or the presence of a left shift), other blood tests (possible high levels of C-reactive protein) and amniotic fluid testing. Placental and umbilical cord pathology are also very important in diagnosis, because of the greater frequency of histological chorioamnionitis. (2)

The fetal response to infection termed as the fetal inflammatory response syndrome (FIRS), describes cord blood elevations of the fetal interleukin-6 (IL-6) level, which is a marker for inflammation and fetal organ injury. (2, 8)

Timely and valid antibiotic therapy is essential to prevent maternal and fetal complications.(9)

Chorioamnionitis and FIRS are significantly associated with shorter gestation and lower birth weight. (10) The mentioned factors are the leading causes of retinopathy of prematurity (ROP), the major cause of childhood blindness. (11)

Retinopathy of prematurity:

ROP is a disease that occurs only in immature retinal tissue, first described in 1942 by Terry, who was considering prematurity a major cause of ROP. But in 1950s other authors found that an immoderate amount of oxygen supplementation also caused the disease, so Patz started more restrictive use of oxygen supplements. As a result, the incidence of the disease decreased but morbidity and mortality increased. (12)

“Retinal angiogenesis beginning at 16th week of gestation starts from the optic disc to the periphery and finishes at 40th week. “(13)

The basic pathogenesis of ROP is still unknown, but a number of studies have shown that many various risk factors exist, such as multiple births, male sex, intrauterine growth retardation, mechanical ventilation, respiratory distress syndrome and etc. (14)

Clinical manifestations range from mild to moderate, usually transitory, changes of the peripheral retina (in more than 90 % of risk infants) to serious progressive vasoproliferation, scarring, and potentially blinding retinal detachment.

Classification of ROP is based on 3 concentric zones and 5 stages. Zones (describe location) measure how far the normal progression of blood vessels develops before the disease is

involved. "Zone I, the posterior or inner zone, extends twice the disc-macular distance or 30 degrees in all directions from the optic disc. Zone II, the middle zone, extends from the outer edge of zone I to the *ora serrata* nasally and to the anatomic equator temporally. Zone III, the outer zone, is the residual crescent that extends from the outer border of zone II to the *ora serrata* temporally. The extent of involvement is described by the number of circumferential clock hours involved. "(13)

Staging of disease is done according to degree of vascular changes. Stage 1 is characterized by demarcation line, thin structure separating avascular from vascular area. Demarcation line lies within the plane of the retina. In stage 2 the demarcation line actually begins to develop in the rolled ridge of tissue. Stage 3, characterized by the development of extraretinal fibrovascular tissue. Stage 4 is subdivided into 2 phases: partial retinal detachment outside of macula with chance for usable vision, and partial retinal detachment involving the macula with limited prospect for usable vision. They are both caused by scar tissue. Stage 5 or complete retinal detachment, with no useful vision in that eye. Very important sign of rapid progression is plus disease, with typically tortuosity of the normal blood vessels in the retina; absolute indication for treatment. (13)

Serial screening is performed by ophthalmologist with ophthalmologist exams and indirect ophthalmoscopy of premature infants at risk. US guidelines recommend screening for all infants of gestational age (GA) 30 weeks or younger or birth weight (BW) 1500 g or less as well as for infants older than 30 weeks GA at the discretion of the neonatologist for those with an unstable clinical course. (15)

“The timing of first eye examination is based on gestation age at birth, mostly between 4th to 7th weeks after birth. “(13)

In selected cases, cryotherapy or laser photocoagulation of the avascular retina reduces the more severe complications of progressive ROP. (13) Laser photocoagulation is the gold standard for treating, the off-label use of anti-vascular endothelial growth factor (anti-VEGF) therapy to treat ROP is increasing. (16)

PURPOSE

The aim of this study was to find out is there a causal relationship between histological chorioamnionitis (CA) and retinopathy of prematurity (ROP). A number of studies has tried to evaluate this hypothetical connection, but that relation has not been well established yet. However, these previous studies confirmed histological chorioamnionitis as one of the major risk factors for prematurity, which is the leading risk factor for development of retinopathy of prematurity; a major cause of childhood blindness. With the aim to discover an effective prevention of ROP, and save the usable vision in these premature neonates, we designed a prospective, cohort study to analyze the effect of chorioamnionitis on later development of retinopathy of prematurity, with the use a path-analysis methods to compare the results with the results obtained using standard statistical methods.

METHODS

Patients

Between January 1999 and December 2008, all neonates with less than 32 weeks of completed gestational age were screened for ROP in accordance with the screening criteria proposed by, American association for pediatric ophthalmology and strabismus screening examination of premature infants for retinopathy of prematurity at the Neonatal Intensive Care Unit (NICU) of the University Hospital Center Rijeka (Croatia). (18)

All the preterm infants with the diagnosis of ROP were followed up for at least 45 weeks of postmenstrual age or until full retinal vascularization or effective stabilization of retinopathy after treatment. During the study period, demographic, antenatal, delivery and outcome data for all infants have been entered prospectively into the database by the attending practitioners. Infants who died before the 36th week of postconceptional age as well as infants with congenital malformations including eyes malformations were excluded.

Maternal, obstetric and neonatal records were reviewed.

The screening sessions and the follow-up were performed according to guidelines to detect the ROP, which recommended initial ophthalmological examination between the fourth and sixth week of life or from 31-33 week of postmenstrual age, whichever came first.

ROP screening was performed by two attending retinal specialist from 1999 to 2008.

The follow-up examinations were repeated weekly or more frequently according to the findings until normal vascularization began in zone 3.

The stages of ROP were classified according to the International Classification of Retinopathy of Prematurity. (18)

Placental examination

The placentas were regularly submitted for histopathological diagnosis in all cases of premature delivery. An experienced pathologist in placental pathology examined the placentas according to the published guidelines by Langston. (19)

A minimum of three cross-sections of the umbilical cord taken from its fetal and placental side, three membrane rolls and a sample of the chorionic plate. The inflammatory findings at histology were recorded and accounted for the worst area scored, according to the classification proposed by Redline. (20)

For the purpose of this study, newborns were classified as having FIRS if severe histological chorioamnionitis and funisitis were confirmed to be present. (21, 22)

Perinatal variables

The perinatal variables considered for the study included gender, gestational age at birth, birth weight, 5-min Apgar score, use of surfactant and mechanical ventilation, duration of oxygen inhalation, presence of neonatal sepsis and patent ductus arteriosus (PDA).

Statistics

Descriptive statistics was used for group comparisons (HCA vs FIRS, ROP 0-2 vs ROP3-5) that were used to examine the data. Pearson chi-square and Fischer exact tests were used to determine differences between categorical variables. Analyzed proportional differences, with $p = 0.01$ considered as the level of significance. Cross-tabulation was used to identify significant associations between related variables. We used multivariable logistic regression analysis to examine the relationships between chorioamnionitis, neonatal outcome and ROP.

Computations were performed with SPSS v 14.0 for Windows (2006). Chicago, USA: SPSS Inc.

Path analysis

Path analysis is not a substitute of regression analysis; rather, it is a complementary methodology to regression analysis, used to trace out indirect effects and display all of the causal relationship. The crucial task in path analysis is to formulate a plausible path diagram based on existing evidence and current biological concepts.

To test the relationship between FIRS, HCA, GA, MV, sO₂, and ROP, we performed two path analysis. The relationships between variables in either of them were the same, although we changed the “prenatal inflammation“ variable. In the first one, it was the presence or absence of HCA, and in the second one, it was the presence or absence of FIRS (severe HCA and funisitis).

Each dependent variable, starting at the far right of the model, was regressed initially on the first variable on the extreme left. The next variable to the right of that independent variable than was entered into the model, forcing in all preceding variables. This process continued until all independent variables to the left of the dependent variable were included in the regression equation. The same process then was repeated with the variable second from the right as the dependent variable, and so on until each variable and all preceding variables had been regressed. The regression coefficient for a variable when it first entered the model represents the total effect, which is free of the effect of all previously occurring variables. The coefficient for a variable represents the direct effect of the variable on the dependent variable when all other variables are included in the model.

The major benefit of path analysis is the ability to estimate both, direct and indirect effects of variables on specified outcomes and, in so doing, to more fully comprehend the hypothesized causal web. The strength of the effect in the path analysis is represented by a path coefficient

whereby absolute values less than 0.10 indicate a „small“ effect; values around 0.30, a „medium“ effect; and values greater than 0.50, a „large“ effect. (23)

Computations for the path analysis were performed with LISREL 8 (1996; Scientific Software International, Chicago, IL).

RESULTS

Population characteristics and outcome

The study enrollment pathway led to a final study sample of 262 infants. (Figure 1)

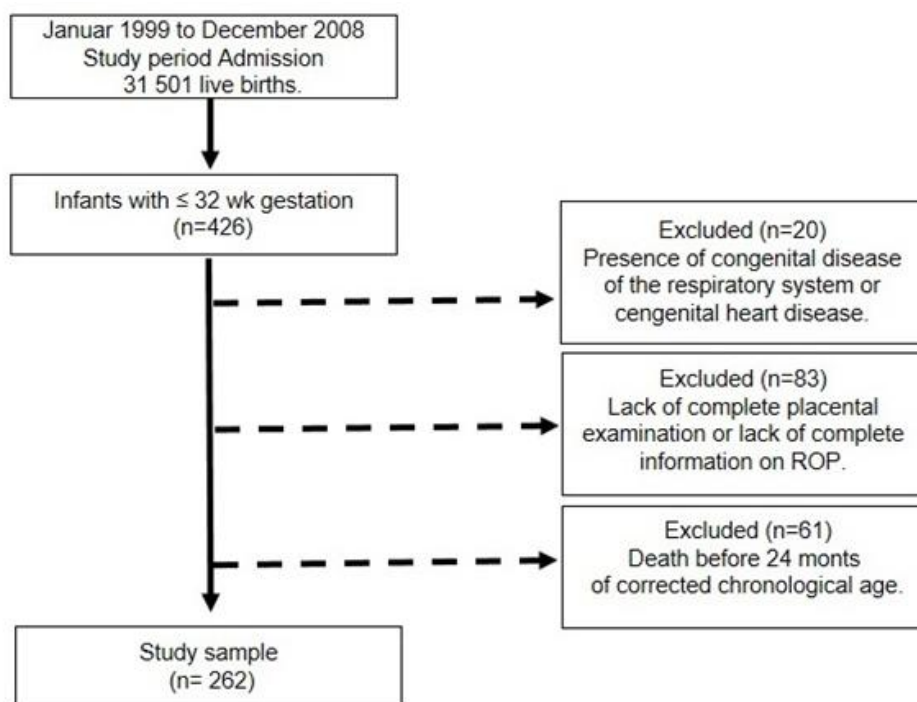


Figure 1: Schematic diagram of the distribution of infants in the study

Among the newborns enrolled in the study, 105/262 (40%) had histological chorioamnionitis and 45/262 (17%) had FIRS. Of the enrolled newborns, 60/262 (23%) had retinopathy of prematurity in any stage, of which 36/262 (14%) were classified having retinopathy of prematurity stage 1 or 2 and 24 (9%) of them had stage 3 or more. (Table 1)

There wasn't significant gender disparity found in ROP incidence.

Table 1: Demographic and clinical characteristics of the patients

Characteristics	N= 262
Gestation age (weeks)	
Median	30
Distribution – no. (%)	
< 28	42 (16)
28-30	49 (20)
31-32	171 (64)
Male sex- no. (%)	129 (49)
Birth weight (grams)	
Mean (grams)	1420
Distribution –no. (%)	
<1000	40 (15)
1000-1499	105 (40)
>1500	117 (45)
Placentas histology - no. (%)	
Chorioamnionitis	105 (40)
Fetal inflammatory response syndrome (FIRS)	45 (17)
Amniotic infection – no. (%)	37 (14)
Apgar score at 5 minutes < 6 – no. (%)	73 (28)
Surfactant – no. (%)	74 (28)
Mechanical ventilatory support – no. (%)	80 (30)
Neonatal sepsis– no. (%)	100 (38)
Patent ductus arteriosus– no. (%)	42 (16)
Chronic lung disease	62 (24)
Retinopathy of prematurity in any stage (ROP) –no. (%)	60 (23)
NoROP	202 (77)
ROP ≤ 2	36 (14)
ROP ≥ 3	24 (9)

Among the newborns enrolled in the study, 105/262 (40%) had histological chorioamnionitis and 45/262 (17%) had FIRS. Of the enrolled newborns, 60/262 (23%) had retinopathy of prematurity in any stage, of which 36/262 (14%) were classified having retinopathy of prematurity stage 1 or 2 and 24 (9%) of them had stage 3 or more. (Table 1)

Standard statistics

In multivariable analysis, development of ROP (any stage) was associated with shorter gestation age, lower birth weight and lower Apgar score at 5 minutes. Also premature infants with diagnosis of chronic lung disease (CLD) had higher chance for development of ROP.

A severe form of prenatal infection (FIRS) was also associated with ROP, but histological chorioamnionitis doesn't.

Table 2: Multivariate logistic regression analysis of significance of risk factors for the development of retinopathy of prematurity in any stage.

Clinical Characteristics	ROP		Odds Ratio 95% Confidence Interval	X ²	P	
	Stage ≥3	Stage ≤2				
Gestation age <30 weeks	Yes	17 (70.8%)	76 (31.9%)	5.17 (2.06-13.01)	12.760	<0.001
	No	7 (29.2%)	162 (68.1%)			
Gestation age <28 weeks	Yes	12 (50.0%)	34 (14.3%)	6.00 (2.49-14.46)	16.823	<0.001
	No	12 (50.0%)	204 (85.7%)			
Birth weight <1500 grams	Yes	22 (91.7%)	123 (51.7%)	10.28 (2.37-44.72)	12.533	<0.001
	No	2 (8.3%)	115 (48.3%)			
Birth weight <1000 grams	Yes	9 (37.5%)	31 (13.0%)	4.00 (1.62-9.94)	8.292	0.004
	No	15 (62.5%)	207 (87.0%)			
Chorioamnionitis	Yes	16 (66.7%)	89 (37.4%)	3.34 (1.38-8.14)	6.607	0.01
	No	8 (33.3%)	149 (62.6%)			

FIRS	Yes	10 (41.7%)	35 (14.7%)	4.14 (1.71-10.06)	9.325	0.002
	No	14 (58.3%)	238 (85.3%)			
Amniotic infection	Yes	6 (25.0%)	31 (13.0%)	2.22 (0.82-6.04)	1.685	0.19
	No	18 (75.0%)	207 (87.0%)			
Apgar score at 5 minutes < 6	Yes	13(54.2%)	60 (25.2%)	3.50 (1.49-8.24)	7.711	0.005
	No	11(45.8%)	178 (74.8%)			
Chronic lung disease	Yes	10 (41.7%)	52 (21.8%)	2.55 (1.07-6.09)	3.706	0.05
	No	14 (58.3%)	186 (78.2%)			
Surfactant	Yes	9 (37.5%)	65 (27.3%)	1.597 (0.67-3.83)	0.671	0.41
	No	15 (62.5%)	173 (72.7%)			
Mechanical ventilatory support	Yes	10 (41.7%)	70 (29.4%)	1.71 (0.73-4.04)	1.020	0.31
	No	14 (58.3%)	168 (70.6%)			
Neonatal sepsis	Yes	13 (54.2%)	87 (36.6%)	2.05 (0.88-4.78)	2.168	0.14
	No	11 (45.8%)	151 (63.4%)			
Patent ductus arteriosus	Yes	7 (29.2%)	35 (14.7%)	2.38 (0.92-6.18)	2.398	0.12
	No	17 (70.8%)	203 (85.3%)			

In multivariable analysis, ROP stage 3 or worse was associated with a shorter gestation, lower birth weight, and lower Apgar score at 5 minutes. Prenatal exposure to inflammation; severe (FIRS) form, showed an increase risk for high stage ROP. Children with CLD and DAP were associated with an appreciably increased risk for ROP ≥ 3 . (Table 3)

Table 3. Multivariate logistic regression analysis of significance of risk factors for the development of retinopathy of prematurity in stage ≥ 3 ($X^2=10.781$; $p=0.462$).

Clinical characteristics	ROP in stage ≥ 3		
	Odds Ratio	95% Confidence Interval	P
Gestation age < 30 weeks	0.76	0.34 - 1.74	0.03
Birth weight < 1500 grams	0.72	0.33 - 1.58	0.04
Chorioamnionitis	0.87	0.41 - 1.87	0.23
FIRS	1.17	0.40 - 3.41	0.15
Amniotic infection	0.90	0.38 - 2.12	0.51
Apgar score at 5 minutes < 6	0.68	0.33 - 1.41	0.08
Chronic lung disease	0.67	0.27 - 1.61	0.04
Surfactant	1.46	0.67 - 3.18	0.50
Mechanical ventilatory support	1.20	0.51 - 2.83	0.24
Neonatal infection	0.99	0.46 - 2.14	0.21
Patent ductus arteriosus	0.52	0.23 - 1.17	0.03

Path-analysis:

The obtained path coefficients show that chorioamnionitis has a significant overall effect on gestational age (-0.35), but it is not significant at ROP (0.10). Chorioamnionitis has a significant overall effect on BPD (0.18) which is completely irreversible. Its indirect effect on ROP is statistically significant and is 0.07. The overall gestational age effect on BPD is -0.52, ROP -0.20, and overall BPD effect on ROP 0.15. All of these effects are significant.

(Figure 2)

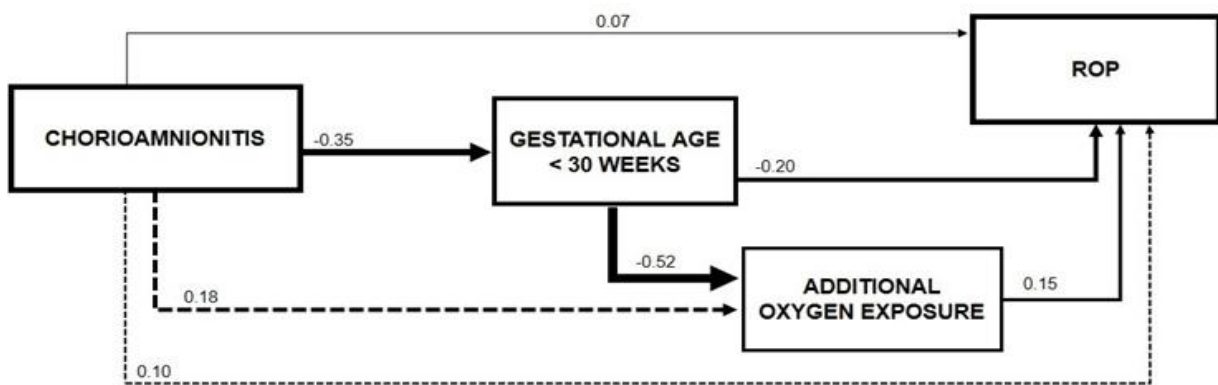


Figure 2: Path diagram for causality of retinopathy of prematurity including the presence of histological chorioamnionitis as an indirect variable.

The obtained path coefficients show that FIRS has a significant total effect on gestational age (-0.53), but not significant on ROP (0.07). FIRS has a significant total BPD effect (0.27) that is completely inconsistent. Its imprecise effect on ROP is statistically significant and amounts to 0.12. The overall gestational age effect on BPD is -0.52, ROP -0.23, and overall BPD effect at ROP 0.19. All of these effects are significant. (Figure 3)

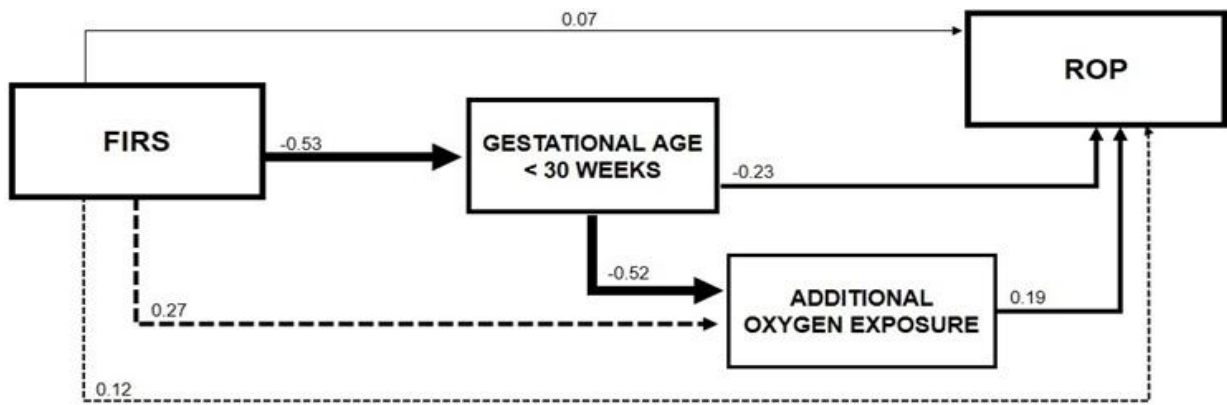


Figure 3: Path diagram for causality of retinopathy of prematurity including the presence of severe chorioamnionitis and funisitis (FIRS) as an indirect variable.

DISCUSSION

Analysis of data from our study population with conventional statistical methods showed us that there is a strong association between shorter gestational age, lower birth weight, FIRS, lower Apgar score at 5 minutes, and development of ROP (any stage), but it is not the case with the histological chorioamnionitis, amniotic infection, surfactant use and mechanical ventilator support. However, with path analysis we confirmed that histological chorioamnionitis and FIRS, both of them have significant effect on gestational age but not significant effect on development of ROP.

Study limitation was a sample size, only 60 of 262 premature neonates have diagnosed ROP in any stage, and if we consider the number of infants who have ROP in stage 3 or worse, there were only 24 of them.

Numerous studies have tried to evaluate the relationship of histological chorioamnionitis and retinopathy of prematurity. Histological chorioamnionitis, present in 36% of pregnancies shorter than 32 weeks, can lead to preterm delivery and fetal inflammatory response syndrome and consequent fetal tissue injury. (24)

Intrauterine inflammation can be responsible for the “first hit” to fetal organism which is followed by various postnatal “multiple hits”, associated with conditions like chronic lung disease of prematurity, necrotizing enterocolitis and neurological pathologies as white matter injury, intraventricular hemorrhage and cerebral palsy. (10, 25)

And that pathogenesis is explained with consequently pro-inflammatory cytokines release as a response to maternal systematic inflammation such as tumor necrosis-factor alpha and interleukins (IL-)-1, IL-6 and IL-8, which are available to pass blood-brain barrier leading to brain cells damage (oligodendroglia). (26)

When we talk about risk factors for development of ROP, it is very important to mention that some studies have confirmed that increased cytokines levels in the premature infant serum in the first three days of life have a big role in the development of ROP. (27)

Moreover, chorioamnionitis leads to a release of insulin-like growth factor (IGF), also associated with development of ROP, according to some studies. (28)

So we can assume that chorioamnionitis has an important role in the development of ROP, but actual establishing of this hypothesis is a challenge because of a number of confounding factors. One of them is prematurity, since lower GA and lower birth weight are associated with increased oxygen therapy, a “known risk factor” for ROP. For example, a meta-analysis designed by Saugstad and Aune, has shown that a lower oxygen saturation targeting by pulse oximetry reduced the development of severe stages of ROP, from 20,9% to 9,5%. (31)

A big meta-analysis designed by Mitra et al. in 2015 included 10,590 preterm infants across 27 studies, and had a goal to evaluate the relation between histological chorioamnionitis and the development of ROP. The results have shown that a relative risk (RR) of developing ROP was significantly higher in infants exposed to histological chorioamnionitis, more precisely 33% more chance to develop ROP. Also, there was a significant (27%) chance for the development of severe ROP (stage 3 or worse). But only 8 out of 27 studies has adjusted for gestational age the meta-analysis of data, showing no significant association between histological chorioamnionitis and retinopathy of prematurity. (29)

A second possible confounding factor was explained by Dammann et al. (30) in their study about genetic variation. In that study they are comparing a whole genome expression in the first months of life in two different groups: one group were infants with ROP in any stage and other were infants without ROP.

In the results we can see that more genes were under-expressed than over-expressed in the group with ROP. And this information may be an explanation why more than 90% of premature infants with ROP regress spontaneously or progress in mid-stages and in 10% the disease progresses in severe stages. (31)

In a Danish national study “Neonatal Risk Factors for Treatment- Demanding Retinopathy of Prematurity”, the goal was to identify statistically significant risk factors for development of ROP, and from 31 potential risk factors they found only 2 factors statistically significant: mechanical ventilation and blood transfusion. (32)

In our study mechanical ventilation wasn't a statistically significant risk factor for development of ROP. Perhaps it could be explained by the sample size, since only 80 out of 262 (30%) premature infants were exposed to mechanical ventilation. However a possible reason could be found in the fact that during mechanical ventilation support in preterm there is a marked tendency to avoid high oxygen saturations in order to avoid potential complications of hyperoxia. Thus, the preterm on mechanical ventilation shouldn't have undergone levels of hyperoxia. In a study published in 2009, the centers included had a tendency to a restrictive use of mechanical ventilation, and the target for titrating oxygen supply was in the range of 85% to 96% according to international recommendations. (30)

In 2013 the Neonatal Oxygen Prospective Meta-analysis Collaboration reported that lower oxygen saturation (85-89%) compared with higher oxygen saturation (91%-95%) was associated with lower rates of ROP treatment but higher mortality and there was no difference of major disability (blindness included). (33)

In the already mentioned they take Apgar score like a variable as well, and it is divided into 3 levels: 1 to 3, 4 to 6 and 7 to 9, and only Apgar score level 4-6 was statistically significant.

We also take that level of Apgar score for our research and we have found it statistically significant, especially for the development of severe stages of ROP. (32)

SUMMARY

Every year more than 15 million babies are born preterm (born alive before 37 weeks of pregnancy are completed, according to WHO), and that number is rising. Complications from prematurity are the leading cause of death in children under the age of 5. One of the main risk factors of preterm birth is chorioamnionitis, acute inflammation of the membranes and chorion of the placenta. Chorioamnionitis can lead to development of maternal and fetal inflammatory response characterized by the release of cytokines and chemokines. That encourages prostaglandin release, ripening of the cervix, membrane injury and preterm birth. Preterm birth is major risk factor for development retinopathy of prematurity, retinal vascular disease, main cause of childhood blindness. We designed a prospective cohort study, that included born premature infants less than 32 weeks of gestation, during period between January 1999 and December 2008, whose placentas were regularly submitted for histopathological diagnosis. The aim of this study was to evaluate a causal relationship between histological chorioamnionitis and retinopathy of prematurity with the use a standard descriptive statistics and path-analysis. Like other similar studies we confirmed that histological chorioamnionitis cannot be definitively considered as risk factor for development of retinopathy of prematurity in any stage.

CONCLUSION

Analysis of data from our study population with conventional statistical methods showed us that there is a strong association between shorter gestational age, lower birth weight, FIRS, lower Apgar score at 5 minutes, and development of ROP (any stage), but it is not the case with the histological chorioamnionitis, amniotic infection, surfactant use and mechanical ventilator support. However, with path analysis we confirmed that histological chorioamnionitis and FIRS, both have significant effect on gestational age but not significant effect on development of ROP. Mechanical ventilation wasn't statistically significant risk factor for development of ROP by our study and maybe we can explain this with a sample size.

REFERENCES

1. World Health Organization [Internet]. World Health Organization: Media Center- Preterm birth. [cited 2017 Nov]. Available from: <http://www.who.int/mediacentre/factsheets/fs363/en/>.
2. Tita A, Andrews W. Diagnosis and management of clinical chorioamnionitis. *Clinical Perinatology* 2010; 37(2): 339–354.
3. Eschenbach DA. Ureaplasma urealyticum and premature birth. *Clin Infect Dis*. 1993;17 (Suppl 1):S100–6
4. Viscardi RM. Prenatal and postnatal microbial colonization and respiratory outcome in preterm infants. In Bancalari E, Polin RA (eds). *The Newborn Lung: Neonatology Questions and Controversies*. Philadelphia: Elsevier Saunders,2012;
5. Wu HC, Shen CM, Wu YY, Yuh YS, Kua KE. Subclinical histologic chorioamnionitis and related clinical and laboratory parameters in preterm deliveries. *Pediatric Neonatology* 2009; 50(5):217–221)
6. Sherman MP, Lauriello NF. Chorioamnionitis Clinical Presentation. <https://emedicine.medscape.com/article/973237-clinical>. Jan 05, 2017
7. Yoon BH, Romero R, Moon JB, Shim SS, Kim M, Kim G, Jun JK. Clinical significance of intra-amniotic inflammation in patients with preterm labor and intact membranes. *Am J Obstet Gynecol*. 2001;185(5):1130–6
8. Holzman C, Lin X, Senagore P, Chung H. Histologic chorioamnionitis and preterm delivery. *Am J Epidemiol*. 2007;166(7):786–94
9. Mitchell T, MacDonald JW, Srinouanpranchanh S, Bammler TK, Merillat S, Boldenow E, Coleman M et al. Evidence of cardiac involvement in the fetal inflammatory

response syndrome: disruption of gene networks programming cardiac development in nonhuman primates. *Am J Obstet Gynecol.* 2018 Feb 21. pii: S0002-9378(18)30009-7

10. Sindjic Dessardo N, Mustac E, Dessardo S, Banac S, Peter B, Funderle A et al. Chorioamnionitis and Chronic Lung Disease of Prematurity: A path analysis of causality. *American Journal of Perinatology* 2011;29(2):133-40
11. Souvik M, Dagfinn A, Speer PC, Didrik Saugstad O. Chorioamnionitis as a risk factor for retinopathy of prematurity: a systematic review and meta-analysis. *Neonatology* 2014;105:189–199
12. Patz A, Hoek LE. Studies on the effect of high oxygen administration in retrolental fibroplasia. I. Nursery observations. *Am J Ophthalmol* 1952;35:1248–53
13. Kliegman RM, Stanton BF, Schor NF, St Geme III JW. *Nelson textbook of Pediatrics.* 20th Edition. Philadelphia, Elsevier 2016. 978-1-4557-7566-8
14. Slidsborg C, Jensen A, Lyng Forman J, Rasmussen S, Bangsgaard R, Callø Fledelius H et al. Neonatal risk factors for treatment demanding retinopathy of prematurity, a Danish national study. *Ophthalmology.* 2016 Apr;123(4):796-803
15. VanderVeen KD. Weighing in on new screening models for retinopathy of prematurity. *JAMA Ophthalmol.*2018;
16. Tran KD, Cernichiaro-Espinosa LA, Berrocal AM. Management of retinopathy of prematurity-use of Anti-VEGF therapy. *Asia Pac J Ophthalmol (Phila).* 2018 Jan-Feb;7(1):56-62
17. American Academy of Pediatrics, Section on Ophthalmology. American Academy of Ophthalmology. American Association for pediatric ophthalmology and strabismus screening examination of premature infants for retinopathy of prematurity. *Pediatrics.* 2006;117:572–6

18. International Committee for the Classification of retinopathy of Prematurity: The International Classification of Retinopathy of prematurity revisited. Arch Ophthalmol 2005;123:991-999
19. Langston C, Kaplan C, Macpherson T, Mancini E, Peevy K, Clark B, et al. Practice guideline for examination of the placenta. Arch Pathol Lab Med 1997; 121:449-76.
20. Redline RW. Inflammatory responses in the placenta and umbilical cord. Semin Fetal Neonatal Med 2006; 11: 296-301.)
21. Kent A, Dahlstrom JE. Chorioamnionitis/funisitis and the development of bronchopulmonary dysplasia. J Paediatr Child Health 2004; 40:356-359.
22. Pacora P, Chaiworapongsa T, Maymon E, et al. Funisitis and chorionic vasculitis: the histological counterpart of the fetal inflammatory response syndrome. J Matern Fetal Neonatal Med 2002; 11:18-25
23. Ahn J. Beyond single equation regression analysis: path analysis and multi-stage regression analysis. American Journal of Pharmaceutical Education 2002;66:37-42
24. Mehta R, Nanjudaswamy S, Shen-Schwarz S, Petrova A. Neonatal morbidity and placental pathology, Indian J Pediatr 2006; 73 (1):25-28
25. Dammann O, Leviton A, Bartels DB, Dammann CEL: Lung and brain damage in preterm newborns, are they related? How? Why? . Biol Neonate 2004;85:305-313
26. Dammann O, Leviton A: Maternal intrauterine infection, cytokines, and brain damage in the preterm newborn. Pediatr Res 1997; 42:1-8
27. Silveira RC, Fortes Filho JB, Procianny RS: Assessment of the contribution of cytokine plasma levels to detect retinopathy of prematurity in very low birth weight infants. Invest Ophthalmol Vis Sci 2011; 52:1297-1301

28. Woo JS, Park KH, Jung HJ, et al: Effects of maternal and placental inflammation on retinopathy of prematurity. *Graefes Arch Clin Exp Ophthalmol* 2012;250:915-923
29. Mitra S, Aune D, Speer CP, Saugstad OD: Chorioamnionitis as a risk factor for retinopathy of prematurity: a systematic review and meta-analysis. *Neonatology* 2014; 105:189-1999
30. Dammann O, Brinkhaus MJ, Bartes DB, et al: Immaturity, perinatal inflammation, and retinopathy of prematurity: a multi-hit hypothesis. *Early Hum* 2009; 85:325-329
31. Pietrzyk JJ, Kwinta P, Bik-Multanowski M, et al: New sight into the pathogenesis of retinopathy of prematurity: assessment of whole genome expression. *Pediatr Res* 2013; 78:476-483
32. Slidborg C, Jensn A, Forman JL, Rasmussen S et al: Neonatal risk factors for treatment-demanding retinopathy of prematurity, a Danish national study. *American Academy of Ophthalmology* 2016;
33. Askie LM, Brocklehurst P, Darlow BA, Finer N, Schmidt B, Tarnow-Mordi W. NeOProm: Neonatal oxygenation prospective meta-analysis collaboration study protocol. *BMC Pediatr.* 2011; 10.1186/1471-2431-11-6

Životopis

Nikolina Jurišić, rođena je 20. lipnja 1991. godine u Zagrebu. Osnovnu školu Ksavera Šandora Đalskog u Donjoj Zelini završava 2006. godine, te upisuje Gornjogradsku gimnaziju u Zarebu. Paralelno završava Osnovnu glazbenu školu Zlatko Grgošević u Zagrebu, smjer klavir. Medicinski fakultet u Rijeci upisuje 2011. godine. Za vrijeme studija član je organizacijskog odbora studentskog kongresa Prehrana i klinička dijetoterapija te aktivni i pasivni sudionik mnogih drugih studentskih međunarodnih kongresa: ISC Graz 2018., 1. SaMed, BRIK, Neuri, Kongres hitne medicine itd...). Također član je studentskog pjevačkog zbora Axis, s kojima sudjeluje na brojnim natjecanjima, te član studentske udruge Teddy Bear Hospital (TBH).