

New “L value” parameter simplifies and enhances hip ultrasound interpretation in the detection of developmental dysplasia of the hip

Rakovac, Ivan; Tudor, Anton; Šestan, Branko; Prpić, Tomislav; Gulan, Gordan; Mađarevic, Tomislav; Šantic, Veljko; Ružić, Lana

Source / Izvornik: **International Orthopaedics, 2011, 35, 1523 - 1528**

Journal article, Published version

Rad u časopisu, Objavljena verzija rada (izdavačev PDF)

<https://doi.org/10.1007/s00264-011-1256-0>

Permanent link / Trajna poveznica: <https://um.nsk.hr/um:nbn:hr:184:580050>

Rights / Prava: [Attribution-NonCommercial-NoDerivatives 4.0 International/Imenovanje-Nekomercijalno-Bez prerada 4.0 međunarodna](#)

Download date / Datum preuzimanja: **2024-09-12**



Repository / Repozitorij:

[Repository of the University of Rijeka, Faculty of Medicine - FMRI Repository](#)



Bone allograft provides bone healing in the medial opening high tibial osteotomy

Veljko Santic · Anton Tudor · Branko Sestan ·
Dalen Legovic · Luka Sirola · Ivan Rakovac

Received: 3 November 2009 / Accepted: 8 November 2009 / Published online: 8 December 2009
© Springer-Verlag 2009

Abstract Various materials are used to fill osteotomy defects created in the medial opening wedge high tibial osteotomy (MOWHTO). Our hypothesis was that a bone allograft would provide the osteotomy site bone healing within the expected time. We performed the MOWHTO using a cancellous bone allograft in 310 knees in 284 patients between 2000 and 2005. Internal fixation was achieved with a T-profile AO plate. Preoperative and postoperative radiographic measurements were taken and statistically processed. All patients were followed up for a period ranging from three to eight years, or 5.9 years on average. Implanted cancellous bone allografts ≤ 9 mm healed within 12 weeks in 90% of cases. With the properly selected patient and surgical technique, use of a cancellous bone allograft in MOWHTO represents a satisfactory choice in providing bone healing.

Introduction

High tibial osteotomy is an effective treatment for medial compartment osteoarthritis and varus malalignment of the knee causing pain and functional limitations. Both lateral closing wedge and medial opening wedge techniques have been described for these indications and have been shown to produce satisfactory clinical results [3, 4, 10, 22]. Complications such as fracture, inadequate correction, patella infera, compartment syndrome, arthrofibrosis, infection and delayed union or non-union may complicate both of these methods [13, 22]. However, because of the problems in the lateral

closing wedge osteotomy related to detachment of the extensor muscles, fibular osteotomy, peroneal nerve injuries, disruption of the proximal tibio-fibular joint and shortening of the limb, medial opening wedge high tibial osteotomy (MOWHTO) has become increasingly popular in recent years [1, 6, 13, 19]. Other advantages of the MOWHTO may include a more precise three-dimensional correction, avoidance of changes in the proximal morphology of the tibia, enhancement of bone stock and the possibility of correcting large deformities [16]. The disadvantages of the MOWHTO are fracture of the proximal tibia lateral aspect and the development of a potentially unstable construction and implant failure [14, 18]. These problems can be avoided with proper selection of the patient, surgical technique and the implant material or bone graft to be used to fill the osteotomy defect. Autogenous iliac crest bone graft has been the gold standard for filling the osteotomy defect, based on its well-known osteoconductive and osteoinductive potential [15]. The use of a bone allograft provides osteoconductive benefit only. However, owing to its availability, which requires no additional surgical access, potential complications associated with the harvesting procedure of autogenous bone graft are avoided [3, 7].

The purpose of this study was to report the results achieved with the use of a cancellous bone allograft in the MOWHTO without evaluating the clinical outcome of the procedure. Our hypothesis was such that by using this graft the tibial osteotomy healing would be achieved within the expected time of 12 weeks.

Patients and methods

We performed a MOWHTO using a cancellous bone allograft on 310 knees in 284 patients between 2000 and

V. Santic (✉) · A. Tudor · B. Sestan · D. Legovic · L. Sirola ·
I. Rakovac
Clinic for Orthopaedic Surgery Lovran,
Lovran, Croatia
e-mail: veljko.santic@ri.t-com.hr

2005. There were 184 women and 100 men involved, ranging in age from 26 to 67 years, with a mean of 55.6 years (SD 7.4 years). There were 26 patients who underwent bilateral MOWHTO. The criteria for inclusion in the study were radiological evidence of various grades of medial compartment osteoarthritis with medial joint pain and varus malalignment. The criteria for exclusion were osteoarthritis of the lateral compartment, associated anterior knee pain, rheumatoid arthritis, insulin dependent diabetes mellitus, systemic steroid use, flexion contracture $>10^\circ$ and history of previous open operation of the knee. Our patients were followed-up for three to eight years, or 5.9 years on average. The osteotomy correction angle size ranged from 5° to 18° with a mean of 8.9° (SD 2.3°). The osteotomy opening ranged from 4 to 16 mm, with a mean of 8.6 mm (SD 2.0 mm). All operations were performed by a team of experienced surgeons and under the same conditions, using the same surgical technique. Knee arthroscopy was performed in 62 patients, and nine of them were microfractures.

For their postoperational thromboprophylactic protection, they were administered low-molecular-weight heparin.

Clinical and radiographic assessment

Clinical examination for identification of painful medial osteoarthritis, range of motion and stability of the knee, suspected intra-articular injuries, postoperative scar healing and local swelling and pain was done.

Preoperatively, malalignment was assessed using the single leg standing long-leg radiographs. The osteotomy was planned to make the weight bearing line fall in a selected position [5, 8]. Postoperative radiographs were taken after the operation, then subsequently six, 12 and 16 weeks after the surgery and then as required, until the bone healing was evident. Delayed union was defined as the lack of the bridging callus and the presence of radiolucent areas within the opening wedge defect.

Operative technique

The standard operation technique was performed using a tourniquet and spinal anaesthesia [10]. Care was taken not to break the lateral cortex during the tibial osteotomy in order to preserve some degree of stability between bone fragments [15]. The bone allografts used were parts of femoral heads stored at -80°C . They were unfrozen prior to application in a suitable physiological medium for approximately 30 minutes at room temperature. Internal fixation was done with a T-profile AO plate (Fig. 1). The internal fixation plate was removed 12 to 18 months after the operation.

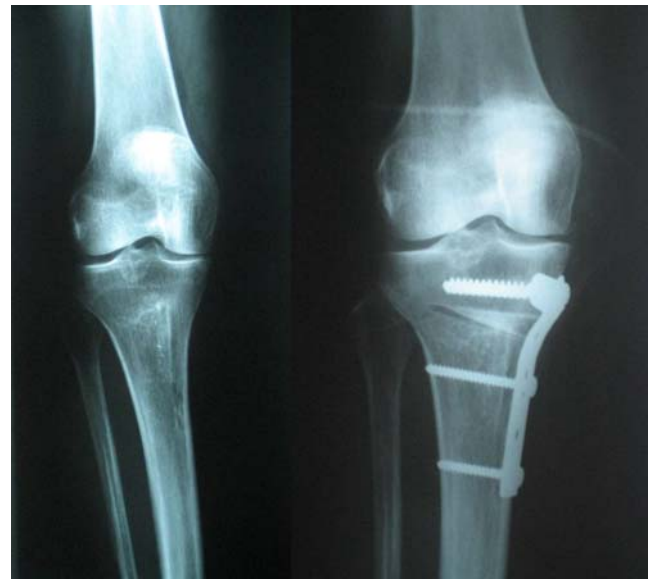

Fig. 1 Preoperative and immediate postoperative anteroposterior radiograph after a medial opening wedge high tibial osteotomy using a cancellous bone allograft and fixation with AO plate and screws

Postoperative rehabilitation

The patients underwent the appropriate rehabilitative program in order to preserve the force of the knee muscles and to prevent the development of patella infera or arthrofibrosis [21]. No postoperative knee immobilisers were applied. Weight bearing was increased to 50% after six weeks. Thereafter, weight was successively added each week. Full weight bearing was permitted in accordance with radiological findings from the twelfth week onwards.

Statistical analysis

Statistical analysis of the data obtained was performed using Statistica for Windows, release 7.1. (Stasoft, Inc., Tulsa, OK, USA). The correlation analyses were expressed by the Pearson correlation coefficient and Fisher Z test. The analysis of the number of cases in relation to their respective bone allograft sizes (mm) and healing times (weeks) was performed using Pearson's χ^2 test or *t*-test for proportion. All statistical values were considered significant at the $P < 0.05$ level.

Results

Out of 310 cases followed up, six were excluded from the statistical processing due to complications which directly affected normal healing conditions of the osteotomy defect. We had three cases of tibial lateral cortex fracture, one

infraction of the lateral tibial condyle, one case of early bone graft absorption and one case of deep infection. There were no cases of neurovascular injury or arthrofibrosis in our series.

In the remaining 304 cases, healing occurred within 24 weeks. The correlation coefficient determined between the size of the cancellous bone allograft used and the time of healing was positive and statistically significant ($r=0.704$, $P<0.001$) (Fig. 2). Likewise, the correlation coefficient determined between the size of the correction angle and the time of healing was positive and statistically significant ($r=0.515$, $P<0.001$) (Fig. 3). This means that a larger bone allograft as well as a wider correction angle will take statistically longer to heal completely.

Comparing the significance of these two correlation coefficients, a more significant correlation was found ($P=0.002$) between the size of the cancellous bone allograft used and the time of the osteotomy site healing in relation to the correlation between the size of the correction angle and healing time required.

The resulting relationship between particular sizes of cancellous bone allografts, their number and the osteotomy site healing time falling within 24 weeks are given in Table 1. In bone allografts up to 9 mm in size, the healing time falling within 12 weeks was statistically significant (all $P<0.001$). A bone allograft of 10 mm in size took up to 12–16 weeks for healing ($P=0.519$). Healing of bone allografts of more than 10 mm in size was statistically significant exceeding 12 weeks (all $P<0.001$).

Discussion

Many studies have shown that the MOWHTO for uni-compartmental osteoarthritis and varus malalignment of the knee produces satisfactory results [3, 4, 10, 13, 22]. The efficiency of the method is dependent on the preoperative planning, surgical technique and the implant material or bone graft used to fill the osteotomy defect.

Our hypothesis was that a cancellous bone allograft would be a satisfactory graft choice in the MOWHTO and would provide bone healing within 12 weeks.

So far, there have been various materials used to fill the MOWHTO osteotomy defects. Autologous iliac crest bone graft, owing to its osteoconductive and osteoinductive potential, provides bone healing with low incidence of delayed union and nonunion in the MOWHTO [15]. Its advantages, as compared with the use of bone substitute materials like hydroxyapatite and acrylic bone cement, have been well described in previous studies [2, 9, 11].

By using the cancellous bone allograft in the MOWHTO, we intended to take advantage of its osteoconductive potential. The quality and safety of the bone allograft must be guaranteed by the operating principles of the bone bank. The Clinic for Orthopaedic Surgery Lovran bone bank operates in compliance with applicable laws of the Republic of Croatia, which have been brought in compliance with the legislation of the European Union [17].

The results of our study using a cancellous bone allograft in MOWHTO have shown that all of the 304 cases treated

Fig. 2 Correlation between cancellous bone allograft size and healing time (* indicates significant correlation)

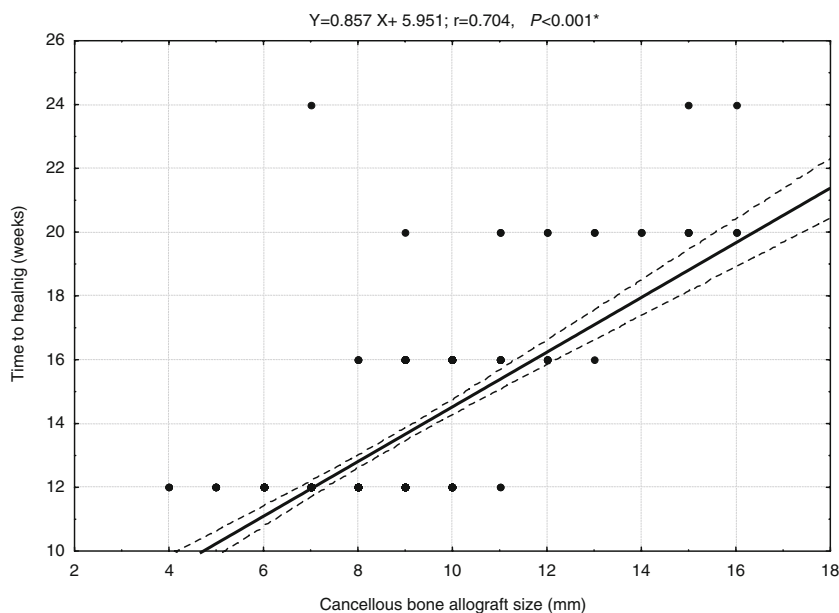
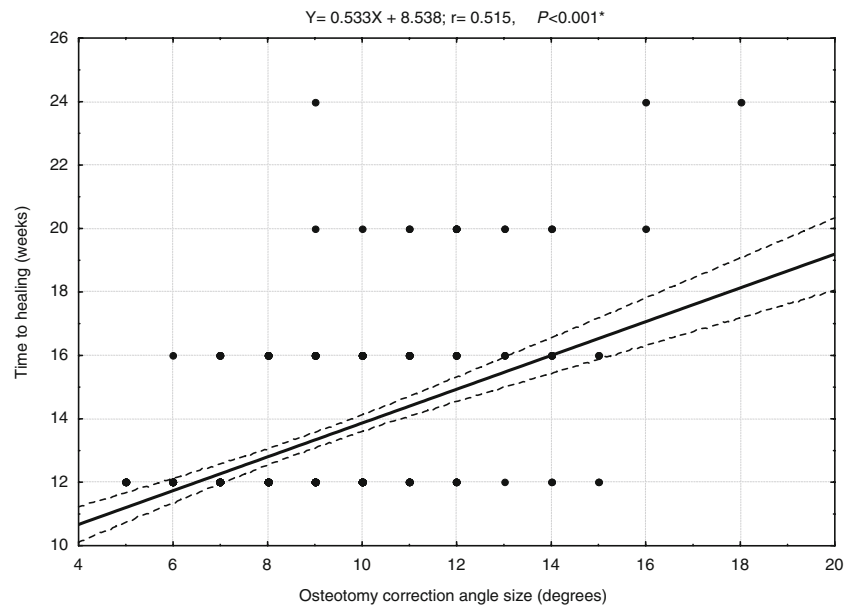


Fig. 3 Correlation between osteotomy correction angle size and healing time (* indicates significant correlation)



have resulted in the osteotomy healing within 24 weeks. As the correction angle and the basis of the cancellous wedge allograft became wider, the healing time became longer. These results were actually expected, bearing in mind the well-known facts in the domain of bone healing biology. Similar results have been obtained by Yacobucci et al. [23] from a series of 50 cases, although such a small data sample group did not allow for proper statistical comparison between each osteotomy size.

Significant correlation between the size of a cancellous wedge allograft and the time required for healing, as compared with the correlation between the size of the correction angle and the time of healing, may be explained in geometrical terms. It is a well-known fact that the width of an angle increases proportionally with the distance from its point. Thus, the size of a cancellous wedge allograft being tamped into the osteotomy site at the level of the tibial medial edge will vary in size at the same angle of correction yet different width of the tibial bone. Allograft size therefore appears to be a more precise prognostic factor in the assessment of the osteotomy site expected time of healing.

The results obtained through the follow-up of correlations between different sizes of cancellous bone allografts and healing times have demonstrated that healing of allografts reaching up to 9 mm was achieved in 200 (90%) out of 221 cases within 12 weeks. A 10-mm bone allograft proved to be the marginal size. Its use in 51 cases resulted in healing in 24 (47%) cases within 12 weeks and in 27 (53%) cases within 16 weeks. In 32 cases with bone allograft ranging from 11 to 16 mm, healing took from 16 to 24 weeks, apart from two cases. Healing time exceeding that which was expected in the use of bone allograft of

10 mm and more was probably attributable to the absence of osteoinductive activity, which is considered to be its major disadvantage. The presented results may be compared with previously known results about the use of autologous bone graft in MOWHTO [12, 20]. Thus, the prospective study performed by Noyes et al. [15] using autologous iliac crest bone graft in 55 patients subject to MOWHTO resulted in 52 (95%) defect healings within

Table 1 Number of cases in relation to cancellous bone allograft sizes (mm) and healing time (weeks)

Cancellous bone allograft size (mm)	Healing time (weeks)				Total number of cases	Statistical P value
	12	16	20	24		
4	3				3	
5	7				7	
6	25				25	
7	57		1		58	<0.001
8	60	3			63	<0.001
9	48	16	1		65	<0.001
10	24	27			51	0.519
11	2	8	2		12	<0.001
12		5	2		7	<0.001
13		1	2		3	
14			2		2	
15			4	1	5	
16			2	1	3	
Total	226	60	15	3	304	

Values given as number of cases

12 weeks. In three (5%) cases which took more than 12 weeks to heal, the size of the opening wedge osteotomy ranged between 11 and 16 mm.

Conclusion

The use of a cancellous bone allograft of up to 9 mm in size in the MOWHTO generally results in the osteotomy site healing within 12 weeks. These results support this approach as compared with the use of autologous bone graft, in view of the shorter surgical time and avoidance of an additional surgical incision.

In cases requiring the use of a cancellous bone allograft of 10 mm or more in size, the expected healing takes more than 12 weeks. In such cases, we would favour autologous bone graft because of its additional osteoinductive potential. This viewpoint certainly requires further comparative clinical study using autologous and allogeneous bone grafts in MOWHTO requiring larger degrees of correction.

References

- Amendola A, Fowler PJ, Litchfield R, Kirkley S, Clatworthy M (2004) Opening wedge high tibial osteotomy using a novel technique: early results and complications. *J Knee Surg* 17:164–169
- Aryee S, Imhoff AB, Rose T, Tischer T (2008) Do we need synthetic osteotomy augmentation materials for opening-wedge high tibial osteotomy? *Biomaterials* 29:3497–3502
- Brouwer RW, Bierma-Zeinstra SMA, van Raaij TM, Verhaar JAN (2006) Osteotomy for medial compartment arthritis of the knee using a closing wedge or an opening wedge controlled by a Puddu plate. *J Bone Joint Surg Br* 88:1454–1459
- Coventry MB, Ilstrup DM, Wallrichs SL (1993) Proximal tibial osteotomy: a critical long-term study of eighty-seven cases. *J Bone Joint Surg Am* 75:196–201
- Dugdale TW, Noyes FR, Styer D (1992) Preoperative planning for high tibial osteotomy: the effect of lateral tibiofemoral separation and tibiofemoral length. *Clin Orthop Relat Res* 274:248–264
- Gaasbeek RDA, Nicolaas L, Rijnberg WJ, Van Loon CJM, Van Kampen A (2009) Correction accuracy and collateral laxity in open versus closed wedge high tibial osteotomy. A one year randomized controlled study. *Int Orthop*. doi:10.1007/s00264-009-0861-7
- Heary RF, Schlenk RP, Sacchieri TA, Barone D, Brotea C (2002) Persistent iliac crest donor site pain: independent outcome assessment. *Neurosurgery* 50:510–516
- Hernigou P, Ovidia H, Goutallier D (1992) Mathematical modelling of open wedge tibial osteotomy and correction tables. *Rev Chir Orthop Reparatrice Appar Mot* 78:258–263
- Hernigou P, Ma W (2001) Open wedge tibial osteotomy with acrylic bone cement as bone substitute. *Knee* 8:103–110
- Hernigou P, Medevielle D, Debeyre J, Goutallier D (1987) Proximal tibial osteotomy for osteoarthritis with varus deformity. A ten to thirteen-year follow-up study. *J Bone Joint Surg Am* 69:332–354
- Koshino T, Murase T, Saito T (2003) Medial opening-wedge high tibial osteotomy with use of porous hydroxyapatite to treat medial compartment osteoarthritis of the knee. *J Bone Joint Surg Am* 85:78–85
- Marti RK, Verhagen RA, Kerkhoffs GM, Moojen TM (2001) Proximal tibial varus osteotomy: indications, technique, and five to twenty-one-year results. *J Bone Joint Surg Am* 83:164–170
- Naudie D, Bourne RB, Rorabeck CH, Bourne TJ (1999) Survivorship of the high tibial valgus osteotomy: a 10 to 22 year follow-up study. *Clin Orthop Relat Res* 367:18–27
- Nelissen EM, Van Langelaan EJ, Nelissen RGH (2009) Stability of medial opening wedge high tibial osteotomy: a failure analysis. *Int Orthop*. doi:10.1007/s00264-009-0723-3
- Noyes FR, Mayfield W, Barber-Westin SD, Albright JC, Heckeman TP (2006) Opening wedge high tibial osteotomy. An operative technique and rehabilitation program to decrease complications and promote early union and function. *Am J Sports Med* 34:1262–1273
- Rodner CM, Adams DJ, Diaz-Doran V, Tate JP, Santangelo SA, Mazzocca AD, Arciero RA (2006) Medial opening wedge tibial osteotomy and the sagittal plane. *Am J Sports Med* 34:1431–1441
- Santic V, Legovic D (2007) The clinic for orthopaedic surgery Lovran bone bank. *Acta Med Croatica* 61:487–489
- Spahn G, Wittig R (2002) Primary stability of various implants in tibial opening wedge osteotomy: a biomechanical study. *J Orthop Sci* 7:683–687
- Tunggal JAW, Higgins GA, Waddell JP (2009) Complications of closing wedge high tibial osteotomy. *Int Orthop*. doi:10.1007/s00264-009-0819-9
- Warden SJ, Morris HG, Crossley KM, Brukner PD, Bennell KL (2005) Delayed and non-union following opening wedge high tibial osteotomy: surgeons' results from 182 completed cases. *Knee Surg Sports Traumatol Arthrosc* 13:34–37
- Westrich GH, Peters LE, Haas SB, Buly RL, Windsor RE (1998) Patella height after high tibial osteotomy with internal fixation and early motion. *Clin Orthop Relat Res* 354:169–174
- Wright JM, Crockett HC, Slawski DP, Madsen MW, Windsor RE (2005) High tibial osteotomy. *J Am Acad Orthop Surg* 13:279–289
- Yacobucci GN, Cocking MR (2008) Union of medial opening wedge high tibial osteotomy using a corticocancellous proximal tibial wedge allograft. *Am J Sports Med* 36:713–719