

Two Different Manifestations of Locked-In Syndrome

Golubović, Vesna; Muhvić, Damir; Golubović, Snježana; Juretić, Mirna; Sotošek Tokmadžić, Vlatka

Source / Izvornik: **Collegium antropologicum, 2013, 37, 313 - 316**

Journal article, Published version

Rad u časopisu, Objavljena verzija rada (izdavačev PDF)

Permanent link / Trajna poveznica: <https://um.nsk.hr/um:nbn:hr:184:530795>

Rights / Prava: [In copyright](#)/[Zaštićeno autorskim pravom.](#)

Download date / Datum preuzimanja: **2024-09-08**



Repository / Repozitorij:

[Repository of the University of Rijeka, Faculty of Medicine - FMRI Repository](#)



Two Different Manifestations of Locked-In Syndrome

Vesna Golubović¹, Damir Muhvić², Snježana Golubović¹, Mirna Juretić³ and Vlatka Sotošek Tokmadžić¹

¹ University of Rijeka, Rijeka University Hospital Center, Clinic of Anesthesiology and Intensive Care, Rijeka, Croatia

² University of Rijeka, School of Medicine, Department of Physiology and Immunology, Rijeka, Croatia

³ University of Rijeka, Rijeka University Hospital Center, Clinic of Maxillofacial Surgery, Rijeka, Croatia

ABSTRACT

Locked-in syndrome (LIS) is an entity that usually occur a consequence of the lesion of ventral part of pons. Etiology of locked-in syndrome can be vascular and nonvascular origin. Locked-in syndrome usually occurs as a consequence of thrombosis of intermedial segment of basilar artery that induces bilateral infarction of the ventrobasal part of the pons. Additionally, LIS can be caused by trauma which often leads to posttraumatic thrombosis of basilar artery. The incidence of locked-in syndrome is still unknown. The basic clinical features of locked-in syndrome are: quadriplegia (a consequence of disruption of corticospinal pathways located in ventral part of pons), different stages of paralysis of mimic musculature, paralysis of pharynx, tongue and palate with mutism and anarthria. The patient can not move, but is conscious and can communicate only by eye movements. Two patients with locked-in syndrome were present in this article. In the first case, the patient had classic locked-in syndrome that was first described by Plum and Posner¹. Other patient had incomplete form of locked-in syndrome which was first described by Bauer². In these two patients locked-in syndrome occurred as a consequence of trauma. In the first patient locked-in syndrome was caused by direct contusion of ventral part of pons while in other patient locked-in syndrome was a consequence of posttraumatic thrombosis of vertebrobasilar artery. The introduction of anticoagulant therapy, besides the other measures of intensive therapy, has shown complete justification in the second patient. The gradual partial recovery of neurologic deficit has developed in the second patient without any additional complications.

Key words: *locked-in syndrome, posttraumatic locked-in syndrome, basilar thrombosis, anticoagulant therapy, anti-oedema therapy*

Introduction

Locked-in syndrome is a nosologic entity which sometimes appears after an injury or infarction of the brainstem located predominantly in the area of ventrobasal part of pons. The most often feature of LIS is thrombosis of intermedial segment of basilar artery that leads to bilateral infarct of ventrobasal part of pons. The term »locked-in syndrome« describes a clinical picture of selective motor de-efferentiation characterized by tetraplegia, sparing of vertical eye movement and blinking, mutism and paralysis of the lower cranial nerves without affecting consciousness³. In most cases LIS is predominantly a vascular disease of ventral pons or medulla oblongata⁴, but sometimes, although rarely, LIS occurs after trau-

matic lesion of the ventrobasal part of the pons with or without occlusion of bilateral vertebral and basilar arteries⁵. In this article two cases of LIS were described. In the first patient, LIS occurred as a consequence of ventrobasal part of pons injury without bilateral occlusion of the vertebral and basilar arteries, while in other patient locked-in syndrome was a consequence of posttraumatic occlusion of one vertebral artery. The diagnosis of locked-in syndrome in the first patient was not recognized until the fifteenth day after the injury, because the symptoms of LIS were masked by multiple body injuries. In the second patient, locked-in syndrome was present at the admittance.

Case Reports

The first case

A 23-year-old man had a car accident and multiple body injuries occurred. At the hospital admittance the Glasgow Coma Scale (GCS) of the patient was 3. He suffered for hemorrhagic shock and was not able to breathe spontaneously. The presence of free liquid intra-abdominally was confirmed by an urgent sonogram of the abdomen. The contusion of the right lung with haematothorax was shown by chest-ray. After resuscitation, urgent laparotomy and right drainage of thorax were performed and the patient was admitted to Intensive Care Unit (ICU). He was mechanically ventilated and received anti-oedematous and antibiotic therapy and high doses of Piracetam. After a few days the brain computerized tomography (CT) showed contusion of the ventrobasal part of pons. The normal findings of cervical vertebrae were found on X-rays examination. On day 15 after injury control neurologic examination showed that patient was conscious and able to communicate only through eye blinking especially with (de) sursumvergence. He reacted to stimulation with a painful grimace. The patient had flaccid tetraplegia with bilateral Babinski sign. The LIS diagnosis was established. Electroencephalography (EEG) showed lower amplitudes of theta waves with occasional gathering of monomorphic slow delta waves of 4 Hz. Normal blood flow through the vertebral and basilar arteries was shown by transcranial doppler examination (TD). Normal vascular anatomy was shown by catheter angiography of the brain. On day 26 after injury the patient was able to open and close his eyes when instructed. Repeated (control) CT of the brain showed a post-contusional focus in the ventrobasal part of the pons. Repeated (control) EEG showed diffuse theta activity of low voltage. On day 64 after injury the patient started to turn his head to the left or to the right on verbal command. This was a moderate improvement of neurological status.

On day 96 after injury control EEG showed diffuse theta activity outside the occipital area.

During intensive care treatment, the patient was permanently mechanically ventilated. In spite of the aimed antibiotic therapy, the patient had permanently high body temperature. On day 105 after injury, bilateral pneumonia occurred. Finally, bacteriemia and acute respiratory distress syndrome (ARDS) occurred and cause lethal outcome. Pathohistological finding of postmortal material revealed pons damage (Figure 1).

The second case

A previously healthy 33-year-old man sustained an injury of the head and a whiplash injury to the neck provoked by acceleration-deceleration mechanism during a rear-end car accident. Radiographic examination of the cervical spine showed no bone injury. At the hospital admittance the patient was conscious but able to communicate only through eye-blinking especially with (de) sursumvergence. Computerized tomography examination of the brain showed the infarction of the ventrobasal part of

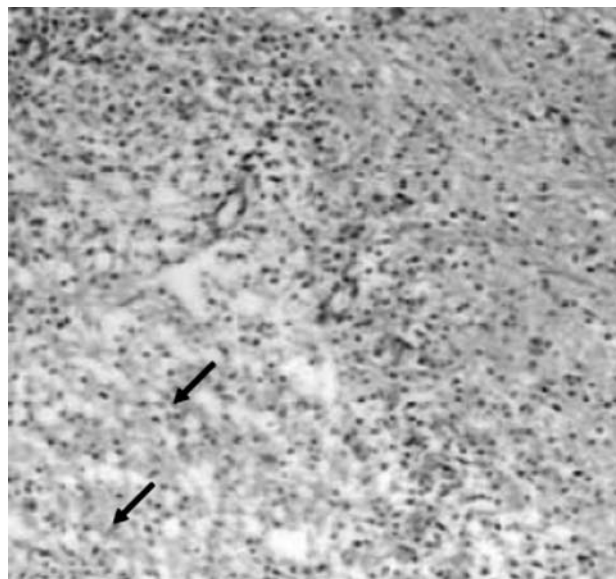


Fig. 1. The arrows indicate the area of brain necrosis (magnification 100 x).

the pons. Transcranial doppler examination of vertebral-basilar vessels did not show an echo of vertebral and basilar artery.

Electroencephalography examination registered normal rhythm with low amplitudes of alpha frequency mixed with low rhythm of theta frequency above the left hemisphere. Vertebral angiography showed occlusion of the right vertebral artery while the left vertebral artery was intact. Upon admittance to hospital anti-oedematose therapy started with a continuous anticoagulant therapy (Heparin) which was lately replaced by per oral anticoagulant drugs. The patient stayed in our hospital for three months and then was transferred to another hospital at the request of his family. At discharge the patient was conscious with restricted horizontal eye movement and a weak abduction of both arms.

Discussion

The reported cases are rarities in several aspects. From the etiologic point of view LIS is the primary vascular disease of the pons or medulla oblongata while it seldom occurs due to head and neck trauma³. Considering the neuropathologic aspect, it is interesting that LIS in the first case was not followed by thrombosis of the basilar and vertebral artery which usually occurs in LIS². On the contrary, LIS was a consequence of the pons lesion. In this case, the moderate improvement in neurological status appeared on day 64 after the injury when the patient started to rotate his head. This might suggest a tendency for better prognosis in patients without occlusion of the basilar artery. This finding is opposite to the absence of neurological improvements in LIS patients with acute basilar artery occlusion⁶. The lesion of the pons was proved by an urgent and repeated CT while both, the first and the second EEG showed pathological

findings. The patient's recovery was complicated by multiple lesions of abdominal organs (liver, pancreas and intestine) which were confirmed by autopsy. In spite of a rather unusual improvement in the neurological status the patient finally developed bacteremia with acute respiratory distress syndrome (ARDS), the illness of high mortality⁷. Therefore, posttraumatic LIS that developed after pontine contusion was not followed by posttraumatic occlusion of the vertebral and basilar arteries and therefore represents a rare neurologic entity. Moreover, this report shows that hyperflexion and hyperextension injury to the cervical spine that can occur during the rear-end car accident can be the pathophysiologic mechanism that can lead to the development of posttraumatic LIS which is not followed by bilateral posttraumatic occlusion of the vertebral and basilar arteries. In the second case, LIS was present at the admittance to the hospital. These findings are different from the literature data that have reported an asymptomatic period of 6–48 hours after injury⁵. These cases also suggest that asymptomatic period can be significantly shortened (less than six hours). The varieties of asymptomatic periods could be a consequence of different mechanisms of trauma. According to Bauer, posttraumatic LIS can be divided into two groups, first group with the primary injury to the brainstem by the forces acting at the moment of accident and the second group with delayed ischemia secondary to vascular damage that occurred at the moment of the accident². Patients of the second group usually sustained minor head injuries without losing consciousness at any moment, but progressive deterioration which leads to

LIS occurs within hours after the accident. According to mentioned facts, our first case would fit in the first group while the second case would fit in the second group of posttraumatic LIS. In the second case the hyperextension injury to the cervical spine was provoked by a whiplash injury to the neck induced by strong acceleration-deceleration forces present during the rear-end car accident. X-ray examination of cervical spine showed no bone injuries that occurred during the traffic accident indicating that the vertebral artery injury was provoked by hyperextension of the neck which can happen with or without rotation or lateral flexion that represents the permanent feature of the non-penetrating mechanisms responsible for the appearance of LIS. Similar mechanism of LIS was described by our research group in fourteen-year old gymnast who had cervical spine injury and consequently occlusion of vertebral and basilar artery as a result of hyperextension of the cervical spine during the floor exercise⁸.

Additionally, anticoagulant (Heparin and per oral anticoagulants) and anti-oedema therapy (corticosteroids and manitol) that significantly improved the neurological status and protected the 14-year old gymnast from the development of further neurological complications, in the second case these therapy provoked only minor neurological improvements⁸.

It can be concluded that locked-in syndrome can have different manifestations. The asymptomatic period can vary from hour up to 72 hours after injury. The final outcome depends of the injury intensity.

REFERENCES

1. PLUM F, POSNER JB, Davis 1st ed (Davis Company, Philadelphia, 1969). — 2. BAUER G, GERSTENBRAND F, RUMPL E, *J Neurol*, 221 (1979) 77. — 3. BRUNO MA, PELLAS F, SCHNAKERS C, VAN EECKHOUT P, BERNHEIM J, PANTKE KH, DAMAS F, FAYMONVILLE ME, MOONEN G, GOLDMAN S, LAUREYS S, *Rev Neurol*, 164 (2008) 322. DOI: 10.1016/j.neurol.2007.12.010. — 4. BIVINS D, BILLER J, LASTER DW, MCLEAN WT, *Surg Neurol*, 16 (1981) 230. — 5. SUGRUE PA, HAGE ZA, SURDELL DL, FOROOHAR M, LIU J, BENDOK BR, *Neurocrit*

Care, 11 (2009) 255. DOI: 10.1007/s12028-008-9159-7. — 6. WIJDRICKS EFM, SCOTT JP, *Stroke* 27 (1996) 1301. — 7. PHUA J, BADIA JR, ADHIKARI NK, FRIEDRICH JO, FOWLER RA, SINGH JM, SCALES DC, STATHER DR, LI A, JONES A, GATTAS DJ, HALLETT D, TOMLINSON G, STEWART TE, FERGUSON ND, *Am J Respir Crit Care Med*, 179 (2009) 220. DOI: 10.1164/rccm.200805-722OC. — 8. GOLUBOVIĆ V, MUHVIĆ D, GOLUBOVIĆ S, *Coll Antropol*, 28 (2004) 923.

V. Golubović

University of Rijeka, Rijeka University Hospital Center, Clinic of Anesthesiology and Intensive Care, Krešimirova 42, 51000 Rijeka, Croatia
e-mail: vesna.golubovic@medri.hr

PRIKAZ DVA BOLESNIKA S LOCKED-IN SINDROMOM – DVIJE RAZLIČITE MANIFESTACIJE LOCKED-IN SINDROMA

SAŽETAK

Locked-in sindrom (LIS) je entitet koji obično nastaje kao posljedica lezije u ventralnom dijelu ponsa. Etiologija LIS može biti vaskularna ili ne vaskularna. Locked-in sindrom se obično javlja kao posljedica tromboze interdijalnog dijela bazilarne arterije koja ima za posljedicu infarkt ventrobazalnog dijela ponsa. Dodatno, LIS može nastati kao posljedica

ozljede koja obično dovodi do posttraumatske tromboze bazilarne arterije. Učestalost LIS još uvijek nije u potpunosti poznata. Osnovna klinička obilježja LIS su: kvadriplegija (posljedica prekida kortikospinalnog puta koji se nalazi u ventralnom dijelu ponsa), različiti stadiji paralize mimične muskulature, paraliza ždrijela, jezika i nepca s mutismom i anartrijom. Bolesnik se ne može micati, svjestan je, može komunicirati samo pokretima očiju. U ovome članku smo prikazali dva bolesnika s LIS. U prvog prikazanog bolesnika, javila se klasična slika LIS koju su prvi puta u svojim radovima opisali Plum i Posner¹. Drugi bolesnik je imao netipični oblik LIS koji je prvi puta opisao Bauer². U oba bolesnika LIS se je javio kao posljedica ozljede. U prvog bolesnika LIS je nastao kao posljedica izravnog udara u ventralni dio ponsa dok je u drugoga bolesnika LIS bio posljedica posttraumatske tromboze verterbobazilarne arterije. Uvođenje antikoagulacijske terapije, kao sastavnog dijela intenzivnog liječenja, pokazalo se opravdanim u drugog bolesnika. U drugog bolesnika došlo je do postpunog neurološkog oporavka bez razvoja dodatnih komplikacija.