

Assessment of Perforin Expression in Peripheral Blood Lymphocytes in Psoriatic Patients During Exacerbation of Disease

Prpić, Larisa; Štrbo, Nataša; Sotošek, Vlatka; Gruber, Franjo; Podack, Eckhard R.; Rukavina, Daniel

Source / Izvornik: **Acta Dermato-Venereologica Supplementum, 2000, 211, 14 - 16**

Journal article, Published version

Rad u časopisu, Objavljena verzija rada (izdavačev PDF)

<https://doi.org/10.1080/00015550050500059>

Permanent link / Trajna poveznica: <https://um.nsk.hr/um:nbn:hr:184:001688>

Rights / Prava: [Attribution-NonCommercial 4.0 International](#)/[Imenovanje-Nekomercijalno 4.0 međunarodna](#)

Download date / Datum preuzimanja: **2024-11-22**



Repository / Repozitorij:

[Repository of the University of Rijeka, Faculty of Medicine - FMRI Repository](#)



Assessment of Perforin Expression in Peripheral Blood Lymphocytes in Psoriatic Patients During Exacerbation of Disease

LARISA PRPIĆ¹, NATAŠA ŠTRBO², VLATKA SOTOŠEK², FRANJO GRUBER¹, ECKHARD R. PODACK³ and DANIEL RUKAVINA²

Departments of, ¹Dermatovenerology, Medical Faculty, ²Physiology and Immunology, Medical Faculty, University of Rijeka, Rijeka, Croatia and ³Microbiology and Immunology, University of Miami, Miami, Florida, USA

There are very few data concerning the role played by cell-mediated cytotoxicity, particularly at the molecular level, in the course of psoriasis. Both cytotoxic T lymphocytes (CTL) and natural killer cells contain in their granules the cytolytic protein perforin, a mediator in cell-mediated cytotoxicity reactions. The aim of this study was to analyze perforin expression in various sets and subsets of perforin-positive peripheral blood lymphocytes in 17 patients with chronic psoriasis vulgaris in the exacerbation phase. The results were compared with those of an age- and sex-matched healthy control group ($n=21$). Perforin (intracellular antigen) and cell surface antigens were detected using the simultaneous double-staining method. We found a significant increase in perforin (P) expression in the patient group for CTL (CD3+ P+ cells), which are located mostly in the CD8+ population of T lymphocytes (CD8+ P+). **Key words:** psoriasis; perforin; cytotoxic T lymphocytes; NK cells.

Acta Derm Venereol 2000; Suppl 211: 14–16.

Daniel Rukavina, Department of Physiology and Immunology, Medical Faculty, University of Rijeka, B. Branchetta 20/1, HR-51000, Rijeka, Croatia.
E-mail: Daniel.Rukavina@mamed.medri.hr

INTRODUCTION

Psoriasis is an inflammatory papulosquamous skin disease which is immunologically characterized by increased keratinocyte proliferation, infiltration of inflammatory cells, especially T lymphocytes, and production of inflammatory cytokines, mostly of Th1 phenotype (1).

Immunological changes characteristic of psoriasis occur at the systemic and local levels, in the region of the psoriatic lesion in the skin (2). It is generally considered that T lymphocytes play an important role in the pathogenesis of psoriasis. Skin lesions in psoriatic patients are strongly infiltrated with T lymphocytes and, depending on the stage of disease, CD4+ or CD8+ cells predominate. Variations in the levels of these cells are observed in the peripheral blood (1, 3, 4).

There are very few data concerning the role of lymphocyte (cell)-mediated cytotoxicity (CMC), particularly at the molecular level. Both cytotoxic T lymphocytes (CTL) and natural killer (NK) cells are mediators in CMC reactions. These cells are endowed with a potent cytolytic armamentarium located in the cytoplasmic granules, containing the cytolytic molecule perforin (pore-forming protein) and associated serine esterases (granzymes). In unstimulated peripheral blood lymphocytes perforin is constitutively expressed in NK and gamma/delta TCR+ cells (high level

of expression) and in the subpopulation of CD8+ cells expressing CD11b antigen (moderate expression). However, perforin can be induced in the CD8+ CD11b- subpopulation and in some CD4+ T cells (5, 6). Perforin is a mediator in CMC reactions and the main function of granzymes is to mediate target DNA degradation upon gaining entry into the target cell through the presence of perforin pores (7). According to a search of the literature, the role of perforin-mediated cytotoxicity in psoriasis has not yet been investigated, either in the peripheral blood or in lesions.

The aim of this study was to analyze perforin expression in various sets and subsets of perforin-positive peripheral blood lymphocytes, which are known to have different functions.

MATERIALS AND METHODS

Patients

This study was approved by the Ethics Committee of the Medical Faculty, University of Rijeka. For flow cytometric analyses 2 groups of patients were recruited: (i) 17 patients (8 males, 9 females; 23–60 years) who were in the early exacerbation phase of chronic psoriasis; and (ii) 21 healthy persons (laboratory personnel and volunteer blood donors; 9 males, 12 females; 20–57 years) who served as controls.

Lymphocyte preparation

Heparinized venous peripheral blood (10 ml) was layered onto Ficoll/Hypaque density gradient and centrifuged for 20 min at 800 g. Cells accumulating at the interface were washed twice in RPMI 1640 and resuspended at a final concentration of 1×10^6 peripheral blood lymphocytes per sample in fluorescent-activated cell sorting (FACS) buffer. Cell viability was checked using trypan blue.

Monoclonal antibodies

A murine antihuman perforin monoclonal antibody (MoAb) δ G9 (IgG2b) was purified from Balb/c ascites (produced by E. R. P.). The following MoAbs were obtained conjugated to phycoerythrin from Becton Dickinson (Mountain View, CA): Leu-4 (anti-CD3), Leu-3a (anti-CD4), Leu-2a (anti-CD8), Leu-11b (anti-CD16) and Leu-19 (anti-CD56).

Simultaneous detection of cell surface and intracellular antigens by flow cytometry

Our procedure for the simultaneous detection of intracellular (perforin) and cell surface membrane antigens has been described elsewhere (8). Briefly, peripheral blood lymphocytes were cultured overnight at 37°C in complete RPMI. Non-adherent cells were aliquoted (10^6 per aliquot), washed in FACS buffer and then fixed in 100 μ l PBS containing 4% paraformaldehyde, pH 7.4, for 10 min at room temperature. After 2 washes in FACS buffer, the cells were permeabilized with saponin buffer (0.1% saponin) (Sigma, Poole, UK) for 20 min at room temperature. Anti-perforin MoAb in saponin

buffer (3 µg/100 ml) was added to the cell suspension at a final concentration of 8–10 µg per sample and incubated for 30 min at room temperature. A second antibody (fluorescein-conjugated goat anti-mouse IgG; Becton Dickinson) was added for a further 30 min at room temperature. Cell surface antigens were then labeled by incubating for 30 min at room temperature with phycoerythrin-conjugated MoAbs after the integrity of the membranes was restored by a 10-min incubation in FACS buffer. In some experiments, only cell surface labeling was performed. An irrelevant isotype-matched murine MoAb was used as a negative control.

Lymphocytes were gated on the basis of forward and side scatter. A minimum of 10^4 cells were analyzed on a FACScan (Becton Dickinson) and the results are shown as contour graphs. Thresholds for positive staining were set at <2% using the negative control and percentages of positive cells were obtained by subtracting the value of the control.

Statistical analysis

Results were analyzed using Sigma Plot for Windows, version 1.02 (Jandel Scientific). Statistical analyses were performed using a Student's *t*-test 1-way analysis for comparison of means.

RESULTS

Lymphocyte subpopulations (T and NK cells) and total perforin-positive cells

Significant increases in CD3⁺ and CD8⁺ cells in the peripheral blood lymphocytes of psoriatic patients in the acute phase of disease were found compared to healthy controls (Fig. 1). The incidence of CD3⁺ cells increased from 62% to 74.4% and the incidence of CD8⁺ cells increased from 23.2% to 36.5% ($p < 0.001$). There was no difference between the healthy control group and the patient group in terms of either CD4⁺ T lymphocytes or both markers of NK cells (CD16⁺ and CD56⁺). The percentage of lymphocytes containing cytolytic molecule perforin (P⁺ cells) was slightly higher in the patient group than in the healthy control group, but this difference was not significant (Fig. 1). The incidence of total P⁺ lymphocytes was 31.4% for the patient group and 27% for the healthy controls.

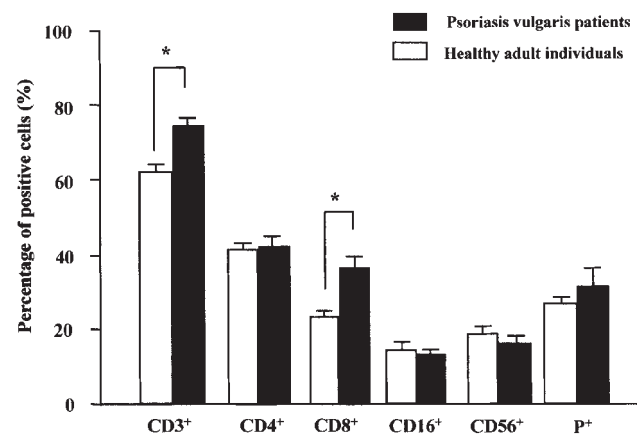


Fig. 1. The percentages of T and NK lymphocyte populations and total perforin-positive cells (P⁺) in peripheral blood lymphocytes of patients in the exacerbation phase of chronic psoriasis vulgaris compared to healthy controls. * $p < 0.001$.

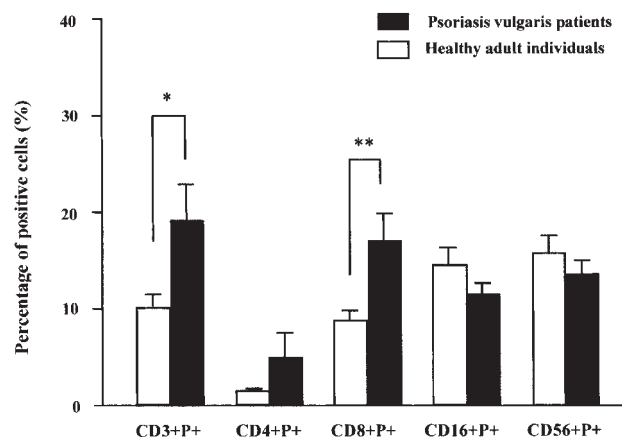


Fig. 2. The percentage of double positive lymphocytes [perforin-positive (P⁺) and surface marker-positive] in peripheral blood of patients in the exacerbation phase of chronic psoriasis vulgaris compared to healthy controls. * $p < 0.02$, ** $p < 0.01$.

Double positive peripheral blood lymphocytes

Double positive cells (simultaneously perforin-positive and surface marker-positive) are represented as a fraction of the total peripheral blood lymphocytes counted (10,000 cells), which is set at 100% (Fig. 2). A significant increase in perforin expression was found in the patient group for the population of T lymphocytes, i.e. CD3⁺ P⁺ cells (19.2% vs. 10%; $p < 0.02$). This increase occurred mostly in the CD8⁺ population of T lymphocytes (CD8⁺ P⁺), which was significantly higher in the patient group ($p < 0.01$). A slight but non-significant increase was also found for CD4⁺ P⁺ cells. There was no significant difference for both populations of NK cells (CD16⁺ P⁺ and CD56⁺ P⁺), in spite of the fact that slightly lower levels were found in the psoriasis group.

DISCUSSION

It has been shown that the perforin-mediated cytolytic pathway plays a role in the rejection of foreign tissue, autoimmunity, control of tumor growth and viral infections and infections by intracellular pathogens (9–11), and is greatly weakened in elderly subjects (8). In the cytotoxic pathway mediated by regulated secretion of granules the formation of membrane pores by perforin is a prerequisite for apoptosis of the target cell (12, 13). In addition to perforin the main protein component of granules is a group of serine proteases known as granzymes (14). Their main function is to mediate target DNA degradation upon gaining entry to the target cell by means of perforin pores (7).

In the present investigation we noticed significant differences in some lymphocyte subpopulations between healthy controls and psoriatic patients. The cloning of skin-infiltrating lymphocytes from lesional skin showed that some clones are cytotoxic against autologous lymphoblastic cell lines. Cytolytic clones were mostly CD4⁺ and some exhibited characteristics of NK cells (15). Eruption of acute psoriatic lesions coincides with the epidermal influx and activation of CD4⁺ T cells, whereas spontaneous disease resolution is associated with recruitment of CD8⁺ cells (16). Accordingly, the absence of CD8⁺ cytotoxic clones in the experiments

cited above could be the consequence of the clinical phase of the disease, when samples were collected.

Cellular infiltrates in lesional skin consist largely of HLA-DR+ /IL-2R+ T cells, i.e. activated T cells (17), and perforin expression in T cells is a marker for functionally activated cytotoxic cells *in situ* (5, 7). Evidence of the role of granzyme B-expressing CD8-positive T cells and perforin-positive cells in the apoptosis of keratinocytes in lichen planus, which is also thought to be a T cell-mediated disease, has been obtained (18). However, perforin expression in psoriatic patients was not analyzed either *in situ* or in cloned cells.

There was no significant difference in perforin expression in NK cell subpopulations between psoriatic patients and healthy controls. The percentage of P+ cells was slightly lower in the patient group. This might mean either that these cells are shifted to the lesional skin or that NK cells and lymphocyte-mediated antibody-dependent cytotoxicity do not play an important role in the pathogenesis of psoriasis.

Although preliminary, the results of perforin expression in the T lymphocytes of psoriatic patients are interesting. They point to the role that perforin could play in the pathogenesis of the disease, particularly in the exacerbation phase. We have examined perforin expression in CTL, both CD4+ P+ and CD8+ P+ cells, in order to directly address the question of whether a specific cell population containing perforin in its granules is operative in the disease process *in vivo*. The results clearly showed that CD3+ P+ cells are upregulated compared to healthy controls in the phase of disease exacerbation, and that this increase is mostly located in the CD8+ P+ subpopulation ($p < 0.01$). CD8+ P+ cells are the subpopulation of CD8+ T lymphocytes with cytotoxic potential and rapid killing of target cells bearing MHC class I molecules and appropriate antigen (5, 7). These cells could participate directly in the switching off of the inflammatory process via HLA class I-mediated recognition of the psoriasis epitope(s) (16). Investigations of perforin expression in the T lymphocytes at various disease stages and simultaneous detection in the peripheral blood and lesional skin, which are in progress in our laboratory, could shed light on the potential role of cytolytic pathways in the clinical course of the disease.

ACKNOWLEDGEMENT

These investigations are partially supported by the Ministry of Science and Technology of the Republic of Croatia (Grant no. 062041).

REFERENCES

1. Dahl MV. Psoriasis and lichen planus. In: Dahl MV, ed. Clinical immunodermatology, 3rd edn. St. Louis, MO: Mosby, 1996: 301–315.
2. Krueger JG, Krane JF, Carter DM, Gottlieb AB. Role of growth

- factors, cytokines, and their receptors in the pathogenesis of psoriasis. *J Invest Dermatol* 1990; 94(6 Suppl): 135S–140S.
3. Valdimarsson H, Baker BS, Jonsdottir I, Fry L. Psoriasis: a disease of abnormal keratinocyte proliferation induced by T lymphocytes. *Immunol Today* 1986; 7: 256–259.
4. Bos JD, Hagenaaars C, Das PK, Kreig SR, Voorn WJ, Kapsenberg ML. Predominance of “memory” T cells (CD4+ , CDw29+) over “naïve” T cells (CD4+ , CD45R) in both normal and diseased human skin. *Arch Dermatol Res* 1989; 281: 24–30.
5. Podack ER. Perforin: structure, function and regulation. *Curr Top Microbiol Immunol* 1992; 178: 175–184.
6. Yagita H, Nakata M, Kawasaki A, Shinkai Y, Okumura K. Role of perforin in lymphocyte-mediated cytotoxicity. *Adv Immunol* 1992; 51: 215–241.
7. Podack ER. Functional significance of two cytolytic pathways of cytotoxic T lymphocytes. *J Leukoc Biol* 1995; 57: 548–552.
8. Rukavina D, Laskarin G, Rubesa G, Strbo N, Bedenicki I, Manestar D, et al. The age-related decline of perforin expression in human cytotoxic T lymphocytes and natural killer cells. *Blood* 1998; 92: 1–12.
9. Rukavina D, Balen-Marunic S, Rubesa G, Orlic P, Vujaklija K, Podack ER. Perforin expression in peripheral blood lymphocytes in rejecting and tolerating kidney transplant recipients. *Transplantation* 1996; 61: 285–291.
10. Rubesa G, Podack ER, Sepcic J, Rukavina D. Increased perforin expression in peripheral blood lymphocytes in multiple sclerosis patients in exacerbation of disease. *J Neuroimmunol* 1997; 74: 198–204.
11. Liu CC, Walsh CM, Yung JD. Perforin: Structure and function. *Immunol Today* 1995; 16: 194–201.
12. Shi L, Kam CM, Powers JC, Aebersold R, Greenberg AH. Purification of three cytotoxic lymphocyte granule serine proteases that induce apoptosis through distinct substrate and target cell interactions. *J Exp Med* 1992; 176: 1521–1529.
13. Shiver JW, Su L, Henkart PA. Cytotoxicity with target DNA breakdown by rat basophilic leukemia cells expressing both cytolytic and granzyme A. *Cell* 1992; 71: 315–322.
14. Hameed A, Lowrey DM, Lichtenheld M, Podack ER. Characterization of three serine esterases isolated from human interleukin-2 activated killer cells. *J Immunol* 1988; 141: 3142–3147.
15. Nikaein A, Morris L, Phillips C, Soliman M, Ordonez G, Silverman A, et al. Characterization of T-cell clones generated from skin of patients with psoriasis. *J Am Acad Dermatol* 1993; 28: 551–557.
16. Valdimarsson H, Baker BS, Jonsdottir I, Powles A, Fry L. Psoriasis: a T-cell-mediated autoimmune disease induced by streptococcal superantigens? *Immunol Today* 1995; 16: 145–149.
17. De Boer OJ, van der Loos CM, Hamerlinck F, Bos JD, Das PK. Reappraisal of *in situ* immunophenotypic analysis of psoriasis skin: interaction of activated HLA-DR+ immunocompetent cells and endothelial cells is a major feature of psoriatic lesions. *Arch Dermatol Res* 1994; 286: 87–96.
18. Shimizu M, Higaki Y, Higaki M, Kawashima M. The role of granzyme B-expressing CD8-positive T cells in apoptosis of keratinocytes in lichen planus. *Arch Dermatol Res* 1997; 289: 527–532.