

# Clinical Outcomes in Patients after Lumbar Disk Surgery with Annular Reinforcement Device: Two-Year Follow Up

---

Vukas, Duje; Ledić, Darko; Grahovac, Gordan; Kolić, Zlatko; Rotim, Krešimir; Vilendečić, Milorad

Source / Izvornik: **Acta clinica Croatica, 2013, 52., 87 - 91**

Journal article, Published version

Rad u časopisu, Objavljena verzija rada (izdavačev PDF)

Permanent link / Trajna poveznica: <https://urn.nsk.hr/urn:nbn:hr:184:488221>

Rights / Prava: [In copyright](#) / [Zaštićeno autorskim pravom.](#)

Download date / Datum preuzimanja: **2025-01-01**



Repository / Repozitorij:

[Repository of the University of Rijeka, Faculty of Medicine - FMRI Repository](#)



# CLINICAL OUTCOMES IN PATIENTS AFTER LUMBAR DISK SURGERY WITH ANNULAR REINFORCEMENT DEVICE: TWO-YEAR FOLLOW UP

Duje Vukas<sup>1</sup>, Darko Ledić<sup>1</sup>, Gordan Grahovac<sup>2</sup>, Zlatko Kolić<sup>1</sup>, Krešimir Rotim<sup>3</sup> and Milorad Vilendečić<sup>2</sup>

<sup>1</sup>Rijeka University Hospital Center, Rijeka; <sup>2</sup>Dubrava University Hospital; <sup>3</sup>Sestre milosrdnice University Hospital Center, Zagreb, Croatia

**SUMMARY** – Annular Reinforcement Device represents a modification of operative treatment of intervertebral disk herniation. It is a prosthesis that is anchored into the body of the vertebra. The intradiscal part of the implant is placed in the inner part of the annulus fibrosus defect. The aim of this technique is to reduce the incidence of reherniation and the degree of intervertebral space collapse, which is the most frequent adverse effect of discectomy. Clinical outcomes of the treatment group indicated a statistically significant improvement with respect to the control group. Furthermore, over the period of two years, no cases of symptomatic reherniation were recorded. Considering that no serious complications occurred during the procedures, it would appear that this is an implant that, given its encouraging results, should be further verified in carefully designed future studies.

**Key words:** *Annular closure device; Lumbar spine; Intervertebral disk; Disk herniation; Discectomy, outcome*

## Introduction

The most frequent cause of radicular pain in the leg among the working population is disk herniation. In most cases, the symptoms remit spontaneously following conservative treatment, with no indication for surgery<sup>1</sup>. In some patients, however, operative treatment is indicated<sup>2</sup>. These are patients with serious neurologic deficits, those with cauda equina syndrome, and, most frequently, those patients that show no improvement following conservative treatment in the period of six weeks after the onset of symptoms<sup>3</sup>.

Microdiscectomy and sequestrectomy are the most frequent types of operative treatment for treating disk herniation. These are standard operative procedures with positive clinical outcomes; 70%-80% of patients report satisfactory recovery<sup>2</sup>.

Correspondence to: *Duje Vukas, MD*, Clinical Department of Neurosurgery, Rijeka University Hospital Center, Tome Strižića 3, HR-51000 Rijeka, Croatia  
E-mail: *dvukas@net.hr*

Received April 18, 2012, accepted January 17, 2013

Microdiscectomy is a standard operative procedure for herniated disk<sup>4</sup>. An alternative approach in patients with sequestered disk herniation is sequestrectomy, which represents a less invasive surgical procedure, producing comparable clinical results<sup>5</sup>.

It has also been proven that the incidence of reherniation is reduced when more aggressive discectomy is performed, but such an aggressive approach increases degenerative changes<sup>6</sup>. On the other hand, less invasive discectomy leads to a higher incidence of reherniation<sup>7</sup>.

The idea of modified surgical procedures that would partially replace the disk tissue in order to reduce the impact of the procedure on biomechanical relations has been developed for a number of years now. The first attempts included hard intradiscal materials (stainless steel, PEEK)<sup>8,9</sup> that are implanted inside the disk itself. Next, nucleus replacement implants made of different biochemical structures (hydrogel, polyvinyl-alcohol, hydrolyzed polyacrylonitrile polymer, polyurethane, protein hydrogel)<sup>10-14</sup> that are inserted inside the disk

and primarily function so as to absorb water, have been developed. The goal of this has been to try and re-establish the anatomical relations as they were prior to surgical procedure, and keep them as such.

There are also implants that function mechanically, with the aim of closing the defect in the annulus fibrosus and protect the remaining disk tissue. Clinical results obtained with the latter technique were the focus of this study.

There are a few main consequences for the biomechanics of the treated segment. The collapse of the intervertebral disk space speeds up degenerative changes, especially in the facet joints. The most frequent adverse consequences of the procedure are the increase in the speed of degenerative changes, accompanied by chronic pain. Another frequent complication, occurring in up to 25% of surgical patients, is reherniation within ten years after surgical procedure<sup>15</sup>, which is the leading cause of repeated surgical procedures.

The first approach described was suture of the annulus following discectomy<sup>16</sup>. Then, over the past fifteen years, injectable hydroactive substances and mechanical implants have been developed. The most frequent complication of the aforementioned surgical procedures was migration of the implanted material from the intervertebral space, inflammatory reaction of the endplates, and implant subsidence<sup>17,18</sup>.

The study reported below presents comparison of patients treated prospectively by standard microdiscectomy (control group), and patients who, following evacuation of the disk tissue during microdiscectomy, had the Annular Reinforcement Device (Barricaid ARD, Intrinsic Therapeutics, Woburn, MA USA) (Fig. 1) inserted, with the aim of preserving the anatomical structures.

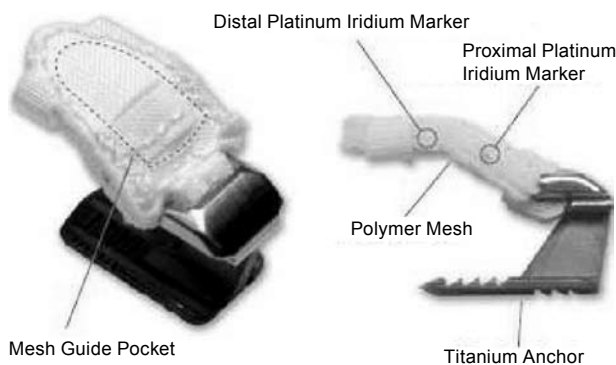


Fig. 1. Barricaid Annular Reinforcement Device.

## Patients and Methods

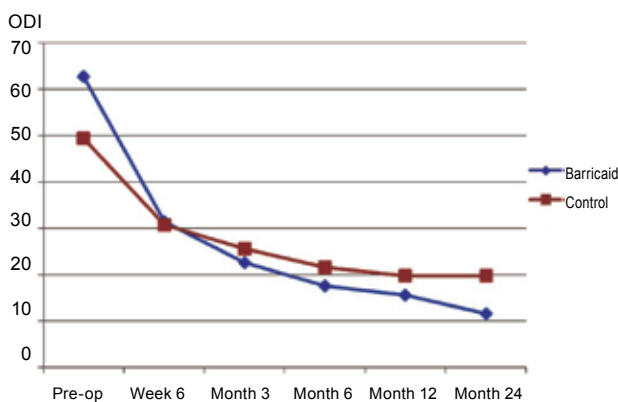
In this prospective study, we followed two groups of patients non-concurrently in an identical way. Control group comprised 72 patients who were treated with standard discectomy between 2003 and 2007, before the Annular Reinforcement Device was available. Treatment group patients received the Annular Reinforcement Device in 2008 and 2009. Treatment group consisted of 30 patients, 16 male and 14 female, mean age 38.2 years, treated and followed up by the same physicians as the control group. In the control group, there were 49 male and 23 female patients, mean age 40.6 years. The aim of this study was to compare and contrast clinical outcome in patients of the two groups over the study period of 24 months. Patients were treated at two hospitals (Dubrava University Hospital, Zagreb, and Rijeka University Hospital Center, Rijeka, Croatia). The patients were followed up in identical manner. First examination was carried out prior to surgery, second examination immediately after the surgery, and then at 6 weeks, 3 months, 6 months, 12 months, and finally two years after surgical procedure. At both hospitals, the treatment group was approved by the institution's ethics committee, although changes to the device and protocol were made with subsequent ethics committee review. The control group was an investigator initiated study approved by each institution's ethics committee. During the follow up period, any patient reporting symptoms would be physically examined and referred for magnetic resonance imaging (MRI) to confirm suspected reherniation.

Similar inclusion/exclusion criteria were applied to both groups. All patients suffered from neurologic deficit (radiculopathy) for at least six weeks. The deficit did not improve with conservative treatment. All patients underwent preoperative MRI to confirm disk herniation as the cause of neurologic deficit. Patients with leg pain measured by the visual analog scale (VAS) of the intensity 40/100 or more and disability graded by means of the Oswestry Disability Index (ODI) higher than 40/100 were included in the implant group. No minimum ODI was applied in the group undergoing only discectomy. VAS and ODI at all time points were administered and graded by the same physicians in the treatment and

Table 1. Oswestry Disability Index

Time point	Control		Barricaid		p*
	Mean	SD	Mean	SD	
Preoperative	49.4	18.3	62.7	13.7	0.0004
Week 6	30.7	15.5	31.4	14.6	0.7505
Month 3	25.6	13.9	22.6	10.9	0.4239
Month 6	21.6	15.5	17.7	11.5	0.3639
Month 12	19.8	15.8	15.6	12.2	0.2743
Month 24	19.8	17.1	11.6	10.4	0.0763

\*Wilcoxon rank-sum



control groups. All patients were in the age range 18-70 years. Patients who had previously had some spine surgery were not included in the study. Also, patients suffering from foraminal or extraforaminal disk herniation were also excluded from the study, as well as those who suffered from some other spinal

pathology. Patients unable or unwilling to take part in the study, as well as those suffering from systemic or metabolic diseases were not included either. The annulus fibrosus defect was measured during the surgery, and, following the prosthesis manufacturer's instructions, the prosthesis was not implanted in those patients with annulus defect greater than 6x10 mm (height x width).

### Surgical technique

All patients were treated with lumbar discectomy. All surgeries were performed under general anesthesia. The patients were in the prone position, with knees and hips flexed. Prior to surgical procedure, each surgical patient was administered antibiotic prophylaxis (cefazolin). Medial incision of the skin was used for unilateral approach to the intralaminar space. Fluoroscopy was used to verify appropriateness of the space. Flavectomy was performed, most frequently accompanied by cranial lamina undercutting. In all treatment group patients, prosthesis for annular reinforcement was implanted. The prosthesis is made of a titanium anchor and polymer mesh. The planned location of the mesh is between the remaining material of the nuclear tissue and annulus fibrosus. The mesh contains markers that are visible on x-rays, and are used for visual control of the implant position (Fig. 2). The implant (prosthesis) is inserted following the manufacturer's recommendations. Each step is guided by fluoroscopy.

### Results

The implant was inserted in all patients who were planned to receive prosthesis and satisfied the criteria for inclusion in the study. There were no intraoperative complications due to the modification of the standard procedure. The procedure was not significantly prolonged, and the postoperative course was identical in both groups. Postoperative care in the hospital was identical (a mean of 4 days). In terms of complications, we report durotomy in one patient from the treatment and control group each.

The mean preoperative ODI was 49.4 in control group and 62.7 in treatment group. In both groups, there was considerable (ex-

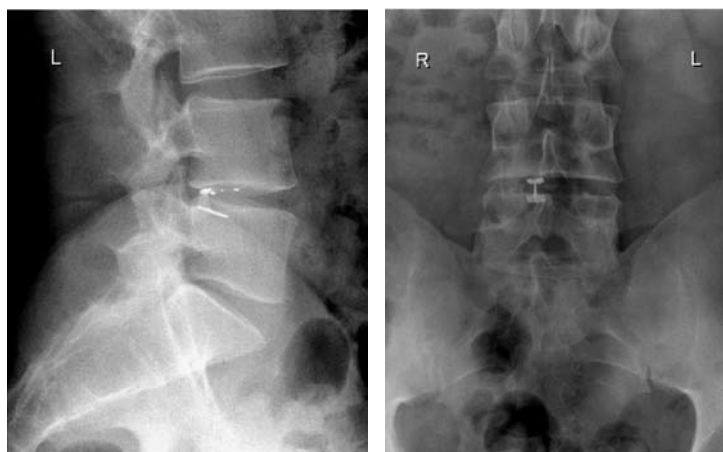


Fig. 2. Annular Reinforcement Device in situ.

Table 2. Visual analog scale – back

Time point	Control		Barricaid		p*
	Mean	SD	Mean	SD	
Preoperative	43.1	24.2	66.3	16.6	0.0000
Week 6	22.5	20.4	18.1	18.0	0.3770
Month 3	22.8	22.0	12.1	11.2	0.0560
Month 6	23.4	23.4	14.1	11.6	0.2100
Month 12	21.0	21.4	13.2	15.9	0.1360
Month 24	19.1	21.9	10.5	19.5	0.2725

\*Wilcoxon rank-sum

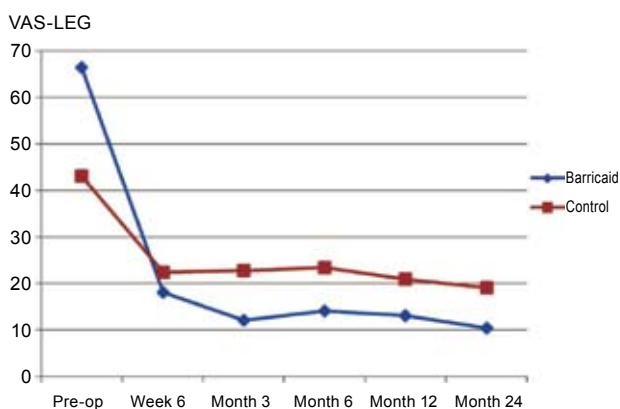
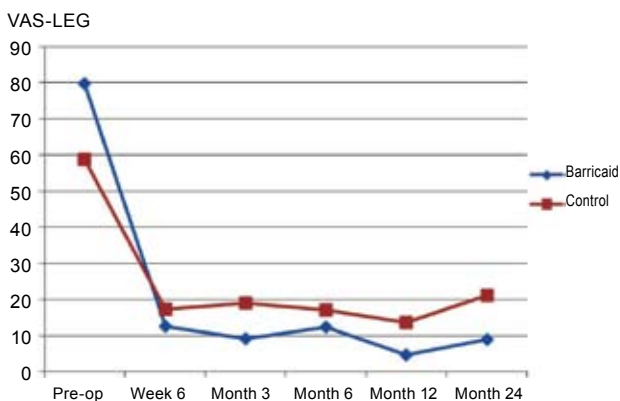


Table 3. Visual analog scale – ipsilateral leg

Time point	Control		Barricaid		P*
	Mean	SD	Mean	SD	
Preoperative	58.8	26.7	79.8	12.8	0.0001
Week 6	17.4	19.7	12.7	18.4	0.2568
Month 3	19.0	22.5	9.2	15.0	0.0558
Month 6	17.1	23.6	12.3	19.3	0.6961
Month 12	13.6	16.4	4.7	8.1	0.0160
Month 24	21.2	23.1	8.9	20.1	0.0046

\*Wilcoxon rank-sum



pected) improvement following the surgery. In the first 6 months of surgical procedure, the improvement was relatively the same in both groups, whereas at 24 months of the procedure ODI score was 11.6 in treatment group and 19.8 in control group (Table 1).

VAS was analyzed separately for back pain and for pain in the affected leg. In this case, too, treatment group showed higher preoperative values. The mean preoperative VAS-back was 43.1 in control group and 66.3 in treatment group. At 24 months of the surgery, the difference in VAS-back was 8.6 (19.1 in control group and 10.5 in treatment group) (Table 2).

VAS-affected leg was statistically better in treatment group at both 12 (p=0.016) and 24 months (p=0.0046) of the procedure. At 24 months, the difference between the two groups was 12.3 (21.2 in control group and 8.9 in treatment group) (Table 3).

In treatment group, not a single symptomatic reherniation occurred. In control group, a 6.9% (5/72) symptomatic reherniation rate was recorded over 2-year period, with two of the five reherniations occurring in the first three months following the procedure. All of these were reoperated on. There were no instances of implanted material migration out of or subsidence into the vertebral body.

### Discussion and Conclusion

Intradiscal implants represent a relatively new technology for treating disk herniation. The implant we used is simple to use and does not lengthen the duration of surgical procedure. Its use led to significant clinical improvement as compared with patients who underwent standard discectomy. Furthermore, there was no case of symptomatic reherniation at the operated level among treatment group patients. Outcomes in both groups were good, with treatment group outcomes being even better; however, the difference was generally nonsignificant. The significance in leg pain on later follow ups, along with the near significance at three months, may have been closely related to the occurrence of symptomatic reherniations in control group. A larger study would be useful to clarify these results. Since our postoperative follow up was quite short (two years), the study needs to be continued. Good clinical results obtained in this study are very encouraging with respect to positive attitudes toward the implant as a treatment method.

## References

- WEINSTEIN JN, LURIE JD, TOSTESON TD, TOSTESON AN, BLOOD EA, ABDU WA, *et al.* Surgical *versus* nonoperative treatment for lumbar disk herniation. *Spine* 2008;33:2789-800.
- MOORE AJ, CHILTON JD, UTTLEY D. Long-term results of microlumbar discectomy. *Br J Neurosurg* 1994;8:319-26.
- ATLAS SJ, KELLER RB, WU YA. Long-term outcomes of surgical and nonsurgical management of sciatica secondary to a lumbar disc herniation: 10 year results from the Maine Lumbar Spine study. *Spine* 2005;30:927-35.
- GIBSON JN, GRANT IC, WADDELL G. The Cochrane review of surgery for lumbar disc prolapsed and degenerative lumbar spondylosis. *Spine* 1999;24:1820-32.
- THOME C, BARTH M, SCHARF J, SCHMIEDEK P. Outcome after lumbar sequestrectomy compared with microdiscectomy: a prospective randomized study. *J Neurosurg Spine* 2005;2:271-8.
- WATTERS WC, MCGIRT MJ. An evidence-based review of the literature on the consequences of conservative *versus* aggressive discectomy for the treatment of primary disc herniation with radiculopathy. *Spine* 2009;9:240-57.
- CARRAGEE E, HAN M, SUEN P, KOM D. Clinical outcomes after lumbar discectomy for sciatica: the effects of fragment type and annular competence. *J Bone Joint Surg Am* 2003;85-A:102-8.
- GOINS ML, WIMBERLEY DW, YUAN PS, FITZHENRY LN, VACCARO AR. Nucleus pulposus replacement: an emerging technology. *Spine* 2005;5 Suppl 6:317-24.
- McKENZIE AH. Fernstrom intervertebral disc arthroplasty: long term clinical results. *Orthop Intern* 1995;3:313-24.
- BERTAGNOLI R, SABATINO CT, EDWARDS JT, GONTARZ GA, PREWETT A, PERSONS JR. Mechanical testing of a novel hydrogel nucleus replacement implant. *Spine J* 2005;5:672-81.
- ALLEN MJ, SCHOONMAKER JE, BAUER TW, WILLIAMS PF, HIGHAM PA, YUAN HA. Preclinical evaluation of a poly(vinyl alcohol) hydrogel implant as a replacement for the nucleus pulposus. *Spine* 2004;29:515-23.
- BAO QB, YUAN HA. New technologies in spine: nucleus replacement. *Spine* 2002;27:1245-7.
- HUANG RC, TROPIANO P, MARNAY T, GIRARDI FP, LIM MR, CAMMISA FP Jr. Range of motion and adjacent level degeneration after lumbar thoracic disc replacement. *Spine J* 2006;6:242-7.
- BERTAGNOLI R, KARG A, VOIGT S. Lumbar partial disc replacement. *Ortop Clin North Am* 2005;36:341-7.
- DAVIS RA. A long-term outcome analysis of 984 surgically treated herniated lumbar discs. *J Neurosurg* 1994;80:415-21.
- YASARGIL MG. Microsurgical operation of herniated lumbar disc. *Adv Neurosurg* 1977;4:81.
- KORGE A, NYDEGGER T, POLARD JL, MAYER H, HUSSON J. A spiral implant as nucleus prosthesis in the lumbar spine. *Eur Spine J* 2002;11:149-53.
- BERTAGNOLI R, SCHÖNMAYER R. Surgical and clinical results with the PDN® prosthetic disc-nucleus device. *Eur Spine J* 2002;11:143-8.

## Sažetak

### KLINIČKI ISHOD U BOLESNIKA NAKON OPERACIJE HERNIJE INTERVERTEBRALNOG DISKA POMOĆU PROTEZE ZA REKONSTRUKCIJU DEFEKTA ANULUSA: REZULTATI DVOGODIŠNJEG PRAĆENJA

*D. Vukas, D. Ledić, G. Grabovac, Z. Kolić, K. Rotim i M. Vilendečić*

Ugradnja proteze za rekonstrukciju defekta anulusa čini modifikaciju operacijskog liječenja hernije intervertebralnog diska. Radi se o protezi koja se ugrađuje (usidri) u korpus kralješka. Intradiskalni dio implantata postavlja se s unutarnje strane defekta anulusa fibrozusa. Cilj navedene tehnike je smanjivanje incidencije rehernijacija te smanjivanje stupnja kolapsa intervertebralnog prostora kao najčešćih neželjenih posljedica diskektomije. Klinički ishod ispitivane skupine pokazao je statistički značajan napredak u odnosu na kontrolnu skupinu. Također tijekom dvije godine nije zabilježen nijedan slučaj simptomatske rehernijacije. S obzirom na to da nije bilo ozbiljnih komplikacija tijekom samog zahvata, smatramo da se radi o implantatu čiji početni rezultati ohrabruju te se moraju potvrditi u slijedećim dobro dizajniranim prospektivnim studijama.

Ključne riječi: *Proteza za rekonstrukciju defekta anulusa; Lumbalni segment kralježnice; Intervertebralni disk; Hernija diska; Diskektomija; Ishod*

