

Successful Treatment of Acute Aortic Dissection Type Stanford A Presenting as Limb Ischemia, ype Stanford A Presenting as Limb Ischemia, Successfully Tre ...

Kovačević, Miljenko; Borojević, Marin; Medved, Igor; Kovačić, Slavica; Primc, Davor; Sokolić, Jadranko

Source / Izvornik: Collegium antropologicum, 2015, 39, 953 - 956

Journal article, Published version

Rad u časopisu, Objavljena verzija rada (izdavačev PDF)

Permanent link / Trajna poveznica: <https://um.nsk.hr/um:nbn:hr:184:317397>

Rights / Prava: [In copyright](#)/[Zaštićeno autorskim pravom.](#)

Download date / Datum preuzimanja: **2025-01-13**



Repository / Repozitorij:

[Repository of the University of Rijeka, Faculty of Medicine - FMRI Repository](#)



Successful Treatment of Acute Aortic Dissection Type Stanford A Presenting as Limb Ischemia, Successfully Treated with Operative and Endovascular Procedures

Miljenko Kovačević¹, Marin Borojević¹, Igor Medved¹, Slavica Kovačić², Davor Primožič¹ and Jadranko Sokolić³

¹ Department of Surgery, Clinical Hospital Center Rijeka, Rijeka, Croatia

² Department of Radiology, Clinical Hospital Center Rijeka, Rijeka, Croatia

³ Department of Anesthesiology, Clinical Hospital Center Rijeka, Rijeka, Croatia

ABSTRACT

We report a successful treatment of unusual case of a 48 year old male patient with acute aortic dissection type Stanford A that expanded into left common and external iliac artery diagnosed by MSCT angiography, presenting as a single leg paresis, without symptoms of a chest or back pain. Patient was operated with conventional ascending aortic replacement. Patient had no known prior medical condition. He has been treated for acute thrombosis of the left popliteal artery developing one day after ascending aortic replacement surgery, embolectomy was performed. Critical limb ischemia developed due to preocclusive stenosis of the left common and left external iliac artery and was treated by endovascular procedure of iliac artery stenting performed on the fifth postoperative day. After 17 days patient was discharged from hospital, showing no neurological or vascular deficit. For successful treatment of acute aortic dissection type Stanford A complicated with limb ischemia, rapid and accurate diagnosis is essential, together with close cooperation of cardio surgeons, vascular surgeons and invasive radiologists and individual approach to these demanding patients.

Key words: acute aortic dissection, ascending aorta, Stanford A, postoperative complication, thrombosis, preocclusive stenosis, common iliac artery, popliteal artery, thrombectomy, good postoperative result

Introduction

Acute aortic dissection is defined as the rapid development of a false, blood filled channel within the tunica media of the aorta¹. Acute type Stanford A aortic dissection (DeBakey 1) is associated with a significant mortality rate, which has been reported as 1% per hour in the first 48 hours or about 50% at 2 days, 75% at 2 weeks, and 90% at 1 year². Aortic dissection can be rapidly fatal with patient dying before diagnosis is made. No clinical symptom alone can positively identify acute aortic dissection. Once an acute aortic dissection develops, symptoms can be produced by rupture or the occlusion of blood vessels. Although severe chest or back pain is most common symptom, aortic dissection can very rarely be painless³. Diagnosis involves: history and physical examination, electrocardiography, imaging studies and laboratory tests (serum chemistry, blood count, cardiac markers). Two most used classification schemes are DeBakey and Stanford classification (Figure 1).

Case Report

A 48 years old male patient arrived at the emergency department presenting with acute monoparesis of a left lower extremity that started one hour before he was admitted to the emergency department.

He had no prior known medical conditions and took no medications.

His major complaint was left leg paresis with clinical signs of acute limb ischemia.

During physical exam there was an left sided absence of femoral artery pulsations, accompanied by slight cyanosis and a loss of sensation and movement of the left leg.

His vital signs were: blood pressure 165/90 mmHg, pulse 80/min, respiration rate of 16/min, oxygen saturation 95%. Electrocardiogram shows sinus rhythm, right bundle branch block, and negative T waves in V5 and V6.

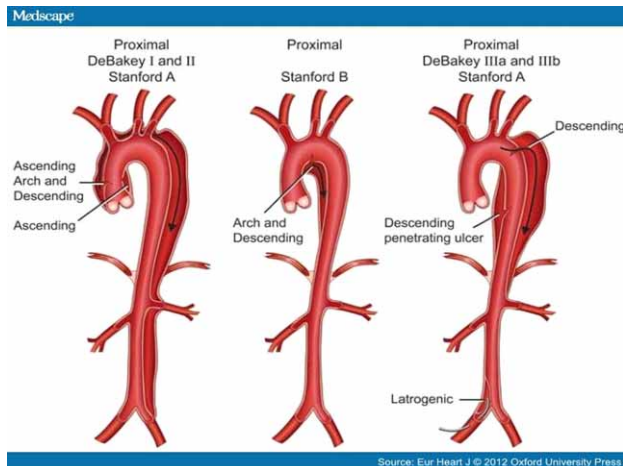


Fig. 1. DeBakey and Stanford classification.

An urgent MSCT angiography shown aortic dissection (DeBakey 1/Stanford A) (Figure 2) that started from typically above aortic valve level and expanded distally all the way to the left common iliac artery and right external iliac artery. There were no signs of aortic rupture.

Normal blood flow to the right lower extremity was recorded.

Left renal artery originated from the false lumen, and right renal artery originated from the renal lumen. Celiac artery and upper mesenteric artery originated from both lumens.

On the left side a loss in the blood flow distally of the common iliac artery and common femoral artery was recorded due to dissection and sub-occlusion of left common and external iliac artery (Figures 3a and 3b).

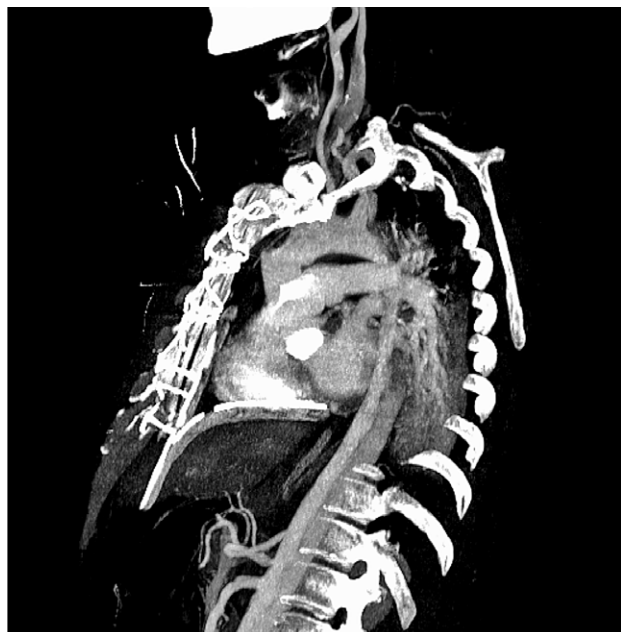


Fig. 2. Aortic dissection type Stanford A.

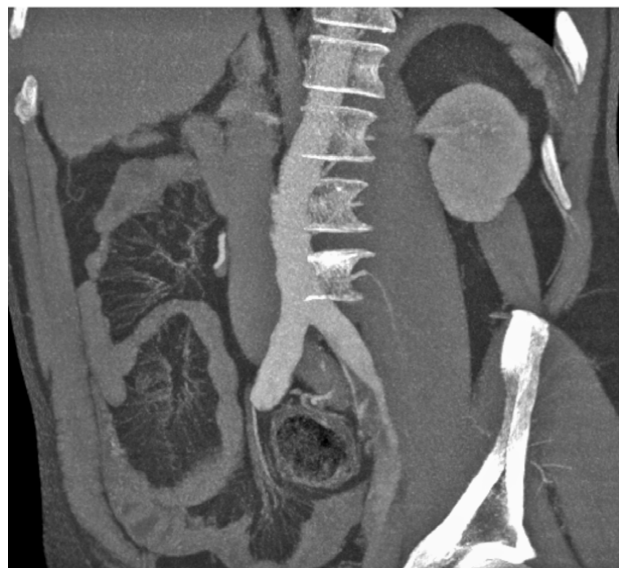
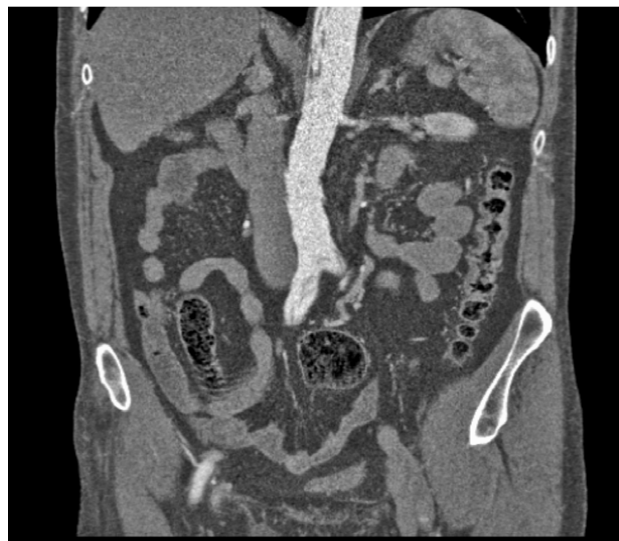
Fig. 3a and 3b. MSCT angiography.

After MSCT angiography patient was immediately transferred to the operating theatre.

We performed endoesophageal echo and verified starting point of aortic dissection 15 mm above the aortic valve and aortic valve insufficiency grade 4.

A median sternotomy was performed, cardio-pulmonary bypass with moderate hypothermia procedure was started with cannulation of right subclavian artery.

Aortic valve and ascending aorta were excised and then replaced by a 25 mm mechanical valve and composite graft, coronary arteries were re-implanted into the composite graft.

After surgery, patient was transferred to the ICU.

Next day, due to persistent limb ischemia MSCT aortography and angiography revealed thrombosis of left popliteal artery (Figure 4) and emergent thrombectomy was performed.

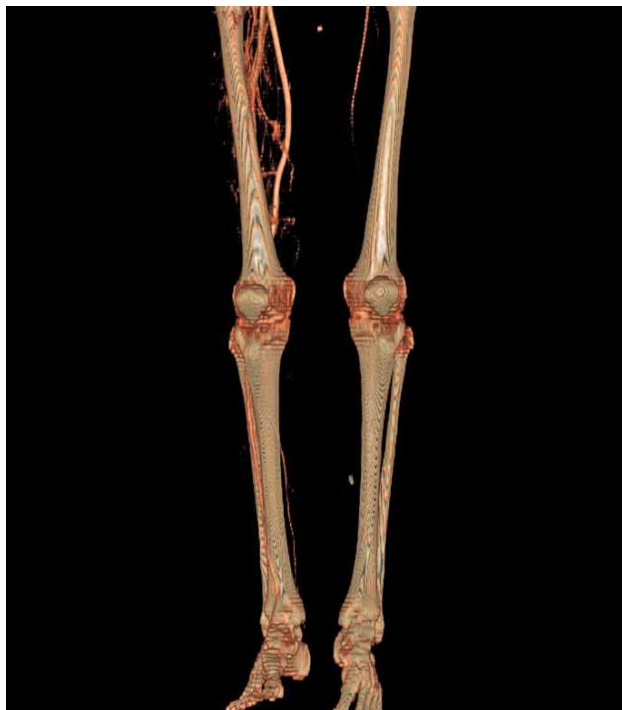

Fig. 4. Loss of blood flow distally of left popliteal artery.

Also, signs of starting thrombosis of false lumen in aortic arch and left external iliac artery were noted. Pre occlusive stenosis of the left common and external iliac artery.

After thrombectomy was performed there were notable regression of clinical signs of left leg ischemia.

During the first four days in ICU patient was hemodynamically stable, after 72 hrs without any inotropic support, without clinical signs of visceral malperfusion. Persistent signs of left limb ischemia remained.

Because of persistent limb ischemia without any other visible clinical complications, as a first choice we decided to try endovascular treatment of persistent subocclusion of dissected left iliac artery and endovascular treatment consisting of placement of 2 STENTs in left iliac artery was performed. Excellent result were noted, with total regression of clinical signs of left limb ischemia.

After seventeen days patient was discharged from hospital without any further complications.

REFERENCES

1. KUMAR, ROBBINS, COTRAN, Pathologic Basis of Disease (Elsevier, New York, 2005). — 2. BREWSTER DC, CRONENWETT JL, HALLETT JR JW, *J Vasc Surg*, 37 (2003) 1106. — 3. DEBAKEY ME, MCCOLLUM CH, CRAWFORD ES, MORRIS GC JR, HOWELL J, *Surgery*, 92 (1982) 1118. — 4. COLAK N, NAZLI Y, FATIH ALPAY M, OLGUN AKKAYA I, CAKIR O, *Tex Heart Inst J*, 39 (2012) 273. — 5. HIRATZKA

Discussion

Acute type Stanford A aortic dissection (DeBakey 1) is associated with a significant mortality rate, which has been reported as 1% per hour in the first 48 hours or about 50% at 2 days, 75% at 2 weeks. Whereas dissection of the aorta can be painless and at times unknown to the patient, pain is typically the most common and dramatic symptom. Many individual cases of painless aortic dissection have been reported. The prevalence of painlessness in aortic dissection has varied in different series⁴.

Mortality and morbidity of this demanding patients are associated with aortic ruptures and malperfusion syndromes, mostly of visceral arteries or supra aortic branches.

The incidence of fatal complications is exceedingly high in acute aortic dissection involving ascending part of the aorta (pericardial tamponade from hemorrhage, severe aortic valvular insufficiency, and malperfusion syndromes of the coronary and arch arteries, to rupture and malperfusion syndromes of other vessels).

Acute limb ischaemia in patients with aortic dissection (Stanford A) is reported as a symptom in 10% of cases⁵. Untreated acute limb ischemia in patients with aortic dissection can lead to extremity loss. In these cases endovascular treatment with stenting could be the first option. When endovascular treatment is impossible, extra anatomic bypasses such as femoro-femoral or axilo-femoral are indicated to prevent limb loss. Because these complications are associated with very high mortality, surgery is always indicated in acute ascending dissections, as the benefits of repair far outweigh the risks in all but a few patients⁶.

Conclusion

In conclusion we report a case of painless aortic dissection type Stanford A that presented only as leg monoparesis. After first urgent aortic surgery, persistent limb ischemia was treated with surgical (thrombectomy) and endovascular procedures (stenting of left iliac artery) with excellent post operative results.

In this patient with acute limb ischemia most important was prompt and precise diagnosis and multidisciplinary approach combined with taking into account general condition and hemodynamical stability of patient. Multidisciplinary approach of cardiac surgeons, vascular surgeons and interventional radiologists and ICU specialists.

LF, BAKRIS GL, BECKMAN JA, BERSIN RM, CARR VF, CASEY DE JR, EAGLE KA, HERMANN LK, ISSELBACHER EM, KAZEROONI EA, KOUCHOUKOS NT, LYTLE BW, MILEWICZ DM, REICH DL, SEN S, SHINN JA, SVENSSON LG, WILLIAMS DM, *Circulation*, 121 (2010) e266. — 6. WONG DR, LEMAIRE SA, COSELLI JS, *Am Surg*, 74 (2008) 364.

M. Kovačević

*University Hospital Center Rijeka, Department of Surgery, Tome Strižića 3, 51 000 Rijeka, Croatia
e-mail: mkovacevic685@gmail.com*

USPJEŠNO PROVEDENO LIJEČENJE AKUTNE DISEKCIJE AORTE TIPA STANFORD A KOJA SE PREZENTIRALA KAO ISHEMIJA EKSTREMITETA, TRETIRANA SA OPERACIJSKIM I ENDOVASKULARNIM POSTUPCIMA

SAŽETAK

Prikazujemo uspješno liječenje neobičnog slučaja 48 godina starog pacijenta sa akutnom disekcijom aorte tipa Stanford A sa disekatom koji se širio u lijevu zajedničku i vanjsku ilijačnu arteriju, dijagnosticiranu MSCT angiografijom, koja se prezentirala kao ishemija donjeg ekstremiteta, bez simptoma stenokardije ili drugih bolnosti. Bolesnik je operiran standardnom tehnikom zamjene uzlazne aorte. U anamnezi bez prethodnih oboljenja. Prvi postoperativni dan, radi razvoja akutne tromboembolije lijeve poplitealne arterije, bolesnik je operiran i učinjena je embolektomija lijeve poplitealne arterije. Zbog preokluzivne stenoze lijeve zajedničke i vanjske ilijačne arterije perzistira kritična ishemija donjeg ekstremiteta koja se tretira endovaskularnim postupkom postavljanja 2 stenta peti postoperativni dan. Nakon 17 dana bolesnik se otpušta iz bolnice bez znakova vaskularnog ili neurološkog deficita. Za uspješno liječenje akutne disekcije aorte tipa Stanford A koja se komplicira kritičnom ishemijom ekstremiteta, brza i točna dijagnostika je od presudne važnosti, uz multidisciplinarnu suradnju tima kojeg čine vaskularni i kardiokirurzi uz invazivne radiologe, sve u cilju poboljšavanja individualnog pristupa svakom od ovih zahtjevnih pacijenata.