

Prognostic Value of Refined Wiberg's Angle in Hip Development

Tudor, Anton; Dalen, Legović; Dušan, Rubinić; Prpić, Tomislav; Salamon, Ratko

Source / Izvornik: **Collegium antropologicum, 2005, 29, 267 - 270**

Journal article, Published version

Rad u časopisu, Objavljena verzija rada (izdavačev PDF)

Permanent link / Trajna poveznica: <https://um.nsk.hr/um:nbn:hr:184:111575>

Rights / Prava: [In copyright](#)/[Zaštićeno autorskim pravom.](#)

Download date / Datum preuzimanja: **2025-03-04**



Repository / Repozitorij:

[Repository of the University of Rijeka, Faculty of Medicine - FMRI Repository](#)



Prognostic Value of Refined Wiberg's Angle in Hip Development

Anton Tudor, Legović Dalen, Rubinić Dušan, Prpić Tomislav and Salamon Ratko

Clinic for Orthopedic Surgery Lovran, Lovran, Croatia

ABSTRACT

There are many angles measured on hip radiographs, but their prognostic value for hip development in patient with DDH is controversial. Our aim was to find out how the development of congenitally luxated hip could be predicted after reduction using Wiberg's CE angle and CE angle refined according to Ogata. 119 hips of 61 patients were retrospectively evaluated after reduction from 3 months of age until at least full osteomaturity. According to results of CE angles measurements good and poor hip development group were formed. Healthy hips of the patients with unilateral DDH were considered to be the control group. Negative linear trend of the curve connecting Wiberg's CE angle values measured within first postreductive years is a poor prognostic sign of hip development as are absolute negative values of refined CE angles. In cases where negative initial refined CE angles are combined with negative linear trend of Wiberg's CE angles prognosis is extremely poor. Both Wiberg's and Ogata's CE angle are of prognostic value regarding hip development and should be measured when evaluating AP radiographs of infant's hip.

Key words: hip development, developmental hip dysplasia (DDH), Wiberg's CE angle

Introduction

Most DDH cases are detectable at birth; however, despite newborn screening programs, some cases are missed. A real historical revolution considering diagnosis and treatment of DDH began in 1936 when Ortolani described clinical test based on femoral gliding in and out of the acetabulum¹. With such a method it is possible to diagnose unstable or dislocated newborn hip immediately after birth. This method has gradually become generally accepted and has proved its validity until present time. However, general clinical screening based on Ortolani's maneuver cannot eliminate all so called »missed« or late cases². Ultrasonography may be helpful in detecting DDH as well. Ultrasound based hip screening of all newborns immediately after delivery seems to be the most effective and may eliminate late diagnosis of DDH³⁻⁶.

When radiographically evaluating infant's hip, commonly, acetabular angle and Wiberg's CE angle are measured. Ogata described refined CE angle as his modification of original Wiberg's CE angle⁷. He modified Wiberg's CE angle proposing that lateral end of subchondral sclerosis, rather than lateral end of visible bony acetabulum should be taken as true lateral end of acetabulum. Subchondral sclerosis is radiographical sign of bio-

mechanically involved part of acetabular roof. Consequently, if some part of acetabular roof is excluded from dynamic transfer of weight-bearing forces AP hip radiograph shows no subchondral sclerosis. One can summarize that part of acetabulum lateral from end of subchondral sclerosis represents biomechanically insufficient part of acetabulum. When measuring standard Wiberg's CE angle, the lateral end of subchondral sclerosis is not taken into account as lateral end point of acetabulum, unless these points overlap (Figure 1). This thesis has been proved using three-dimensional CT examinations of infant's hips and comparing them to plain radiographs of the same hips. In cases where on plain radiograph lateral end of subchondral sclerosis does not reach lateral end of visible bony acetabulum three-dimensional CT confirmed that biomechanically most important part of acetabulum – roof of acetabulum – was insufficient.

In other terms, it means that by using a refined CE angle one can much more accurately define a real coverage of femoral head. For that reason, evaluating plain radiographs of infant hips using only Wiberg's CE angle is not a considerable prognostic sign of hip development after reduction of dislocated hip. Ogata hypotheses that

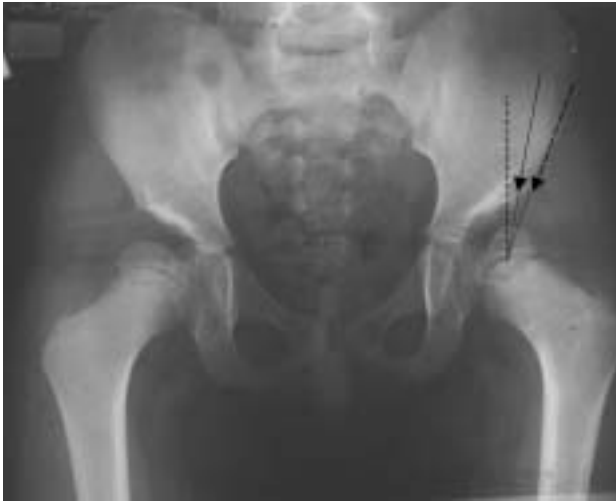

Fig. 1. Wiberg's CE angle (dotted arrow) and CE angle refined according to Ogata (full line arrow)

his CE angle could be quite significant prognostic sign of hip development even though his conclusions were based on limited study material (27 cases).

The goal of this research is to compare significance of Ogata's CE and Wiberg's CE angle when predicting development of the congenitally luxated hip after reduction.

Materials and Methods

Between 1978 and 1987 we treated 61 patients for DDH. Eleven boys and fifty girls formed study group. In 21 patients bilateral luxation was present while in 40 patients we found unilateral luxation. In unilateral luxation group left hip was dysplastic in 29 patients and right hip in 11 patients. Three hips were excluded from the study because of the presence of femoral head osteochondritis. 79 dysplastic hips were reduced using either operative or conservative methods at average age of 20 months (ranging from 3–30). Average follow-up duration was 20 years (ranging from 16–25). Taking at least 20° of Wiberg's CE angle at the end of bone osteomaturity as criterion of good hip development, out of 79 reduced hips, good hip development group was formed by 43 and poor hip development group by 36 hips, respectively. 40 normal hips on the contralateral side of the patients with unilateral involvement formed control group. The method for determination of CE angle related to dysplasia was taken from Severin's classification system^{8,9}.

The patients were evaluated radiographically using Wiberg's CE angle and Ogata's CE angle as radiographic parameters of hip development. Wiberg's CE angle is defined on the AP hip radiograph as the angle between the line perpendicular to the center of the head of the femur and the line connecting hip center and lateral bony end of acetabulum. Wiberg's CE angle modified according to Ogata is defined on the AP hip radiograph as

the angle between the line perpendicular to the center of the head of the femur and the line between center of the hip and lateral end of subchondral sclerosis if it doesn't reach visible bony end of the acetabulum. Both angles were measured on AP hip radiographs taken before and after reduction, and in the first three postreductive years taken two times per year. Finally, Wiberg's CE angle was measured on AP hip radiograph at the end of full osteomaturity – at least sixteen years of age. Statistical evaluation was carried out using unpaired t-tests. Differences were considered to be significant at the level of significance $p < 0.05$.

Results

Wiberg's CE angle mean values of the initial measurements were $15.24^\circ \pm 4.26^\circ$ in poor hip development group compared to $19.84^\circ \pm 5.40^\circ$ in good hip development group and $21.15^\circ \pm 4.20^\circ$ in control group. Refined CE angle mean values of the initial measurements taken after reduction of dislocated hip were $-4.15^\circ \pm 5.82^\circ$ in poor hip development group, while in good hip development group $9.09^\circ \pm 5.08^\circ$ and $14.23^\circ \pm 4.86^\circ$ in control group were measured. Wiberg's CE angle mean values of osteomature hips were $10.72^\circ \pm 5.05^\circ$ in poor hip development group and shows significant difference, in comparison with good hip development group ($30.74^\circ \pm 4.38^\circ$), $p < 0.001$, and control group ($35.05^\circ \pm 5.68^\circ$), $p < 0.001$. Figure 2 summaries results of all measurements taken in all three groups throughout patient's growth. Regression line analysis was performed for both angles in all three groups from the first measurement until osteomaturity, Figures 3a, 3b, and 3c present results.

Discussion

Once DDH has been diagnosed and treatment instituted we are interested in prognosis of hip development especially when and if treated patient could be consid-

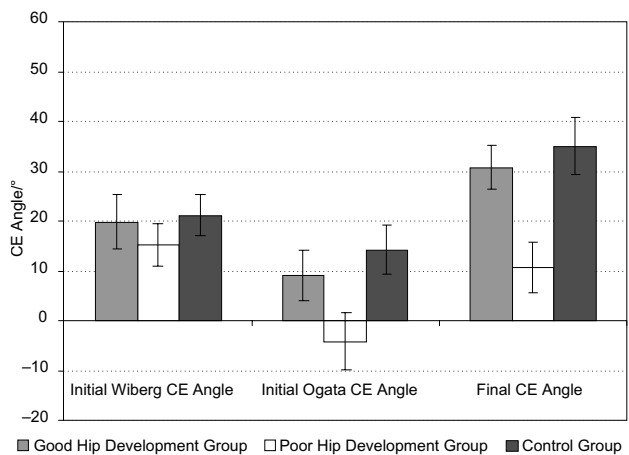


Fig. 2. Wiberg's CE angle and Ogata's CE angle mean values of measurements taken in first three years post reduction and Wiberg's CE angle mean values measured after bone osteomaturity.

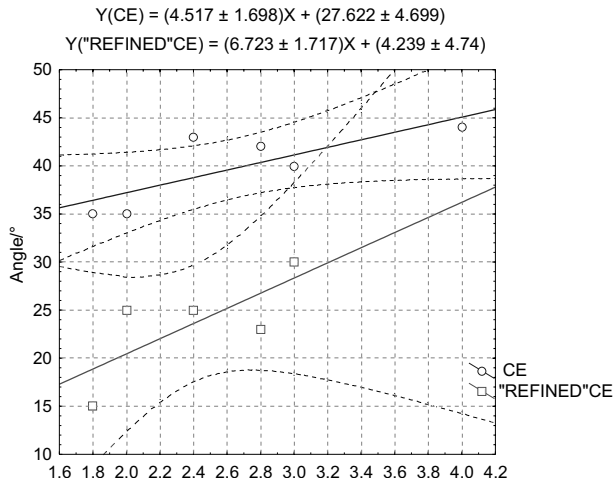


Fig. 3a. The hip development pattern in control group of hips – healthy hips. Trend of both lines is positive (blue color – measured Wiberg's CE angle values, red color – measured refined CE angle values).

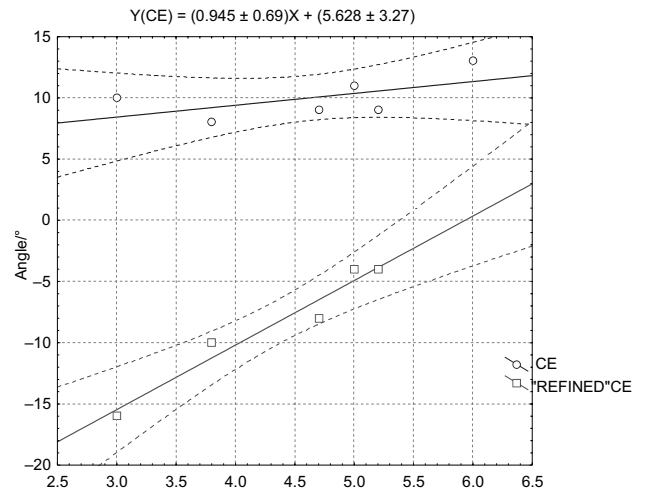


Fig. 3b. The hip development pattern in good hip developing group in postreductive period. Trend of both lines is positive (blue color – measured Wiberg's CE angle values, red color – measured refined CE angle values).

ered healthy. It should be emphasized that purpose of our study was to find out if final hip development could be predicted using measurements derived from simple AP hip radiographs taken in first three years after reduction of dislocated hip. Wiberg's CE angle values are widely accepted to be indirect sign of hip development. Radiographic evaluation of acetabular development through Wiberg's CE angle gives generally information on all parts of acetabulum rather than being specific to the biomechanically the most important part – roof of acetabulum. Ogata proved that lateral end of subchondral sclerosis visible on AP view of hip radiograph presents real lateral end of roof of acetabulum. When drawing angle in patient suspected for DDH one should be very cautious because of at least two reasons – when taking an X-ray child's position cannot be fixed and it is difficult to place referent points on a drawing always in the same place. Single measurement outcomes of these drawings are subject of intra- and interobserver variation¹⁰. One should not draw conclusions of the hip development based on one or two measurements rather than on increase or decrease of absolute values of CE angles throughout patient's growth. In poor hip development group negative absolute values of first measurements of Ogata's CE angles are observed, stressing out poor prognosis for hip development. Regression line analysis shows positive linear trends in both Wiberg's and Ogata's CE angle measurements in good hip development and control group measurements taken in the first three years of postreductive period. In poor hip development group positive linear trend of Ogata's CE angles was observed combined with negative linear trend of classical Wiberg's CE angles. Slight decrease of absolute Wiberg's CE angle values through postreductive three years period presents a paradox at first, implying development of hip from better to worse. It could be explained that measuring Wiberg's and Ogata's CE angles different referent points are taken as lateral end of acetabulum. When

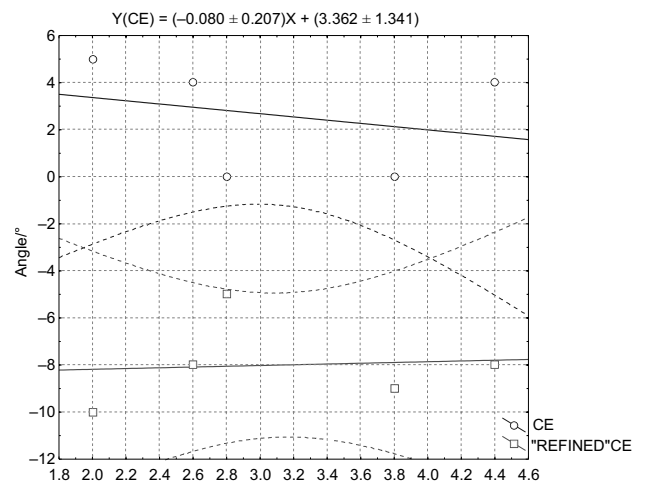


Fig. 3c. The hip development pattern of poor hip developing group in postreductive period. Trend of red line is positive, but trend of blue line is negative (blue color – Wiberg's CE angle values, red color – refined CE angle values).

measuring Wiberg's CE angle lateral referent point of acetabulum does not rely always on lateral end of subchondral sclerosis. The true end of acetabular roof according to Ogata is lateral end of subchondral sclerosis rather than visible bony end of acetabulum if the end point of subchondral sclerosis and visible bony end of acetabulum on AP hip radiograph are not the same point. According to that, slightly increasing values of Ogata's CE angles throughout patient growth means that hip really does develop. However, first negative values of Ogata's CE angles measured in early postreductive period and decrease of absolute values of Wiberg's CE angles as well as poor starting point for final hip development. These hips are at great risk for developing final dysplasia at the end of osteomaturity. Accord-

ing to many authors the most of dysplasia leads to hip arthrosis^{11–13}.

If Wiberg's CE angles measured at the end of osteomaturity are compared in good and control groups, statistically significantly lower values in good hip development group presenting less developed hip in comparison to opposite, healthy hip. It may be predicting factor of hip arthrosis as well¹⁴.

Conclusion

Absolute negative values of Ogata's CE angles measured within first postreductive years are poor prognos-

tic sign of hip development. Negative linear trend of the curve connecting Wiberg's CE angle values is a poor prognostic sign of hip development as well. In cases where negative initial Ogata's CE angle values are combined with negative linear trend of Wiberg's CE angles prognosis is extremely poor and hip should be at least closely monitored. The hip in patient with unilateral DDH after reduction will not develop as hip on contralateral, healthy side. All patients after reduction of congenitally luxated hip, regardless of treatment success, should be periodically monitored. Both Wiberg's and Ogata's CE angle are of prognostic value regarding hip development and should be measured when evaluating AP radiographs of infant's hip.

REFERENCES

1. ORTOLANI, M.: Un segno poco noto sua importanza par la diagnosi di preluazione congenitale dell'anca. *Pediatria* 45 (1937) 129. — 2. CASTELEIN, R. M., *Ned. Tijdschr. Geneesk.* 146 (2002) 1077. — 3. SCHILT, M., *Ultraschall. Med.*, 22 (2001) 39. — 4. KARAPINAR, L., F. SURENKOK, H. OZTURK, M. R. US, L. YURDAKUL, *Acta Orthop. Traumatol. Turc.*, 36 (2002) 106. — 5. WIRTH, T., L. STRATMANN, F. HINRICHS, *J. Bone Joint Surg. Br.*, 86 (2004) 585. — 6. LEWIS, K., D. A. JONES, N. POWELL, *J. Pediat. Orthop.*, 19 (1999) 760. — 7. OGATA, S., M. MORIYA, K. TSUCHIYA, T. AHITA, M. KAMEGAYA, M. SOMEGA, *J. Bone Joint Surg. Br.*, 72 (1990) 190. — 8. SEVERIN, E., *Acta Chir.*

Scand., 63 (1941) 1. — 9. SEVERIN, E., *J. Bone Joint Surg. (Am)* 32 (1950) 507. — 10. WARD, W. T., M. VOGT, J. S. GRUDZIAK, Y. TUMER, P. C. COOK, R. D. FITCH, *J. Bone Joint Surg. (Am)* 79 (1997) 656. — 11. SCHATZKER J.: *The intertrochanteric osteotomy.* (Springer Verlag, Berlin, 1983). — 12. COOPERMAN, D. R., R. WALLENSTEN, S. D. STULBERG, *Clin. Orthop.*, 175 (1983) 79. — 13. DUDKIEWICZ, I., M. SALAI, A. GANEL, A. BLANKSTEIN, A. CHECHIK, *Arch. Orthop. Trauma Surg.*, 122 (2002) 139. — 14. GIBSON, P. H., M. K. D. BENSON, *J. Bone Joint Surg. (Br)*, 64 (1982) 169.

A. Tudor

Clinic for Orthopedic Surgery Lovran 51415 Lovran, Croatia
e-mail: anton.tudor@email.t-com.hr

PROGNOŠTIČKA VRIJEDNOST »PROČIŠĆENOG« WIBERGOVOG KUTA U RAZVOJU ZGLOBA KUKA

SAŽETAK

Mjerenjem različitih kutova na radiogramu kuka procijenjuje se razvoj zgloba, ali njihova prognostička vrijednost kod pacijenata sa dijagnosticiranim razvojnim poremećajem kuka je upitna. Cilj je našeg istraživanja da se objektivizira mogućnost prognoze razvoja kuka putem mjerenja radiograma kuka Wibergovim CE kutom kao i CE kutom modificiranim prema Ogati. Retrospektivnom studijom analiziran je razvoj 119 kukova u 61 pacijenta poslije repozicije prirođenog iščašenja u dobi od 3 mjeseca starosti pa do pune koštane zrelosti. Prema rezultatima mjerenja CE kutova formirane su skupine s dobrim, odnosno lošim razvojem kuka. Zdravi kukovi na suprotnoj strani, u pacijenata s jednostranim razvojnim poremećajem kuka, čine kontrolnu skupinu kukova. Negativan linearan trend krivulje koja povezuje početne vrijednosti Wibergovih CE kutova, isto kao i prosječne negativne vrijednosti u prvim mjerenjima pročišćenog CE kuta, upućuju na loš razvoj kuka. U slučajevima gdje u prvim mjerenjima prosječne negativne vrijednosti pročišćenog CE kuta idu zajedno sa negativnim linearnim trendom Wibergovih CE kutova, prognoza razvoja kuka je iznimno loša. Wibergov, isto kao i pročišćeni CE kut, ima prognostičku vrijednost u razvoju zgloba kuka. Prema tome, oba mjerenja na AP radiogramu dječjeg kuka mogu se koristiti za procjenu stanja kuka.