

Tibial Stress Fracture Simulate Osteomyelitic Foci in the Course of Chronic Recurrent Multifocal Osteomyelitis

Rožmanić, Vojko; Zamolo, Gordana; Gulan, Gordan; Bilić, Iva; Jotanović, Zdravko

Source / Izvornik: **Collegium antropologicum, 2013, 37, 1347 - 1351**

Journal article, Published version

Rad u časopisu, Objavljena verzija rada (izdavačev PDF)

Permanent link / Trajna poveznica: <https://urn.nsk.hr/urn:nbn:hr:184:262939>

Rights / Prava: [In copyright](#) / [Zaštićeno autorskim pravom.](#)

Download date / Datum preuzimanja: **2024-08-31**



Repository / Repozitorij:

[Repository of the University of Rijeka, Faculty of Medicine - FMRI Repository](#)



Tibial Stress Fracture Simulate Osteomyelitic Foci in the Course of Chronic Recurrent Multifocal Osteomyelitis

Sandor Roth¹, Vojko Rožmanić², Gordana Zamolo³, Gordan Gulan⁴, Iva Bilić² and Zdravko Jotanović⁴

¹ University of Rijeka, School of Medicine, University Hospital Center Rijeka, Department for Children Orthopaedics, Rijeka, Croatia

² University of Rijeka, School of Medicine, University Hospital Center Rijeka, Clinic for Pediatrics, Rijeka, Croatia

³ University of Rijeka, School of Medicine, University Hospital Center Rijeka, Department of Pathology, Rijeka, Croatia

⁴ University of Rijeka, School of Medicine, Clinic for Orthopaedic Surgery Lovran, Lovran, Croatia

ABSTRACT

Chronic recurrent multifocal osteomyelitis (CRMO) is an extremely rare and most severe form of chronic nonbacterial osteomyelitis of unknown etiology. Here we present the first case of a six-year-old girl in which was observed that the stress fracture mimic osteomyelitic foci in the course of CRMO.

Key words: chronic recurrent multifocal osteomyelitis, bone lesions, negative microbiological cultures, stress fracture

Introduction

Chronic recurrent multifocal osteomyelitis (CRMO) is an autoinflammatory bone disease which was first described by Giedion et al. in 1972¹. It is characterized by an insidious onset of bone pain, soft tissue swelling, fever and osteolysis with an unpredictable course of exacerbations and spontaneous remissions^{2,3}. CRMO predominantly affects children and adolescents⁴⁻⁶, primarily girls with a mean age at onset of 8.5 years and a mean time to diagnosis of 8.5 months⁷, accounting for 2–5% of all osteomyelitis cases⁸. It is one of more severe types of chronic nonbacterial osteomyelitis⁹. The etiology of CRMO is still not elucidated but it is probably due to infection, immune deficiency or autoimmunity². Several recent studies indicate contribution of genetic factors to the etiology of CRMO¹⁰⁻¹². Localization of inflammatory bone lesions is similar to those of hematogenous osteomyelitis in childhood, i.e. metaphyses of long bones¹³. However, other skeletal localizations have been described as well, such as the vertebral body, the clavicle, the ribs, the sternum, the sphenoid bones, the pelvis, and the mandible¹⁴⁻¹⁶. The diagnosis of this rare entity is difficult because of its vague clinical presentation and course⁸, and is made after exclusion¹⁴. Given the fact that there is no

specific treatment for it, the goal of its management is effective pain control^{4,5}.

Case Report

A 6-year-old female patient was admitted to our department due to the pain in her left leg after weight-bearing. Physical evaluation revealed swelling, redness and tenderness of the skin above the left ankle joint, and limping. She was afebrile and in good general condition. Her family and personal history was insignificant. Laboratory findings showed an elevated white blood cell (WBC) count, which was $20.2 \times 10^9/L$, and an elevated erythrocyte sedimentation rate (ESR), which was 25 mm/h. Other laboratory values were normal. Radiographs of the left ankle showed two osteolytic foci above the distal tibial growth plate. Computerized tomography (CT) of the left ankle showed two osteolytic areas with sharp sclerotic edges. Magnetic resonance imaging (MRI) of the left ankle was recommended for better visualization of the cancellous bone and the surrounding bone marrow, particularly due to the vicinity of the physis. It revealed two

osteolytic foci above the physis involved in the tibial metaphyses with cortical erosion and signs of swelling of the surrounding spongiosis, indicating osteomyelitis (Figure 1). Because of the above-mentioned CT and MRI findings, we performed open biopsy, trepanation and curettage of the osteolytic foci. The patient was treated by

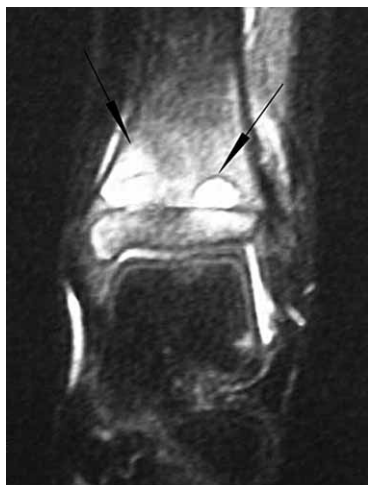

Fig. 1. MRI of the left ankle show two osteolytic foci (black arrows) above epiphyseal cartilage plate involved in the tibial metaphyses with denivelation of cortical bone and signs of swelling of the surrounding spongiosis.

ceftriaxone for seven days, when pustules on both forearms and shins appeared. Because of suspicion that the pustules were a consequence of an allergic reaction to the antibiotics applied, the treatment was changed to amoxicillin in combination with clavulanic acid perorally two times daily in doses of 475 mg through seven days. Osteolytic foci smears were negative, both to bacteria and acid resistant bacteria. Pathohistological findings showed acute osteomyelitis (Figure 2). On the 11th postoperative day the wound started to moist. Wound smear

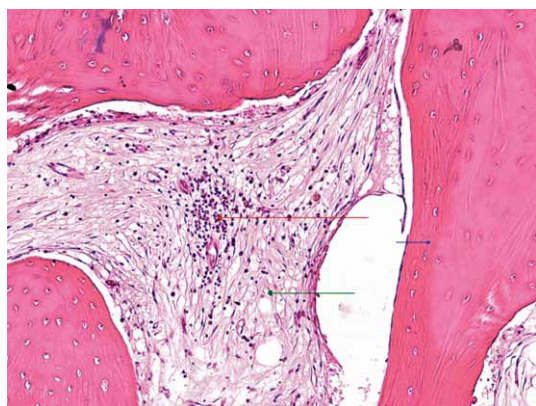


Fig. 2. Photomicrograph of bone fragment from osteolytic foci show edematous connective tissue stroma (green arrow) among bone trabecula (blue arrow) with lymphocytes infiltration (red arrow) (hematoxylin and eosin, original magnification x 200).

was taken, stitches removal postponed, and the wound was rebandaged every second day. Cast immobilization of the shin without weight-bearing was ordered and she was discharged from the hospital.

The first smear of the wound was sterile. The second wound smear showed MRSE (methicillin-resistant *Staphylococcus epidermidis*). The patient was readmitted to hospital and was given trimetoprim-sulfometoxazol perorally two times daily in doses of 480 mg through fourteen days. The wound dried but did not heal completely. Mild, temporary toothache appeared and panoramic radiographs of the jaw showed granulomas on the roots of two teeth. After extraction of the teeth, the wound on the shin healed completely. The smear of the root of the teeth showed *Streptococcus viridans*. The smear previously taken from the shin revealed MRSE. Evidently, there was no correlation between the osteomyelitic foci and teeth granulomas. We believed that the MRSE was skin superinfection and that the patient had been cured.

Four months later, she complained of pain, swelling and redness in the right shin. She was subfebrile with elevated ESR (27 mm/h) and WBC ($11 \times 10^9/L$). Radiographs of the right shin were negative. Due to suspected osteomyelitis, bed rest and ceftriaxone through 15 days were ordered. After that we continued with a 3rd generation cephalosporin perorally through 9 days. Control radiographs, bone scan and CT showed stress fracture at the proximal part of the right tibial diaphysis (Figures 3a, 3b and 3c), so we immediately stopped the antibiotic therapy. Two months after, the stress fracture healed after a resting period. Once again we thought that the patient had been cured.

However, the patient returned two years later, limping on the right leg and complaining of a pain and mild swelling in the area of the right heel. She was subfebrile with elevated ESR (26 mm/h). Radiographs, bone scan and MRI showed osteolytic lesions in the talus and calcaneus (Figures 4a, 4b and 4c). A needle biopsy was conducted and the pathohistological findings indicated osteomyelitis. Microbiological findings were negative. Ibuprofen and clindamycin were administrated perorally through 15 days and resulted in resolution of the symptoms. The recurrence of symptoms, the chronic course, multifocality and lack of evidence of a specific cause of osteomyelitis led us to suspect CRMO. We also isolated DNA (deoxyribonucleic acid) for molecular analysis of the LPIN2 (lipin 2) gene (exon 4 and 17) because of suspected Majeed syndrome. Molecular analysis of the LPIN2 genes showed none of the mutations searched for.

A year later, the patient returned complaining of pain and mild swelling in the area of the medial condyle of the right tibia. Radiographs, bone scan (Figure 5) and MRI showed identical changes in the area next to the proximal physis of the right tibia, the left sacrum and ilium to those found on previous locations. Biopsy of the right tibial foci showed the same pathohistological findings and the smear did not show any bacteria. We treated the patient with symptomatic therapy (effective pain control) and the patient was without symptoms.

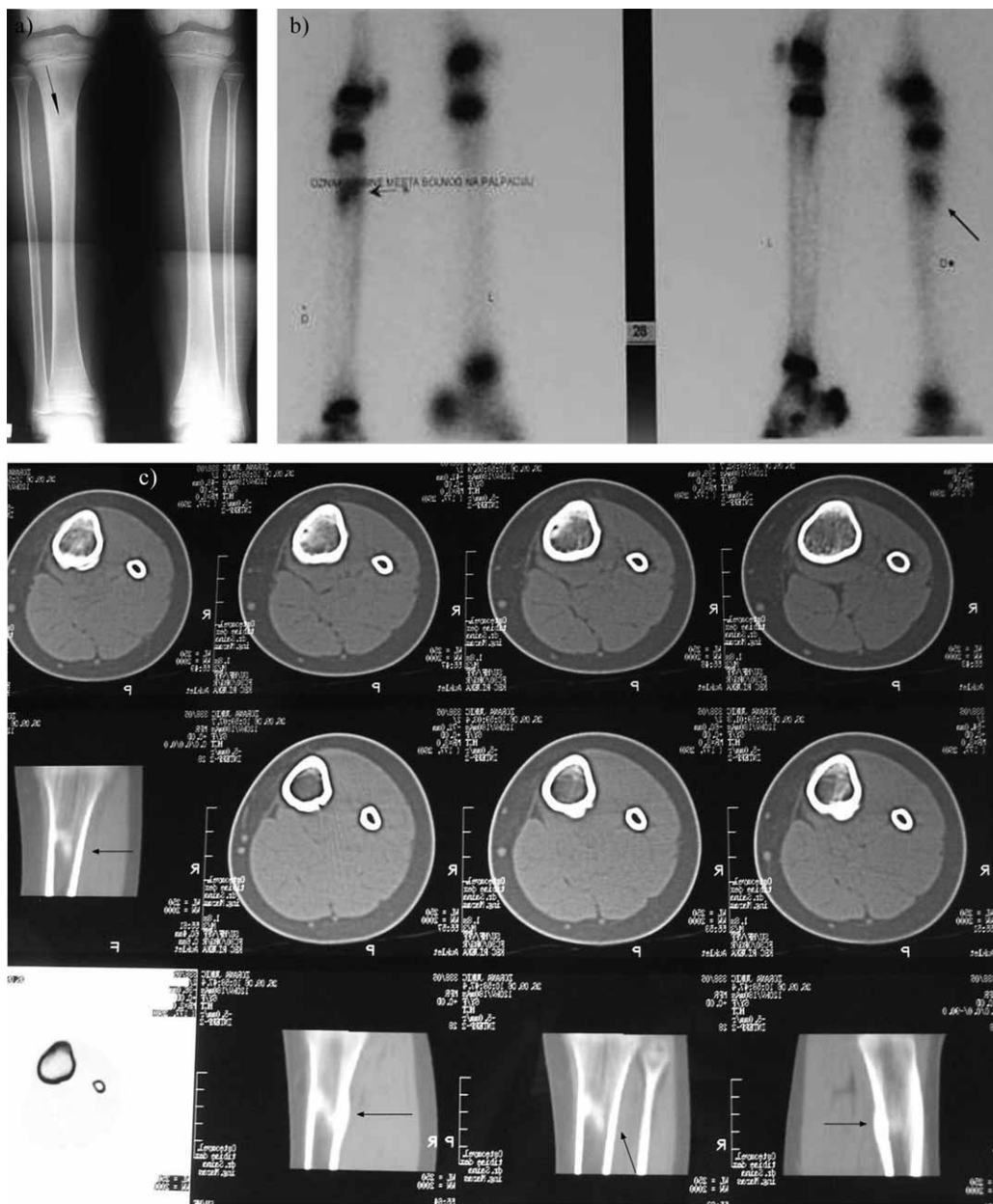


Fig. 3 a) The control radiographs, b) bone scan, and c) CT showing stress fracture (black arrows) at the proximal part of diaphysis of the right tibia.




Fig. 4 a) Lateral radiographs, b) bone scan, and c) MRI of the right ankle showing osteolytic lesions in talus and calcaneus (black arrows).

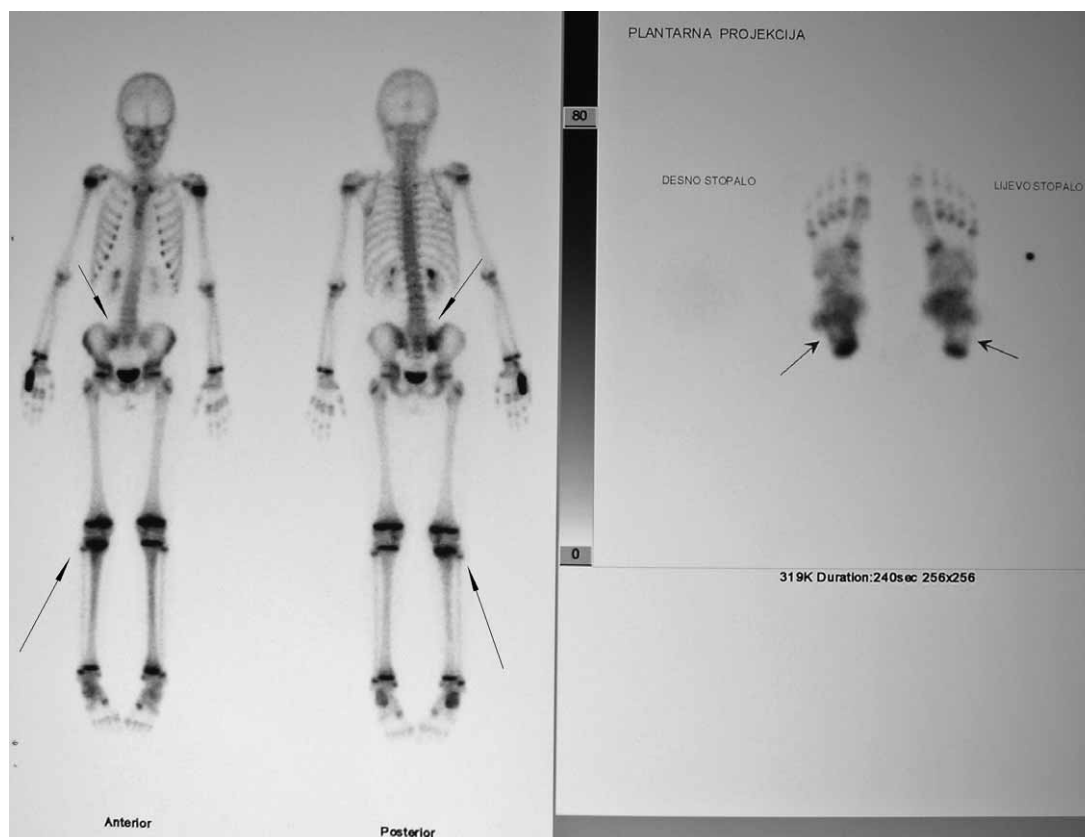


Fig. 5. Bone scan show increased radionuclide uptake in the area next to the proximal growth plate of the right tibia and left sacroiliac joint (black arrows).

Discussion

CRMO is a well-described but poorly understood clinical entity with diagnostic and therapeutic dilemmas. One of such poorly understood parts of the puzzle called CRMO are its long-term sequelae (complications). We can tentatively divide them in two main groups. The first group are skeletal complications, such as sclerosis, premature epiphyseal fusion, long bone deformity, growth arrest, progressive kyphosis^{17,18}, »migratory« or »saltatory« spondylitis which represents spinal involvement from the mid-cervical spine to the sacrum, and ultimately vertebra plana – vertebral deformity due to compression and total collapse¹⁹. The second groups are the so-called non-skeletal complications, such as school difficulties, psoriasis and the inflammatory bowel disease²⁰. According to our knowledge, no short-term skeletal complications of the CRMO, such as stress fracture of the tibia in our case, have been described.

A stress fracture is caused by repetitive bone overloading which exceeds its mechanical capacity²¹. There are two types of stress fractures: fatigue fractures, caused by excessive loads in normal bones, and insufficiency fractures, caused by normal loads in bones with reduced mechanical properties^{22,23}. When the overload persists during the phase of bone weakening, microdamage accumulation may also cause a stress fracture²⁴. Pediatric

stress fractures are rare²⁵. Approximately one half of all stress fractures in children and adults are tibial fractures^{26,27}. Tibial stress fractures are the most common lower extremity stress fracture^{26,28}. They are especially common in sports involving running and jumping^{28,29}. Pediatric tibial stress fractures usually occur in the anterior proximal one third of the bone, whereas in adults, they occur at the junction of the middle and the distal thirds of the tibia²⁷.

We believe that in our case the stress fracture of the proximal part of the tibial diaphysis was a consequence of long-lasting overloading of the right leg and unloading of the left leg because of a threatening fracture of the distal part of the left tibia after abundant curettage. Also, this stress fracture of the proximal part of the right tibial diaphysis, being an unusual and so far not described complication in the course of CRMO, was concealed with the common clinical picture of osteolytic foci.

In conclusion, when dealing with CRMO, possible short-term skeletal complications, such as stress fracture of the healthy leg after abundant curettage of the opposite leg, should always be considered. The above-mentioned unusual and hitherto not described complications can be disguised and easily misdiagnosed with the usual clinical picture of osteolytic foci in the course of CRMO.

REFERENCES

1. GIEDION A, HOLTHUSEN W, MASEL LF, VISCHER D, *Ann Radiol*, 15 (1972) 329. — 2. EL-SHANTI HI, FERGUSON PJ, *Clin Orthop Relat Res*, 462 (2007) 11. — 3. MIETTUNEN PMH, WEI X, KAURA D, RESLAN WA, AGUIRRE AN, KELLNER JD, *Pediatr Rheumatol Online J*, 7 (2009) 2. — 4. PIDDO C, REED MH, BLACK GB, *Skeletal Radiol*, 29 (2000) 94. — 5. HUBER AM, LAM PY, DUFFY CM, YEUNG RS, DITCHFIELD M, LAXER D, COLE WG, KERR GRAHAM H, ALLEN RC, LAXER RM, *J Pediatr*, 141 (2002) 198. — 6. JANSSON A, RENNER ED, RAMSER J, MAYER A, HABAN M, MEINDL A, GROTE V, DIEBOLD J, JANSSON V, SCHNEIDER K, BELOHRADSKY BH, *Rheumatology (Oxford)*, 46 (2007) 154. — 7. INSALACO A, BOZZOLA E, CAMPANA A, PAGNOTTA G, TONIOLO RM, CIOFETTA GC, BARBUTI D, CORTIS E (2008) *Pediatr Rheumatol*, 6 (2008) 188. — 8. BRILAKIS E, AGGOURIS K, POTAMITIS N, GKIOKAS A, E.E.X.O.T., 60 (2009) 41. — 9. GIRSCHICK HJ, RAAB P, SURBAUM S, TRUSEN A, KIRSCHNER S, SCHNEIDER P, PAPADOPOULOS T, MÜLLER-HERMELINK HK, LIPSKY PE, *Ann Rheum Dis*, 64 (2005) 279. — 10. GOLLA A, JANSSON A, RAMSER J, HELLEBRAND H, ZAHN R, MEITINGER T, BELOHRADSKY BH, MEINDL A, *Eur J Hum Genet*, 10 (2002) 217. — 11. FERGUSON PJ, CHEN S, TAYEH MK, OCHOA L, LEAL SM, PELET A, MUNNICH A, LYONNET S, MAJEED HA, EL-SHANTI H, *J Med Genet*, 42 (2005) 551. — 12. FERGUSON PJ, BING X, VASEF MA, OCHOA LA, MAHGOUB A, WALDSCHMIDT TJ, TYGRET T, SCHLUETER AJ, EL-SHANTI H, *Bone*, 38 (2006) 41. — 13. BJÖRKSTÉN B, BOQUIST L, *J Bone Joint Surg Br*, 62 (1980) 376. — 14. DABOV G, Osteomyelitis. In: CANALE T. *Cambell's operative orthopaedics* (Mosby Inc, St. Louis, USA, 10th ed., 2003). — 15. CHUN CSY, *Pediatrics*, 113 (2004) 380. — 16. CARR AJ, COLE WG, ROBERTON DM, CHOW CW, *J Bone Joint Surg Br*, 75 (1993) 582. — 17. BROWN T, WILKINSON RH, *Radiology*, 166 (1988) 493. — 18. KING SM, LAXER RM, MANSON D, GOLD R, *Pediatr Infect Dis J*, 6 (1987) 907. — 19. SCHILLING F, FEDLMEIER M, ECKKARDT A, KESSLER S, *Rofo*, 174 (2002) 1236. — 20. HUBER AM, LAM PY, DUFFY CM, YEUNG RS, DITCHFIELD M, LAXER D, COLE WG, KERR GRAHAM H, ALLEN RC, LAXER RM, *J Pediatr*, 141 (2002) 198. — 21. FOTTNER A, BAUR-MELNYK A, BIRKENMAIER C, JANSSON V, DÜRR HR, *Int Orthop*, 33 (2009) 489. — 22. DAFFNER RH, PAVLOV H, *Am J Roentgenol*, 159 (1992) 245. — 23. PENTECOST RL, MURRAY RA, BRINDLEY HH, *JAMA*, 28 (1964) 1001. — 24. STERLING JC, EDELSTEIN DW, CALVO RD, WEBB R, *Sports Med*, 14 (1992) 336. — 25. DE LA CUADRA P, ALBINANA J, *Int Orthop*, 24 (2000) 47. — 26. BENNELL KL, BRUKNER PD, *Clin Sports Med*, 16 (1997) 179. — 27. COADY CM, MICHELI LJ, *Clin Sports Med*, 16 (1997) 225. — 28. MONTELEONE GP, *Orthop Clin North Am*, 26 (1995) 423. — 29. MAITRA RS, JOHNSON DL, *Clin Sports Med*, 16 (1997) 259.

S. Roth

University of Rijeka, School of Medicine, University Hospital Center Rijeka, Department for Children Orthopaedics, Istarska 43, 51000 Rijeka, Croatia
e-mail: rothmed@ri.htnet.hr

PRIJELOM ZAMORA GOLJENICE OPONAŠA OSTEOMIJELITIČNO ŽARIŠTE U TIJEKU KRONIČNOG REKURENTNOG MULTIFOKALNOG OSTEOMIJELITISA

SAŽETAK

Kronični rekurentni multifokalni osteomijelitis (CRMO) je iznimno rijedak, a ujedno i najteži oblik kroničnog ne-bakterijskog osteomijelitisa nepoznate etiologije. U ovom prikazu slučaja opisujemo prvi slučaj da prijelom zamora oponaša osteomijelitično žarište u tijeku CRMO kod šestogodišnje djevojčice.

