

A New Tibial Torsiometer Applicable to Clinical Practice

Šestan, Branko; Gulan, Gordan; Tudor, Anton; Miletić, Damir; Prpić, Tomislav; Rakovac, Ivan

Source / Izvornik: **Collegium antropologicum, 2009, 33, 37 - 41**

Journal article, Published version

Rad u časopisu, Objavljena verzija rada (izdavačev PDF)

Permanent link / Trajna poveznica: <https://um.nsk.hr/um:nbn:hr:184:926572>

Rights / Prava: [In copyright](#)/[Zaštićeno autorskim pravom.](#)

Download date / Datum preuzimanja: **2025-01-09**



Repository / Repozitorij:

[Repository of the University of Rijeka, Faculty of Medicine - FMRI Repository](#)



A New Tibial Torsiometer Applicable to Clinical Practice

Branko Šestan¹, Gordan Gulan¹, Anton Tudor¹, Damir Miletić², Tomislav Prpić¹ and Ivan Rakovac¹

¹ Orthopaedic University Hospital Lovran, Lovran, Croatia

² Department of Radiology, Faculty of Medicine, University Hospital Centre »Rijeka«, Rijeka, Croatia

ABSTRACT

This study evaluated a new tibial torsiometer that is universally applicable to all limb sizes and requires no special training, jigs, or radiographic equipment. To compare the reliability of measurements obtained with the torsiometer, 160 tibias were evaluated with both the torsiometer and computed tomography. Results for both methods were identical in 51 tibias, within 1° in 66 tibias, and within 2° in 43 tibias. The difference between the two methods was not significantly different. No significant differences were found among examiners. This device should prove to be useful for the quantification of tibial torsion.

Key words: tibial torsion, computed tomography, measurements, torsiometer

Introduction

Knowledge of the normal range of tibial torsion and its accurate clinical measurement is important in the assessment of torsional deformities¹. Accurate measurement of tibial torsion in children is particularly important to reduce lower-limb rotational defects such as in-toeing and out-toeing in adulthood.

Various mechanical, radiographic, computed tomography, and ultrasound methods have been suggested for measuring tibial torsion^{2–9}. Radiographic methods require trained personnel, present an additional expense and radiographic exposure, and are not applicable to the incompletely developed osseous structures of children¹⁰.

Despite the availability of imaging techniques, clinical examination still provides the basis for management of this condition. However, the accurate determination of tibial torsion in vivo is relatively difficult as there are no obvious relevant landmarks that can be used as reference points.

Noninvasive techniques for measuring tibial torsion include a standard goniometer^{11–13}, caliper¹⁴, and torsiometer, which is a device using a fixed marker on the tibial tuberosity and a goniometer to measure the malleoli position^{15,16}. However, these devices are somewhat cumbersome for routine clinical use and have not been widely accepted.

To study and evaluate tibial torsion, an effective and reliable technique for in vivo measurement is required.

Clinical assessment of tibial torsion by estimation of the angle formed by the transmalleolar axis with the axis of the knee joint is possible. Although convenient and inexpensive, these methods are grossly inaccurate and vary subjectively by both examiner and patient.

Few studies have examined the validity of noninvasive measurement techniques versus radiography or computed tomography (CT)^{8,13,17,18}. Malekafzali and Wood¹⁶ demonstrated agreement within 3° using a torsiometer and standard radiograph.

Because specialized equipment such as a torsiometer is seldom available or desired in a busy clinic setting, the need to establish the reliability of commonly used clinical methods and validity against direct measures such as CT is needed. The ideal means of quantification of tibial torsion should be simple, fast, inexpensive, and reliable while also minimizing subjective variables. This article describes a new tibial torsiometer applicable to clinical practice that satisfies these requirements.

Materials and Methods

The test group consisted of 80 healthy individuals (160 tibias) without history of orthopedic problems (38 women and 42 men). Mean age was 28 years (range, 21–36 years). Informed consent was obtained before inclusion in the study.




Fig. 1. Photographs showing the construct of the torsiometer: A= freely rotating telescopic tube, B=the adjustable arms, C=rubberized malleolar and epicondylar (femoral) cups, D=the goniometric scale on the spot of tube rotation.

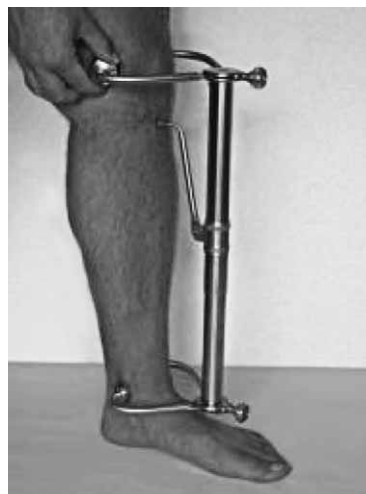

Fig. 2. Torsiometer in use.

The device is universally applicable and fully adjustable to accommodate a broad range of limb sizes, even in children. It consists of a freely rotating telescopic tube that retracts to 14 cm and arms at the end of the tube with rubberized malleolar and epicondylar (femoral) cups. A goniometric scale is precisely marked on the spot of tube rotation (Figure 1).

The epicondylar position of the femoral cups is interpreted to represent the transcondylar axis of the tibia. The knee can be in full extension; there is no need to flex the knee to represent the transcondylar axis of the tibia.

Placement of the malleolar cups over the medial and lateral malleoli with the epicondylar (femoral) cups in place rotates the telescopic tube (Figure 2). The angle thus described by the goniometer reflects the angle formed by the transmalleolar axis with the transcondylar

axis of the tibia. This measurement technique only requires a few seconds.

To compare the reliability of the measurements obtained with the torsiometer, 160 tibias were evaluated with both the torsiometer and the CT method described by Stuberg et al¹⁹ and Widjaja et al²⁰. Goniometric measurements were recorded by 3 physical therapists with more than 10 years of experience. Instruction was provided, and a pilot study using 30 volunteers was completed before data collection.

The pilot study was designed to standardize the torsiometric technique and minimize the learning effect between testers. Volunteers were positioned upright with their knee extended, and their ankle was positioned in neutral dorsi/plantar flexion. Each tester obtained 3 measurements, and the mean value of the 3 recordings by each tester was calculated. Testers were blinded for both CT results and torsiometric results of other testers.

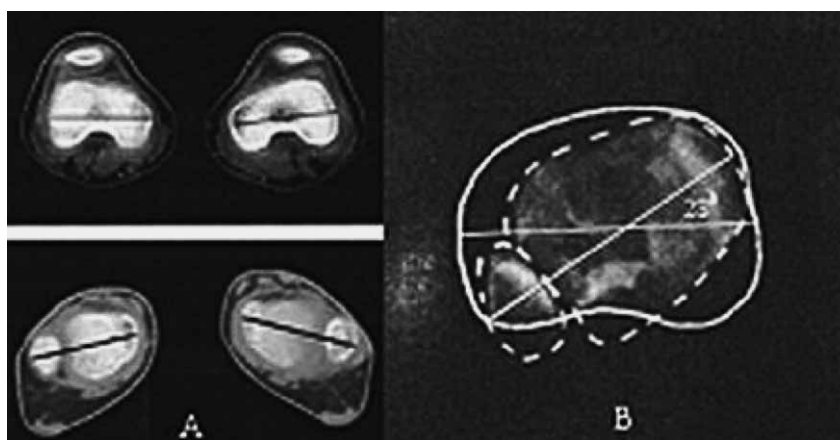


Fig. 3. Computed tomography method for measuring tibial torsion. The ends of the transcondylar (femoral) and transmalleolar axis represent the placement of the epicondylar (femoral) and malleolar cups of the torsiometer. The epicondylar position of the femoral cups is interpreted to represent the transcondylar axis of the tibia (A). On the superimposed tibial and malleolar scans, the angle described by the goniometric scale reflects the angle formed by the transmalleolar axis with the transcondylar axis of the tibia (B).

TABLE 1
COMPARISON OF MEASUREMENT OF TIBIAL TORSION:
CLINICAL TORSIOMETER VS. CT

No.	Clinical torsiometer		CT	
	Right	Left	Right	Left
1	15	13	15	14
2	14	13	13	14
3	17	17	17	19
4	14	14	14	16
5	15	15	17	16
6	16	16	18	18
7	14	15	14	15
8	16	15	18	17
9	17	17	17	17
10	16	16	16	15
11	14	15	16	17
12	12	13	14	13
13	13	15	13	16
14	13	15	14	14
15	15	15	14	15
16	15	14	16	15
17	14	17	15	17
18	14	14	14	15
19	15	16	14	16
20	14	16	15	17
21	20	14	20	13
22	14	14	14	15
23	16	8	15	7
24	13	14	14	15
25	13	12	15	12
26	15	15	17	15
27	16	14	17	14
28	14	15	14	16
29	15	15	17	15
30	15	15	15	15
31	15	15	16	14
32	16	16	15	17
33	15	13	15	15
34	15	15	16	17
35	15	14	17	16
36	13	12	13	13
37	14	12	13	12
38	13	15	13	14
39	15	14	13	12
40	15	14	14	15
41	14	15	13	13
42	13	13	14	14
43	11	10	12	11
44	14	14	13	14

(continued)

(continued)

No.	Clinical torsiometer		CT	
	Right	Left	Right	Left
45	12	12	12	13
46	10	10	10	10
47	14	15	14	13
48	12	13	12	14
49	14	14	12	12
50	15	14	14	16
51	15	13	16	14
52	14	13	13	14
53	17	17	19	19
54	14	14	14	16
55	15	15	17	16
56	16	16	18	18
57	14	15	14	15
58	16	15	18	17
59	17	17	17	17
60	16	16	18	15
61	15	15	17	15
62	16	14	16	14
63	14	15	14	16
64	15	15	17	15
65	15	15	15	15
66	15	15	15	14
67	16	16	15	17
68	15	13	14	15
69	15	15	15	17
70	15	14	17	16
71	13	12	13	13
72	14	12	14	12
73	13	15	14	14
74	13	12	15	14
75	15	14	15	15
76	14	15	13	13
77	13	12	15	12
78	15	14	14	16
79	12	13	12	14
80	16	8	15	7

For the CT measurements, volunteers were positioned supine and adhesive tape was used to stabilize their feet and thighs. The CT scan measurements (Figure 3) were performed by one of the authors who had no knowledge of the torsiometric results.

Kruskal-Wallis nonparametric analysis of variance (ANOVA) was used to determine between-tester differences. Wilcoxon's rank sum test was calculated by tester to compare the CT versus torsiometric measures. The 95% confidence interval on the difference between means

for two methods also was calculated. Level of significance was set to $P < 0.05$.

Results

Table 1 shows comparison of the mean measurements for the torsiometer and CT. Of the 160 tibias, measurements for both methods were identical in 51 tibias, within 1° in 66 tibias, and within 2° in 43 tibias.

Mean tibial torsion values were 14.78° (range, $7\text{--}20^\circ$) for CT and 14.34° (range, $8\text{--}20^\circ$) for the torsiometer. The difference between the two methods was not significant as determined by the Wilcoxon test. The confidence intervals for the data indicate that in general, the mean difference between the two methods was within a range of a 1° to 2° . No significant difference was found among testers (Kruskal-Wallis ANOVA).

Discussion

Lower limb rotational profile in children is frequently a cause of great concern to parents. Determination of tibial torsion is important in order to give parents clear information. In pathologic conditions accurate measurement of tibial torsion is essential for preoperative planning and postoperative follow-up. Clinical importance of accurate measurement in patients with cerebral palsy cannot be overemphasized as it grossly affects gait capability.

Herein, non-invasive tool to accurately measure tibial torsion is described and compared with CT measurement. Lawand et al. in 2004²¹ described a device for measurement of the tibial torsion angle using a set of rulers. Distance between both center of medial et lateral malleolus and posterior buttress was measured. Third ruler measured intermalleolar distance. After gathering variables arch tangent function of angle between malleoli was calculated. This arch tangent function corresponded to the value of torsion angle. This study has several limitations compared to our study. As measurements are taken in knee flexion, rotation of the lower leg could highly affect measurement results. Furthermore, our results were compared to CT results which is not the case in study described by Lawand et al. Limitation of our tool could be skin motion artifacts during placement of the tool on epicondyles and malleoli, as well as the size of calf.

This could be avoided by firm adjustment of apparatus on previously properly cleaned skin. In order to further reduce result dispersion we suggest that at least three consecutive measurements for each leg be performed. Mean value of these three results should be taken as final result. Our tool can be used in almost all age groups ex-

cept newborns and extremely obese patients as reference points on malleoli are difficult to detect.

The magnitude of difference in our study comparing the goniometric and CT methods is comparable to the variability inherent in recording goniometric measures and may not represent a clinically significant difference. The results indicate that the clinicians should expect an error of 1° to 2° as being routine for goniometry in normal individuals, and a change of greater magnitude is necessary to denote a difference other than by measurement error alone.

The variability among the testers in our study is consistent with the findings in other goniometric reliability studies^{22–26}. Although not essential for measuring torsion, with 3 observers per volunteer, we additionally wanted to test the accuracy of the application of the torsiometer to the leg. Low²⁴ reported a range of mean error from 0.6° to 3.3° . Similar findings were reported by Boone et al²², with standard deviations of inter-tester measures at the hip, knee, and ankle ranging from 1.5° to 4.6° . Ekstrand et al²³ measured hip, knee, and ankle motions in 22 normal individuals and reported a mean standard deviation of 3.7° (range, $2.5^\circ\text{--}5.5^\circ$).

The results of our study are consistent with the findings of Malekafzali and Wood¹⁶. They reported a 3° range of error for tibiofibular torsion in their study comparing a torsiometer and standard radiographs in healthy adults.

Our findings, however, do not support the conclusions of Luchini and Stevens¹² who reported inter-tester differences of approximately 25° in 7 patients measured on 2 occasions by 6 examiners. The authors concluded a difference of at least 25° may be caused by tester error. Our study found that an error of approximately 3° may be caused by measurement error. In three cases more than one half of difference between the two legs was found in both torsiometric and CT measurements. As no history nor physical evaluation revealed clinically relevant abnormalities, these cases can only be treated as margins of normal distribution.

This new torsiometer should prove to be a useful tool for the quantification of tibial torsion as well as a useful adjunct in the management of torsional deformities. It is universally applicable to all limb sizes and requires no special training, jigs, or radiographic equipment.

This method is simple, rapid, convenient, inexpensive, accurate, and reliable. The technique of measuring minimizes subjective variables and does not require highly trained personnel.

We have used this device for more than 3 years in our clinical practice, and it has proven to be useful and practical. In this study, the results obtained using the torsiometer compared favorably with accepted CT methods.

REFERENCES

1. SASS P, HASSAN G, *Am Fam Physician*, 68 (2003) 461. — 2. BOUCHARD R, MEEDER PJ, KRUG F, LIBICHER M, *Rofo*, 176 (2004) 1278.

— 3. KRISTIANSSEN LP, GUNDERSON RB, STEEN H, REIKERAS O, *Skeletal Radiol*, 30 (2001) 519. — 4. REIKERAS O, KRISTIANSSEN LP,

- GUNDERSON R, STEEN H, Acta Orthop Scand, 72 (2001) 53. — 5. PFEIFER T, MAHLO R, FRANZREB M, HEISS U, LUTZ P, WÖHRLE A, WIKSTRÖM M, In Vivo, 9 (1995) 257. — 6. ECKHOFF DG, JOHNSON KK, Clin Orthop Relat Res, 302 (1994) 42. — 7. SAYLI U, BOLUKBASI S, ATIK OS, GUNDOĞDU S, J Foot Ankle Surg, 33 (1994) 144. — 8. BUTLER-MANUEL PA, GUY RL, HEATLEY FW, Br J Radiol, 65 (1992) 119. — 9. LANG LM, VOLPE RG, J Am Podiatr Med Assoc, 88 (1998) 160. — 10. RIMONDI E, BUSACCA M, MOLINARI M, ROLLO G, ANDRISANO A, MARTINI A, MONTI C, Radiol Med, 89 (1995) 22. — 11. KING HA, STAHELI LT, Foot Ankle, 4 (1984) 180. — 12. LUCHINI M, STEVENS DB, J Pediatr Orthop, 3 (1983) 41. — 13. STAHELI LT, CORBETT M, WYSS C, KING H, J Bone Joint Surg Am, 67 (1985) 39. — 14. HEROLD HZ, MARCOVICH C, Acta Orthop Scand, 47 (1976) 112. — 15. HUTCHINS PM, RAMBICKI D, COMACCHIO L, PATERSON DC, J Pediatr Orthop, 6 (1986) 452. — 16. MALEKAFZALI S, WOOD MB, Clin Orthop Relat Res, 145 (1979) 154. — 17. RITTER MA, DEROSA GP, BABCOCK JL, Clin Orthop Relat Res, 120 (1976) 159. — 18. STAHELI LT, ENGEL GM, Clin Orthop Relat Res, 86 (1972) 183. — 19. STUBERG W, TEMME J, KAPLAN P, CLARKE A, FUCHS R, Clin Orthop Relat Res, 272 (1991) 208. — 20. WIDJAJA PM, ERMERS JW, SIJBRANDIJ S, DAMSMA H, KLINKHAMER AC, J Comput Assist Tomogr, 9 (1985) 466. — 21. LAWAND SJ, RAMALHO JR, SMITH RL, Rev Bras Ortop, 39 (2004) 420. — 22. BOONE DC, AZEN SP, LIN CM, SPENCE C, BARON C, LEE L, Phys Ther, 58 (1978) 1355. — 23. EKSTRAND J, WIKTORSSON M, OBERG B, GILLQUIST J, Arch Phys Med Rehabil, 63 (1982) 171. — 24. LOW JL, Physiotherapy, 62 (1976) 227. — 25. MAYERSON NH, MILANO RA, Arch Phys Med Rehabil, 65 (1984) 92. — 26. ROTHSTEIN JM, MILLER PJ, ROETTGER RF, Phys Ther, 63 (1983) 1611.

I. Rakovac

Orthopaedic University Hospital – Louran, M. Tita 1b, HR-51415 Louran, Croatia
e-mail: ivan.rakovac@gmail.com

NOVI TIBIJALNI TORZIOMETAR PRIMJENJIV U PRAKSI

SAŽETAK

Ova studija vrednuje novi tibijalni torziometer. Torziometer je univerzalno primjenjiv u praksi neovisno o veličini ekstremiteta i ne zahtijeva specijalni trening, šablone ili radiološku opremu. Kako bi provjerili pouzdanost mjerenja dobivenih torziometrom, uspoređena su mjerenja torzije na 160 tibija pomoću torziometra i CT pretrage. Rezultati obje metoda su identični na 51 tibiji, unutar 1° na 66 tibija i unutar 2° na 43 tibije. Zaključno nije pronađena značajna razlika između metoda mjerenja, kao ni između ispitivača. Ovaj rad dokazuje da je novi tibijalni torziometer koristan u kvantifikaciji tibijalne torzije.